

Distinct Patterns of Chronic Gastritis Associated with Carcinoid and Cancer and Their Role in Tumorigenesis

ENRICO SOLCIA, M.D., Ph.D.,^a GUIDO RINDI, M.D., Ph.D.,^a
ROBERTO FIOCCA, M.D., Ph.D.,^a LAURA VILLANI, M.D.,^a
ROBERTO BUFFA, M.D., Ph.D.,^b LUCIANA AMBROSIANI, M.D.,^c
AND CARLO CAPELLA, M.D., Ph.D.^c

^aDepartment of Human Pathology and Genetics, Pathologic Anatomy Section, I Medical Faculty, University of Pavia and IRCCS Policlinico San Matteo, Pavia, Italy;

^bInstitute of Pathologic Anatomy, Faculty of Medicine, University of Milan, Milan, Italy;

^cDepartment of Human Pathology and Genetics, Pathologic Anatomy Section, II Medical Faculty, University of Pavia at Varese, Italy

Received July 6, 1992

A series of 60 gastric endocrine tumors comprised 44 body-fundus argyrophil carcinoids, of which 23 arose in a background of hypergastrinemia and type A chronic atrophic gastritis (A-CAG), mainly with histologic patterns suggestive of an autoimmune process. Only 22 percent (compared with 19 percent of 58 tumor-free A-CAG cases) of 36 carcinoids and 21 percent of 19 A-CAG carcinoids investigated had *Helicobacter pylori* (HP) colonization, against 50 percent of 14 CAG-associated neuroendocrine carcinomas or mixed endocrine-exocrine tumors, 84 percent of 150 cases with early gastric cancer ($p < 0.001$ versus carcinoids), mostly with B- or AB-type CAG, 76 percent of 97 tumor-free AB-CAG, and 95 percent of 151 tumor-free B-CAG cases. Secondary hypergastrinemia and local mechanisms activated by chronic autoimmune gastritis are among factors involved in the pathogenesis of relatively indolent CAG-associated carcinoids, whereas active HP gastritis in cooperation with environmental carcinogens may likely cause more severe epithelial transformation, leading to ordinary cancer and, possibly, to neuroendocrine carcinomas or mixed endocrine-exocrine tumors.

The association between gastric body-fundus carcinoids and autoimmune body-fundus (type A) chronic atrophic gastritis (CAG) with hypergastrinemia is well documented [1-5]. The recent detection of *Helicobacter pylori* (HP) antibodies in serum of elderly people with type A CAG [6] as well as the progressive evolution of some antrum-body (type AB) pangastritis into A-type CAG [7] suggest that end-stage HP-related type A CAG may also contribute to carcinoid development. In addition, there have been reports of carcinoids arising in non-CAG gastric mucosa, either with hypergastrinemia and multiple endocrine neoplasia/Zollinger-Ellison syndrome (MEN/ZES) [8] or without hypergastrinemia [4,9-11].

The association of CAG or CAG-related intestinal metaplasia (IM) with gastric

793

Abbreviations: A-CAG: type A chronic atrophic gastritis CAG: chronic atrophic gastritis ECL: enterochromaffin-like EGCa: early gastric cancer EMA: epithelial membrane antigen HID: high-iron diamine HP: *Helicobacter pylori* IM: intestinal metaplasia MEN/ZES: multiple endocrine neoplasia/Zollinger-Ellison syndrome NEC: neuroendocrine carcinoma NSE: neuron-specific enolase PA: pernicious anemia PCONA: periodic acid-concanavalin A PAS: periodic acid-Schiff PGE₂: prostaglandin E₂ PGP: protein gene product

Address reprint requests to: Prof. Enrico Solcia, Dept. of Human Pathology, Via Forlanini 16, I-27100 Pavia, Italy

Copyright © 1992 by The Yale Journal of Biology and Medicine, Inc.
All rights of reproduction in any form reserved.

cancer of "intestinal" (i.e., glandular) type is well documented [12–14]. Follow-up studies have outlined the increased cancer risk inherent to CAG and IM [15], although intestinal phenotypes were not more frequent in CAG/IM associated glandular cancers than in CAG/IM unrelated diffuse cancers [16,17]. In addition, both serological prospective [18,19] and histological retrospective studies [20,21] have found HP infection, with resultant chronic gastritis, to be positively associated with gastric cancer, either of intestinal or diffuse histology.

In this paper, non-tumor mucosa from patients with and without gastric carcinoids, neuroendocrine carcinomas, or early cancers has been investigated for distinctive patterns of tumor-associated gastritis. Attention specifically focused on HP colonization and gastritis activity, atrophy, or topography as possible factors in tumorigenesis.

MATERIALS AND METHODS

Histologic material and clinical records of all the 60 gastric endocrine tumors (mean age, 52 years; 32 males, 28 females) available in the files of our departments due to personal observation or consultation were reinvestigated. Histologic sections from tumor tissue and non-tumor mucosa were stained with hematoxylin-eosin, Grimelius' silver impregnation for argyrophil cells, periodic acid-Schiff (PAS)-alcian blue pH 2.5, high-iron diamine (HID), and periodic acid-concanavalin A (PACONA) techniques for mucins, as well as Giemsa stain for *Helicobacter pylori* [17,22]. Immunoperoxidase tests for chromogranin A, serotonin, gastrin, somatostatin, pancreatic polypeptide, enteroglucagon, epithelial membrane antigen (EMA), pepsinogen II, M1 antigen of gastric surface mucin, CAR-5 intestinal antigen, HLA-DR antigen, L26 B lymphocyte antigen, and UCHL1 T-lymphocyte antigen were carried out as reported elsewhere [8,17,21,23,24].

Non-tumor mucosa from a surgical series of 150 early gastric cancers (EGCa; mean age, 63.2 years), an endoscopic series of 1,177 unselected tumor-free patients (mean age, 53.7 years), and 58 endoscopic tumor-free A-CAG were systematically investigated for HP and gastritis status according to previously reported criteria [24]. The EGCa series was collected during the years 1979–1991 in the Pavia and Varese sections of our department, while the unselected non-tumor series included all the patients undergoing endoscopy at the Endoscopic Unit of Pavia II Medical Clinic in the period 1987–1991 with diagnosis of active (228 cases) or healed (269) peptic ulcer, non-ulcer dyspepsia (631), or various non-gastric symptoms (49). The 58 A-CAG cases resulted from the addition of all the 42 cases observed in Varese, during the years 1979–1991, to the 16 cases found among the Pavia unselected series.

The chi-squared test was used for statistical analysis.

RESULTS

Gastritis and Endocrine Tumors

Tumor Histology The 60 cases of gastric endocrine tumors were classified, as reported in Table 1, based on their histology (Fig. 1) and on previously reported criteria [1–5,25,26]. They included 44 carcinoids (mean age, 51 years), nine neuroendocrine carcinomas (NEC, also called small-cell carcinomas, intermediate grade; mean age, 64), three of these with co-existing carcinoid, one gastrinoma, and six mixed endocrine-exocrine tumors (two combined carcinoid/early cancer, one com-

TABLE 1
Relationship Between Gastritis Status, HP Colonization, and Co-Existing Tumor

Mucosal Pathology	n	Tumor Disease	n	HP status	
				+ / Total	%
A-CAG	29	Carcinoid	23	4/19	21
		Adenocarcinoid	1	0/1	
		Carcinoid/NEC	3	2/3	
		Carcinoid/EGCa	1	1/1	
		Carcinoid/adenoma	1	0/1	
AB-CAG	5	Carcinoid/EGCa	1	1/1	
		Carcinoid/mucinousCa	1	0/1	50
		NEC	3	1/2	
CAG, type not assessed	7	Carcinoid	3	1/1	
		NEC	3	1/2	
		Carcinoid/NEC/ChorCa	1	0/1	
HG ± MEN/ZES	8	Carcinoid	8	2/7	
					20
None	10	Carcinoid, sporadic	10	1/8	
	1	Gastrinoma	1	1/1	
Endocrine tumors, total			60	15/49	31
Chronic gastritis ^a	150	EGCa, glandular		64/86	74
		EGCa, diffuse		46/46	100
		EGCa, mixed		16/18	89
A-CAG	58	None		11/58	19
AB-CAG	97	None		74/97	76
B-CAG	151	None		143/151	95
Non-atrophic gastritis	790	None		711/790	90

HP: *Helicobacter pylori*; CAG: chronic atrophic gastritis; NEC: neuroendocrine carcinoma; HG +/- MEN/ZES: hypertrophic gastropathy with (seven) or without (one) proven multiple endocrine neoplasia/Zollinger-Ellison syndrome; EGCa: early gastric cancer; MucinousCa: mucinous carcinoma, ChorCa: chorioncarcinoma 80 percent of which was CAG, B or AB type

bined carcinoid/tubular adenoma, one adenocarcinoid, one composite carcinoid/mucinous carcinoma, and one composite carcinoid/NEC/chorioncarcinoma). Detailed information on the clinicopathologic profile of the tumors has been reported elsewhere [26].

All carcinoids were histologically well differentiated, intensely chromogranin A-immunoreactive, argyrophil but not argentaffin, thus fulfilling the criteria for their diagnosis as enterochromaffin-like (ECL)-cell argyrophil carcinoids [2-5,9,11,25,26]. They arose in the fundus (sometimes involving cardiac mucosa), corpus, or transition between corpus and antrum, especially in the angular region.

Neuroendocrine carcinomas differed from carcinoids in showing immature, anaplastic cells with abundant mitoses, scarce reactivity for secretory granule markers (chromogranins, argyrophilia, hormones), and relatively abundant immunostaining for cytosolic endocrine markers such as neuron-specific enolase (NSE) or protein gene product (PGP) 9.5, as well as for the non-endocrine marker epithelial membrane antigen (EMA). An intimate admixture of carcinoid and NEC growths inside the same tumor was found only in two cases, possibly suggesting an origin of the NEC component from anaplastic change of a pre-existing carcinoid. One of these two

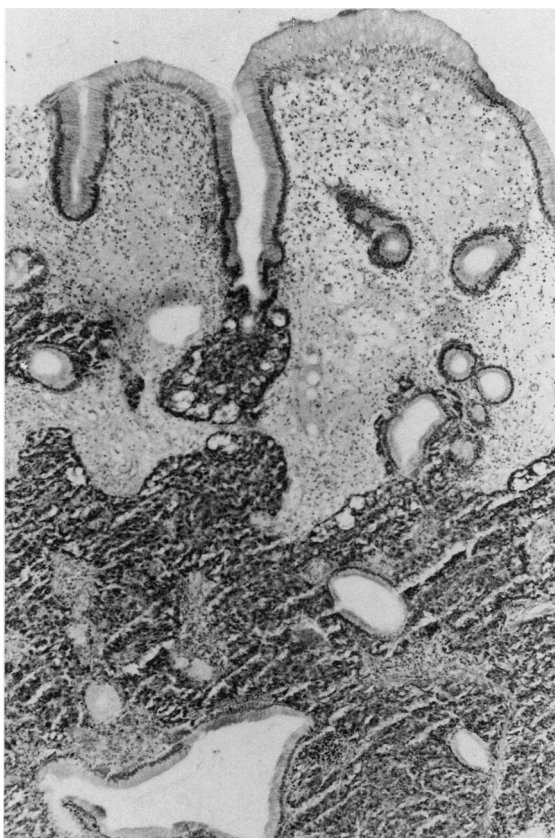


FIG. 1. Gastric argyrophil carcinoid admixed with hyperplastic growth of mature foveolae. Grimelius' silver, $\times 65$.

tumors, however, the carcinoid/NEC/chorioncarcinoma, had the histologic pattern of a highly malignant, complex tumor of unknown histogenesis. The remaining two composite tumors showed intimate admixtures of well-differentiated endocrine cells and either frankly carcinomatous mucous-secreting cells (carcinoid/carcinoma) or well-differentiated, mildly atypical mucopeptic cells reacting with pepsinogen II antibodies and the PACONA test for gastric glands mucin (adenocarcinoid) [10,22,23]. In addition, close association of carcinoid with apparently hyperplastic growth of foveolar cells was frequently observed (Fig. 1).

Associated Gastritis The histology of non-tumor gastric mucosa, with special reference to gastritis status and colonization by *Helicobacter pylori*, has been outlined in Table 1. Forty-one of the 60 tumors (68.3 percent), including 26 of the 44 (59 percent) carcinoids, and all NECs and mixed tumors, showed some kind of CAG in non-tumor mucosa. The remaining 19 cases (18 carcinoids and one gastrinoma) arose in gastritis-free or non-atrophic (less than 30 percent gland atrophy) gastritis mucosa, either with (eight cases) or without (ten cases) hypertrophic gastropathy due to hypergastrinemia. In 29 cases, CAG was restricted to corpus-fundus mucosa (type A); in five, it involved both antral and corpus-fundus mucosa (type AB); and in seven, the topographic type was not assessed due to insufficient material available. Among 19 type A CAG associated with carcinoids investigated, only four (21 percent) had HP colonization, against seven of the remaining 14 (50 percent) CAG

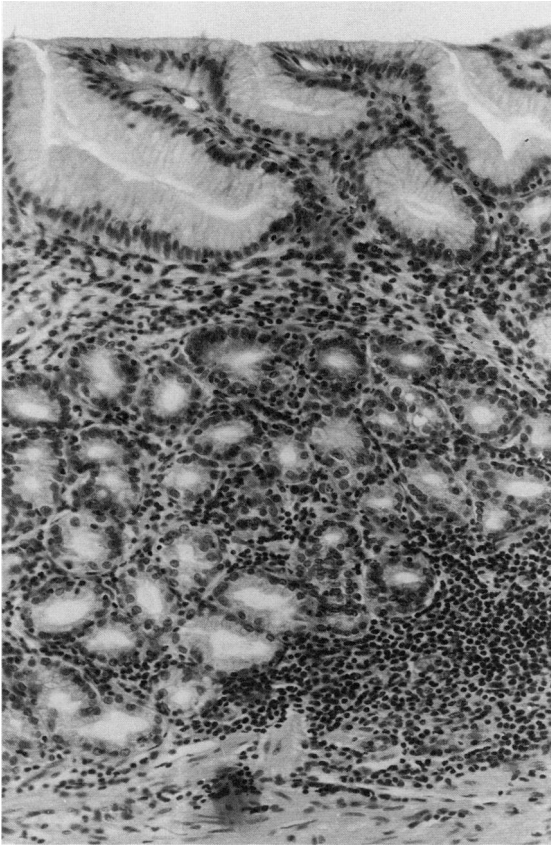


FIG. 2. HP-negative, type A chronic atrophic gastritis with diffuse total atrophy of acidopeptic glands and hyperplasia of mucous-neck cells. Pernicious anemia patient with serum anti-parietal cell antibodies and hypergastrinemia. Hematoxylin-eosin, $\times 160$.

cases showing a variety of tumors and CAG types (Table 1). Intestinal metaplasia was detected in corpus mucosa of 30 of 49 (61 percent) endocrine tumors investigated, including 21 of 35 (60 percent) carcinoids, 27 of 33 (82 percent) CAG-associated tumors, and 17 of 19 (89 percent) A-CAG carcinoids, with mean extension of metaplastic mucosa in positive cases of about 20–30 percent. In antral mucosa, intestinal metaplasia was consistently found only in the few cases with AB CAG.

Five of ten carcinoid patients with HP-negative type A CAG in whom pertinent hematologic investigations were performed showed pernicious anemia (PA). In another HP-negative A-CAG case showing corpus-fundus carcinoids and NEC, megaloblastic anemia developed five years after proximal gastric resection. Only one of 11 HP-positive CAG cases (seven of which were type A) with various kinds of tumors showed PA. In addition to type A CAG, this patient also had circulating anti-parietal cell antibodies as well as autoimmune thyroiditis. The class II histocompatibility antigen HLA-DR was abundantly expressed in non-endocrine epithelia of both HP-negative and HP-positive CAG mucosa. No HLA-DR antigen was detected in adjacent endocrine growths, however, either hyperplastic or dysplastic and neoplastic.

HP-negative A-CAG cases with PA (Fig. 2) were characterized by diffuse, total, or at least subtotal atrophy of acidopeptic glands, with disappearance of mature parietal

and chief cells coupled with hyperplasia of immature, basophilic, PGI-, PGII-, and PACONA-positive mucous neck cells (so-called pseudopyloric metaplasia) [22]. Deep, multifocal pyloric-type metaplasia (PGII- and PACONA-positive, but PGI-negative) with or without gastrin-immunoreactive G cells, more or less extensive intestinal metaplasia of small intestine (I) type, and more or less prominent foveolar hyperplasia with or without hyperplastic polyps were also found. Abundant inflammatory cells were observed in the lamina propria of deep and mid mucosa, with relative prevalence of lymphocytes (both B and T cells) over plasma cells, especially around immature mucous-neck glands with evidence of epithelial aggression and damage. Neutrophilic granulocytes were found only occasionally at sites of non-HP bacterial colonization of superficial mucosa. The antropyloric mucosa was either entirely normal or with mild, superficial, inactive gastritis and no epithelial damage or metaplastic change.

HP-positive CAG cases (Fig. 3) showed an abundance of plasma cells in the superficial half of the corpus fundus mucosa, with or without few neutrophilic granulocytes, abundance of lymphocytes (especially B cells in follicles, both B and T cells diffusely in the lamina propria) in the deep half, often coupled with fairly abundant eosinophils, mast cells, and macrophages. All 11 cases had HP colonization of inflamed corpus fundus mucosa, while only two of nine cases tested had antral mucosa colonization. Surviving areas or small groups of acidopeptic glands with mature parietal and chief cells, in addition to mucous-neck and transitional mucous-neck/chief cells [27], were found in all cases, especially in proximal fundus mucosa. Immature mucous-neck cell hyperplasia was less prominent, while intestinal metaplasia, partly of incomplete (II or III) type, was more abundant than in HP-negative PA cases. Antropyloric mucosa of cases with HP-positive corpus fundus CAG was characterized by various grades of chronic gastritis, from atrophic with intestinal metaplasia (AB-type CAG, two cases) to HP-positive interstitial-follicular type with relatively scarce activity and abundant plasma cells and B lymphocytes (one case), or HP-negative type with mild inflammation, often associated with myofibroblast proliferation in the mild and deep lamina propria (six cases). The latter pattern probably results from healing of antritis coupled with progression of atrophic corpus gastritis, a relatively frequent observation in older patients with chronic HP gastritis [6,7,24].

Gastritis and Early Cancer

As outlined in Table 1, of the 150 early gastric cancers investigated, 86 (57 percent) formed glandular structures (glandular or "intestinal" type), 46 (31 percent) were non-structured tumor growths (diffuse type), and 18 (12 percent) were mixed glandular/diffuse. HP colonization of non-tumor mucosa was detected in 126 cases (84 percent, $p < 0.001$ versus the 49 endocrine tumors, the 35 pure carcinoids, as well as the 19 A-CAG carcinoids investigated), including all diffuse tumors, 64 of 86 (74 percent) glandular, and 16 of 18 (89 percent) mixed tumors. Corpus fundus mucosa showed HP in 80 percent of cases against 60 percent of antropyloric mucosa. Gastritis activity was prominent at the foveolar-neck level of pyloric and/or corpus mucosa in the majority of cases.

CAG was found in 82 percent of the cases, of which 46 percent was B type (restricted to the antrum), 34 percent AB type, and 2 percent A type, while non-atrophic or mildly atrophic gastritis accounted for the remaining 18 percent.

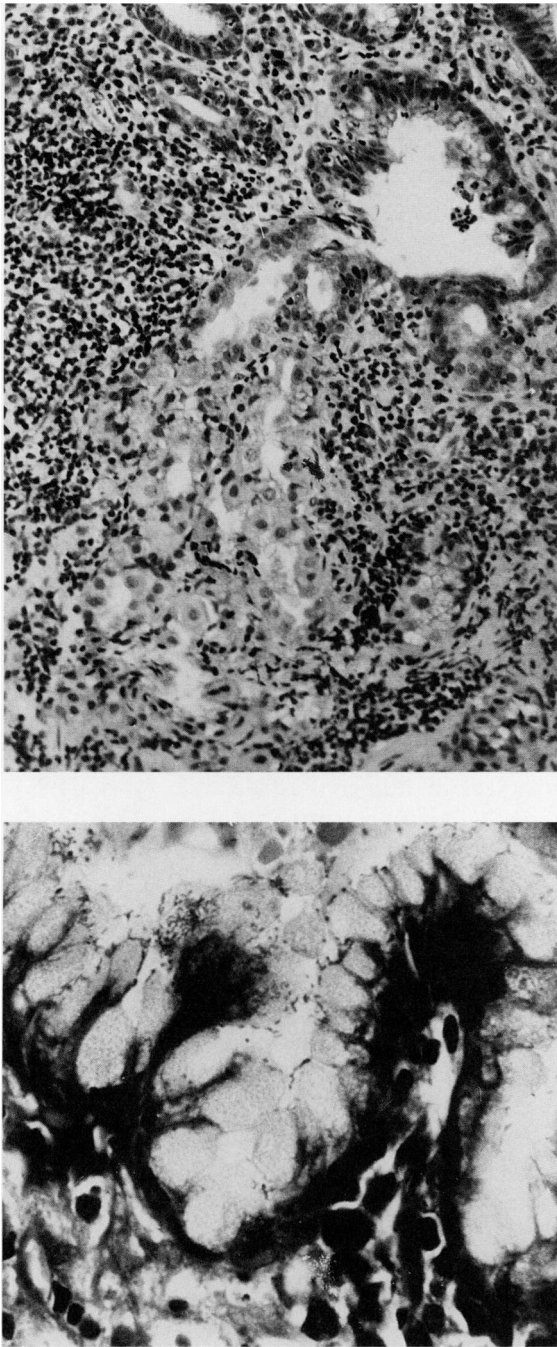


FIG. 3. **a.** HP-positive type A chronic atrophic gastritis with a surviving islet of mature acidopeptic glands surrounded by heavy lymphoid infiltrates. Hematoxylin-eosin, $\times 160$. **b.** HP colonization of damaged superficial-foveolar epithelium in a non-atrophic area of acidopeptic mucosa, from a composite NEC-carcinoid case. Giemsa stain, $\times 600$.

This gastritis pattern differed significantly from that of endocrine tumors as a whole or of carcinoids, especially with regard to type A CAG excess among endocrine tumors/carcinoids ($p < 0.001$) and type B CAG excess ($p < 0.001$) among cancer patients. Among cancer patients, HP was detected in 91 percent of type B CAG, 75

percent of type AB, 50 percent of type A, and 100 percent of common gastritis, with slightly higher incidence in the antral mucosa for the last group and more obvious predominance in the corpus mucosa for the other groups.

As many as 88 percent of cases showed intestinal metaplasia in peritumor mucosa, 80 percent in antral mucosa, and 30 percent in corpus mucosa. Type III (sulfomucin-positive) intestinal metaplasia was detected in 56 percent of cases. Intestinal metaplasia as a whole and type III metaplasia were three to five times more abundant in stomachs with glandular cancer than in those with diffuse cancer.

Tumor-Free Gastritis

Unselected Series HP was found in 931 of 1,177 endoscopic patients (79.1 percent), including 27 of 49 asymptomatic subjects (55.1 percent), 462 of 631 patients with non-ulcer dyspepsia (73.2 percent), 71 of 76 active gastric ulcers (93.4 percent), 32 of 39 healed gastric ulcers (82.1 percent), 132 of 138 active duodenal ulcers (95.7 percent), and 194 of 230 healed duodenal ulcers (84.3 percent).

CAG was present in 264 patients (22.4 percent), including 12.8 percent type B, 8.2 percent type AB, and 1.4 percent type A, while 790 subjects (67.1 percent) had non-atrophic gastritis and 123 (10.5 percent) gastritis-free mucosa. The incidence of CAG as a whole was significantly lower ($p < 0.001$) than that of cancer, carcinoid, or endocrine tumor patients. By itself, the ten to 11 years' greater age of cancer patients, with respect to tumor-free patients, would correspond to a marginal, non-significant increase of CAG incidence from 22 to 28 percent in the latter population. A-CAG incidence was obviously higher ($p < 0.001$) in endocrine tumor or carcinoid (but not cancer) cases than in tumor-free cases, while the incidence of both B- and AB-CAG was higher in cancer than in tumor-free cases ($p < 0.001$), and that of B-CAG was lower in endocrine tumor than in tumor-free cases ($p < 0.05$). HP colonization was found in 95 percent of type B, 76 percent of type AB ($p < 0.001$ versus type B), 31 percent of type A ($p < 0.001$ versus type B as well as versus type AB), 90 percent of non-atrophic gastritis ($p < 0.001$ versus type AB as well as type A), and none of gastritis-free cases. No significant difference was observed with respect to corresponding gastritis groups of cancer or endocrine tumor patients.

Intestinal metaplasia (mostly type I) was observed in 25 percent of antral biopsies and 7 percent of corpus biopsies. Both figures were significantly lower ($p < 0.001$) than those observed in cancer patients as a whole or in glandular cancer cases. Combined antrum + corpus incidence of IM was near 0 percent in gastritis-free cases, 20 percent (extension about 5 percent) in common non-atrophic gastritis, 63 percent (antral extension about 30 percent) in type B, 70 percent (extension about 20–30 percent) in type AB, and 81 percent (corpus extension about 30 percent) in type A CAG.

Selected A-CAG Cases Among the 58 A-CAG cases, 11 (19 percent) showed HP colonization, which involved corpus mucosa in all cases and antral mucosa in seven cases. Ten of the 11 HP-positive cases showed a pattern of corpus gastritis characterized by residual acidopeptic glands, abundant plasma cells, granulocytes, and intestinal metaplasia (present in seven cases; mean extension, 30 percent of the mucosa), thus mimicking the HP-positive A-CAG associated with endocrine tumors, apart from increased activity. Forty-three of the 47 HP-negative cases showed a severe diffuse pattern of oxyntic gland atrophy with lack of mature acidopeptic glands, abundant pyloric/pseudopyloric metaplasia (covering about 50 percent of the glandular compartment, as against 20–30 percent in the former group), fewer plasma

cells and granulocytes, and less extensive intestinal metaplasia (present in 20 of the 43 cases, covering less than 10 percent of the mucosa as a mean), thus mimicking “autoimmune” A-CAG of endocrine tumor patients. Pernicious anemia was detected in 11 of the 35 cases (31 percent) from which hematologic data were available. All PA cases were HP-negative and showed the “autoimmune” type of A-CAG with diffuse gland atrophy.

DISCUSSION

Most gastric endocrine tumors investigated were from body-fundus or transitional body-antrum mucosa (95 percent) and showed morphological patterns of argyrophil carcinoids (73 percent), usually with ECL cells as a prominent component [4,10,26]. Twenty-three of 44 (52 percent) argyrophil carcinoids arose in a background of severe corpus fundus (type A) atrophic gastritis, coupled with achlorhydria-related hypergastrinemia, while three (7 percent) showed CAG of type not assessed.

Interestingly, hypergastrinemia has been observed in all A-CAG patients with carcinoids so far investigated [2–5,11,26], suggesting that both advanced A-CAG and the resulting hypergastrinemia are essential in the development of body fundus argyrophil carcinoids with very low malignant potential [26]. A crucial role of hypergastrinemia in the genesis of gastric argyrophil ECL-cell carcinoids has been conclusively shown in aged achlorhydric rats [28]. Circulating anti-parietal cell antibodies impairing acidopeptic gland maturation and function [29–31] as well as HLA-DR-mediated autoimmune aggression to non-endocrine gastric epithelia, with special reference to mucous-neck cells, may account for the severe atrophy of acidopeptic glands in autoimmune type A CAG, often associated with pernicious anemia. The incomplete pattern of gland atrophy (frequently leaving patchy areas of surviving glands with mature parietal and chief cells) that we observed in most HP-positive A-CAG cases may explain their failure to develop pernicious anemia.

Composite tumors showing an intimate admixture of endocrine and exocrine cells, as in two of our cases, suggest that some body fundus endocrine tumors may originate from neoplastic transformation of pluripotent epithelial stem cells that retain some capacity of dual, endocrine, and non-endocrine differentiation [32]. Stem-cell growth seems also involved in the histogenesis of neuroendocrine carcinomas which, in addition to undifferentiated and poorly differentiated endocrine cells, often show more or less prominent non-endocrine glandular or even squamous components [10,33].

The co-existence of topographically separate endocrine and exocrine tumors (as in three of our cases) can be explained by their sharing of some risk factor or condition. Indeed, pernicious anemia patients with A-type CAG are known to be at increased risk for both carcinoids and cancer [34]. Gastrin, a growth factor for ECL cells [35] and related tumors [28], as well as for epithelial stem cells in the oxyntic mucosa [35], might have a role in the pathogenesis of both endocrine and exocrine tumors arising in the corpus fundus, possibly by acting in combination with other factors released locally during chronic inflammation, such as some prostaglandins [36,37] and lymphokines [38–40] known to modulate both endocrine and exocrine gastric epithelia. This hypothesis would also explain the frequent, intimate association of foveolar hyperplasia, known to be promoted by prostaglandin E₂ (PGE₂), and underlying carcinoids.

As for ordinary gastric cancer, it must be recalled that oxyntic gland cell lines are only seldom found in such tumors, where gastrin-independent intestinal and pyloric lines largely predominate [16,17,23,41]. In fact, hypergastrinemia seems to inhibit

rather than stimulate pyloric carcinogenesis, providing mucosal contact with acid juice is preserved [43], while its role in intestinal carcinogenesis is controversial [44,45].

The high incidence of HP colonization in stomachs with early cancer (84 percent, $p < 0.001$ versus carcinoids) was in the same range as that found in simultaneously investigated gastric (93 percent) or duodenal (96 percent) ulcers, two well-established HP-related diseases, and in non-ulcer dyspepsia (73 percent), also known to be in part related to HP gastritis [24], while it differed significantly ($p < 0.001$) from that of subjects free of gastric symptoms (55 percent). Thus, our colonization findings further support the hypothesis suggested by serologic studies, combined with epidemiologic [46] and prospective investigations [18,19], that HP infection may represent a major risk factor for gastric cancer. The fact that diffuse cancer, unrelated to intestinal metaplasia [13,21], has even higher HP colonization (100 percent versus 74 percent, $p < 0.001$) and HP-related risk [19] than does metaplasia-related "intestinal" cancer suggests that, in addition to the carcinogenic pathway leading from CAG to intestinal metaplasia and dysplasia [12–14], another mechanism also contributes to the HP-related risk. It seems possible that the active inflammation observed at foveolar neck level of EGCa patients causes oxidative stress to generative zone epithelia as well as increased proliferation and topographic expansion of the epithelial stem cells, up to superficial epithelia exposed to environmental carcinogens [21]. Direct interaction of lumen-contacting cells retaining proliferative potential and endoluminal carcinogens has already been shown to be crucial in rat carcinogenesis [47].

HP incidence was very low in both CAG-associated (21 percent) and CAG-unrelated (20 percent) carcinoids, and similar to that of tumor-free A-type CAG (19 percent). Moreover, carcinoid-associated gastritis was usually inactive or poorly active, even when HP-positive. As discussed above, other factors, unrelated to HP and intestinal metaplasia, must be involved in carcinoid pathogenesis.

In conclusion, it seems likely that, despite the occurrence of HP in a small proportion of stomachs bearing endocrine tumors, active HP gastritis has little role in the pathogenesis of gastric argyrophil carcinoids. The hypergastrinemia-producing type A CAG, be it purely autoimmune or end stage of HP gastritis, when found in association with carcinoids, is as a rule inactive; that is, devoid of granulocytes. On the contrary, active HP gastritis seems to have a major role in the pathogenesis of gastric cancer, leading preferentially to glandular cancer in a background of type AB or B CAG, coupled with extensive intestinal metaplasia (especially of type III), and to diffuse cancer in the presence of type B CAG or non-atrophic gastritis without type III metaplasia, with or without moderately developed type I metaplasia.

ACKNOWLEDGEMENTS

This work was supported in part by grants from the Italian National Research Council (National Gastroenterology Group and Special Oncology Project) and Ministry of Health (to IRCCS Policlinico San Matteo) and Education.

REFERENCES

1. Wilander E: Achylia and the development of gastric carcinoids. *Virchows Arch (Pathol Anat)* 391:151–160, 1981
2. Carney JA, Go VLW, Fairbanks VF, Moore SB, Alport EC, Nora FE: The syndrome of gastric argyrophil carcinoid tumors and nonantral gastric atrophy. *Ann Int Med* 99:761–766, 1983
3. Borch K, Renvall H, Liedberg G: Gastric endocrine cell hyperplasia and carcinoid tumours in pernicious anemia. *Gastroenterology* 88:638–648, 1985

4. Solcia E, Capella C, Sessa F, Rindi G, Cornaggia M, Riva C: Gastric carcinoid and related endocrine growths. *Digestion* 35 (Supplement 1):3–22, 1986
5. Sjoblom S-M, Sipponen P, Karonen S-L, Jarvinen H: Mucosal argyrophil endocrine cells in pernicious anaemia and upper gastrointestinal carcinoid tumours. *J Clin Path* 42:371–377, 1989
6. Karnes WE Jr, Samloff IM, Siurala M, Kekki M, Sipponen P, Kim SWR, Walsh JH: Positive serum antibodies and negative tissue staining for *Helicobacter pylori* in subjects with atrophic body gastritis. *Gastroenterology* 101:167–174, 1991
7. Ihamaki T, Kekki M, Sipponen P, Siurala M: The sequelae and course of chronic gastritis during a 30- to 34-year bioptic follow-up study. *Scand J Gastroenterol* 20:485–491, 1985
8. Solcia E, Capella C, Fiocca R, Rindi G, Rosai J: Gastric argyrophil carcinoidosis in patients with Zollinger-Ellison syndrome due to type 1 multiple endocrine neoplasia. A newly recognized association. *Am J Surg Pathol* 14:503–513, 1990
9. Grigioni WF, Caletti GC, Gabrielli M, Marrano D, Villanacci V, Mancini A: Gastric carcinoids of ECL cells. Pathological and clinical analysis of eight cases. *Acta Pathol Jpn* 35:361–375, 1985
10. Solcia E, Fiocca R, Sessa F, Rindi G, Gianatti A, Cornaggia M, Capella C: Morphology and natural history of gastric endocrine tumors. In *The Stomach as an Endocrine Organ*. Edited by R Hakanson, F Sundler. Amsterdam, The Netherlands, Elsevier, 1991, pp 473–498
11. Bordi C, Yu JY, Baggi MT, Davoli C, Pilato FP, Baruzzi G, Gardini G, Zamboni G, Franzin G, Papotti M, Bussolati G: Gastric carcinoids and their precursor lesions. A histologic and immunohistochemical study of 23 cases. *Cancer* 67:663–672, 1991
12. Correa P, Sasano N, Stemmermann GN, Haenszel W: Pathology of gastric carcinoma in Japanese populations: Comparisons between Miyagi prefecture, Japan and Hawaii. *JNCI* 51:1449–1457, 1973
13. Johansen A: Early gastric cancer. A contribution to the pathology and to gastric cancer histogenesis. Copenhagen, Denmark, Bispebjerg Hospital, 1981
14. Sipponen P, Kekki M, Siurala M: Atrophic chronic gastritis and intestinal metaplasia in gastric carcinoma. Comparison with a representative population sample. *Cancer* 52:1062–1068, 1983
15. Ihamaki T, Sipponen P, Varis K, Kekki M, Siurala M: Characteristics of gastric mucosa which precede occurrence of gastric malignancy. Results of long-term follow-up of three family samples. *Scand J Gastroenterol* 26 (Supplement 186):16–23, 1991
16. Furihata C, Tatematsu M, Miki K, Katsuyama T, Sudo K, Miyagi N, Kubota T, Jin S-S, Kodama K, Ito N, Koniski Y, Suzuki K, Matsushima T: Gastric- and intestinal-type properties of human gastric cancers transplanted into nude mice. *Cancer Res* 44:727–733, 1984
17. Fiocca R, Villani L, Tenti P, Cornaggia M, Finzi G, Capella C, Prat M, Bussolati G, Solcia E: Widespread expression of intestinal markers in gastric carcinoma: A light and electron microscopic study using BD-5 monoclonal antibody. *J Clin Path* 41:178–187, 1988
18. Nomura A, Stemmermann GN, Chyou PH, Kato I, Perez-Perez GI, Blase MJ: *Helicobacter pylori* infection and gastric carcinoma among Japanese Americans in Hawaii. *N Engl J Med* 325:1132–1136, 1991
19. Parsonnet J, Friedman GF, Vandersteen DP, Chang Y, Vogelmann JH, Orentreich N, Sibley RK: *Helicobacter pylori* infection and the risk of gastric carcinoma. *N Engl J Med* 325:1127–1131, 1991
20. Parsonnet J, Vandersteen D, Goates J, Sibley RK, Pritikin J, Chang Y: *Helicobacter pylori* infection in intestinal- and diffuse-type gastric adenocarcinomas. *JNCI* 83:640–643, 1991
21. Solcia E, Fiocca R, Villani L, Luinetti O, Gianatti A, Trespi E, Stella E, Cornaggia M, Chiaravalli A, Capella C: The role of *Helicobacter pylori* gastritis in ulcerogenesis and cancerogenesis. In *Proceedings of the IV Workshop on Gastrointestinal Pathology and Helicobacter Pylori*. Edited by G Gasbarrini, S Pretolani. Berlin, Germany, Springer-Verlag, in press
22. Solcia E, Capella C, Fiocca R, Cornaggia M, Rindi G, Villani L, Bosi F, Ambrosiani L: Exocrine and endocrine epithelial changes in types A and B chronic gastritis. In *Helicobacter Pylori, Gastritis and Peptic Ulcer*. Edited by P Malfertheiner, H Ditschuneit. Berlin, Germany, Springer-Verlag, 1990, pp 245–258
23. Fiocca R, Cornaggia M, Villani L, Capella C, Solcia E, Samloff M: Expression of pepsinogen II in gastric cancer. Its relationship to local invasion and lymph node metastases. *Cancer* 61:956–962, 1988
24. Fiocca R, Villani L, Luinetti O, Gianatti A, Perego M, Alvisi C, Turpini F, Solcia E: *Helicobacter* colonization and histopathologic profile of chronic gastritis in patients with or without dyspepsia, mucosal erosion and peptic ulcer. A morphologic approach to the study of ulcerogenesis in man. *Virchows Arch A* 420:489–498, 1992
25. Solcia E, Bordi C, Creutzfeldt W, Dayal Y, Dayan AD, Falkmer S, Grimelius L, Havu N: Histopathological classification of nonantral gastric endocrine growth in man. *Digestion* 41:185–200, 1988

26. Rindi G, Luinetti O, Cornaggia M, Capella C, Solcia E: Three subtypes of argyrophilic carcinoid and the gastric neuroendocrine carcinoma. A clinicopathological study. *Gastroenterology*, in press
27. Cornaggia M, Capella C, Riva C, Finzi G, Solcia E: Electron immunocytochemical localization of pepsinogen I (Pgl) in chief cells, mucous-neck cells, and transitional mucous-neck/chief cells of the human fundic mucosa. *Histochemistry* 85:5–11, 1986
28. Mattsson H, Havu N, Brautigam J, Carlsson K, Lundell L, Carlsson E: Partial gastric corpectomy results in hypergastrinemia and development of gastric enterochromaffinlike-cell carcinoids in the rat. *Gastroenterology* 100:311–319, 1991
29. Lopes JD, Ito H, Glass GBJ: Inhibition of parietal and peptic cells proliferation by parietal cell- and intrinsic factor antibodies. *Gastroenterology* 70:910, 1976
30. Loveridge N, Bitensky L, Chayen J, Hausamen TU, Fisher JM, Taylor B, Gardner JD, Bottazzo GF, Doniach D: Inhibition of parietal cell function by human gammaglobulin containing gastric parietal cell antibodies. *Clin Exp Immunol* 41:264–270, 1980
31. De Aizpurua HJ, Cosgrove LJ, Ungar B, Toh B-H: Autoantibodies cytotoxic to gastric parietal cells in serum of patients with pernicious anemia. *N Engl J Med* 309:625–629, 1983
32. Caruso ML, Pilato FP, D'Adda T, Baggi MT, Fucci L, Valentini AM, Lacatena M, Bordi C: Composite carcinoid-adenocarcinoma of the stomach associated with multiple gastric carcinoids and nonantral gastric atrophy. *Cancer* 64:1534–1539, 1989
33. Matsui K, Kitagawa M, Miwa A, Kuroda Y, Tsuji M: Small cell carcinoma of the stomach: A clinicopathologic study of 17 cases. *Am J Gastroenterol* 86:1167–1175, 1991
34. Borch K: Epidemiologic, clinicopathologic and economic aspects of gastroscopic screening in patients with pernicious anemia. *Scand J Gastroenterol* 21:21–30, 1986
35. Tielemans Y, Hakanson R, Sundler F, Willems G: Proliferation of enterochromaffin-like cells in omeprazole-treated hypergastrinemic rats. *Gastroenterology* 96:723–729, 1989
36. Reinhart WH, Muller O, Halter F: Influence of long-term 16,16-dimethyl prostaglandin E2 treatment on the rat gastrointestinal mucosa. *Gastroenterology* 85:1003–1010, 1983
37. Nylander D, Berglindh T, Obrink KJ: Prostaglandin interaction with histamine release and parietal cell activity in isolated gastric glands. *Am J Physiol* 250:G607–G616, 1986
38. Teichmann RK, Pratschke E, Grab J, Hammer C, Brendel W: Gastrin release by interleukin-2 and γ -interferon in vitro (Abstract 23). *Can J Physiol Pharmacol (Supplement Sixth Internat Symposium on Gastrointestinal Hormones)*:62, 1986
39. Teichmann RK, Kramling HJ, Merkle T, Merkle R: Opposite effect of interleukin-1 on gastrin and bombesin release in cell suspension of antral mucosa. *Digestion* 46 (Supplement 1):114, 1990
40. Cucala M, Le T, Mugridge K, Parente L, Wallance JL: Inhibitory effects of interleukin-1 on gastric acid secretion are secretagogue-specific. *Gastroenterology* 100:A49, 1991
41. Capella C, Frigerio B, Cornaggia M, Solcia E, Pinzon-Trujillo Y, Chejfec G: Gastric parietal cell carcinoma. A newly recognized entity: Light microscopic and ultrastructural features. *Histopathology* 8:813–824, 1984
42. Fiocca R, Villani L, Tenti P, Cornaggia M, Finzi G, Riva C, Capella C, Bara J, Samloff M, Solcia E: The foveolar cell component of gastric cancer. *Human Pathol* 21:260–270, 1990
43. Deveney CW, Freeman H, Way LW: Experimental gastric carcinogenesis in the rat. Effects of hypergastrinemia and acid secretion. *Am J Surg* 139:49–54, 1980
44. Morris DL, Watson SA, Gurrant LG, Harrison JD: Hormonal control of gastric and colorectal cancer in man. *Gut* 30:425–429, 1989
45. Creutzfeldt W, Lambert R: Is hypergastrinaemia dangerous to man? *Scand J Gastroenterol* 26 (Supplement 180):179–191, 1991
46. Forman D, Sitas F, Newell DG, Stacey AR, Boreham J, Peto R, Campbell TC, Li J, Chen J: Geographic association of *Helicobacter pylori* antibody prevalence and gastric cancer mortality in rural China. *Int J Cancer* 46:608–611, 1990
47. Ohgaki H, Tomihari M, Sato S, Kleihues P, Sugimura T: Differential proliferative response of gastric mucosa during carcinogenesis induced by N-Methyl-N'-nitro-N-nitrosoguanidine in susceptible ACI rats, resistant Buffalo rats, and their hybrid F1 cross. *Cancer Res* 48:5275–5279, 1988