

## *M. pneumoniae* Respiratory Diseases: Clinical Features – Children

YASUTAKA NIITU, M.D.

*Department of Pediatrics, The Research Institute for Tuberculosis and Cancer,  
Tohoku University, Sendai, Japan*

Received January 4, 1983

---

Chest X-ray findings were studied in 618 pediatric patients with *M. pneumoniae* respiratory infections. Of these, 472 (76 percent) had pneumonia. Pneumonia was most frequently observed in the lower lung field and least frequently in the upper lung field.

The enlargement of hilar lymph nodes was observed in 34 percent of patients with *M. pneumoniae* pneumonia in contrast to 5 to 9 percent of patients with pneumonia due to other agents, suggesting that it was rather characteristic of *M. pneumoniae* pneumonia. It was observed in no patients below one year of age, in 41 percent of those aged one to five years, and then decreased with increase in age.

Of children with *M. pneumoniae* respiratory infections, fever, pneumonia, and positive CF test were less frequently observed in infants below one year, showing that they have slighter symptoms; positive IHA test was less frequently observed and isolation of *M. pneumoniae* was more frequently observed, as compared to other age groups, among whom these findings were similar. It must be kept in mind, however, that fatal cases of *M. pneumoniae* pneumonia in infants were reported.

---

*M. pneumoniae* respiratory infections in children in Sendai were studied from 1960 to July 1982, in the author's department of pediatrics. During this period the peak outbreaks of *M. pneumoniae* infections were observed in Sendai precisely every four years, in 1964, 1968, 1972, 1976, and 1980. Here I present the clinical features of the disease observed in the study.

### MATERIALS AND METHODS

#### *The Study Population*

The study population consisted of pediatric patients with *M. pneumoniae* respiratory infections, mainly with pneumonia, observed from 1960. They comprised two groups; one, pediatric patients with respiratory infections with or without pneumonia who visited our clinic complaining of symptoms from 1966 to July 1982, and the other, pediatric patients with pneumonia found in the annual mass chest photofluorographic surveys among school children in Sendai from 1960 to 1982. The study population of clinical and laboratory findings among age groups consisted of pediatric patients with *M. pneumoniae* respiratory infections who visited our clinic in 1980 and 1981 and those who visited Pediatric Clinic, Sendai Red Cross Hospital, in 1980 and 1981.

### *Diagnosis of M. pneumoniae Infection*

Throughout the studies, both isolation of *M. pneumoniae* and complement-fixation (CF) test were used for the diagnosis of *M. pneumoniae* infection. The combined use of the two methods could detect 95 percent of *M. pneumoniae* infection. Isolation of *M. pneumoniae* or a significant rise in CF antibodies of paired sera were considered to indicate *M. pneumoniae* infection. Kenny [1] noted that high titers in CF antibody are suggestive of recent infection and we [2] also confirmed it. Patients with respiratory infections whose first serum showed a high CF titer and who had no prior disease were diagnosed as having *M. pneumoniae* infections. In addition, the fermentation inhibition (FI) test and the indirect hemagglutination (IHA) test using formalinized, tanned sheep erythrocytes sensitized with *M. pneumoniae* as reported by Lind [3] or the freeze-dried product of the sensitized erythrocytes produced by Japan Lyophilizing Institute [4,5] were used in some patients. For isolation, diphasic medium was used. CF antibodies were determined by the use of boiled *M. pneumoniae* suspension as antigen.

## RESULTS

### *Chest X-Ray Findings*

I observed 633 pediatric patients with *M. pneumoniae* respiratory infections. Of these, chest X-ray films were taken of 618 (98 percent). Of the patients examined by X-ray film, X-ray findings were normal in 121 (20 percent) and abnormal in 497 (80 percent). Of the patients with abnormal X-ray findings, pneumonia was observed in 470, hilar lymph node enlargement only in 17, and increased bronchial markings only in 8.

### *Localization of Lesions of M. pneumoniae Pneumonia*

The localization of lesions of *M. pneumoniae* pneumonia on chest X-ray film was observed in 248 pediatric patients who visited our clinic and in 224 school children whose pneumonia was found in mass chest photofluorographic surveys in Sendai. Of the 248 patients, one lung field was involved in 195 (79 percent) and two or more lung fields in 55 (22 percent), and the upper lung field was involved in 26 percent, the mid-lung field in 37 percent, and the lower lung field in 61 percent. Of the 224 patients, the corresponding values were 216 (96 percent) and 8 (4 percent), and 9 percent, 23 percent, and 71 percent. In the two groups, the lesions were the most frequently observed in the lower lung field, less frequently in the mid-lung field, and least frequently in the upper lung field. It is noteworthy that the upper lung field was a little more frequently involved and the lower lung field a little less frequently involved in patients who visited our clinic, as compared with patients found in mass chest photofluorographic surveys.

### *Enlargement of Hilar Lymph Nodes*

I have frequently observed the enlargement of hilar lymph nodes, mainly of the affected lung, on chest X-ray film in *M. pneumoniae* pneumonia; the involved lymph nodes were usually unilateral and rarely bilateral. These enlarged hilar lymph nodes were clearly demonstrated by tomograms; the enlarged hilar lymph nodes were restored to normal after pneumonia had healed. The hilar lymph nodes were commonly enlarged, and the enlargement of the paratracheal lymph nodes was observed in only one patient.

Cases illustrating the enlargement of hilar lymph nodes are presented in the following reports:

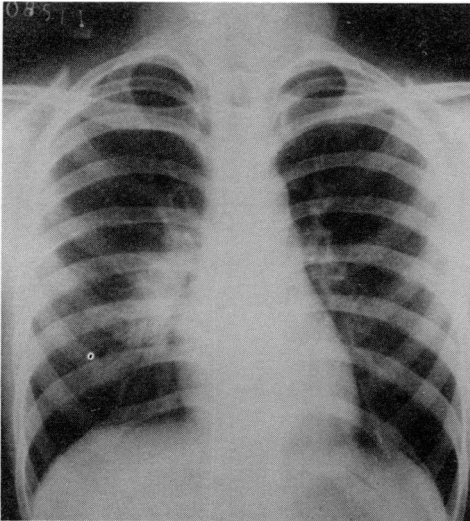


FIG. 1. First chest X-ray film (Case 1).

*Case 1: A girl of eight years* She developed a fever of  $38.6^{\circ}\text{C}$  and cough and visited our clinic six days later. She was treated with chloramphenicol and recovered uneventfully. *M. pneumoniae* was isolated and CF and FI antibodies rose later. The disease was diagnosed as *M. pneumoniae* pneumonia. The first chest X-ray film showed shadows around the right hilum (Fig. 1). The tomogram clearly demonstrated enlargement of the right hilar lymph nodes (Fig. 2). The chest X-ray findings were restored to normal seven days later (Fig. 3).

*Case 2: A boy of ten years* He developed a cough and his temperature rose to  $39.5^{\circ}\text{C}$  next day. He visited a doctor, but the fever continued. Pneumonia was found by X-ray examination four days later. He was referred to our clinic, where he was treated with erythromycin and then tetracycline. The fever disappeared soon

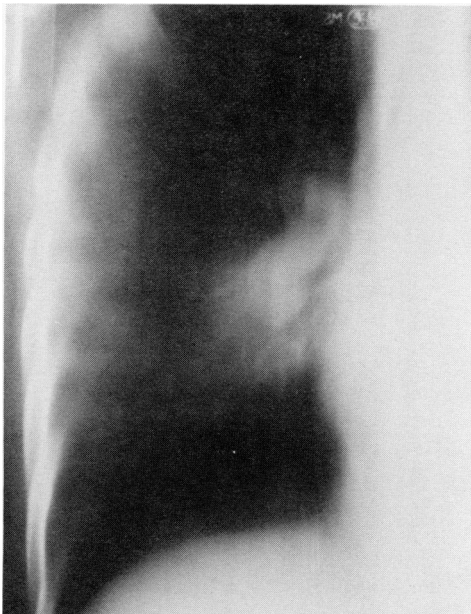


FIG. 2. First tomogram (Case 1).

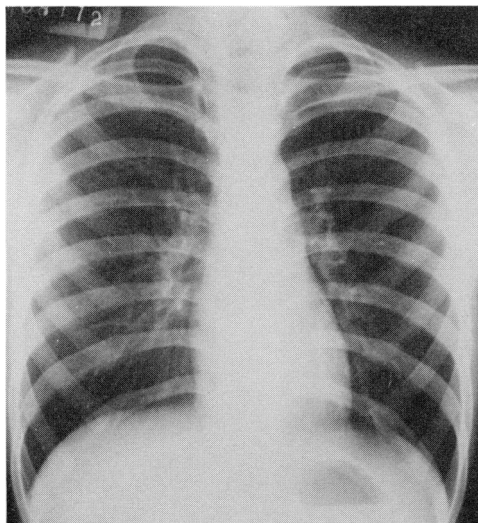


FIG. 3. Chest X-ray film seven days later (Case 1).

and he recovered uneventfully. *M. pneumoniae* was isolated at the first visit and CF and FI antibodies rose later. The disease was diagnosed as *M. pneumoniae* pneumonia. The first chest X-ray film and tomograms showed homogenous shadows in the right lower lung field and enlargement of the right hilar lymph nodes and the right paratracheal lymph nodes (Figs. 4 and 5). The chest X-ray findings were restored to normal one month later (Figs. 6 and 7). This is the only case showing enlargement of the paratracheal lymph nodes.

*Case 3: A girl of six years* Cough began first and was followed by intermittent fever to 39°C for four days. On the eighth day of the disease she visited a doctor and was given spiramycin. Pneumonia was found. She was referred to our clinic two days later. Tetracycline was given and she recovered uneventfully. *M. pneumoniae* was isolated and CF and FI antibodies were elevated later. The course of the disease

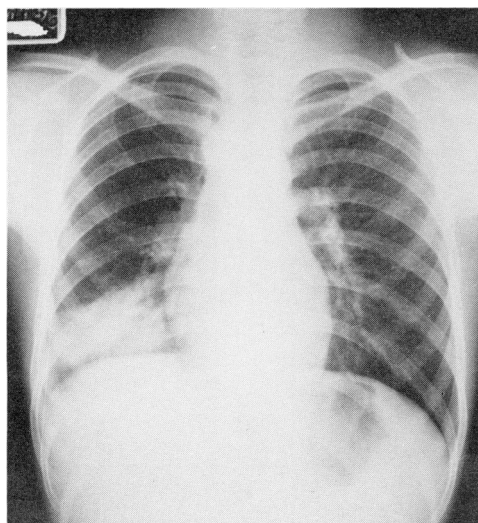


FIG. 4. First chest X-ray film (Case 2).

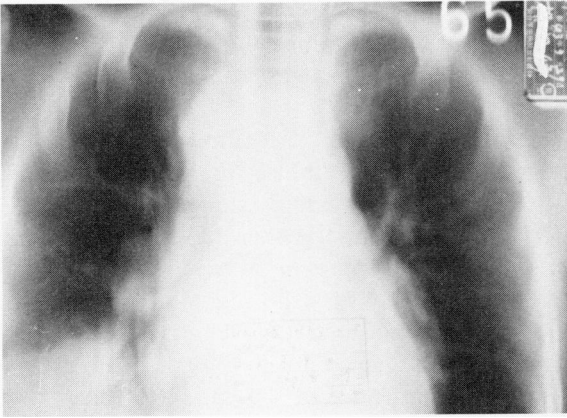


FIG. 5. First tomogram (Case 2).

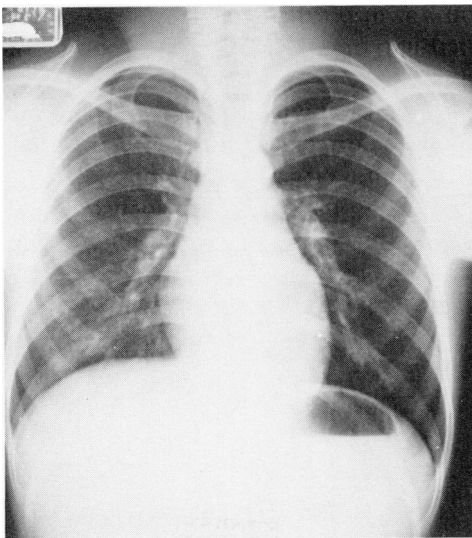


FIG. 6. Chest X-ray film one month later (Case 2).

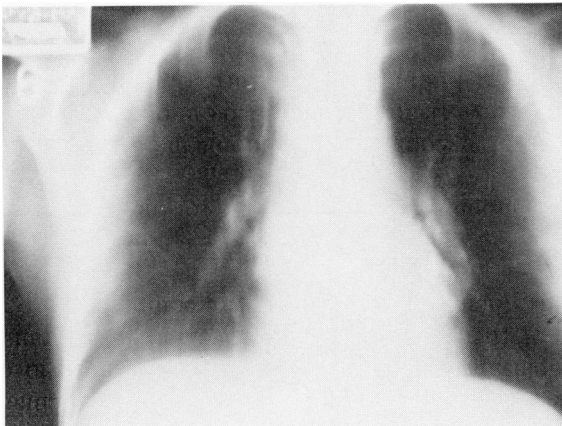

FIG. 7. Tomogram one month later (Case 2).

is shown in Fig. 8. The disease was diagnosed as *M. pneumoniae* pneumonia. The first X-ray film showed atelectatic shadows in the left upper lung field (Fig. 9). The tomogram demonstrated enlargement of the left hilar lymph node (Fig. 10). X-ray findings were restored to normal 20 days later.

**Case 4: A boy of five years** He developed a fever of 38.5°C and visited a doctor. Cough began two days later. Intermittent fever continued for ten days. He was referred to our hospital because the chest X-ray findings suggested sarcoidosis. Though *M. pneumoniae* was not isolated, CF and IHA antibodies were highly elevated at the first examination, indicating *M. pneumoniae* pneumonia. The course of the disease is shown in Fig. 11. The first X-ray film showed enlargement of bilateral hilar lymph nodes with radiating bronchial markings (Fig. 12). The tomogram clearly demonstrated enlargement of the lymph nodes (Fig. 13). Chest X-ray findings were restored to normal with disappearance of the enlarged hilar lymph nodes after three weeks' therapy with erythromycin.

**Case 5: A boy of five years** He had cough and often fever for three weeks. Enlargement of the right hilar lymph node, as shown in Fig. 14, was found by a mass chest X-ray survey. He was given erythromycin and then tetracycline. At the first ex-

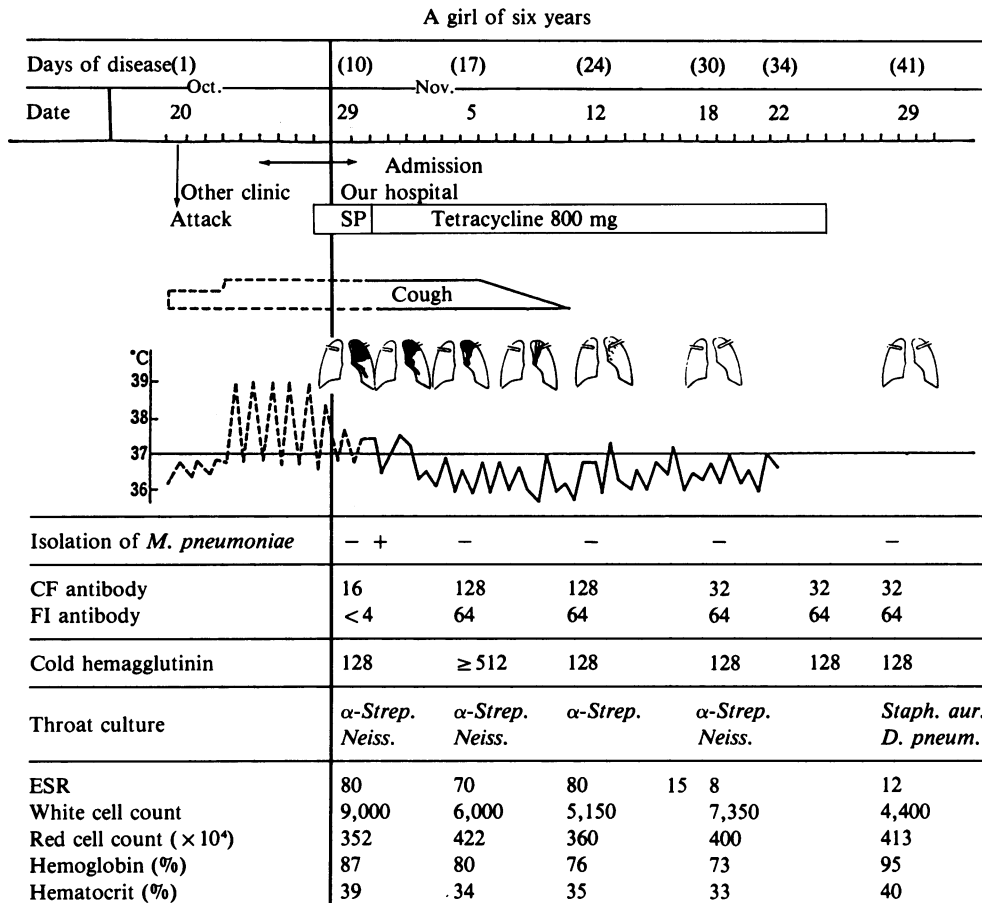


FIG. 8. Course of the disease (Case 3).

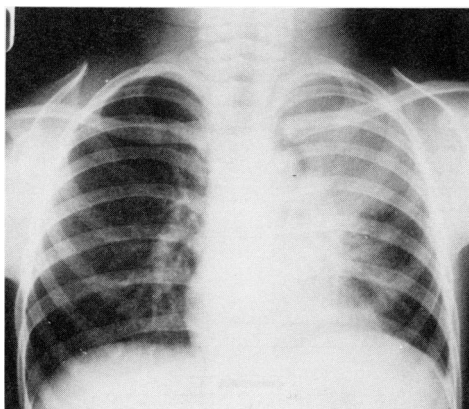


FIG. 9. First chest X-ray film (Case 3).

amination *M. pneumoniae* was isolated and CF and FI antibodies were elevated to 128. The three other members of his family also excreted *M. pneumoniae* and two of them suffered from pneumonia with CF antibody rise. The enlargement of the lymph node had disappeared 14 days later, as shown in Fig. 15. This case showed enlargement of the hilar lymph nodes only, without lung shadows in *M. pneumoniae* respiratory infection.

Of the 470 patients with *M. pneumoniae* pneumonia, enlargement of hilar lymph nodes was observed in 34 percent (Table 1). It was observed in none of five patients below one year of age, in 41 percent from one to five years, then decreased a little with increase in age. In addition to these patients, enlargement of hilar lymph nodes only, without lung lesions, as shown in case 5, was observed in 17 children with *M. pneumoniae* respiratory infections and in all age groups except those below one year, as shown in Table 1.

The percentage of enlargement of hilar lymph nodes was compared among agents of pneumonia in children. The percentage was 34 percent for *M. pneumoniae* pneumonia, as shown in Table 1, whereas it was 5 percent of 20 patients with adenovirus pneumonia, 9 percent of 23 patients with parainfluenza virus pneumonia, 7

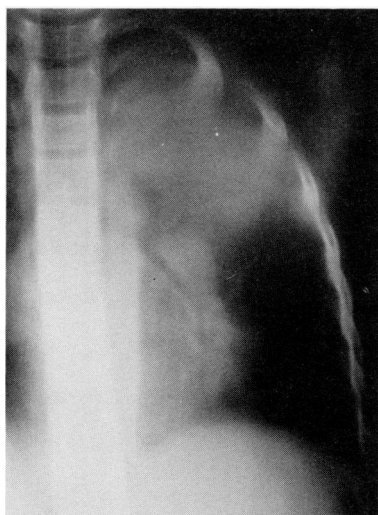

FIG. 10. First tomogram (Case 3).

Days of disease	(12)	(14)	(18)	(25)	(33)
Date	Sep.1	3	7	14	22
Isolation of <i>M. pneumoniae</i>	-	-	-	-	-
CF antibody	512	512	512	512	512
IHA antibody	262,144	524,288	524,288	262,144	131,072
Cold hemagglutinin	512	1,024	4,096	4,096	4,096
Throat culture	<i>Cand.</i> <i>Neiss.</i>		<i>Neiss.</i>	<i>Cand.</i> <i>D. pneu.</i>	<i>Cand.</i> <i>-Strep.</i>
ESR	53		36	28	25
White cell count	13,500		9,700	8,800	8,600
Red cell count ( $\times 10^4$ )	434		436	437	404
Hemoglobin (%)	92		88	92	84
Hematocrit (%)	44		46	49	44

FIG. 11. Course of the disease (Case 4).

percent of 14 patients with pneumonia due to Coxsackie virus B1, B3, or B4, and 6 percent of 79 patients with pneumonia due to bacteria or virus with the exclusion of *M. pneumoniae*.

Transient enlargement of the hilar lymph nodes may be rather characteristic of *M. pneumoniae* respiratory infections in children. These findings were often helpful in clinical diagnosis of *M. pneumoniae* respiratory infections.

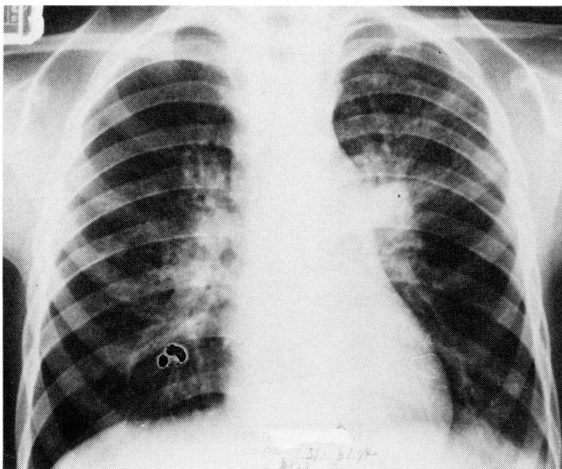


FIG. 12. First chest X-ray film (Case 4).



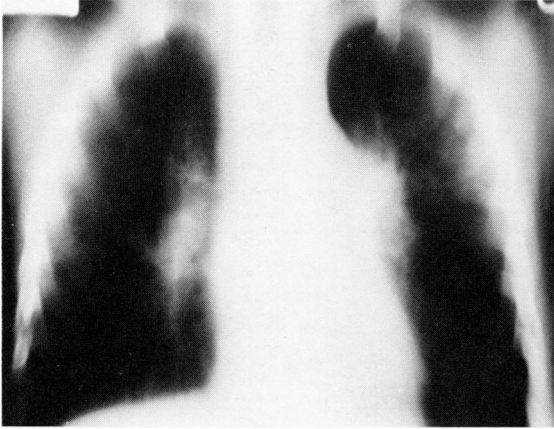


FIG. 13. First tomogram (Case 4).

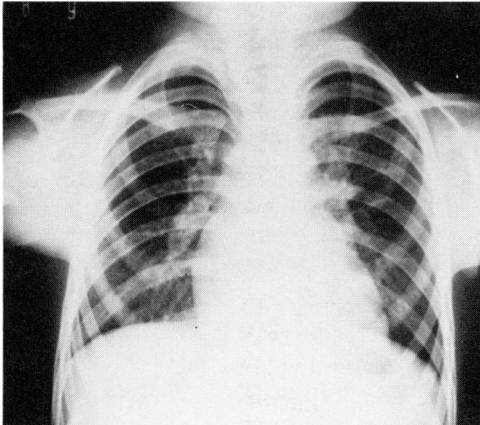


FIG. 14. First chest X-ray film (Case 5).

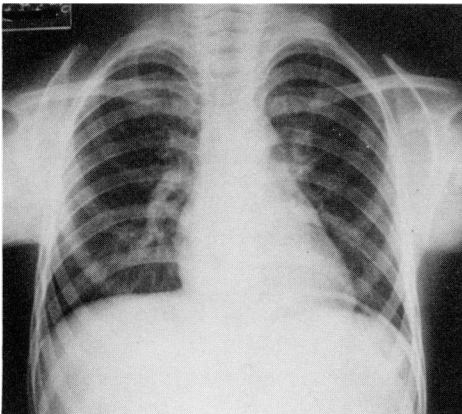


FIG. 15. Chest X-ray film 14 days later (Case 5).

TABLE 1  
Hilar Lymph Node Enlargement on Chest X-Ray Film in  
*M. pneumoniae* Pneumonia in Children

Age in Years	<1	1~5	6~11	12~15	Total
No. of patients with <i>M. pneumoniae</i> pneumonia	5	90	338	37	470
Hilar lymph node enlargement	0	37 (41%)	112 (33%)	10 (27%)	159 (34%)
<i>Hilar Lymph Node Enlargement Only</i>					
No. of patients	0	6	9	2	17

TABLE 2  
Clinical and Laboratory Findings Among Age Groups of Pediatric Patients with  
*M. pneumoniae* Respiratory Infections

Age in Years	No. of Patients	Fever	Pneumonia	CF positive	IHA Positive	Isolation of <i>M. pneumoniae</i>
0	10	3(30%)	3(30%)	4(40%)	7(70%)	7(70%)
1~5	109	51(47%)	64(59%)	76(70%)	97(89%)	34(31%)
6~10	109	65(60%)	60(55%)	85(78%)	86(79%)	49(45%)
11~15	17	10(60%)	8(47%)	12(71%)	10(59%)	8(47%)
Total	245	129(53%)	135(55%)	177(72%)	200(82%)	98(40%)

CF positive: Significant rise in antibody or  $\geq 64$

IHA positive: Significant rise in IHA antibody or  $\geq 256$

#### *Clinical and Laboratory Findings in M. pneumoniae Respiratory Infections Among Age Groups*

Clinical and laboratory findings were compared among age groups of pediatric patients with *M. pneumoniae* respiratory infections (Table 2). Of 245 patients, 10 were below one year of age; 109, one to five years of age, 109, six to ten years of age, and 17, 11 to 15 years of age. In the infants below one year of age, as compared with the other age groups, fever was observed less frequently in 30 percent in contrast to 47-60 percent of the other age groups; pneumonia was observed less frequently in 30 percent in contrast to 47-59 percent; CF test was positive less frequently in 40 percent in contrast to 70-78 percent; IHA test was similarly positive in 70 percent in contrast to 59-80 percent; and *M. pneumoniae* was isolated more frequently in 70 percent in contrast to 31-47 percent. The infants below one year of age showed some characteristic features.

#### DISCUSSION

Only a few reports described the enlargement of hilar or paratracheal lymph nodes in *M. pneumoniae* pneumonia. Hebert [6] reported that hilar lymphadenopathy was found in three (8 percent) of 34 adults and four children with Eaton agent pneumonia. Zeligowska et al. [7] reported that one of the most characteristic

features of *M. pneumoniae* pneumonia was lymphadenopathy in lung hilus in pediatric patients. Brolin and Wernstedt [8] reported that enlargement of the hilar or paratracheal glands was noticed or suspected in 13 of 59 pediatric and adult patients with *M. pneumoniae* pneumonia; of 17 cases of enlarged glands, cases of paratracheal glands numbered six and the number of patients with definitely enlarged glands was three (20 percent) of 15 pediatric patients below 16 years of age, and three (7 percent) of 44 adult patients over 15 years of age, showing that enlarged glands were more frequently observed in children than in adults. In the present report the enlargement of hilar lymph nodes was observed in 34 percent of pediatric patients with *M. pneumoniae* pneumonia and less frequently with an increase in age. It was considerably specific to *M. pneumoniae* respiratory infections and was often helpful in clinical diagnosis of the disease. Enlargement of unilateral hilar lymph nodes was observed in *M. pneumoniae* bronchitis without pneumonia. The enlargement of the hilar lymph nodes was more evident when the first X-ray film was compared with the X-ray film taken after the disease healed.

Symptomatic *M. pneumoniae* infections have rarely been reported in young infants and it seems to be generally considered that *M. pneumoniae* infections are mild in infants. In the present report, infants below one year of age less frequently had fever and pneumonia and showed slighter symptoms as compared with older children. In the routine pediatric practice, however, *M. pneumoniae* infections must be always considered in infants with respiratory infections, because Mizuta et al. [9] reported a fatal case of *M. pneumoniae* pneumonia in an infant of nine months and Litman and Spingland [10] reported the death of two of eight infants less than 16 months old with verified *M. pneumoniae* infection and abnormal X-ray findings.

#### REFERENCES

1. Kenny GE: Serology of mycoplasmic infections. In Manual of Clinical Immunology. Edited by NR Rose, H Friedman. Washington, DC, American Society for Microbiology, 1980, p 547
2. Niitu Y, Hasegawa S, Suetake T, et al: Pneumonia due to *Mycoplasma pneumoniae*. Virus 18:56, 1968 (in Japanese)
3. Lind K: An indirect haemagglutination test for serum antibodies against *Mycoplasma pneumoniae* using formalinized, tanned sheep erythrocytes, Acta Path Microbiol Scand 73:495, 1968
4. Niitu Y, Hasegawa S: Serodiagnosis of *Mycoplasma* infections by indirect hemagglutination test with use of lyophilized sensitized erythrocytes, Mycoplasma HA (KW). Gendai no Shinryo 18:616, 1976 (in Japanese)
5. Niitu Y, Hasegawa S, Suzaki K, et al: Strictly four-year periodicity of outbreaks of *Mycoplasma pneumoniae* infections and usefulness of commercially available lyophilized sensitized erythrocytes in serodiagnosis of *Mycoplasma pneumoniae* infections. Abl Bakt Hyg 1 Abt Orig A 241:256, 1978
6. Hebert DH: The Roentgen features of Eaton agent pneumonia, Am J Roentgenol 98:300, 1966
7. Zeligowska J, Ostojka J, Rajtar-Leontiew Z, et al: Mycoplasma-pneumoniae pneumonia in children. Pediatria Polska 46:1333, 1971
8. Brolin L, Wernstedt L: Radiographic appearance of mycoplasmal pneumonia. Scand J Resp Dis 59:179, 1978
9. Mizuta R, Miyoshi K, Yagi R, et al: Family outbreak and autopsy of a case of *Mycoplasma pneumoniae* pneumonia. Acta Paed Jap 80:908, 1976 (Japanese abstract)
10. Litman N, Spingland I: Severe Mycoplasma pneumoniae infections in infancy. Ped Res 13:463, 1979 (Abstract)