

MARKLEY H. BOYER*
CHRISTOPHER J. F. SPRY**
PAUL B. BEESON†
WALTER H. SHELDON‡

Nuffield Department of Clinical Medicine,
University of Oxford, Oxford, England and
the Department of Pathology, Johns Hopkins
University School of Medicine,
Baltimore, Maryland 21205

MECHANISM OF EOSINOPHILIA. IV. THE PULMONARY LESION RESULTING FROM INTRAVENOUS INJECTION OF *TRICHINELLA SPIRALIS*¶

A striking increase in eosinophil production can be provoked in rats by intravenous injection of muscle stage *Trichinella spiralis* larvae.¹ The parasites, because of their size, are arrested in the pulmonary arterial tree where they disintegrate. Three or four days after injection a peripheral eosinophilia is evident; this reaches its peak about the sixth day, and disappears by the tenth day. Repetition of the challenge two or three weeks later causes an even greater eosinophil response, with features suggestive of a secondary immune reaction.

The model has unique advantages for research on the mechanism of eosinophilia in that the experimental techniques are simple and the cellular response reproducible. We have made use of it in studies of immunosuppressive agents² and of the kinetics of eosinophil production.³

Evidence from other experiments^{2,4} indicated that the stimulus to bone marrow eosinophil proliferation develops within 24 hours after larval inoculation. This communication describes the histologic sequence of the early phases of the pulmonary reaction. We have compared the lesions developing in normal rats with those in rats pretreated by intravenous injection of killed *Corynebacterium anaerobium*, a procedure which had been shown to prevent the development of peripheral eosinophilia.

MATERIALS AND METHODS

Wistar strain rats, obtained from the Medical Research Council Radiobiological Research Unit, Harwell, England, were given 5,000 *Trichinella spiralis* larvae intravenously. Half the animals had received *Corynebacterium anaerobium*# 50 mg/kg, intravenously six hours prior to the injection of the parasites. At intervals thereafter three from each group were killed by

* USPHS Trainee in Medicine. Send reprint requests to present address: Dept. of Tropical Public Health, Harvard U. School of Public Health, Boston, Mass. 02115.

** Assistant to the Nuffield Professor of Clinical Medicine, Oxford.

† Nuffield Professor, Nuffield Dept. of Clinical Medicine, Oxford.

‡ Professor of Pathology, Johns Hopkins University School of Medicine, Baltimore.

¶ Supported by a grant from the Medical Research Council and by Grant AN-04593-11 from the National Institutes of Health.

Received for publication 28 December 1970.

From Prof. Raynaud, Pasteur Institute, Paris.

ether anaesthesia, the lungs removed and fixed in Zenker-formol. Paraffin sections cut at 4μ were stained with Wolbach's Giemsa method.⁵ Selected sections were stained with a modified pyronin stain,⁶ with the Fraser-Lendrum technique⁷ for fibrin or with the Brown and Brenn Gram method.⁸

MORPHOLOGIC FINDINGS

The following changes were noted in the lungs of rats injected only with trichinella. Larvae cut in various planes of section are frequent in branches of the pulmonary artery. Generally only a single parasite is seen in a vessel but occasionally two and rarely three larvae occupy an artery.

At 45 minutes a minimal inflammatory cell response and, occasionally, minute recent hemorrhages mark the foci of parasite localization (Fig. 1). The inflammatory cells consist chiefly of neutrophils, but some monocytes as well as rare small lymphocytes and mature eosinophils are found. They form on the surface of the larvae a thin, discontinuous layer and minute cell aggregates at the free ends. The cellular response is almost entirely intravascular although occasionally an infiltration of the vessel wall is encountered. Red blood cell and platelet aggregates as well as fibrin strands are absent. (See Fig. 2 for response in pretreated rats.)

At 1½ hours the inflammatory cell response to the larvae is increased, most of the surface of the parasite now being covered by a thin layer of cells with somewhat larger cell accumulations at the free ends. The cellular reaction involves the vessel wall and extends slightly into the surrounding tissues. Neutrophils predominate in the exudate but the mononuclear cells are also increased, particularly in extravascular location. Lymphocytes are not identified and the number and appearance of eosinophils is unchanged.

At 3 hours the perivascular cell response is slightly more marked than before with further increase in large mononuclear cells. Neutrophils still predominate and the number and appearance of the eosinophils is not appreciably changed. A thin but continuous layer of inflammatory cells surrounds each larva.

At 6 hours the lesions are further increased in size and occasionally begin to suggest a granulomatous conformation. Large mononuclear cells are the prevailing element; these are occasionally closely applied to the outer membrane of the parasite and sometimes extend in streamer-like manner from the larva into adjacent branches of the vessel. Among the large mononuclear cells, some of which show a heavily basophilic although not pyroninophilic cytoplasm, a few large lymphocytes are seen. Eosinophils are slightly more numerous than before.

At 12 hours the lesions are quite large, form compact granulomata and consist almost entirely of large mononuclear cells, a few of which exhibit

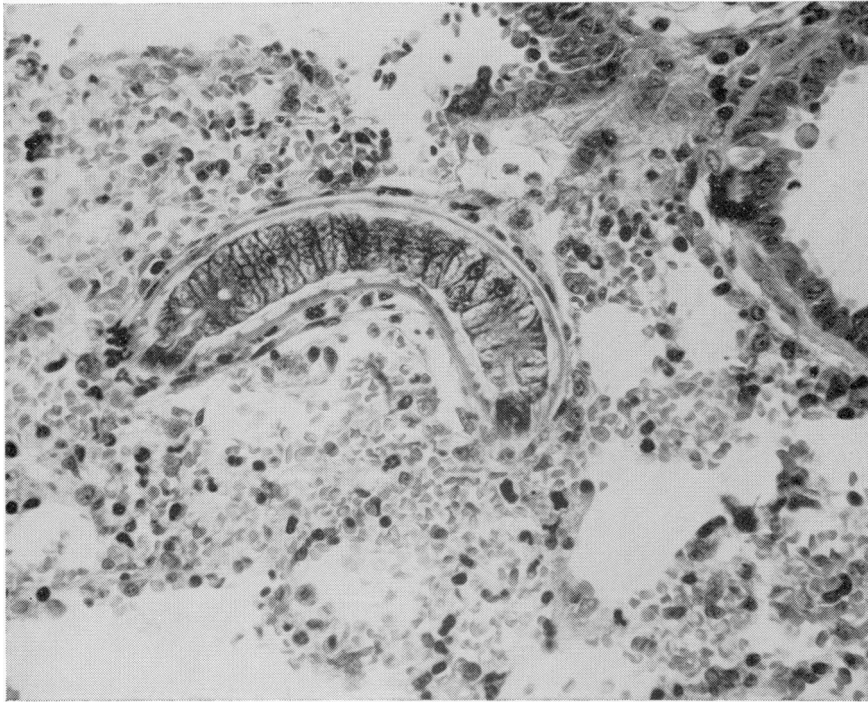


FIG. 1. Normal rat, 45 minutes; larval segment with slight neutrophil response and minimal recent hemorrhage; Giemsa, $\times 380$.

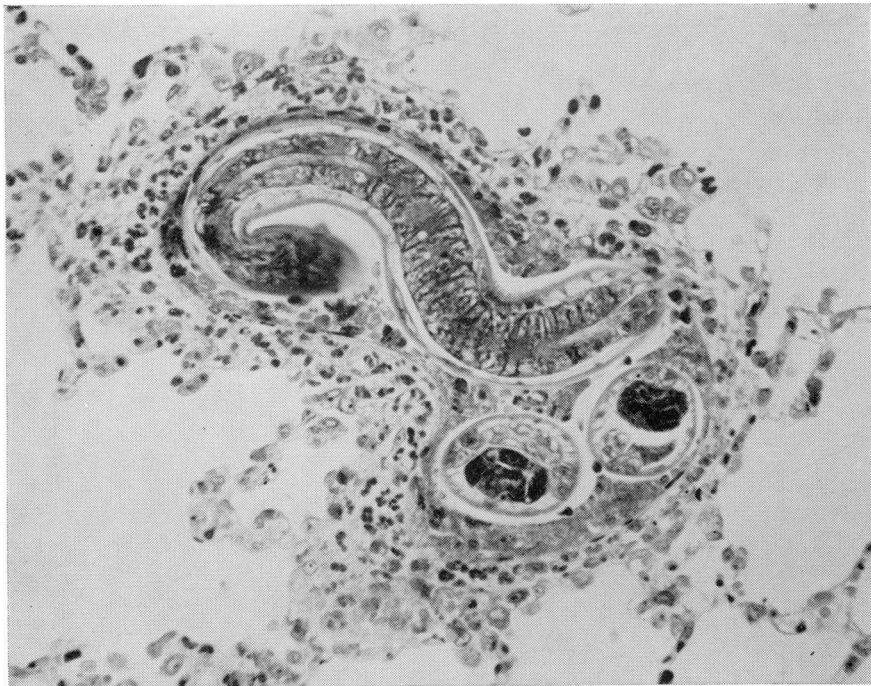


FIG. 2. Pretreated rat, 45 minutes; neutrophil response around larval segments is similar but more marked than in normal host at corresponding time (Fig. 1); Giemsa, $\times 380$.

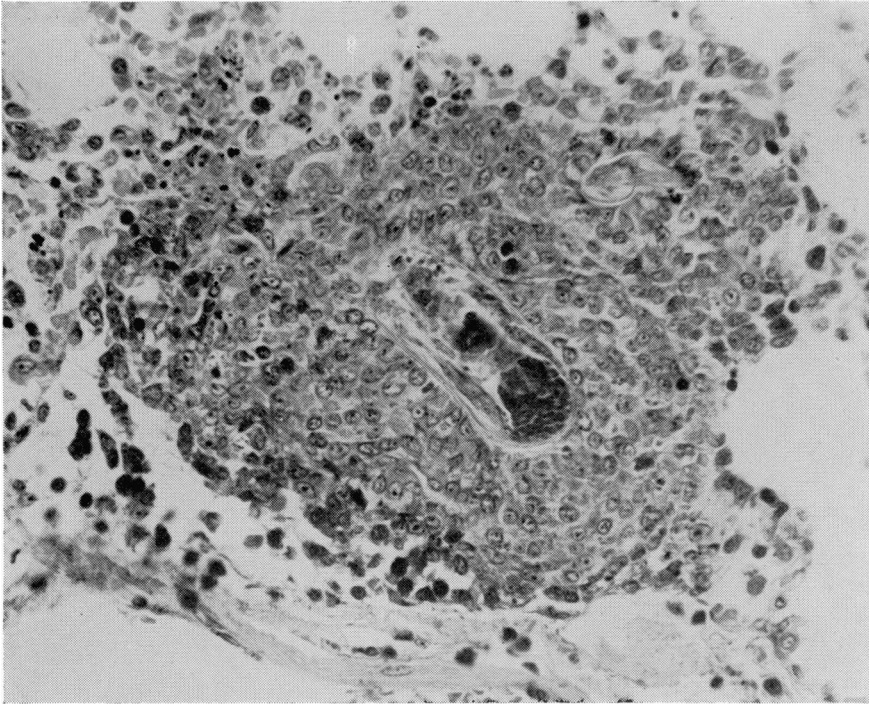


FIG. 3. Normal rat, 12 hours; granuloma chiefly composed of large mononuclear cells encasing larval segments; Giemsa, $\times 430$.

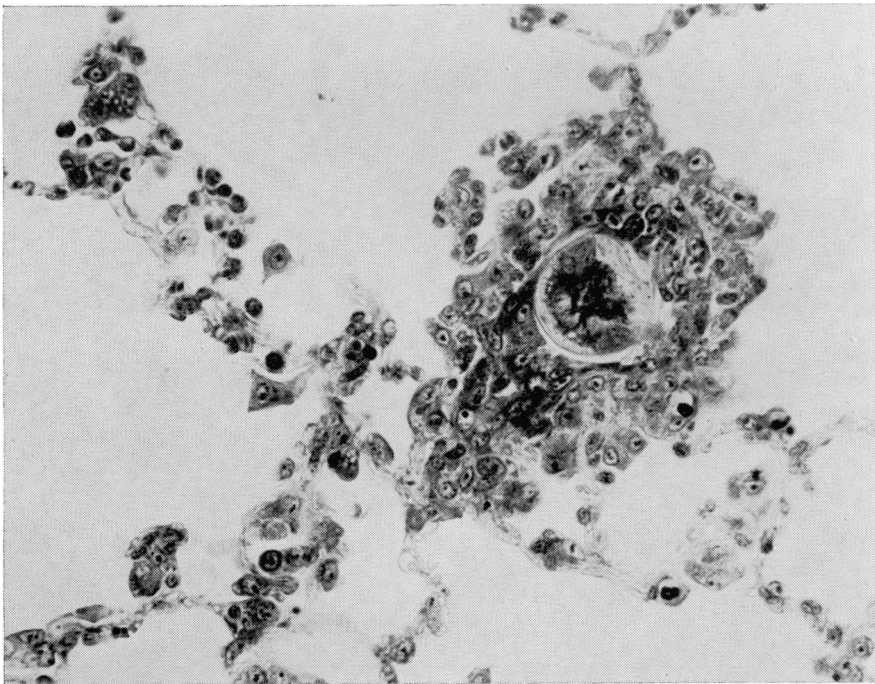


FIG. 4. Pretreated rat, 12 hours; granuloma encasing larval segment; the reaction is less marked than in normal host at corresponding time (Fig. 3); Giemsa, $\times 430$.

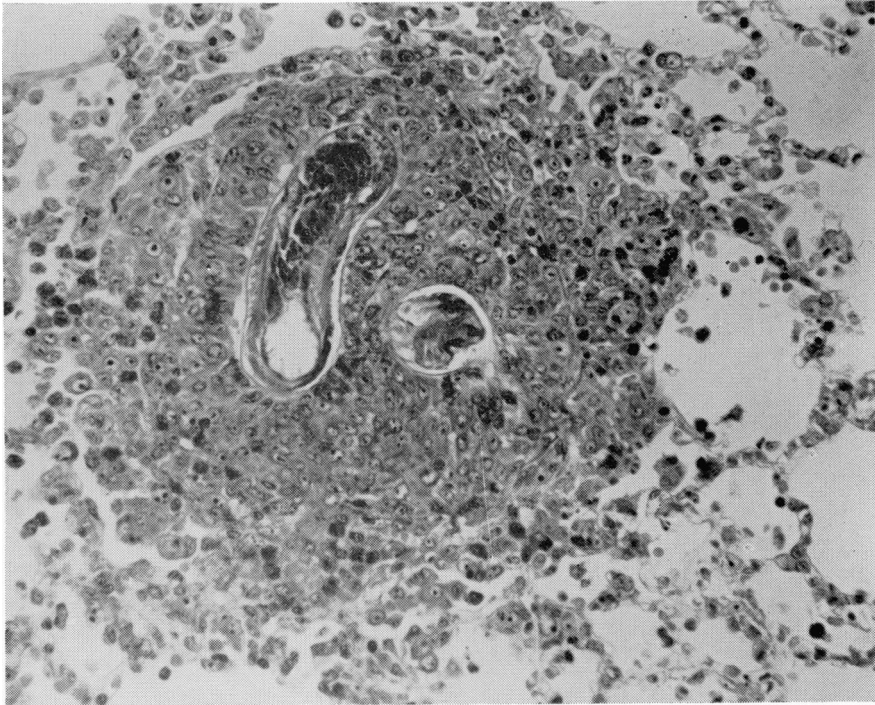


FIG. 5. Normal rat, 24 hours; marked granulomatous response around larval segments; Giemsa, $\times 330$.

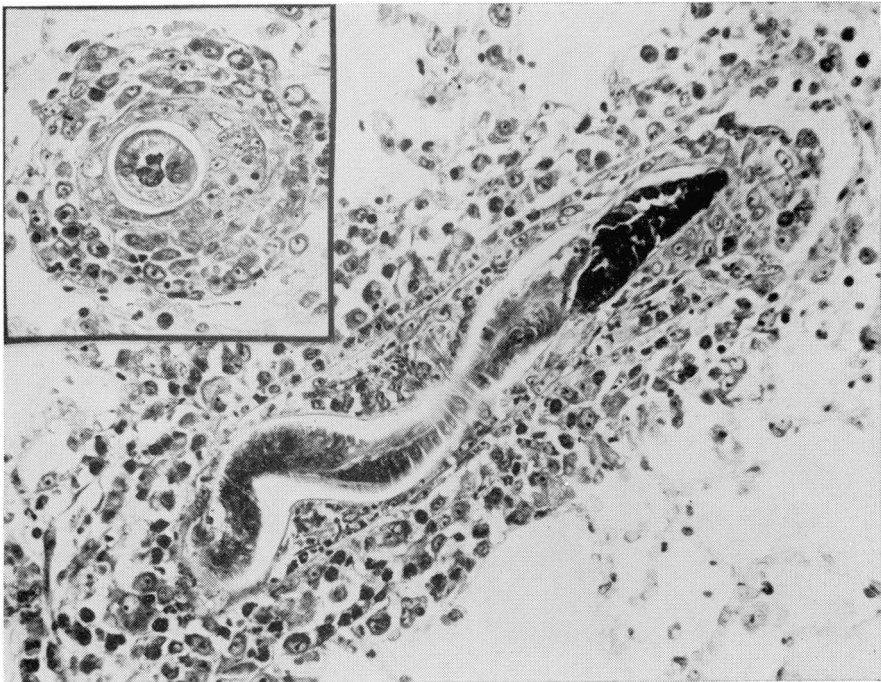


FIG. 6. Pretreated rat, 24 hours; granulomatous reaction around a larva shown in longitudinal and cross (insert) section is less than in normal host at corresponding time (Fig. 5); Giemsa, $\times 330$.

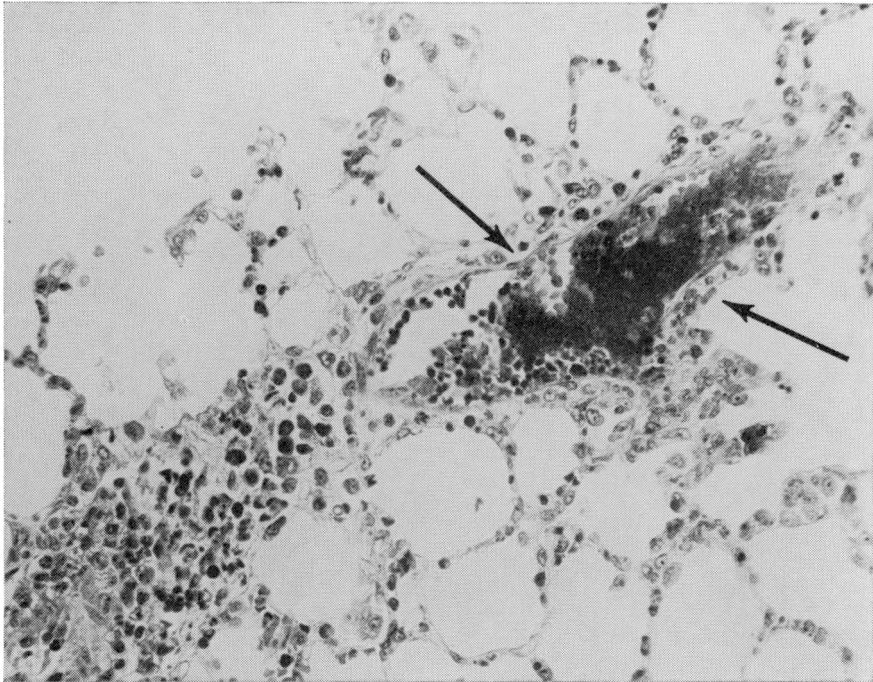


FIG. 7. Pretreated rat, 45 minutes; *C. anaerobium* induced lesion, intravascular bacterial aggregate (arrows); Giemsa, $\times 320$.

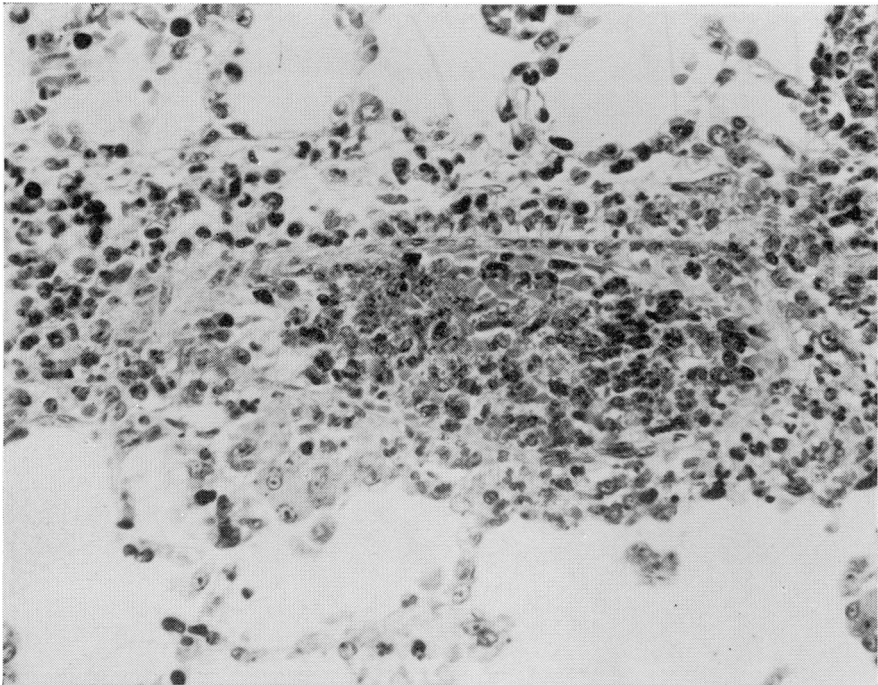


FIG. 8. Same as Fig. 7; mostly intravascular cell response to *C. anaerobium* composed chiefly of degranulated and degenerating neutrophils; Giemsa, $\times 450$.

traces of cytoplasmic pyroninophilia. A continuous layer of large mononuclear cells in intimate contact with the surface of the parasite encases each larva (Fig. 3). Eosinophils are more numerous than before and together with residual neutrophils are breaking down, accounting for scattered chromatin fragments and isolated eosinophil granules. Most of the debris is extracellular. (See Fig. 4 for effect on pretreated rats.)

At 18 hours the granulomatous lesions are still larger and occasionally confluent. Eosinophils are more numerous than before, appear mature and rarely show nuclear degeneration. Cellular debris, extracellular or phagocytized, is scant. Otherwise the cellular composition of the lesions remains unchanged without appreciable increase in cytoplasmic pyroninophilia. The surface of the parasite beneath the continuous layer of adherent large mononuclear cells sometimes appears slightly frayed.

At 24 hours the granulomata have grown again (Fig. 5). Multinucleated giant cells are present among the large mononuclear cells which envelop the parasite. The outer surface of the latter is often slightly frayed and its internal structures are somewhat indistinct. There is no invasion of the larvae by inflammatory cells. Although slight, cytoplasmic pyroninophilia of the large mononuclear cells is somewhat increased and at the periphery of the lesions occasional plasma cell precursors are seen. A few degenerating neutrophils remain in the lesions. Eosinophils, some with nuclear pyknosis, are abundantly scattered through the granulomata and together with some large lymphocytes are present in the perivascular connective tissue and lung septa in the vicinity of the parasitic lesions. The cellular infiltration appears to extend towards the lung hilum and sometimes involves the bronchial walls. The bronchial epithelium is slightly but distinctly infiltrated by eosinophils, a few of which are found among the cilia. (Reaction in pretreated rats is shown in Fig. 6.)

Pretreated rats

In the rats pretreated with *C. anaerobium* before injection of the parasite, some small and medium-sized branches of the pulmonary artery contain aggregates of white blood cells (Fig. 7). The aggregates, which lack fibrin, consist chiefly of neutrophils, occasional eosinophils, some monocytes, and rare lymphocytes (Fig. 8). Many neutrophils appear degranulated and some are degenerating. Some of the intraluminal cell accumulations also contain clumps of minute, gram positive pleomorphic bacteria that are occasionally seen within the cytoplasm of neutrophils and monocytes in the immediate vicinity of the bacterial masses. The vessel walls around the cell aggregates reveal a minimal inflammatory cell response with some proliferation of the lining cells in adjacent alveoli. The above type of lesion is encountered with

decreasing frequency until 12 hours at which time and thereafter the vascular lesions consist of small perivascular accumulations of large mononuclear cells with basophilic but not pyroninophilic cytoplasm. At 24 hours these lesions are few in number and of small size.

In addition to these cell aggregates, the lungs of pretreated animals show a diffuse increased cellularity which at the earlier times relates to the presence in the septal capillaries of single white blood cells, mostly neutrophils but also some mature eosinophils, a few monocytes, and rare lymphocytes. The endothelium of the septal capillaries is prominent but phagocytized bacteria are not seen in either the endothelium or the trapped cells. Beginning at 3 hours and thereafter the increased cellularity of the septa diminishes and consists of large mononuclear cells with basophilic, not pyroninophilic cytoplasm.

In the pretreated rats the frequency, distribution, and localization of the larvae in the lung are like those of the normal animals. Sometimes, the lesions induced by larvae are superimposed upon those produced by *C. anaerobium*. The presence of lesions induced solely by either *C. anaerobium* or by larvae is demonstrated by sequential sections.

In the pretreated rats the inflammatory cell response of the larval lesions is qualitatively like that of the controls, but some differences can be noted. In the former the intensity and extent of the inflammatory cell response is somewhat more marked (Fig. 2) during the first 3 hours, at which time the lesions already begin to display a granulomatous conformation. At 6 hours no appreciable differences between the lesions of both groups are apparent. Thereafter the inflammatory cell response surrounding the parasite is quantitatively somewhat less in the pretreated animals (Figs. 4 & 6). In the latter the following cellular changes are present at earlier times than in the untreated rats: In both larval and bacterial lesions slight pyroninophilia of large mononuclear cells is first seen at 12 hours and is increased thereafter, and the extent of the eosinophil accumulation is similar in both groups. In the larval granulomata multinucleated giant cells are already present at 18 hours and at 24 hours a few small lymphocytes and rare, faintly pyroninophilic plasma cell precursors are encountered at the periphery of some lesions. Changes in the parasite, namely, a slightly frayed outer surface and a somewhat indistinct appearance of the internal structures without invasion by host cells are noted at the same times as in the untreated rats. Eosinophil infiltration of the bronchial epithelium, a constant finding in the untreated animals, is not present in the treated group.

DISCUSSION

We have previously studied the effects of injecting the larvae by different routes and in different forms.¹ The greatest eosinophil responses were ob-

tained when intact parasites, either live or killed by freezing and thawing, were injected into the bloodstream. A response was also obtained when parasites were given by way of the abdominal aorta, thus indicating that pulmonary lodgement is not an essential requirement. On the other hand, eosinophilia failed to occur after subcutaneous or intraperitoneal injection of the same number of parasites. Particularly noteworthy was the finding that no reaction resulted from intravenous injection if the parasites were first ground into fragments small enough to traverse the pulmonary bed.

These facts suggest that the stimulus for eosinophil formation is not directly related to a constituent of the parasite or a product of its metabolism. We have tended, therefore, to assume that the eosinopoietic stimulus is in some way related to the inflammatory process initiated by impaction of the larvae in blood vessels. The simultaneous formation of numerous inflammatory foci with their associated lymph node involvement might be expected to result in a much greater total reaction than that caused by a single bolus of parasites introduced into the peritoneum or the subcutaneous tissues. The hypothesis that the extent and intensity of the inflammatory process is of signal importance is favored by the finding that an eosinophil response is produced by intraperitoneal inoculation of the parasite provided the number of larvae injected is increased several-fold.¹

Histologic study shows that the impaction of the parasite in the blood vessels induces a focal inflammatory process which, from an initial response chiefly composed of neutrophilic granulocytes, rapidly progresses to granuloma formation. At 12 hours in the untreated rats and slightly earlier in the pretreated animals the lesions consist predominantly of large mononuclear cells which encase the larvae and are in close contact with their surfaces. Eosinophils are present throughout the lesions at all times and after 12 hours are numerous, representing the second most frequent cell. The local concentration of eosinophils cannot be ascribed to an alteration in number of these cells in the circulation, because that remains within normal limits during the period under study. Neither the eosinophils nor the few scattered lymphocytes and plasma cell precursors that are also present are seen commonly in direct contact with the parasite. The presence of numerous eosinophils is a distinctive feature of the cellular response to the parasite and might be responsible for the subsequent burst of eosinopoiesis in the bone marrow, possibly by an effect on lymphocytes travelling through the lesions. Other experiments have indicated that the bone marrow response is mediated by lymphocytes² and therefore it had seemed possible that the pulmonary lesions would reveal a conspicuous infiltration with lymphocytes and that many of these might display pyroninophilia. Actually neither feature is prominent. The possibility which cannot be excluded is that a significant

interaction with lymphocytes takes place elsewhere, for example, in the lymph nodes draining the inflammatory foci.

Since pretreatment with *C. anaerobium* prevents eosinophil formation and the subsequent blood eosinophilia, we had thought that histologic study of the larval lesions in pretreated rats might reveal which cellular element (s) of the inflammatory reaction are necessary for the induction of eosinopoiesis. The results of the present study show quantitative but no qualitative differences of the inflammatory cell response in the untreated compared to the pretreated rats. In the latter the cellular response is accelerated and more marked during the first 3 hours but is less pronounced after 6 hours. In both groups the cellular composition of the lesions is quite similar. While the inflammatory process resulting from pretreatment with *C. anaerobium* might be a mechanism by which the stimulus to eosinopoiesis is prevented, the fact remains that other agents such as busulphan and prednisone, which do not induce inflammation, also prevent the eosinophil response.³

The ingredients of the eosinopoietic stimulus appear to be: first, injection of foreign material in a particle size large enough to ensure arrest in a vascular tree (instead of in cells of the reticulo-endothelial system); second, an injurious effect by some component of the parasite, leading to an intense inflammatory reaction; third, rapid destruction of the parasitic material by the inflammatory reaction (which probably curtails the duration of antigenic challenge and accounts for the single sharp peak of response).

SUMMARY

The sequence of pulmonary inflammatory cell reaction in rats after intravenous inoculation of *Trichinella spiralis* larvae has been described in an attempt to shed light on events leading to augmented eosinophil formation in the marrow.

The injected larvae are arrested in the pulmonary vessels where they elicit an inflammatory response that initially consists chiefly of neutrophils, some eosinophils and a few mononuclear cells. After a few hours the inflammatory foci are composed mostly of large mononuclear cells. At 12 hours and thereafter the parasite is solidly encased in large mononuclear cells that form compact granulomata with some multinucleated giant cells. Scattered throughout the lesions and not in close contact with the larvae are numerous eosinophils and small numbers of lymphocytes and plasma cells. At 24 hours the appearance of the parasite suggests that disintegration is beginning.

The larval lesions of normal rats have been compared with those of animals in which the eosinophil response has been prevented by pretreatment with *C. anaerobium*, which produces inflammatory lesions. In the pretreated rats the cellular composition of the larval lesions is qualitatively similar to

that of the normal controls. There are quantitative differences that consist of an initially somewhat more marked inflammatory cell reaction that becomes less pronounced at the later times.

REFERENCES

1. Basten, A., Boyer, M. H., and Beeson, P. B.: Mechanism of eosinophilia. I. Factors affecting the eosinophil response of rats to *Trichinella spiralis*. *J. exp. Med.*, 1970, *131*, 1271-1287.
2. Boyer, M. H., Basten, A., and Beeson, P. B.: Mechanism of eosinophilia. III. Suppression of eosinophilia by agents known to modify immune responses. *Blood*, 1970, *36*, 458-469.
3. Spry, C. J. F.: Mechanism of eosinophilia. V. Kinetics of normal and accelerated eosinopoiesis. *Cell Tissue Kinet.*, 1971, *4*, 351-364.
4. Basten, A. and Beeson, P. B.: Mechanism of eosinophilia. II. Role of the lymphocyte. *J. exp. Med.*, 1970, *131*, 1288-1305.
5. Mallory, F. B.: *Pathological Technique*. New York, Hafner Publishing Co., 1961, p. 153.
6. Wyllie, R. G.: Unpublished data, Dept. of Pathology, Johns Hopkins.
7. Luna, L. G., ed.: *Manual of Histologic Staining Methods of the Armed Forces Institute of Pathology*. New York, McGraw-Hill Book Co., 1968, p. 81.
8. *Ibid.*, p. 222.