

## Fatal Hong Kong Influenza: A Clinical, Microbiological and Pathological Analysis of Nine Cases\*

PHILIP S. FELDMAN,† MARK A. COHAN,‡  
and WALTER J. HIERHOLZER, JR.§

*Departments of Pathology and Pediatrics, Yale University School of Medicine*

*Received for publication 29 June 1971*

Epidemic influenza due to type A<sub>2</sub> strains has been well studied since its first appearance in 1957. In July, 1968, a new influenza A<sub>2</sub> variant was recognized in Hong Kong as the causal agent for a large epidemic(1). In a fashion similar in pattern and timing to the 1957 A<sub>2</sub> pandemic(2), "Hong Kong Influenza" spread to the United States. Our purpose is to present the clinical, microbiological, and pathological data on nine fatal cases of Hong Kong (HK) influenza from a sharp outbreak in Connecticut in November and December, 1968.

### MATERIALS AND METHODS

Patients were included in the study group only if the following criteria were met: (1) isolation of influenza virus A<sub>2</sub>, Hong Kong variant, either from ante-mortem specimens or postmortem tissues; and/or (2) serologic evidence of HK influenza; (3) postmortem examination available for review.

*Virus isolation and identification.* Throat and rectal swabs were submitted and processed in "double-seeded" (DS) tissue culture tubes(3). After 5 to 10 days, the cultures were examined for hemabsorbing viruses by addition of 0.5% guinea pig

† Instructor in Surgical Pathology, Washington University School of Medicine and Barnes Hospital, St. Louis, Mo.

‡ Resident in Pathology, University Hospitals of Cleveland, Cleveland, O.

§ Assistant Professor of Epidemiology and Public Health and Internal Medicine, Yale University School of Medicine, New Haven, C. (PHS Grant #1T1 HD 177-02). To whom reprint requests are to be addressed.

\* Drug names in text: Imuran\* Azathioprine—Burroughs, Wellcome and Co.; Alkuran\* Melphalan—Burroughs, Wellcome and Co.; Declomycin\* Demethylchlortetracycline HCl—Lederle Laboratories; Valium\* Diazepam—Roche Laboratories.

erythrocytes. Isolates were identified by hemadsorption inhibition (HAdI) using specific antisera(4).

For recovery from autopsy tissues, specimens were homogenized to a 10% suspension in Hanks basic salt solution, and the suspension clarified by centrifugation. After addition of antibiotics, fluids were inoculated in 0.5 ml amounts into primary rhesus monkey kidney monolayer cultures, or intraamniotically in 0.2 ml amounts into 8 day fertile chicken eggs(4-6). Tissue culture isolates were handled as noted above. Amniotic fluid from inoculated eggs was harvested after three days and tested for hemagglutination, using 0.5% guinea pig red cells. Hemagglutination inhibition (HI) tests were carried out in microtiter plates with specific antisera(7,8).

*Antibody tests.* Sera were treated with receptor destroying enzyme(5,6) and titers determined in microtiter plates using the HI methods noted above. A 4-fold rise in titer against HK influenza virus was considered significant. When tested against previous A<sub>2</sub> agents, these sera demonstrated minimal titer increases interpreted as typical of crossover type reactions with these previous agents.

## RESULTS

The results of virologic studies are summarized in Table 1. Isolations of HK influenza virus were made from postmortem lung tissue from six of the eight cases tested. Virus was also recovered from a premortem throat swab from one patient (M.N.), who acquired his infection while hospitalized for other problems.

An etiologic diagnosis was established in the other two cases by serologic means alone. Case P.S. had an HI titer rise against the epidemic strain from less than 1:10 to 1:160 during the course of his illness. From case M.C., only a single serum was submitted; the HI titer in this specimen was 1:160, while titers against other influenza strains (A<sub>2</sub>/Tok/3/67 and B/Mass/3/66) were less than 1:10. The patient, who had not traveled out of the area, fell ill during the 3rd week of the epidemic. She has been included in the study group since it seems probable that her antibody against the epidemic strain was associated with her fatal illness.

## CLINICAL FINDINGS

The nine patients in this series were a heterogenous group. Much of the pertinent clinical information is tabulated in Table 2. The patients ranged in age from a 3-year-old boy, who died at home, to a 66-year-old woman. There were 6 men and 3 women, all caucasian.

Two of the patients were immunologically handicapped. L.D., a 45-year-old man and the recipient of a kidney transplant, was being maintained on steroids and Immuran\* before and during his illness. M.V., a 65-year-old woman with a history of multiple myeloma, was receiving Alkuran\*. Two other patients had significant antecedent disease. M.N. was an alcoholic with chronic obstructive

TABLE 1  
VIRUS ISOLATIONS FROM NINE FATAL CASES ON INFLUENZA PNEUMONIA<sup>a</sup>

Case	Age	Sex	Date of onset	Day of hospitalized	Day of death	Premortem		Postmortem		HAI results			
						Specimen	Day of illness	Result	Tissue	Result	Day of illness	Titer	Comment
M.C.	50	F	12/7	5	13	TS	12	Neg	Lung	Neg	11	1:160	Single Sera
P.S.	48	M	12/7	6	11	TS	10	Neg	Brain	Neg	5	1:10	
						RS	10	Neg	Colon	Neg			
A.P.	53	M	12/18	7	7	Sputum	7	Neg	Lung	Pos	ND	—	Isolation in eggs
L.D.	45	M	12/18	8	12	TS	8	Neg	Lung	Pos	ND	—	Isolation in eggs
M.B.	66	F	12/11	<sup>b</sup>	7	ND	—	—	Lung	Pos	ND	—	Isolation in D/S tubes
M.V.	65	F	12/18	2	11	TS	2	Neg	Lung	Pos	ND	—	Isolation in D/S tubes
M.R.	3	M	12/28	<sup>c</sup>	2	ND	—	—	Lung	Pos	ND	—	Isolation in D/S tubes
						RS	2	Neg	Lung	Pos	ND	—	Isolation in D/S tubes
J.W.	66	M	12/10	5	6	ND	—	—	Lung	Pos	ND	—	Isolation in D/S tubes
M.N.	65	M	12/1	<sup>d</sup>	15	TS	2	Pos	ND	—	ND	—	Isolation in eggs

<sup>a</sup> TS—Throat swab, RS—Rectal swab, ND—material not received for virus studies; Neg—No virus isolated, Pos—Isolation of HK influenza virus.  
<sup>b</sup> Hospitalized 11/30 for congestive heart failure.  
<sup>c</sup> Dead on arrival at hospital.  
<sup>d</sup> Hospitalized since 10/16 for chronic pulmonary disease.

TABLE 2  
SUMMARY OF CLINICAL INFORMATION<sup>a</sup>

Case	Sex	Age	Previous disease	Signs and symptoms			WBC	SLDH	Clinical laboratory tests			Cultures		
				Myalgia	Chills	Cough			Hemopt. Cyan	pH	pO <sub>2</sub>		pCO <sub>2</sub>	Blood gases
M.C.	F	50	None	+	+	+	+	8500	3050	A 7.48	54	27	89	pre <i>Pseudomonas a.</i>
P.S.	M	48	None	+	+	+	+	3200	5200	B 7.54	60	60	93	pst <i>Pseudomonas a.</i>
A.P.	M	54	None	+	+	+	+	3400	640	A 7.48	35	24	72	pre Normal Flora
L.D.	M	45	Renal transplant	+	+	+	+	1400	ND	C 7.43	50	22	84	pst No Growth
M.B.	F	66	Diabetes	+	+	+	+	7300	ND	A 7.52	40	40	80	pre <i>Staph. aureus</i>
M.V.	F	65	ACVD-CHF	—	—	—	—	2900	ND	D 7.24	47	64	97	pst <i>Enterococci</i>
M.R.	M	3	Multiple myeloma	+	+	+	+	ND	ND	E 7.40	42	41	77	pre <i>E. coli</i>
J.W.	M	66	None	—	—	—	—	4000	900	F 7.22	30	46	58	pst <i>E. coli</i>
M.N.	M	65	Alcoholic COPD	—	—	—	—	5800	ND	X 7.33	60	25	88	pre <i>Klebsiella pn.</i>
				+	+	+	+	ND	ND	X 6.84	60	55	68	pst No Growth
				X	X	X	X	ND	ND	X 7.42	34	37	68	pre Normal Flora
				—	—	—	—	ND	ND	X 7.29	34	46	60	pst No Growth
				—	—	—	—	ND	ND	ND	ND	ND	ND	pre ND
				—	—	—	—	4000	900	ND	ND	ND	ND	pst <i>Enterococci</i>
				—	—	—	—	5800	ND	ND	ND	ND	ND	pre Normal Flora
				—	—	—	—	ND	ND	ND	ND	ND	ND	pst No Growth
				—	—	—	—	ND	ND	ND	ND	ND	ND	pre ND
				—	—	—	—	ND	ND	ND	ND	ND	ND	pst No Growth

<sup>a</sup> + condition present; — condition absent; X condition unknown; ND test not done; pre—premortem culture; pst—postmortem culture.

A—Breathing room air; B—7th Hosp. day, 100% O<sub>2</sub> assisted respiration; C—4th Hosp. day, 95% O<sub>2</sub> assisted respiration; D—premortem, 80% O<sub>2</sub> assisted respiration; E—1st Hosp. day, 70% O<sub>2</sub> in tent; F—6th Hosp. day, 90% O<sub>2</sub> assisted respiration.

pulmonary disease, and M.B. had severe arteriosclerotic cardiovascular disease and mild diabetes mellitus. Five of the nine patients, however, were in good health before their fatal illness. The illness of P.S. is included as typical of this latter group.

*Case of P.S.:* This was the first hospital admission for this 48-year-old man. Several weeks before the onset of his illness, his children had had upper respiratory infections. Six days before admission the patient felt ill with chills, fever, myalgia, anorexia, and a cough. Four days later, when seen by his physician, he had a cough productive of red-yellow sputum and bilateral pulmonary rales. He was treated with Declomycin\*, but became worse and was admitted to the hospital the following day.

The patient's past medical history was interesting in that he had pneumonia in 1960 that was "slow to respond to antibiotics." His father had died of pneumonia at age 53. On admission the patient's temperature was 103°F rectally, pulse 140 and regular, blood pressure 130/70, and respirations shallow at 60/min. He was in severe respiratory distress with rhonchi and rales bilaterally extending over the lower halves of the lung fields. Bronchial breath sounds were heard in the right axilla and anteriorly over the right chest. A grade I/VI systolic ejection murmur was audible along the left sternal border. There were no friction rubs.

Clinical laboratory results on admission were as follows: the hematocrit was 49%, WBC 3200, with 50% segmented polymorphonuclear leukocytes and 38% band forms; serum electrolytes included a bicarbonate of 14.2 mequiv/liter and a potassium of 5.6 mequiv/liter; arterial blood gas determinations showed a pH of 7.48,  $p\text{CO}_2$  of 29 mm Hg.,  $p\text{O}_2$  of 35 mm Hg. and an oxygen saturation of 72% while breathing room air. X-rays of the chest showed pneumonic infiltrates in the right lower, middle and upper lobes and in the left upper lobe. The sputum was profuse, watery, foamy, and bright red. Only normal bacterial flora grew on culture. Blood cultures were sterile.

Initial treatment consisted of intravenous fluids, intermittent positive pressure breathing (IPPB), endotracheal suction and oxygen by mask. Intravenous fluids, Ampicillin and Oxycillin were begun. On the morning of the second hospital day, while breathing 100% oxygen by mask, the patient's arterial  $p\text{O}_2$  was 42 mm Hg. He was desperately ill and cyanotic while breathing oxygen. A tracheostomy was performed and assisted respiratory ventilation was begun with a volume control respirator. Sedation with morphine sulfate and intravenous Valium\* was given. He continued to produce copious quantities of frothy pink sputum.

During the third hospital day, the patient remained hypoxemic ( $p\text{O}_2$ —51 mm Hg) while on assisted respiration with 72% oxygen, although his serum bicarbonate had fallen as low as 10 mequiv/liter. A chest film at this time showed an increase in the extent of pulmonary involvement. A repeat sputum culture revealed no bacterial growth. The systolic blood pressure fell intermittently below 90 mm Hg and the BUN gradually rose to 87 mg% despite an adequate urine output. Urine culture was sterile.

The patient continued to put forth large quantities of thin, bloody, bacterio-

logically sterile sputum. On the afternoon of the 5th hospital day, his hypoxemia worsened, the  $pO_2$  being 32 mm Hg. while ventilated with 96% oxygen. At this time the central venous pressure began to rise and he was given digitalis. Urine remained adequate, the BUN was 97 mg%, and the serum lactic acid dehydrogenase was 5200 units.

Early in the evening of the 5th hospital day, the first of several grand mal seizures occurred. Despite continued heroic efforts and 100% oxygen with assisted respirations, the  $pO_2$  fell to 20 mg Hg. There were repeated episodes of seizures, cardiac arrhythmias and cardiac arrest. The patient died on the following day.

The illnesses of the other eight patients were similar in onset and course. All began with myalgia, headache and had chills, fever, cough and/or signs of upper respiratory tract infection. In five, the cough was described as productive. On the average, pneumonia followed onset by 4 or more days, with a range of 2 to 7 days.

Of the two patients who were cyanotic on admission to the hospital, one survived less than 6 hr. Marked cyanosis developed in six other patients, four of whom expired within 6 hr of recognition of this sign; two others survived several days on artificial ventilation following tracheostomies.

Survival following the recognition of the onset of pneumonia ranged from 1 to 14 days. Three died on the first hospital day. Of the four patients who had frothy sputum, hemoptysis or "pulmonary edema," two died within 24 hr of the onset of this sign.

Six of the nine patients had total white blood cell counts of less than 5000/mm<sup>3</sup> and none were over 8500. Patients with the lowest counts (L.D.—1400/mm<sup>3</sup> and M.V.—2900/mm<sup>3</sup>) were on leukosuppressive drugs. Serum lactic acid dehydrogenase (LDH) was markedly elevated in the four patients in whom it was determined (Cases M.C., P.S., A.P., and J.W.).

Radiologic findings were generally more striking than those of physical examination in all cases. Three patients had two or more lobes involved on initial x-ray examination, and bilateral involvement was noted in six of eight before death.

All patients required oxygen during their hospitalization. Four had tracheostomies followed by mechanically assisted respiration with oxygen in concentrations over 80%. Three others received oxygen by mask in high concentrations. Two individuals died within hours of having tracheostomy, but two others survived four days on oxygen concentrations of up to 100% without successful control of their severe hypoxemia.

Arterial blood gas determinations on six patients are shown in Table 2. Oxygen partial pressures were markedly decreased in all, ranging from 35 to 60 mm Hg. The initial arterial pH was mildly elevated in three, but carbon dioxide retention was never noted on first testing. In every patient, hypoxemia deepened despite all measures. Respiratory acidosis and CO<sub>2</sub> retention occurred only terminally.

Five cases succumbed to influenzal pneumonia complicated by bacterial superinfection documented by sputum and lung cultures. The organisms were en-

terococci, *Escherechia coli*, *Pseudomonas aeruginosa*, and *Klebsiella pneumoniae*. *Staphylococcus aureus* was isolated antemortem from one patient, but post-mortem cultures grew only enterococci.

Fatal primary influenzal pneumonia without bacterial superinfection was documented in three individuals who on repeated antemortem sputum cultures failed to show significant bacterial growth; postmortem bacteriological cultures were also negative and bacteria were not seen in suitably stained histologic sections. Post-mortem bacteriologic studies on a fourth patient (M.B.) were also negative, though premortem sputum cultures grew *Klebsiella* species. All patients had received antibiotics. Results of ante- and postmortem bacteriologic cultures are included in Table 2.

## PATHOLOGY

Necropsy findings on the nine patients with documented influenza pneumonia are summarized in Table 3.

In all cases the lungs were voluminous with combined weights in excess of 1500 g in the adult cases. Externally, the lungs were violaceous in color. On section, they were diffusely hemorrhagic and abundant bloody fluid escaped. Purulent material exuded from bronchi only in the cases with superimposed bacterial infection. The mucosa of the tracheobronchial tree was markedly congested, hemorrhagic and focally necrotic in most cases. No thrombi were found on gross examination.

The microscopic picture of the lungs was kaleidoscopic. There was a striking variation from case to case and between regions in a single lung. There was a notable difference in microscopic changes in patients dying at different stages in their illnesses.

Hyaline membranes were focally present in seven of the nine cases (Fig. 1). They were seen as early as the second day of the illnesses and as late as the 21st, and were more prominent in patients receiving high concentrations of oxygen by respirator. There was no relationship between duration of illness and the appearance of the membrane formation. Hyaline membranes were most numerous in alveoli, but intrabronchiolar deposition of hyaline plugs was also seen (Fig. 2).

Thromboses in either small or large vessels were present in only one case (M.C.) in which there was a superimposed *pseudomonas* pneumonia. Intraalveolar hemorrhage was pronounced in all cases. Pulmonary edema was less prominent, but relatively constant. Capillaries were severely congested and dilated.

There was histologic focal pneumonia in seven cases. In three (M.R., M.G., and P.S.), alveoli were almost devoid of polymorphonuclear cells. Focal abscesses were found in the lungs of four, especially in M.C. who had superimposed *pseudomonas* pneumonia.

An acute necrotizing tracheobronchitis and bronchiolitis were present in eight cases. These changes were seen as early as the second day of illness and as late as

TABLE 3  
SUMMARY OF AUTOPSY FINDINGS\*

Case	M.C.	P.S.	A.P.	L.D.	M.B.	M.V.	M.R.	J.W.	M.N.
Duration of illness	13d	11d	7d	12d	7d	11d	2d?	5d	14d
<b>Pulmonary findings</b>									
Gross:									
Weight (g) { Right	875	1000	1000	1400	1150	1400	90	1250	800
Left	950	1150	950	1100	1150	1400	75	1000	770
Appearance	Diffusely consolidated, hemorrhagic	Same	Same	Same	Same	Same	Same	Focal consolidation red, gray	Focal severe hemorrhage
<b>Histopathology:</b>									
Alveolar Hemorrhage	+	+	+	+	+	+	+	+	+
Hyaline Membranes	+	+	O	+	+	+	O	+	+
Acute Focal Pneumonia	+	O	+	+	+	+	O	+	+
Epithelial Exfoliation	+	+	O	+	+	+	+	+	+
Atypical regenerative changes:									
Trachea	+	+	O	+	+	+	O	O	O
Bronchi	+	+	O	+	+	+	+	O	+
Bronchioles	+	+	O	+	+	+	O	O	O
Alveoli	+	+	O	+	+	+	O	+	O
<b>Acute necrotizing:</b>									
Tracheitis	+	+	+	+	+	+	O	+	+
Bronchitis	+	+	+	+	+	+	O	+	+
Bronchiolitis	+	+	+	+	+	+	O	+	+
<b>Thrombi:</b>									
Capillary	O	O	O	O	O	O	O	O	O
Arterioles/Arteries	+	O	O	O	O	O	O	O	O
<b>Extrapulmonary:</b>									
<b>Heart:</b>									
Myocarditis	O	O	O	O	O	O	O	O	O
Other	O	O	O	O	ASCVD	O	O	O	O
CNS abnormalities:	Thrombo-emboli recent infarcts	O	O	O	ND	ND	Congested edema	ND	O
Other abnormalities:	O	O	O	Renal transplant, glomerulonephritis	Diabetes mellitus	Multiple myeloma	O	O	O

\* ND—Not examined; +—Finding Present; O—Finding Absent; d—days.



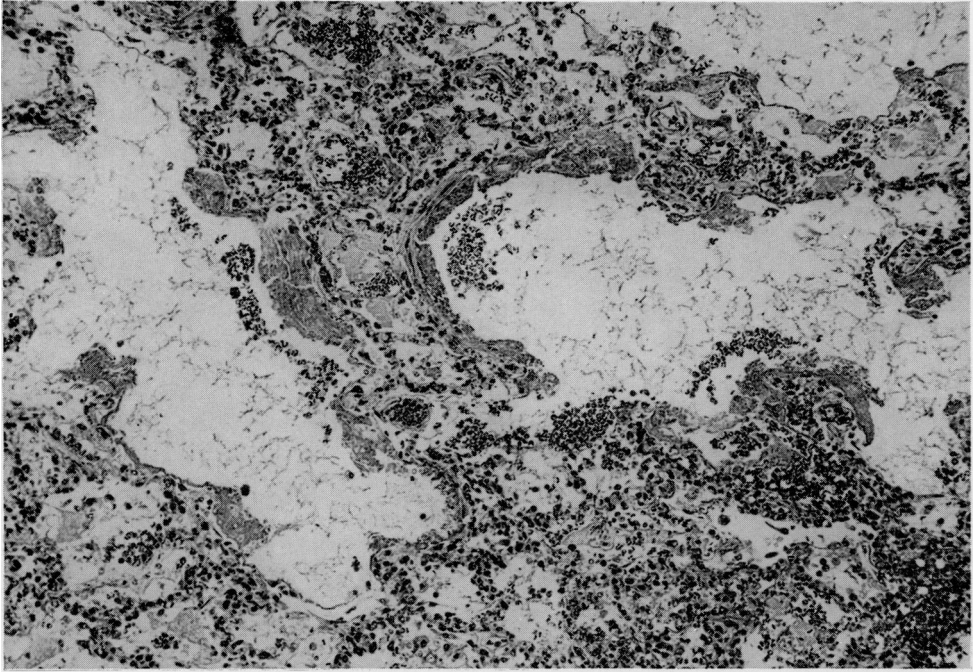


FIG. 1. Hyaline membranes are seen lining alveolar walls with focal intraalveolar hemorrhage ( $\times 150$ , H and E).

the thirteenth day. Focal epithelial changes in the tracheobronchial aborization constituted one of the most striking histopathologic findings in this series. Degenerative changes in the respiratory epithelium was one of the initial histologic alterations. There was necrosis of the goblet and ciliated cells, and desquamation of these cells into the respiratory passages was prominent during the first few days. The basal layer of the respiratory epithelium tended to persist. In three cases of less than a week's duration, regenerative changes were absent. Focal regeneration of the respiratory epithelium was present in five cases; the duration of illness in these patients varied from 7 to 13 days. The epithelial alterations consisted of stratification of respiratory epithelium including the epithelial cells lining alveoli (Figs. 2 and 3). These regenerative changes were indistinguishable from squamous metaplasia in many regions.

Pathologic examination of other organs included observations on the heart, with no gross or microscopic evidence of myocarditis being detected in any of the cases. Examination of the central nervous system revealed abnormalities in only two cases. In M.C., recent and organizing thromboemboli were present in the small cerebral arteries; in addition, multiple small recent hemorrhagic infarcts were identified in the right cerebral and cerebellar hemispheres. In M.R., the brain was congested and edematous. Additional extrapulmonary changes were limited to reactive hyperplasia in lymph nodes, most striking in the hilar areas.

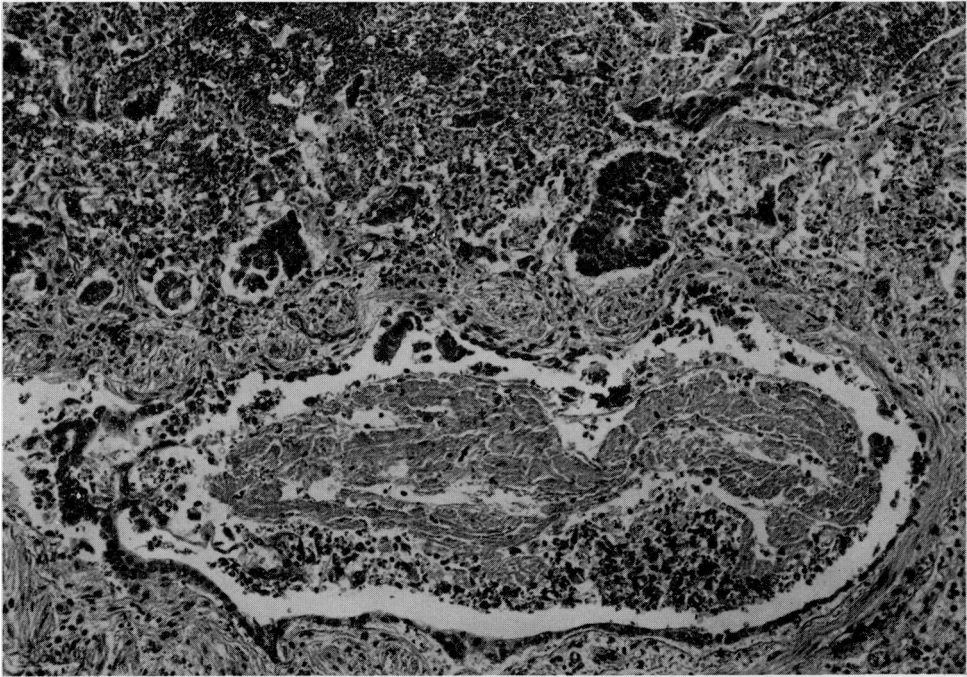


FIG. 2. Extensive epithelial regenerative changes in a bronchiole and alveoli resembling neoplastic change. Within the lumen of the bronchiole there is deposition of material with staining properties identical with hyaline membranes found in the alveoli ( $\times 150$ , H and E).

## DISCUSSION

This necropsy series represents a limited sample of deaths associated with epidemic influenza of the Hong Kong variant. A comparison of the clinical and pathologic data in our study with observations from earlier influenza pandemics indicates a number of similarities which will be discussed briefly.

During a 3-month period beginning in September, 1918, there were 280 fatal cases attributed to influenza in the Grace-New Haven Hospital. Eighty-two of these were autopsied. Although Dr. Winternitz wrote a comprehensive monograph on the pathology of influenza based upon this necropsy material(9), virologic studies were lacking, since influenza virus was not isolated until 1933(10). However, Winternitz's findings have been largely confirmed in subsequent influenza pandemics, and most of the pathologic changes in our cases had been described by him. Some of the original material from which Winternitz made his observations was reviewed. There was a remarkable similarity in both the gross and microscopic findings in both series. The most notable difference was the absence of abacterial influenza pneumonia in Winternitz's cases.

Petersdorf *et al.*(11), reported their experience with the complications of influenza, with particular emphasis on 11 fatal cases in the Yale-New Haven Hospital during the 1957-58 pandemic. A review of this necropsy material revealed pulmonary changes similar to those seen in the present series.

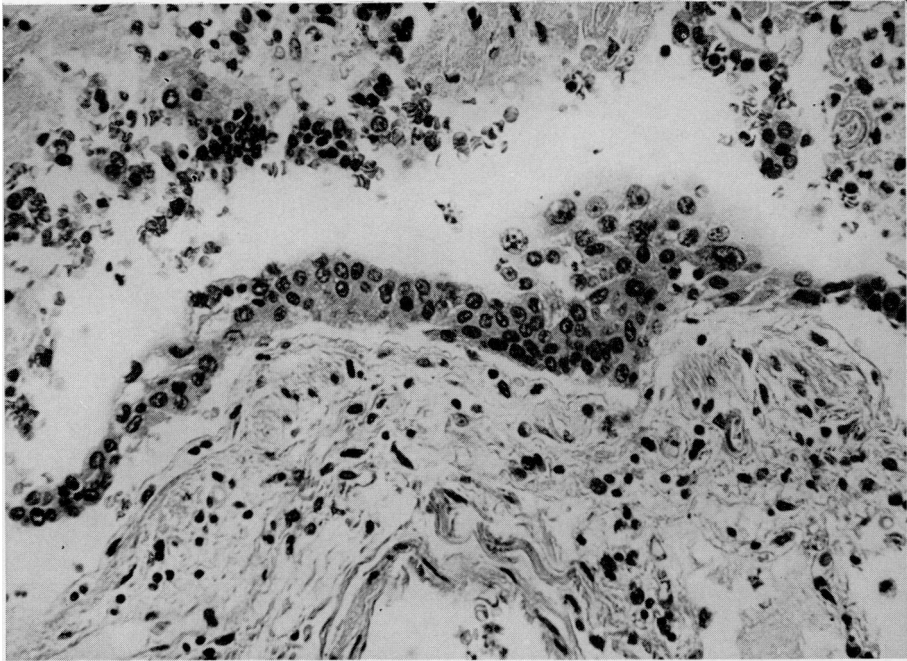


FIG. 3. Wall of small bronchus showing epithelial cell regeneration to form a metaplastic stratified epithelium. Within the epithelium there are several mitoses ( $\times 350$ , H and E).

Hyaline membranes, found in seven of our nine cases, were most prominent in the three patients receiving high concentrations of oxygen over prolonged periods of time by artificial ventilation. Clinical(12-14) and experimental(15) studies have demonstrated that such oxygen therapy and artificial ventilation will result in significant pulmonary damage. It is, therefore, impossible to assess the relative roles played by infection and oxygen toxicity if they occur simultaneously, as they did in several of our cases.

Winternitz found the extrapulmonary lesions of influenza to be neither constant nor characteristic, and our results are similar. We observed a notable discrepancy between cerebral signs and autopsy findings in that although six patients show preterminal central nervous system signs, only two had cerebral pathologic changes. Oseasohn(16) found cerebral edema to be an almost universal autopsy finding in 33 cases, but numerous other authors have not observed such changes.

The frequency of myocarditis also varies markedly in different reports(17-20). Myocarditis was not demonstrated in our series, nor was it observed in either the series of Winternitz(9), or of Petersdorf *et al.*(11).

An etiologic diagnosis was made in seven of the nine cases on the basis of recovery of HK influenza virus either from the throat swab antemortem (1 case) or from the lungs, postmortem (6 cases). In two patients, all virus isolation attempts from throat swabs and organs were negative, but one had a specific HK influenza antibody rise. The other patient had a high titer against the epidemic strain in a single serum specimen; since the agent was so recently(re)introduced and the

clinical course was typical, the serologic result was interpreted as presumptive evidence of infection with HK influenza virus.

The secondary bacterial agents(s) in influenza pneumonia have changed markedly since the 1918-19 pandemic. Not only is there variation from pandemic to pandemic, but from place to place in the same pandemic. In 1918-1919 Winternitz(9) and Chickering and Park(21) found a high incidence of secondary staphylococcal pneumonia; Wolbach(22) reported influenza bacillus to be the principal invasive organism; and MacCallum(23) found pneumococcus Type IV at one army camp and almost 100% influenza bacillus at another.

During the ensuing years the proportion of secondary bacterial pneumonia due to staphylococcus aureus in fatal cases of influenza rose sharply from approximately one-third of the total to two-thirds(16,17,19,24,25). However, only one questionable case of staphylococcus aureus superinfection was found in our series. The secondary bacterial agents in five of our cases were gram-negative organisms (see Table 2). This preponderance of gram negative organisms was not found in the general experience in the United States(27) but may well have been influenced by several factors shown to be of importance in superinfection by gram negative bacteria(28) including "the destructive nature of the involvement of the tracheo-bronchial tree" by the primary infection, tracheostomy and the use of multiple antibiotics.

Of the nine patients in our series, five were in good health before the onset of their terminal illnesses. This parallels the experience of Petersdorf *et al.*(13) in the Yale-New Haven Hospital during the 1957-1958 influenza epidemic: seven of the eleven fatal cases they reported were previously in good health. That influenza may induce a fatal illness in the absence of antecedent disease has been noted by others(18-21,23). Nevertheless, the importance of chronic illness in the pathogenesis of influenza has frequently been emphasized, especially the importance of cardiovascular disease. Rheumatic heart disease was the most common cardiovascular problem noted in fatal cases of influenza in a number of previous reports(19-21,26). None of the patients in our series had rheumatic or hypertensive heart disease, but one was diabetic with arteriosclerotic heart disease.

Two of our patients were on immunosuppressive therapy for antecedent illnesses. It is well-known that such individuals fall prey to severe and disseminated viral illnesses. It is reasonable to assume that such immunosuppression was an important factor in the failure to control a usually self-limited illness and that its combination with severe underlying disease was responsible for their death.

Only one patient in the present series had antecedent pulmonary disease. In our patients, the extent of infiltration on initial chest x-ray seemed less significant than the progression of pulmonary involvement.

As in a previous report(13), the importance of low white blood cell counts as an indication of poor prognosis warrants emphasis. Two other clinical features that heralded a worsening course were grossly bloody sputum and the appearance of cyanosis. The latter sign indicated early death unless heroic measures were begun immediately, and even then, the effectiveness of therapy was vague.

The NCDC estimated that approximately 30 million cases due to Hong Kong

influenza occurred in the United States during the last quarter of 1968(29). Despite this high attack rate, clinical evidence of influenzal pneumonia was infrequent. Nevertheless, respiratory complications constituted the gravest hazard. This was well demonstrated in the fatal cases of influenza presented here. Unfortunately, our experience during the 1968–1969 pandemic poignantly depicts the deficiencies in present day supportive therapy. Progressive respiratory failure through increasing hypoxemia characterized each of our cases as was documented by arterial gas studies. Acidosis and carbon dioxide retention appeared only when the patients were moribund. Despite the careful use of the best equipment and methods available, we were unable to maintain our patients until the reparative mechanisms, evident at postmortem, had progressed to the point of allowing normal respiratory exchange.

Hopefully, improved forms of artificial respiration will become available which will reduce the toxic properties of oxygen while maintaining its therapeutic effects. Some optimism appears warranted since recent results with negative pressure artificial respiration in the treatment of respiratory failure of the newborn suggests a possible solution to this problem(30,31). Stern *et al.*(29) were able to achieve better oxygenation with a negative-pressure unit than with a positive-pressure respirator. Moreover, there was no clinical or pathologic evidence of oxygen toxicity in their patients, despite the use of 100% O<sub>2</sub> concentration for periods of up to two weeks. Another major advantage of this form of artificial respiration is the avoidance of an intratracheal tube with its concomitant high incidence of secondary pulmonary infections. Obviously, influenza pneumonia and idiopathic respiratory distress syndrome (RDS) are markedly dissimilar entities. However, they both share in common hyaline membranes which are one of the key obstacles to successful supportive therapy. The above reasoning requires confirmation by animal experimentation.

## SUMMARY

This report summarizes the clinical, microbiological and pathological data in nine fatal cases associated with influenza virus Type A<sub>2</sub>, Hong Kong variant, in Connecticut in the 1968–1969 epidemic. There was no antecedent chronic illness in five of the nine cases. Antecedent cardiovascular and pulmonary disease were each present in only one case. Two patients were receiving immunosuppressive therapy at the time of onset of their fatal illness. Fatal abacterial influenza virus pneumonia was present in three of the nine cases. In contrast with the 1957–1958 influenza pandemic, the secondary or concomitant bacterial agent in four of the cases, was a gram negative organism. Low white blood cell counts, grossly bloody sputum and cyanosis were associated with a rapidly fatal course. Irreversible progressive hypoxemia led to death in most cases. This was not responsive to electrolyte, oxygen and respirator therapy, and the latter two therapies may have contributed to the progression of disease. Pathologic changes in the lungs were similar to those described in previous influenza pandemics. Regenerative activity was striking in those cases surviving more than one week.

## ACKNOWLEDGMENTS

The authors are indebted to the following doctors who made clinical, laboratory and pathological material available for review: Dr. Robert Tennant, Hartford Hospital, Hartford, Ct.; Dr. C. E. McLeod, Middlesex Memorial Hospital, Middletown, Ct.; and Dr. M. R. Ross, Connecticut State Department of Health Laboratory, Hartford, Ct.

The authors wish to extend recognition and thanks to Drs. Dorothy M. Horstmann, Levin Waters, Averill A. Liebow, Lauren V. Ackerman, Carl G. Harford and John M. Kissane, for their valuable review of and suggestions for this manuscript.

## REFERENCES

1. Coleman, M. *et al.*, The Hong Kong/68 Influenza A<sub>2</sub> variant. *Lancet* **2**, 1384-1385, 1968.
2. Robinson, R. Q., Natural history of influenza since the introduction of the A<sub>2</sub> strain. *Progr. Med. Virol.* **6**, 82-110, 1964.
3. Miller, D. G. *et al.*, Clinical virology and viral surveillance in a pediatric group practice: The use of double-seeded tissue culture tubes for primary virus isolation. *Amer. J. Epid.* **88**, 245-256, 1968.
4. Hsiung, G. D., *Diagnostic Virology*. Yale University Press, New Haven, 1964.
5. Beveridge, W. I. B., and Burnet, F. M., The cultivation of viruses and rickettsia in the chick embryo. Special Report No. 256, His Majesty's Stationery Office, London, 1946.
6. Davenport, F. M., and Minuse, E., Influenza viruses. *in* (E. H. Lennette, and N. J. Schmidt, eds.); *Diagnostic Procedures for Viral and Rickettsial Diseases*. New York, American Public Health Association (Ed. 3), pp. 455-469.
7. Laboratory Manual, Basic Laboratory Methods in Virology, N.C.D.C. Laboratory Program, Laboratory Consultation and Development Section, P.H.S., Atlanta, 1968.
8. Sever, J. L., Application of microtechniques to viral serological investigation. *J. Immunol.* **88**, 320, 1962.
9. Winternitz, M. C. *et al.*, *The Pathology of Influenza*, Yale University Press, New Haven, 1920.
10. Smith, N. *et al.*, A virus obtained from influenza patients. *Lancet* **2**, 66-68, 1933.
11. Petersdorf, R. G. *et al.*, Pulmonary infections complicating Asian influenza. *Arch. Int. Med.* **103**, 262-272, 1959.
12. Cederberg, A. *et al.*, Oxygen treatment and hyaline pulmonary membranes in adults. *Acta Path. Microbiol. Scandinav.* **64**, 450-458, 1965.
13. Nash, G. *et al.*, Pulmonary lesions associated with oxygen therapy and artificial ventilation. *N. Engl. J. Med.* **276**, 368-374, 1967.
14. Northway, W. H., Jr. *et al.*, Pulmonary disease following respirator therapy of hyaline-membrane disease. *N. Engl. J. Med.* **276**, 357-368, 1967.
15. Schaeffer, K. E., Avery, M. E., and Bensch, K., Time course of changes in surface tension and morphology of alveolar epithelial cells in CO<sub>2</sub>-induced hyaline membrane disease. *J. Clin. Invest.* **43**, 2080-2093, 1964.
16. Oseasohn, R. *et al.*, Clinicopathologic study of 33 fatal cases of Asian influenza. *N. Engl. J. Med.* **260**, 509-518, 1959.
17. Giles, C., and Shuttleworth, E. M., Postmortem findings in 46 influenza deaths. *Lancet* **2**, 1224-1225, 1957.
18. Louria, D. B. *et al.*, Studies on influenza in the pandemic of 1957-58. II. Pulmonary complications of influenza. *J. Clin. Invest.* **38**, 213-265, 1959.
19. Martin, C. M. *et al.*, Asian influenza A in Boston, 1957-1958. I. Observations in thirty-two influenza associated fatal cases. *Arch. Int. Med.* **103**, 515-531, 1959.

20. Parker, F. *et al.*, Pathologic findings in the lungs of five cases from which influenza virus was isolated. *Amer. J. Path.* **22**, 797-819, 1946.
21. Chickering, H. T., and Park, J. H., Jr., Staphylococcus aureus pneumonia. *J. Amer. Med. Ass.* **72**, 617-626, 1919.
22. Wolbach, S. B., Comments on the pathology and bacteriology of fatal influenza cases as observed at Camp Devens, Camp Devens, Massachusetts, *Bull of Johns Hopkins Hosp.* **30**, 104, 1919.
23. MacCallum, E. G., Pathology of the pneumonia following influenza. *J. Amer. Med. Ass.* **72**, 720-723, 1919.
24. Mark, D. D., The pathology of 1957 (Asian) influenza. *Amer. Rev. Tuberc.* **79**, 440-449, 1959.
25. Martin, C. M., Kunin, C. M., Gottleib, L. S., and Finland, M., Asian influenza A in Boston, 1957-1958. II. Severe staphylococcal pneumonia complicating influenza. *Arch. Int. Med.* **103**, 532-541, 1959.
26. Bulger, R. J. and Sherris, J. C., Decreased incidence of antibiotic resistance among staphylococcus aureus. *Ann. Int. Med.* **69**, 1099-1108, 1968.
27. Sharrar, R. G., National influenza experience in the USA, 1968-69. *Bull. W. H. O.* **41**, 361-366, 1969.
28. Tillotson, J., and Finland, M., Bacterial colonization and clinical superinfection of the respiratory tract complicating antibiotic treatment of pneumonia. *J. Infect. Dis.* **119**, 597-624, 1969.
29. Stern, L. *et al.*, Negative pressure artificial respiration: Use in treatment of respiratory failure of the newborn. *Canadian Med. Ass. Journal* **102**, 595-601, 1970.
30. Linsao, L. S. *et al.*, Negative pressure artificial respiration: Use in treatment of respiratory distress syndrome of the newborn. *Canadian Med. Ass. Journal* **102**, 602-606, 1970.
31. Hers, J. F. and Mulder, J., Gross aspects of the pathology and pathogenesis of human influenza. *Amer. Rev. Resp. Dis.* **80**, 84-97, 1961.