

# MAMMARY DUCT ECTASIA: A CAUSE OF BLOODY NIPPLE DISCHARGE

Alexander K.C. Leung, MBBS, FRCPC, FRCP (UK & IreI), FRCPCH, FAAP and C. Pion Kao, MD, FRCPC  
Calgary, Alberta, Canada

---

We report a 13-year-old girl with bloody nipple discharge as a result of mammary duct ectasia. Our patient is the second reported case of mammary duct ectasia in a pubertal girl. (*J Natl Med Assoc.* 2004;96:543–545.)

---

**Key words:** blood ♦ nipple discharge ♦  
mammary duct ♦ ectasia

Bloody nipple discharge is very rare in childhood.<sup>1,2</sup> We report a 13-year-old girl who had bloody nipple discharge as a result of mammary duct ectasia. To our knowledge, our patient represents the second reported case of mammary duct ectasia in a pubertal girl.

## CASE REPORT

A 13-year-old white female presented with a history of bloody discharge from the left nipple for about one month. There was no associated pain or history of trauma. She had menarche at 11 years of age. Her cycles were regular with only mild cramps. She had mastitis a year ago, which cleared up in a few days with antibiotic treatment. Her past medical history was otherwise unremarkable.

Her father and paternal great-aunt had carcinoma of the breast. Her mother had carcinoma of the breast and non-Hodgkin lymphoma. Her paternal great-aunt had ovarian cancer.

On examination, she had bloody discharge from the left nipple (Figure 1). The breasts were of normal size and consistency, and there was no breast mass

palpable. The nipples were not retracted or inflamed. She had an ejection systolic murmur 2/6 over the precordium. The rest of the examination was normal. In particular, there was no axillary lymphadenopathy.

An ultrasound of the left breast showed prominent ducts deep to the nipple. The retroareolar ducts contained some debris. No definite mass was identified, and the breast tissue was otherwise unremarkable. A galactogram failed to show the presence of an intraductal papilloma. There was specifically a breast duct measuring 0.7 x 0.2 x 0.2 cm shown in the galactogram. A biopsy was declined because of the potential tissue destruction and permanent disfigurement.

## DISCUSSION

Bloody nipple discharge is very rare in infancy and childhood. Berkowitz and Inkelis were the first to report this phenomenon in two six-week-old infants—one girl and one boy.<sup>3</sup> The girl's bloody discharge resolved spontaneously by nine months of age; the boy was lost for follow-up. Fenster reported an eight-month-old male infant with a "brown, watery, guaiac-positive fluid" from both nipples that resolved spontaneously by 12 months of age.<sup>4</sup>

Stringel et al. (1986) reported two more cases of bloody discharge in a three-year-old boy and a five-month-old girl.<sup>5</sup> A subcutaneous mastectomy was performed in the three-year-old boy. The histologic diagnosis was mammary duct ectasia. The five-month-old girl was treated conservatively and the bloody nipple discharge spontaneously resolved at eight months of age.

---

© 2004. From the University of Calgary (Leung, clinical associate professor of pediatrics; Kao, clinical assistant professor of pediatrics); and Alberta Children's Hospital (Leung, pediatric consultant; Kao, pediatric consultant). Send correspondence and reprint requests for *J Natl Med Assoc.* 2004;96:543–545 to: JNMA, 1012 Tenth St. NW, Washington, DC 20001; phone: (202) 207-1555; e-mail: aspeight@nmanet.org

Miller et al. reported a four-year-old boy with four mobile nodules below the right nipple and two mobile nodules below the left nipple.<sup>6</sup> Pressure on these nodules resulted in bloody discharge from the ipsilateral nipple. The breast masses were excised, and the pathologic diagnosis was mammary duct ectasia.

Böber et al. described a two-year-old boy with bloody nipple discharge.<sup>1</sup> Physical examination revealed bilateral nodules of 1 cm each below the nipples. Pressure on the nodules resulted in bloody discharge from the ipsilateral nipple. The breast masses were excised, and the pathologic diagnosis was mammary duct ectasia.

Kitahara et al. reported a 10-year-old girl with bloody discharge from the left nipple.<sup>2</sup> The ultrasonography and computed tomographic scan showed marked dilatation of the mammary ducts. The dilated ducts were excised, and the pathologic diagnosis was mammary duct ectasia.

Al-Arfai et al. reported a four-year-old boy with an ovoid mass above the left nipple; slight pressure on the mass instigated bloody discharge from the nipple.<sup>7</sup> There were two enlarged lymph nodes in the left axilla. The breast mass, including the nipple, and the lymph nodes were excised. Histologic examination showed features characteristic of duct ectasia.

Recently, Weimann reported an eight-month-old boy who showed bilateral bloody discharge from the nipples for five months. Ultrasound examination revealed dilated mammary ducts. The bloody nipple discharge ceased spontaneously at the age of nine months. The author attributed this benign phenomenon to mammary duct ectasia.<sup>8</sup>

The term *mammary duct ectasia* was first introduced by Haagensen to describe a benign lesion of the breast characterized by dilatation of the mammary duct, with inflammatory reaction and fibrosis

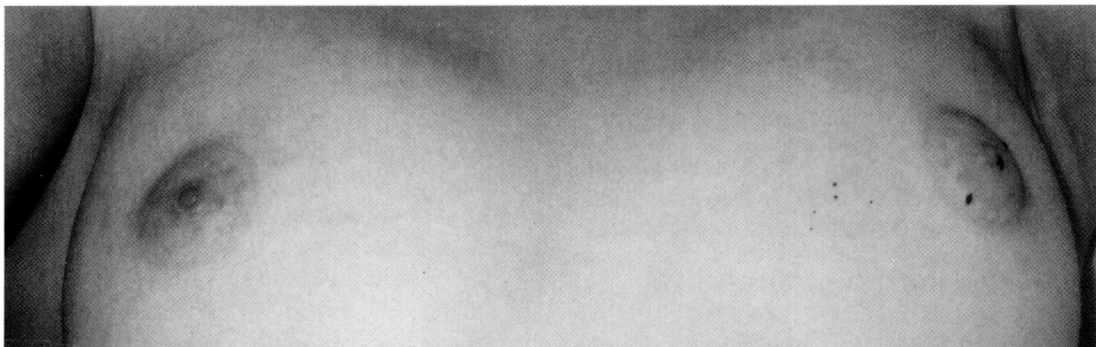
in the periductal stroma.<sup>9</sup> The disease commonly occurs in middle-aged or older multipara.<sup>10,11</sup> Rarely, it occurs in multipara,<sup>12</sup> men,<sup>13,14</sup> and children.<sup>1,2,5,6</sup> Kitahara et al. reported the first case of mammary ductal ectasia in a 10-year-old pubertal girl.<sup>2</sup> To our knowledge, our patient represents the second such case in a pubertal girl.

Mammary duct ectasia is a rare clinical entity in infancy and childhood, but probably is the most common cause of bloody nipple discharge in this age group.<sup>6</sup> Other causes of blood nipple discharge in infancy and childhood include mastitis,<sup>5</sup> trauma,<sup>15</sup> intraductal papilloma,<sup>16</sup> intraductal cyst,<sup>17</sup> mammary ductal hyperplasia,<sup>18</sup> infantile gynecomastia,<sup>19</sup> and very rarely, carcinoma of the breast.<sup>20,21</sup>

The exact etiology of mammary duct ectasia is not known. Possible etiologic factors include chronic inflammation of the periductal stroma with obliteration of the lumen, congenital abnormalities of the nipple and ductal system, infection, trauma, and an autoimmune reaction.<sup>1,5</sup> The degree and severity of ductal ectasia will determine whether palpable masses are present.<sup>6</sup> Bleeding may result from ulceration of the epithelium of the ectatic duct.<sup>6</sup>

In adults, mammary duct ectasia is often treated by local excision in the female<sup>22</sup> and simple mastectomy in the male.<sup>13,14</sup> In children, asymptomatic lesions should be managed conservatively with reassurance and periodic assessments.<sup>5,23</sup> Stimulation or massage of the breast is discouraged, as such maneuvers may cause further ulceration of the ductal epithelium with resultant bleeding.<sup>5</sup> Due to the paucity of available data in the pediatric literature and the lack of established guidelines, surgical intervention for symptomatic lesions is a matter of clinical judgement.<sup>6,23</sup>

**Figure 1. Bloody Discharge from the Left Nipple in a 13-Year-Old Girl**



## ACKNOWLEDGEMENT

The authors would like to thank Enrica Ng for expert secretarial assistance and Sulakhan Chopra of the University of Calgary medical library for help in the preparation of the manuscript.

## REFERENCES

1. Böber E, Özer E, Akgür F, et al. Bilateral breast masses and bloody nipple discharge in a two-year-old boy. *J Pediatr Endocrinol Metabol.* 1996;9: 419-421.
2. Kitahara S, Wakabayashi M, Shiba T, et al. Mammary duct ectasia in children presenting bloody nipple discharge: a case in a pubertal girl. *J Pediatr Surg.* 2001;36:e2.
3. Berkowitz CD, Inkelis SH. Bloody nipple discharge in infancy. *J Pediatr.* 1983;103:755-756.
4. Fenster DL. Bloody nipple discharge. *J Pediatr.* 1984;104:640.
5. Stringel G, Perelman A, Jimenez C. Infantile mammary duct ectasia: a cause of bloody nipple discharge. *J Pediatr Surg.* 1986;21:671-674.
6. Miller JD, Brownell MD, Shaw A. Bilateral breast masses and bloody nipple discharge in a four-year-old boy. *J Pediatr.* 1990;116:744-747.
7. Al-Arfai AA, Chir AF, Mitra DK, et al. Bloody nipple discharge in a four-year-old child. *Ann Saudi Med.* 2003;23:175-176.
8. Weimann E. Clinical management of nipple discharge in neonates and children. *J Paediatr Child Health.* 2003;39:155-156.
9. Haagensen CD. Mammary duct ectasia: a disease that may simulate carcinoma. *Cancer.* 1951;4:749-761.
10. Dixon JM, Anderson TJ, Lumsden AB, et al. Mammary duct ectasia. *Br J Surg.* 1983;70:601-603.
11. Thomas WG, Williamson RC, Davies JD, et al. The clinical syndrome of mammary duct ectasia. *Br J Surg.* 1982;69:423-425.
12. Rees BI, Gravelle IH, Hughes LE. Nipple retraction in duct ectasia. *Br J Surg.* 1977;64:577-580.
13. Chan KW, Lau WY. Duct ectasia in the male breast. *Aust N Z J Surg.* 1984;54:173-176.
14. Mansel RE, Morgan WP. Duct ectasia in the male. *Br J Surg.* 1979;66:660-662.
15. Mudan SS, Ibrahim AE, Wise M, et al. Nipple discharge in a teenager. *J R Soc Med.* 1998;91:490-491.
16. Simpson JS, Barson AJ. Breast tumors in infants and children: a 40-year review of cases at a children's hospital. *Can Med Assoc J.* 1969;101:100-102.
17. Garcia CJ, Espinoza A, Dinamarca V, et al. Breast ultrasound in children and adolescents. *Radiographics.* 2000;20:1605-1612.
18. Myers MB, Kaplan IW. Bleeding from the nipple in infancy due to cystic ductal hyperplasia of the breast. *Ann Surg.* 1956;143:557-560.
19. Olcay I, Gököz A. Infantile gynecomastia with bloody nipple discharge. *J Pediatr Surg.* 1992;27:103-104.
20. Heydenrych JJ, Villet WT, von der Heyden U. Carcinoma of the breast in children: a case report and review of the literature. *S Afr Med J.* 1980;57:1005-1008.
21. Karl SR, Ballantine TV, Zaino R. Juvenile secretory carcinoma of the breast. *J Pediatr Surg.* 1985;20:368-371.
22. Izzidien AY. Mammary duct ectasia. *J R Coll Surg Edin.* 1982;27:361-362.
23. Menken KU, Roll C. Bloody nipple discharge in a three-year-old girl. *Eur J Pediatr.* 1992;152:1047.

Discover your passion  
for excellence. *Again.*

When you join the team at Lovelace Sandia Health System, you not only work alongside some of the best people, using state-of-the-art technology in a supportive environment. You also have the beauty and adventure of the southwest at your front door. We're located in Albuquerque, where outdoor adventures range from bike trails along the Rio Grande valley to skiing the slopes of the spectacular 10,000 foot Sandia Mountains. Of course, we have our share of cultural activities here, too, from the symphony and performing arts to a growing community of art galleries and shops. At Lovelace Sandia Health System, the best is yet to come for your career. Explore a spirit of healing here.

- Cardiology
- Director, Walk-In Clinic
- Ear, Nose & Throat
- Neurosurgery
- Nephrology
- OB Chair
- Pathology
- Pediatrics Chair
- Rheumatology

Lovelace Sandia Health System offers competitive salary and benefits. To apply for a position, please forward your resume to:

Human Resources Department  
Attn: Physician Recruiter  
1258 Ortiz Drive S.E.  
Albuquerque, NM 87108  
physician.midlevel@lovelacesandia.com  
Call (800) 877-7526 x 7700  
www.lovelacesandia.com



**LOVELACE  
SANDIA  
HEALTH SYSTEM**  
Equal Opportunity Employer