

## An Experimental Study of Hip Stability in Human Newborn Cadavers<sup>1</sup>

E. S. CRELIN<sup>2</sup>

*Sections of Gross Anatomy and Orthopaedic Surgery,  
Yale University School of Medicine, New Haven, Connecticut 06510*

Received August 21, 1975

The less frequent variety of hip dislocation occurs before birth and may be associated with neuromuscular disorders such as arthrogryposis or myelomeningocele. The more common variety occurs at or shortly after birth. Therefore, in the common variety the acetabulum is well formed with secondary changes developing rapidly if the hip remains dislocated (13). Trueta (17) states that the latter ought to be called infantile dislocation of the hip (IDH) rather than congenital dislocation of the hip (CDH).

Ligament of the head of the femur is the official term of the Paris Nomina Anatomica. Hereafter the abbreviation LHF will be used whenever the ligament is referred to.

### MATERIALS AND METHODS

The infants used were 13 males and 13 females, between 8 and 9 months gestational age, who died within 24 hr after birth from respiratory distress. A female child was also studied who had both hips dislocated before birth due to arthrogryposis and died of pneumonia at 1.5 years of age. All of the cadavers were willed to me by the parents for scientific study.

The newborn infants were acquired in a fresh state within 8 hr after death and immersed in water at body temperature (36.7°C) so that there was maximum flexibility of their hip joints when studied. The 1.5-year-old female was embalmed prior to the study. Four groups were arranged as follows:

*Group 1 (1 Caucasian and 1 Black male, 1 Caucasian and 1 Black female).* The hip joints were exposed by dissecting away the surrounding soft tissues for a functional study of the joint anatomy. The articular capsule of each joint was excised to determine the relationship the femoral head has with the acetabulum in the position in which the lower limbs are normally maintained in the fetus and newborn infant (Figs. 1 and 2). The limbs were then moved in various directions to determine the possible function the LHF plays in stabilizing the hip joint (Figs. 3 and 4).

*Group 2 (1 Caucasian and 2 Black males, 3 Caucasian females).* The hip joints were exposed in the same manner as those of Group 1 for a test of the strength of the joint capsule and LHF using a push-pull gauge to quantify in foot-pounds the relative differences in force used (Fig. 5). Each cadaver was placed in the prone position with its hip joints exposed, leaving the articular capsules intact. When the right hip joint was studied I placed my left hand firmly against the left lumbar region of the cadaver (Fig. 6). I grasped the entire right thigh with my right hand and placed the thigh in an

<sup>1</sup>Supported by the Crippled Children's Aid Society, New Haven, Conn.

<sup>2</sup>Professor of Anatomy, Section of Gross Anatomy, Department of Surgery; Chairman, Human Growth and Development Study Unit, Yale-New Haven Medical Center.

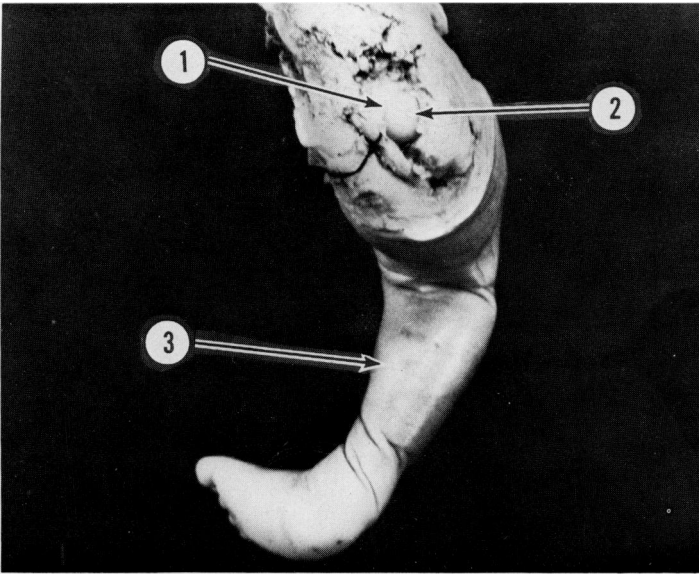


FIG. 1. Posterior view of the right buttock and lower limb from an 8.5-month gestation-age newborn female. The overlying soft tissue and articular capsule of the hip joint were removed. This exposes the head of the femur making maximum contact with the acetabulum as the limb is in the position normally maintained by the fetus and newborn infant. (1) Rim of acetabular labrum; (2) femoral head; (3) leg.

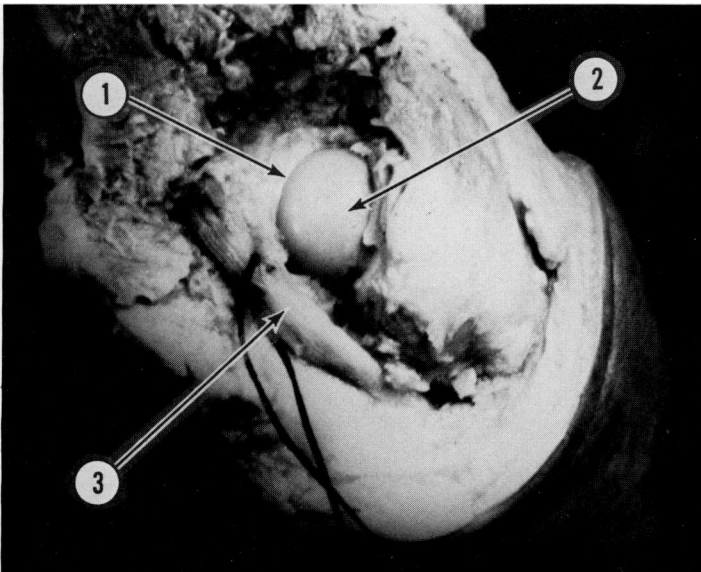


FIG. 2. Enlarged view of the buttock region of Fig. 1. With the thigh flexed and abducted only a small portion of the head of the femur makes contact with the acetabulum. (1) Rim of acetabular labrum; (2) femoral head; (3) sciatic nerve pulled medially with black string to expose the hip joint.

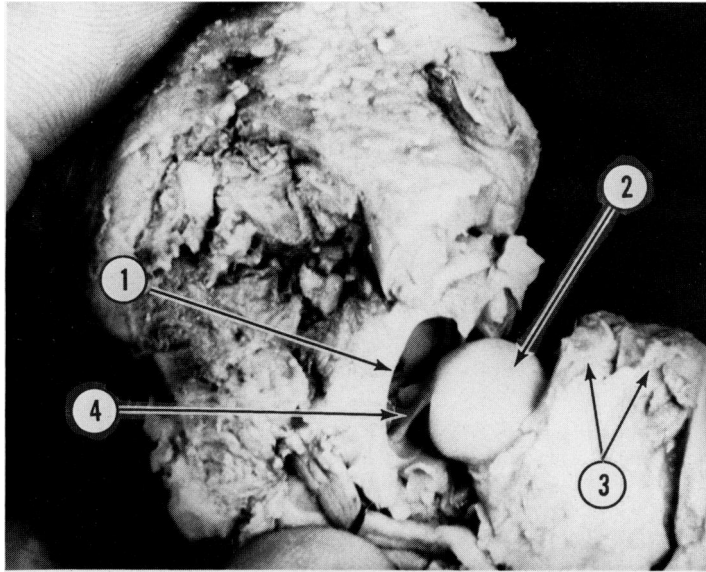


FIG. 3. Posterior view of the hip joint of Fig. 2 with the head of the femur drawn directly laterally away from the acetabulum. (1) Rim of acetabular labrum; (2) femoral head; (3) insertions of gluteus medius and minimus on greater trochanter; (4) LHF.

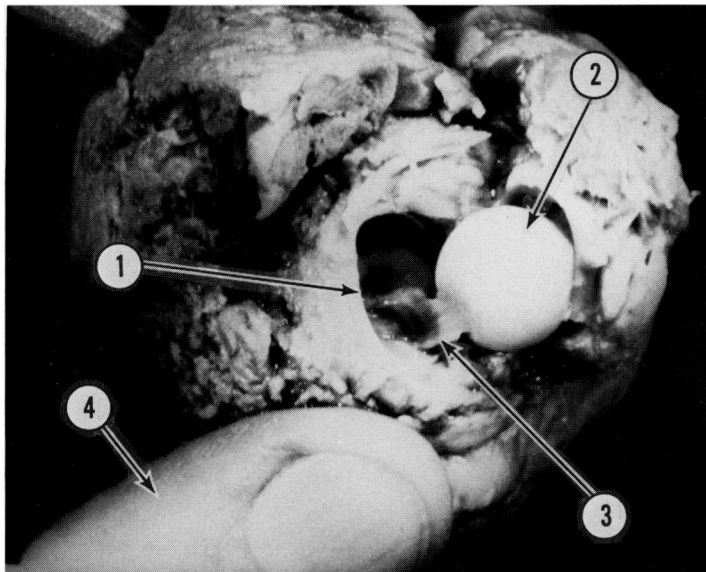


FIG. 4. Posterior view of the hip joint of Fig. 3 with the head of the femur drawn antero-inferiorly away from the acetabulum. (1) Rim of acetabular labrum; (2) femoral head; (3) LHF; (4) left thumb of the investigator.




FIG. 5. Push-pull gauge lying on a flat surface. It was used to estimate the relative force applied to the hip joint. The right hand of the investigator grips the handle of the gauge and is applying a push force of 20 ft-lb.

extended and adducted position. I then forced the thigh until firm resistance was met in the direction that caused the femoral head at the hip joint to move postero-superiorly in relationship to the cadaver. The amount of force used could be estimated by immediately shifting my left hand to the upper left side of the push-pull gauge and grasping a handle on the gauge as shown in Fig. 5. As I firmly held the gauge with my left hand I pushed the handle toward it with my right hand with a force estimated to be what I had just applied to the cadaver thigh. I would repeat this process several

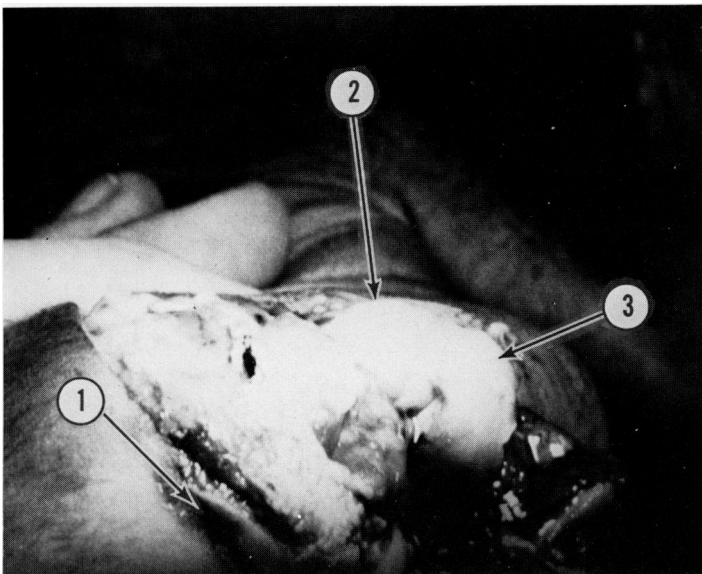


FIG. 6. Caudal view of the right buttock region of an 8.5-month gestation-age newborn female. Overlying soft tissue was removed to expose the hip joint with the articular capsule intact. The head of the femur is pushed against the postero-superior part of the taut capsule (2) using about 20 lb of relative force. (1) Anus; (3) greater trochanter.

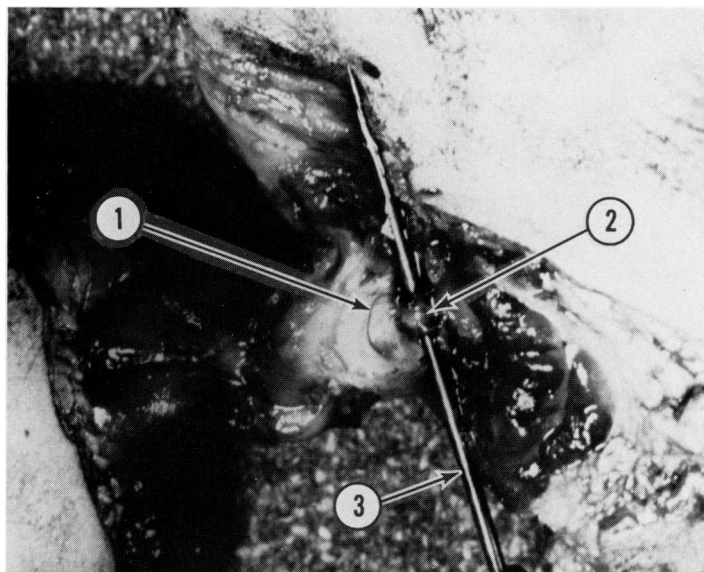


FIG. 7. Antero-inferior view of the hip joint shown in Fig. 6. A small opening was made in the joint capsule to expose the LHF so it could be transected. (1) Cut edge of capsule; (2) LHF; (3) a metal needle probe that was passed behind the LHF so as to expose it for transection.

times, shifting between the cadaver and the gauge, until I had an estimate of the force used as measured in foot-pounds. When the left joint was studied I would use my right hand to steady the cadaver or gauge and would grasp the left thigh or gauge handle with my left hand. This method of determining the relative differences in the force applied by a single individual has been shown to be a good one (8).

After the joints were studied with the articular capsule intact, a small opening was made in the antero-inferior part of the capsule to expose and transect the LHF where it attached to the femoral head (Fig. 7). Each cadaver was then placed in the prone position and each thigh was forced in the direction that caused the femoral head to move postero-superiorly at the hip joint (Fig. 8). The force was applied to the joint in increasing amounts by quantifying it at intervals with the gauge until the capsule ruptured (Fig. 9).

*Group 3 (6 Caucasian and 2 Black males, 7 Caucasian and 1 Black female).* Each extended and adducted thigh of the undissected cadavers was grasped and moved with force in the same manner described for those of Group 2. The force used was applied in increasing amounts, by quantifying it at intervals with the gauge, in an attempt to dislocate the hip joint by having the femoral head pass out of the acetabulum in a postero-superior direction. When either the femur fractured or the femoral head dislocated, the hip joint was exposed immediately by careful dissection and examined (Figs. 10 and 11). The LHF were then excised, preserved, embedded in paraffin, longitudinally serially sectioned at  $7\ \mu\text{m}$ , and stained with hematoxylin and eosin for microscopic study (Figs. 12-14).

*Group 4 (1 Caucasian female).* The hip joints of the 1.5-year-old child that had been dislocated since before birth were dissected and the anatomy evaluated in light of the findings of those of the newborn infants (Fig. 15).

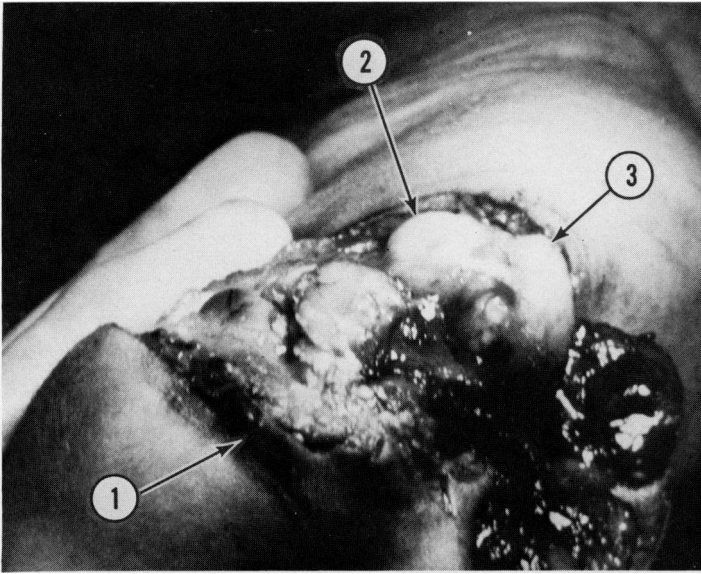


FIG. 8. Caudal view of the hip joint shown in Fig. 7 after the LHF was transected. The head of the femur is pushed against the postero-superior part of the stretched capsule (2) using about 10 lb of relative force. The transection of the LHF allowed the head of the femur to be displaced more and the capsule to be maximally tensed with less force than prior to its transection as shown in Fig. 6. (1) Anus; (3) greater trochanter.

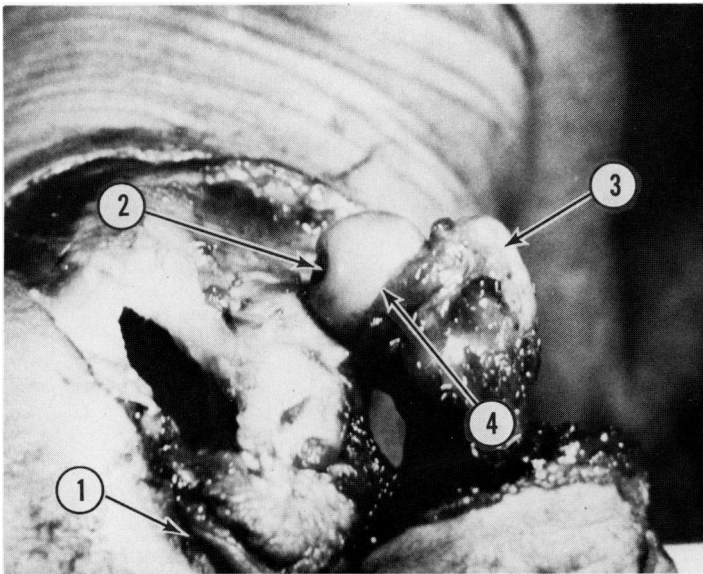


FIG. 9. Caudal view of the hip joint shown in Fig. 8. With the LHF transected the postero-superior part of the capsule ruptured when the head of the femur was pushed against it at between 15 and 20 lb of relative force. This allowed the head to be completely displaced out of the acetabulum. (1) Anus; (2) fovea capitis where the LHF attachment to the head was transected; (3) greater trochanter; (4) torn edge of capsule.

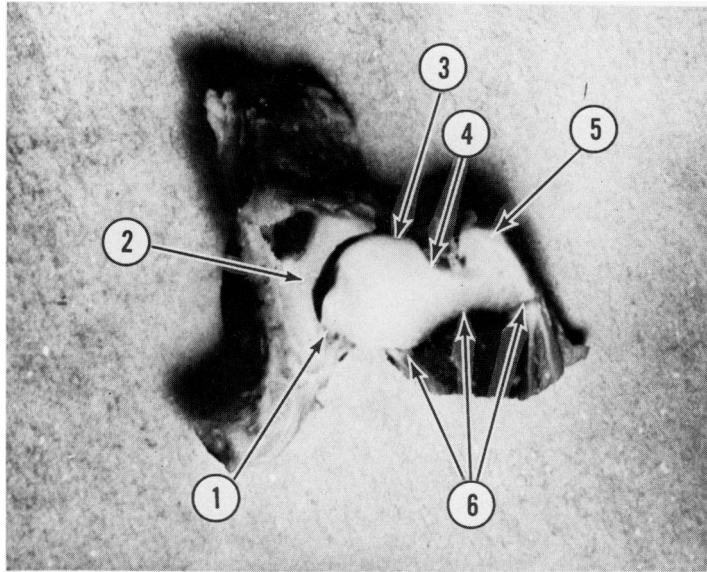


FIG. 10. Midfrontal (coronal) section of the right hip joint of an 8-month gestation-age newborn female. The femur fractured when a relative force exceeding 20 lb was applied to the thigh in an attempt to dislocate the femoral head postero-superiorly at the hip joint. (1) Acetabular attachment of the LHF; (2) cartilagenous acetabulum; (3) femoral head; (4) femoral neck; (5) greater trochanter; (6) site of fracture at the metaphyseal junction of the ossified femoral shaft with the cartilagenous neck and greater trochanter.

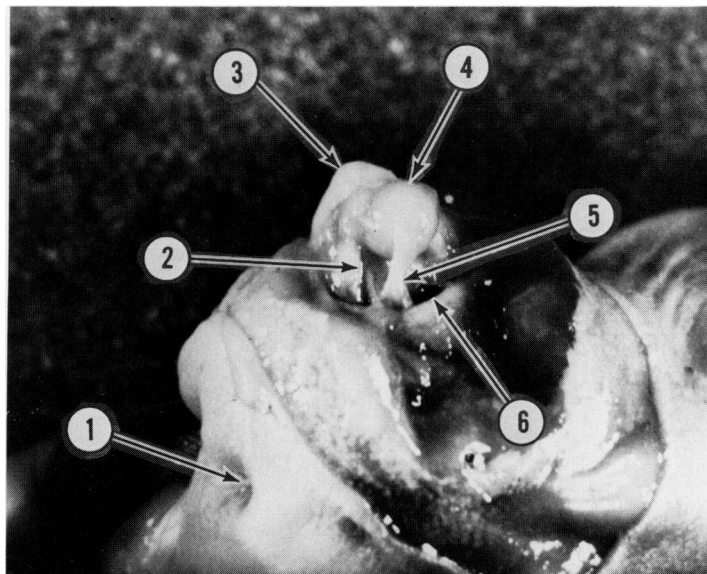


FIG. 11. Posterior view of the left hip region of an 8-month gestation-age newborn female. The hip joint was dislocated when a relative force of about 20 lb was applied to the extended and adducted thigh in a postero-superior direction. The superior part of the articular capsule had ruptured and an excessively long LHF allowed the femoral head to completely dislocate postero-superiorly. (1) Anus; (2) torn edge of capsule; (3) greater trochanter; (4) femoral head; (5) LHF; (6) rim of acetabular labrum.



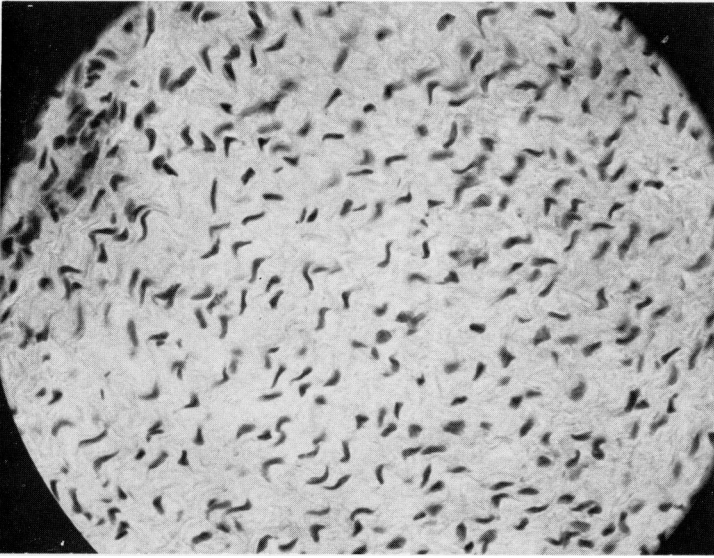


FIG. 12. Photomicrograph showing the nuclei of fibrocytes interspersed among wavy, parallel bundles of collagen fibers of the LHF of normal length from a newborn female.  $\times 200$ .

## RESULTS

*Group 1.* The most common position of the lower limbs in the fetus and newborn infant is with the thighs flexed and abducted at the hip joints, the knees flexed, and the feet inverted in the talipes varus mode (3) (Fig. 1). In this position it was found that only a small part of the femoral head is in contact with the relatively small and shallow acetabulum (Fig. 2). In fact, it is shallower at birth than at any other time in

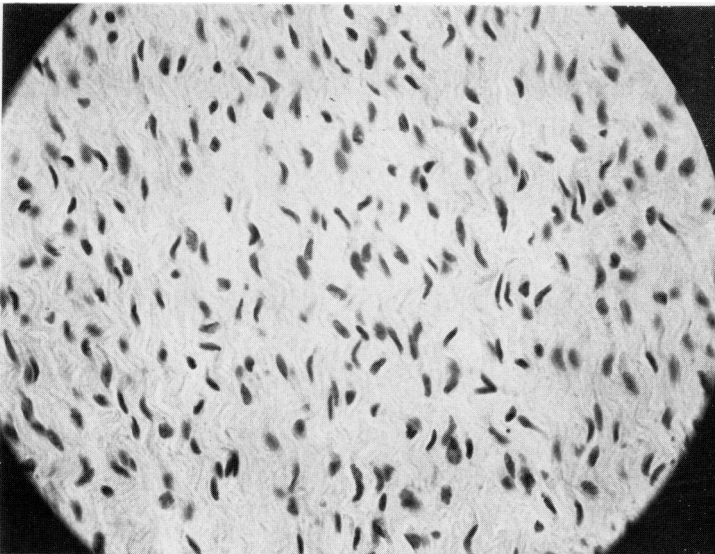


FIG. 13. Photomicrograph showing the nuclei of fibrocytes interspersed among wavy parallel bundles of collagen fibers of the LHF of an abnormally long length from a newborn female.  $\times 200$ .



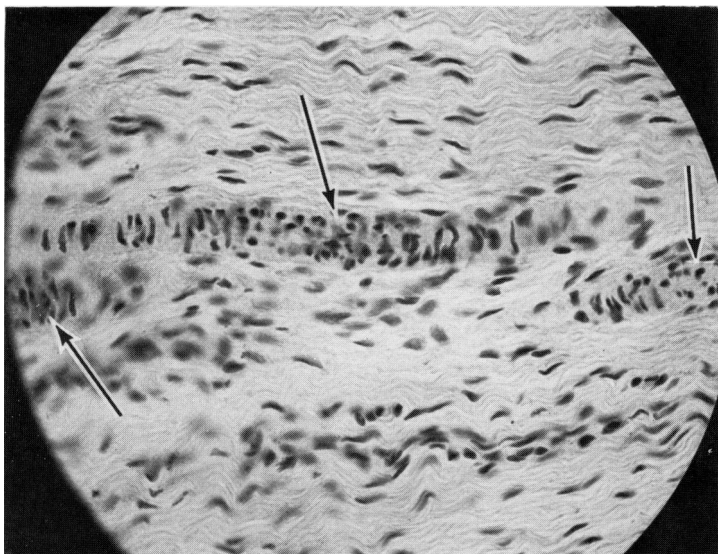


FIG. 14. Photomicrograph of the center of the LHF of Fig. 13 showing arterioles (arrows) passing parallel along the length of the LHF.  $\times 200$ .

development (11). The neck of the femur is very short at birth and forms a much more acute angle with the shaft than in adulthood (1,3) (Fig. 10). This results in the sciatic nerve being in closer relationship to the hip joint at birth than in adulthood (1,19) (Fig. 2).

With the articular capsule excised and the LHF intact the femoral head could

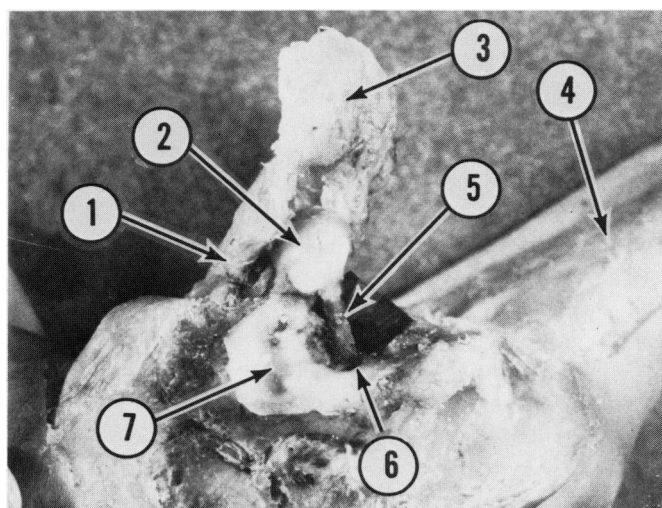


FIG. 15. Posterior view of the right hip region of a 1.5-year-old female whose hips were dislocated bilaterally since before birth. The overlying gluteus maximus muscle was completely removed and the joint capsule was opened. The right thigh (1) was flexed and adducted to allow exposure of the femoral head (2) that was drawn away from its articulation with a false acetabulum (7). The visibility of the abnormally long LHF (5), attached to the femoral head and the abnormally small true acetabulum (6), was enhanced by placing a piece of black paper behind it. Parts of the gluteus medius and minimus muscles (3) attached to the greater trochanter and the left thigh (4) are also shown.

readily be moved laterally away from its contact with the acetabulum (Fig. 3). If the head was then moved in an antero-inferior direction it could be completely displaced away from the acetabulum before the intact LHF prevented further displacement (1) (Fig. 4). When the thigh was grasped and placed in the normal fetal position of flexion and abduction, with force exerted in a postero-superior direction, the tensed LHF caused the head to make a snug contact with the acetabulum.

The LHF in each cadaver was a flat band of connective tissue just as it always is in the adult (Figs. 3, 4, 11, and 15). Therefore, the commonly used unofficial term ligamentum teres, or round ligament, is descriptively erroneous.

The hip joint anatomy, including size, was essentially the same in both sexes. In fact, the pelvises at birth lack the sexual dimorphism found in adulthood (1-3).

*Group 2.* Firm resistance to postero-superior displacement of the femoral head at the hip joint occurred at about 20 lb ( $\pm$  3 lb) of relative force in exposed joints with the articular capsule and LHF intact. The amount of postero-superior movement of the femoral head was small, causing only a slight bulge of the capsule (Fig. 6).

When the LHF was transected through a small opening in the antero-inferior part of the capsule, the femoral head made a pronounced bulge of the stretched capsule with only about 10 lb of relative force directed postero-superiorly at the hip joint (Fig. 8). When this application of force was increased to between 15 and 20 lb the capsule ruptured, allowing the femoral head to be completely displaced postero-superiorly away from the acetabulum (Fig. 9).

There were no differences in the elasticity and strength of the capsule and LHF between the sexes or races.

*Group 3.* In every undissected cadaver, except two, the femur fractured when the relative force used to attempt to dislocate the femoral head postero-superiorly at the hip joint exceeded 20 lb. It was not possible to determine accurately just how much relative force was needed to fracture the femurs except to state that it occurred between 20 and 40 lb of force. The fracture in each femur was transverse, occurring at the junction between the ossified metaphysis and the cartilagenous head, neck, and greater trochanter (Fig. 10).

The two exceptions were Caucasian females. Bilateral postero-superior dislocations of the femoral heads occurred when a relative force of about 20 lb was used (Fig. 11). Immediate exposure of the joints revealed ruptured articular capsules but intact LHF. The LHF were abnormally long in that they allowed the femoral heads to be completely dislocated postero-superiorly. The LHF were similar to all of those of the other cadavers in that they were only slightly elastic. Microscopic examination of these abnormally long LHF revealed that they were essentially the same as those from the other cadavers (Figs. 12 and 13). They consisted chiefly of parallel bundles of collagen fibers in which elongated fibrocytes were interspersed. In the center of each LHF there were small blood vessels running parallel with the longitudinally arranged collagen fibers (Fig. 14).

*Group 4.* Exposure of the hip joints of the 1.5-year-old female that had been dislocated since before birth due to arthrogryposis revealed that both LHF were intact and abnormally long (Fig. 15). The postero-superiorly dislocated femoral heads articulated with false acetabula. Each false acetabulum had developed on the surface of the ilial portion of the coxal bone immediately postero-superiorly to the true acetabulum. On each side the false and true acetabula were lined with a continuous layer of hyaline cartilage. The true acetabula were very small, abnormal shallow facets. The articular capsules were intact but abnormally thick.

## DISCUSSION AND CONCLUSIONS

It is well known that the incidence of newborn hip dislocation is three to five times greater in females (4,13). Therefore, it was not surprising that the only two infants that had their hips dislocate experimentally were females.

In the numerous research articles and textbooks on the subject, the prevailing stated cause of the common variety of dislocation, subluxation or instability of the hip at birth is simple laxity of the joint capsule (13). The results of the present experiment demonstrate that the LHF and not the capsule is the most important structure in preventing postero-superior dislocation. The results also demonstrate that the LHF plays no role in preventing dislocation in any other direction. Therefore, the capsule and the adductor muscles of the joint function primarily to prevent dislocation in every direction except postero-superiorly. Fortunately, the newborn infant reflexly maintains the lower limbs in essentially the same position in which they were maintained in the uterus. In this position any force that pushes the lower limbs toward the body causes the LHF to function at a maximum in stabilizing the hip joint. The newborn infant reflexly strongly resists the straightening of the lower limbs. This prevents the weak supporting structures of the hip joint, the capsule and adductor muscles, from being stressed. It is interesting to read in an article that in order for the femoral head to move out of the acetabulum, the capsule and the powerful anterior iliofemoral ligament must become weakened (17). Powerful is one of the last adjectives I would use to describe the flimsy, almost transparent capsule and iliofemoral ligament of the newborn infant. Therefore, Salter (12) is quite correct in warning against the practice of straightening a newborn's legs. He stresses that maintained extension of the unduly lax hip in a tightly wrapped blanket may then lead to persistent dislocation.

The results of the present experiment reveal that in order for the femoral head to dislocate postero-superiorly, the LHF has to be abnormally long. Judging from the high incidence of hip instability when infants are examined shortly after birth, it is not uncommon for the LHF to be longer than normal. Fortunately, in these candidates for hip dislocation the joint becomes more stable at 4 to 8 weeks when the positive Barlow and/or Ortolani sign is lost (10).

Stanisavljevic (14) attempted to dislocate the femoral head postero-superiorly in normal newborn cadavers. He did not have any specimens with abnormally long LHF; therefore, he only succeeded in fracturing their femurs. He also found that negative pressure plays no significant role in stabilizing the hip joint of the newborn infant.

McKibbin (9) found in a newborn cadaver with bilateral dislocation of the hips that the only significant abnormality present was a redundancy of the capsular ligaments and elongation of the LHF. The fact that the LHF of the child of the present experiment whose hip dislocations occurred before birth were intact indicates that the ligament must be long enough to permit postero-superior dislocation of the femoral head. The arthrogyrosis caused abnormal stresses on the hip joints over a critical period of time before birth that probably induced a gradual abnormal lengthening of the LHF to occur. The reason why abnormally long LHF are commonly present at birth in the absence of any other pathology is more difficult to explain, unless one accepts the simple fact that some merely grow too long in relationship to the femoral head and acetabulum.

After studying for many years the effects of the hormones of pregnancy on the joints of mammalian pelvises (2), I was confident I would find histological changes in

the abnormally long LHF of the present experiment reflecting a response to the maternal hormones before birth. However, there were no differences in the microscopic structure or the elasticity of the abnormally long LHF when compared with those of normal length.

The authors of well-known human anatomy textbooks are in a quandary when they try to describe the utility of the LHF in the adult, i.e., "Although it should theoretically resist adduction, it apparently does not become taut enough to function as a checking ligament" (7). "The ligament of the head of the femur is of little use in resisting violence or in imparting strength to the joint" (15). "It has, however, but little influence as a ligament" (6). "It is of doubtful mechanical significance" (5). "Its function is uncertain" (18). The results of the present experiment should allow these authors to state with confidence that although the LHF serves no function in the adult, it is the most important structure in stabilizing the very immature hip joint before and for the first 8 weeks after birth. Likewise, even though the contribution of arterial blood to the femoral head via the LHF may be negligible or even absent in the adult (16), it is undoubtedly quite important during the early formation and growth of the ligament.

### SUMMARY

A functional quantitative study of the anatomy of the hip joint in newborn cadavers revealed that the ligament of the head of the femur is the most important structure in stabilizing the joint with the lower limbs held in the usual *in utero* position. Attempts to forcefully dislocate the femoral head postero-superiorly failed except in two females in whom the ligaments of the head were abnormally long. Microscopic study of these ligaments did not show any evidence that their increased length was due to the effects of maternal hormones.

### REFERENCES

1. Crelin, E. S., "Anatomy of the Newborn: An Atlas." Lea & Febiger, Philadelphia, 1969.
2. Crelin, E. S., The development of the bony pelvis and its changes during pregnancy. *Trans. N.Y. Acad. Sci.* 31, 1049 (1969).
3. Crelin, E. S., "Functional Anatomy of the Newborn." Yale Univ. Press, New Haven, 1973.
4. Duthie, R., and Hoagland, F. T., Congenital orthopedic deformities. In "Principles of Surgery." (S. Schwartz, Ed.), McGraw-Hill, New York, 1974.
5. Gardner, E., Gray, D. J., and O'Rahilly, R. "Anatomy." Saunders, Philadelphia, 1975.
6. "Gray's Anatomy." (C. M. Goss, Ed.). Lea & Febiger, Philadelphia, 1973.
7. Hollinshead, W. H., "Textbook of Anatomy." Harper & Row, New York, 1974.
8. Katz, D., and Stevenson, W., Experiments on elasticity. *Brit. J. Psychol.* 28, 190 (1937).
9. McKibbin, B., Anatomical factors in the stability of the hip joint in the newborn. *J. Bone Joint Surg.* 52B, 148 (1970).
10. Pappas, A. M., Congenital hip dysplasia, In "Surgery of the Hip Joint" (R. G. Tronzo, Ed.), Lea & Febiger, Philadelphia, 1973.
11. Ralis, Z., and McKibbin, B., Changes in shape of the human hip joint during its development and their relation to its stability. *J. Bone Joint Surg.* 55B, 780 (1973).
12. Salter, R. B., Degenerative arthritis linked to postnatal hip dislocation. *RN*, 25 (1972).
13. Sharrard, W. J. W. "Paediatric Orthopedics and Fractures." Blackwell Scientific, Oxford, 1971.
14. Stanisavljevic, S. "Diagnosis and Treatment of Congenital Hip Pathology in the Newborn." "Williams & Wilkins, Baltimore, 1964.
15. Trotter, M., and Peterson, R. R., Arthrology. In "Morris' Human Anatomy," (B. J. Anson, Ed.), pp. 390. McGraw-Hill, New York, 1966.
16. Trueta, J. "Studies of the Development and Decay of the Human Frame." Saunders, Philadelphia, 1968.

17. Trueta, J., Growth and development of bones and joints: Orthopaedic aspects. *In* "Scientific Foundations of Paediatrics" (J. A. Davis and J. Dobbing, Eds.), pp. 399-419. Saunders, Philadelphia, 1974.
18. Walmsley, R., Syndesmology or arthrology. *In* "Cunningham's Textbook of Anatomy" (G. J. Romanes, Ed.), pp. 246. Oxford Univ. Press, London, 1964.
19. White, A. A., Crelin, E. S., and McIntosh, S., Septic arthritis of the hip joint secondary to umbilical artery catheterization associated with transient femoral and sciatic neuropathy. *Clin. Orthop.* **100**, 190 (1974).