

## Systemic Uptake and Intestinal Inflammatory Effects of Luminal Bacterial Cell Wall Polymers in Rats with Acute Colonic Injury

R. BALFOUR SARTOR,<sup>1,2\*</sup> THOMAS M. BOND,<sup>1</sup> AND JOHN H. SCHWAB<sup>2,3</sup>

*Department of Medicine,<sup>1</sup> Department of Microbiology and Immunology,<sup>3</sup> and Core Center for Diarrheal Diseases,<sup>2</sup> University of North Carolina School of Medicine, Chapel Hill, North Carolina 27599*

Received 31 December 1987/Accepted 4 May 1988

**The systemic uptake and local intestinal inflammatory potential of luminal bacterial cell wall polymers in rats with normal and acutely inflamed colons were measured. Rats were injected intracecally with either <sup>125</sup>I-labeled group A streptococcal peptidoglycan-polysaccharide complexes or equal amounts of Na<sup>125</sup>I, after either nonspecific colonic injury with 4% acetic acid or injection with buffer. The colons of rats injected with peptidoglycan-polysaccharide had higher inflammatory scores than Na<sup>125</sup>I-injected rats, a greater incidence of mucosal ulceration and transmural inflammation after acetic acid injury, and an increased frequency of focal accumulations of inflammatory cells in the lamina propria and submucosa after buffer injection. Radioactivity in the liver, spleen, and mesenteric lymph nodes was higher in the colon-injured rats that received peptidoglycan-polysaccharide 48 h before tissue collection than in the noninjured rats (*P* < 0.002). Group A streptococcal polysaccharide antigen concentration within the liver, spleen, and mesenteric lymph nodes, measured by enzyme-linked immunosorbent assay, was significantly higher in the colon-injured rats that received cell wall polymers than in noninjured rats. These results indicate that luminal bacterial cell wall polymers with well-described inflammatory and immunoregulatory potential can cross injured colonic epithelia and are capable of initiating and potentiating intestinal inflammation.**

Bacterial cell wall polymers initiate and sustain acute and chronic relapsing granulomatous inflammation with characteristic immunological changes after local or systemic injection in laboratory animals (3, 33). Covalently bound peptidoglycan-polysaccharide complexes (PG-PS), the primary structural component of cell walls of nearly all bacterial species, including the normal intestinal flora, are responsible for these inflammatory and immunomodulating effects. Aqueous suspensions of purified group A streptococcal PG-PS induce local granulomatous enterocolitis that persists for 6 months when injected intramurally into rat intestines (27) and chronic relapsing erosive synovitis (5), vasculitis with skin lesions (4), uveitis (46), hepatic granulomas (40), and anemia (R. B. Sartor, S. K. Anderle, W. J. Cromartie, and J. H. Schwab, *Abstr. Annu. Meet. Am. Soc. Microbiol.* 1987, B146, p. 49) when injected systemically. In vivo and in vitro immunomodulating effects of PG-PS include activation of macrophages (30) and the classical and alternate complement pathways (8); mitogenic, adjuvant, and immunogenic effects on B lymphocytes (18); and regulation of T cells (D. Regan, P. Cohen, W. J. Cromartie, and J. H. Schwab, submitted for publication). Because the histologic appearance, systemic distribution of inflammation, and immunologic changes induced by PG-PS resemble the inflammatory characteristics of Crohn's disease and because high concentrations of bacteria and presumably their cell wall polymers are found in the colon and distal small intestine, we have postulated that PG-PS from intestinal bacteria is involved in the pathogenesis of Crohn's disease, as well as certain other chronic inflammatory diseases (5, 25). However, intestinal PG-PS complexes must cross the epithelium if they are to produce intestinal and systemic inflammation. High-molecular-weight compounds within the intestinal lumen are capable of crossing the intestinal epithelium (19, 42), with evidence of increased transport across injured intestines (28,

36). In preliminary experiments we have demonstrated that small but immunologically significant amounts of gavage-fed group A streptococcal PG-PS are absorbed by the normal rat intestine, as indicated by immunoreactive PG-PS within liver and mesenteric lymph nodes and a serum immunoglobulin M (IgM) response to PG-PS epitopes (26).

The goals of this study were to investigate systemic uptake of luminal PG-PS across normal and nonspecifically injured rat colons and to determine whether enteral PG-PS can induce and perpetuate intestinal inflammation. Because PG-PS is concentrated within macrophages in the liver, spleen, and mesenteric lymph nodes after systemic injection (7), we measured PG-PS radioactivity and antigen in these organs after intracecal injection. In this paper we report that mucosal absorption and systemic distribution of luminal bacterial cell wall polymers are enhanced by acute colonic injury. Furthermore, PG-PS induces mild mucosal and submucosal inflammation and potentiates nonspecific colonic injury.

### MATERIALS AND METHODS

**Bacterial cell culture.** Group A, type 3, strain D-58 streptococci (*Streptococcus pyogenes*) were grown to early stationary phase in 15-liter batches of Todd-Hewitt broth (BBL Microbiology Systems, Cockeysville, Md.) in a VirTis fermentor (The VirTis Co., Gardiner, N.Y.) with continuous stirring at 37°C. The pH was maintained at 7.00 to 7.03 by the automatic addition of 5 N NaOH, and additional glucose was added (1 liter of 45% glucose at 3 ml/min).

**PG-PS purification.** Bacterial cell wall fragments were prepared as previously described (11). Briefly, bacteria were washed three times with phosphate-buffered saline (PBS) and broken by shaking with glass beads in an MSK cell homogenizer (Bronwill Scientific, Inc., Rochester, N.Y.). Cell walls were separated from glass beads by filtration through a coarse-sintered glass filter, the filtrate was centrifuged at 30,000 × *g* for 30 min, and the cell wall layer was

\* Corresponding author.

washed three times in PBS. PG-PS polymers were then prepared by extraction of the cell wall three times with 2% sodium dodecyl sulfate (Sigma Chemical Co., St. Louis, Mo.) at 56°C (10). PG-PS polymers were washed 10 times with PBS and distilled water, dialyzed against distilled water, and lyophilized. This entire procedure was carried out under aseptic conditions, and the purified PG-PS preparations were sterile as determined by the lack of growth on blood agar plates. PG-PS polymers ranging from molecular weight (MW)  $5 \times 10^6$  to  $5 \times 10^8$  were prepared by sonication for 45 min (Branson Sonicator) and removal of large fragments by centrifugation at  $1,000 \times g$  for 30 min (11). Rhamnose was measured colorimetrically by the method of Dische and Shettles (6) and was the basis for determining injection dose.

**Radiolabeling of PG-PS fragments.** Purified PG-PS fragments were labeled with  $^{125}\text{I}$  by a modification of the method of Ulevitch (39) as previously described (10). Briefly, benzimidate-substituted PG-PS fragments were radiolabeled with  $^{125}\text{I}$  using lactoperoxidase coupled to CNBr-activated Sepharose 4B (Pharmacia Fine Chemicals, Piscataway, N.J.) and dialyzed against PBS to remove unbound  $^{125}\text{I}$ . Gel filtration of the PG-PS suspension on Sephacryl S-200 (200,000 MW exclusion limit; Pharmacia) demonstrated that the majority of the  $^{125}\text{I}$  was covalently bound to PG-PS, with a mean of 80% of radioactivity in the void volume and 4% in the fractions corresponding to free  $^{125}\text{I}$  on three determinations. Each milliliter of  $^{125}\text{I}$ -PG-PS contained  $5.4 \times 10^7$  cpm and 14.4 mg of cell wall as determined by rhamnose concentration.

**Experimental protocol.** Twenty female Sprague-Dawley rats 7 to 9 weeks old (143 to 187 g) were obtained from Zivic-Miller Laboratories, Allison Park, Pa. Rats were given water containing 0.05 M NaI for 48 h prior to the experiment and 0.5 ml of 0.15 M NaI via tail vein injection immediately prior to laparotomy, in a modification of Skogh's technique, to saturate their serum and tissue protein iodine-binding sites (29). In a preliminary experiment, oral and intravenous NaI pretreatment of rats gavage-fed  $^{125}\text{I}$  decreased tissue and blood radioactivity by 74.5 to 93.5% (data not shown). Rats were divided into four groups of five rats each and fasted overnight. Animals were anesthetized with an intramuscular injection of 0.13 ml of Innovar (fentanyl, 0.05 mg, plus droperidol, 2.5 mg/ml; Janssen Pharmaceutica, Inc., Piscataway, N.J.) per 100 g of body weight and given 0.5 ml of 0.15 M NaI via tail vein injection. After a laparotomy under aseptic conditions, a ligature of 4-0 silk was placed at the cecal-ascending colon junction. Using a modification of the method of Krawisz et al. (15), colon injury was produced in groups I and II by injecting 1.5 ml of 4% acetic acid (HAc) into the ascending colon approximately 5 mm distal to the suture, followed at 20-s intervals by injections of 2 ml of air and 3 ml of PBS at the same site. Rats in groups III and IV (noninjured colon groups) received injection of 1.5 ml of PBS into the ascending colon followed at 20-s intervals by 2 ml of air and 3 ml of PBS. Immediately after the ascending colon injections, rats in groups I and III then were injected with 1 ml of radiolabeled PG-PS ( $5.4 \times 10^7$  cpm) into the superior portion of the cecum, while groups II and IV received intracecal injections of 1 ml of  $\text{Na}^{125}\text{I}$  ( $5.4 \times 10^7$  cpm). All injections were done with 27-gauge needles. Preliminary studies demonstrated that  $^{125}\text{I}$  levels within luminal contents of the distal ileum and proximal jejunum were not different 2 and 4 h after injection, indicating that  $^{125}\text{I}$  injected into the cecum did not reflux into the small intestine. The ligature around the cecal-ascending colon junction was then re-

moved, and the abdominal incision was closed with two layers of 4-0 chromic and 4-0 silk sutures. Each group of rats was then placed in separate cages with food and water ad libitum. Forty-eight h after injection, rats were killed with carbon dioxide, their intestines were examined grossly, and tissues were collected for histology, radioactive counting, and immunoassay. Portions of the liver, spleen, mesenteric lymph nodes, cardiac blood, cecal contents, and an ankle joint with skin removed were weighed, and the amount of  $^{125}\text{I}$  was determined with a gamma counter (1197 series, automatic Gamma Counting System; Searle Analytic Inc., Des Plaines, Ill.). After counting, tissues for immunoassay were stored at  $-20^\circ\text{C}$  in sterile tubes and the intestines were fixed in 10% buffered Formalin. Forty-eight h was used as the experimental time point because preliminary studies showed reproducible inflammation with 4% HAc and less retention of free  $^{125}\text{I}$  within organs than at earlier time points.

**Immunoassay.** Preparation of liver, spleen, and mesenteric nodes for enzyme-linked immunosorbent assay (ELISA) of group A streptococcal polysaccharide was carried out in the following manner. Weighed specimens were homogenized in a glass tissue grinder with 0.6 ml of 0.1 M Tris with 1% Tween 80 and 0.02% sodium azide per g of tissue. Each sample was then sonicated for 10 min (Raytheon Sonicator) and centrifuged at  $13,000 \times g$  for 5 min. Radioactivity of supernatants was compared with values before homogenization to correct for loss of antigen during the homogenization and centrifugation steps. The supernatant contained 46% (mean value of eight tissues; range, 35.7 to 67.3%) of the radioactivity that was present within the tissue prior to homogenization and measured 0.73 ml for 1 g of tissue. The extraction efficiency was similar in the liver, spleen, and mesenteric lymph nodes. The amount of PG-PS in the supernatant was measured by the microELISA method developed by Eisenberg et al. (1, 7). Extracts of tissues were added to 96-well microtiter plates previously coated with rabbit anti-group A streptococcal polysaccharide antibody (1  $\mu\text{g}/\text{ml}$ ) which had been affinity purified on an *N*-acetylglucosamine column. Biotinylated affinity-purified anti-group A polysaccharide antibody (1  $\mu\text{g}/\text{ml}$ ) was then added, followed by avidin-conjugated alkaline phosphatase. The color reaction was developed with *p*-nitrophenylphosphate substrate and read in an automated microELISA reader (Dynatech Laboratories, Inc., Alexandria, Va.). A standard curve was constructed using known amounts of PG-PS. The concentration of PG-PS within whole organs was calculated using the formula: tissue weight (g)  $\times$  0.73 ml/g  $\times$  value (pg/ml), divided by 46% to correct for extraction losses. The validity of this method of measuring PG-PS within tissues was substantiated by measuring known concentrations of PG-PS added to normal liver extracts. There was no evidence of significant tissue inhibitors, and measurement of PG-PS correlated well with added amounts.

**Histologic scoring criteria.** A section of the proximal, middle, and distal colon was obtained from each rat after fixation in 10% buffered Formalin. Sections were collected from grossly involved tissues, if present, or 1 cm distal to the injection site and from the mid-transverse and mid-descending colon in grossly normal specimens. Tissues were embedded in paraffin, and sections were stained with hematoxylin and eosin and then scored in a blinded fashion by a single observer (R.B.S.) on a 0 to 4+ scale as follows: 0, normal tissue; 1+, increased mononuclear cells or presence of scattered polymorphonuclear leukocytes (PMNs) with no thickening of the lamina propria or submucosa; 2+, moderate increase in inflammatory cells with some thickening of

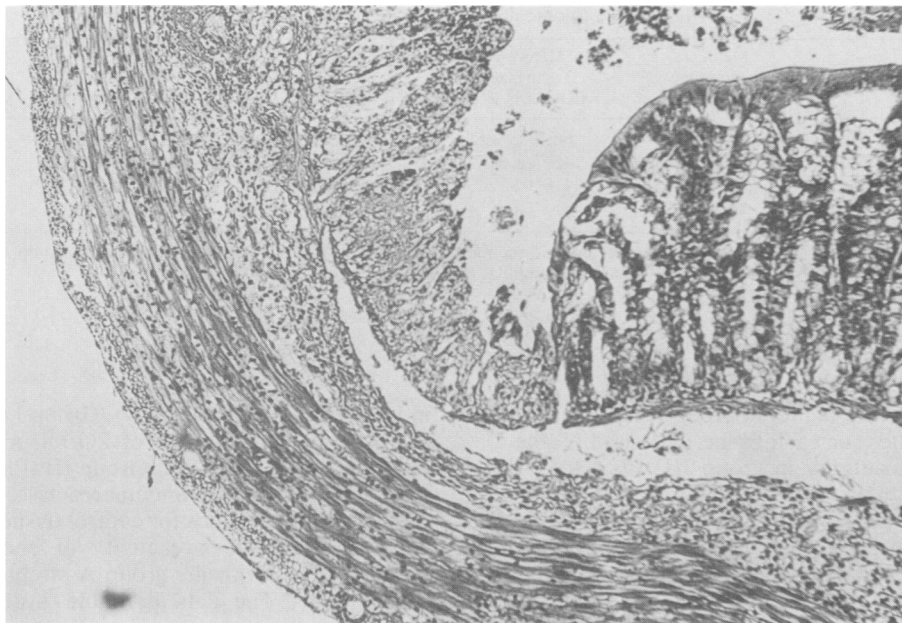


FIG. 1. Histology of acute inflammation of a rat colon injected with 4% HAC and 14.4 mg of sonicated group A streptococcal PG-PS 48 h before harvesting (group I). The mucosa is focally inflamed with denuded epithelium, shallow ulcers, and infiltration of the lamina propria with PMNs adjacent to intact mucosa with limited inflammation. The submucosa is thickened with infiltrating PMNs. (Hematoxylin plus eosin stain.)

the intestinal wall; 3+, marked increase in PMNs or mononuclear cells or both, widening of the lamina propria or submucosa, and focal mucosal ulcers; 4+, widespread ulceration and necrosis. The percentage of the surface area that was denuded of epithelial cells and the presence of transmural inflammation and PMNs were noted on each section of intestine.

**Statistical evaluation.** The mean and standard error of the mean for inflammatory scores, percentage of mucosal surface ulcerated, tissue radioactivity, and antigen concentrations were computed for each group. Results were analyzed to determine whether the data were parametric or nonparametric. Most results were nonparametric. Statistical significance of HAC and PG-PS exposure was determined by parametric or nonparametric analysis of variance. If this analysis indicated a statistical difference, the individual groups were further compared using parametric or nonparametric one-tailed *T* tests, as appropriate. Alpha levels were adjusted on the basis of the number of comparisons made.

## RESULTS

**Clinical observations.** All rats which had 4% HAC injected into the colon developed signs of systemic illness by 12 to 24 h after gut injury. This included both group I (HAC + PG-PS) and group II (HAC + Na<sup>125</sup>I). Most prominent signs included decreased activity level and watery diarrhea. Several animals developed mild conjunctivitis. In contrast, rats in groups III (PBS + PG-PS) and IV (PBS + Na<sup>125</sup>I), which did not receive colonic injection of HAC, showed no evidence of illness and had completely recovered from surgery by 12 h after laparotomy.

**Gross observations.** All rats with HAC colon injury (groups I and II) had hemorrhages on the serosal (external) surface of the ascending colon near the injection site and on focal areas of the transverse and descending colon and rectum. The mucosal surface of the HAC-injured colons contained exten-

sive areas of sharply demarcated ulceration with an adherent grey or tan exudate and hemorrhage. Mucosal ulceration was consistently present in the proximal colon near the injection site and in the mid-colon, but was less evident in the distal colon. The cecum and small intestines were grossly normal. In contrast, control rats injected with PBS (groups III and IV) had no grossly visible abnormalities of the serosal or mucosal surfaces of the colon.

**Microscopic observations.** All animals with HAC injury had obvious colonic injury. There were multiple areas of hemorrhagic necrosis of the mucosa with marked thickening of the lamina propria and dense infiltration of PMNs. Areas of intense inflammation with ulceration were adjacent to areas with intact epithelium but increased numbers of PMNs in the submucosa (Fig. 1). Inflammation was present from the injection site in the ascending colon to the distal colon, although the descending colon was less actively involved. Group I (HAC + PG-PS) colon sections had higher inflammatory scores, and a larger percentage of the colonic surface area was denuded of epithelial cells, than was the case for group II (HAC + Na<sup>125</sup>I) (Table 1). Transmural inflammation and PMNs were more frequently seen in sections from group I than other groups. PBS-injected colons had no evidence of mucosal ulceration or transmural inflammation (Fig. 2). However, 73% of the sections from group III (PBS + PG-PS) had increased numbers of mucosal and submucosal mononuclear cells as compared with 27% of group IV (PBS + Na<sup>125</sup>I) sections, and the inflammatory score of group III was higher than that of group IV ( $P = 0.003$ ). One rat in group III had submucosal PMNs (Fig. 3) associated with a 2+ inflammatory score. These findings suggest that PG-PS within the colonic lumen potentiated HAC-induced injury and produced mild inflammation in buffer-injected animals.

**Systemic uptake from the colon and tissue distribution of PG-PS.** The radioactivity levels of livers, spleens, and mes-

TABLE 1. Histological evaluation of colonic inflammation

Group	Mean inflammatory score <sup>a</sup> ± SE	Mean % of surface denuded <sup>a</sup> ± SE	Transmural inflammation <sup>b</sup> (%)	PMNs <sup>b</sup> (%)	Mucosal and submucosal inflammation <sup>b</sup> (%)
Group I (HAc + PG-PS)	3.6 ± 0.1 <sup>c</sup>	66.7 ± 3.8 <sup>d</sup>	16/18 <sup>c</sup> (89)	18/18 <sup>c</sup> (100)	18/18 <sup>c</sup> (100)
Group II (HAc + <sup>125</sup> I)	3.0 ± 0.4	45.7 ± 4.7	10/15 (67)	13/15 (87)	13/15 (87)
Group III (PBS + PG-PS)	0.9 ± 0.2 <sup>c</sup>	0	0/15 (0)	1/15 (7)	11/15 (73) <sup>e</sup>
Group IV (PBS + <sup>125</sup> I)	0.3 ± 0.1	0	0/15 (0)	0/15 (0)	4/15 (27)

<sup>a</sup> Results are obtained from microscopic evaluation of three colonic sections from each rat, five rats in each group (except group I, *n* = 6).

<sup>b</sup> Number of colonic sections positive/total number of sections examined, percentage in parentheses.

<sup>c</sup> *P* ≤ 0.06 compared with group II.

<sup>d</sup> *P* = 0.02 compared with group II.

<sup>e</sup> *P* ≤ 0.009 compared with group IV.

enteric lymph nodes were higher in group I (HAc + PG-PS) than in all other groups for each tissue measured (Table 2). Although organ radioactivity in group III (PBS + PG-PS) was much lower than in the colon-injured groups, levels were significantly higher (*P* ≤ 0.003) than those of group IV (PBS + Na<sup>125</sup>I), suggesting transport of radiolabeled PG-PS across noninjured colon. Radioactivity of cecal contents 48 h after injection was much higher in the rats receiving PG-PS than in those receiving Na<sup>125</sup>I for both HAc-injured groups (group I, 689 × 10<sup>3</sup> cpm/g, versus group II, 22 × 10<sup>3</sup> cpm/g; *P* < 0.001) and noninjured groups (group III, 19 × 10<sup>3</sup> cpm/g, versus group IV, 0.8 × 10<sup>3</sup> cpm/g; *P* = 0.003). These results indicate a higher rate of absorption or emptying of free <sup>125</sup>I from the cecum compared with the higher-MW PG-PS and also suggest that colonic injury with HAc delays cecal emptying. Organs of group I animals also contained the highest percentage uptake of injected radioactivity, and group III levels were significantly higher than those of group IV (*P* < 0.001) (Table 2).

To determine whether radioactivity within tissues represented radiolabeled PG-PS or merely enzymatically cleaved free <sup>125</sup>I, immunoreactive group A streptococcal PG-PS was measured in liver, spleen, and mesenteric lymph node ho-

mogenates by ELISA (Fig. 4). Group I (HAc + PG-PS) had significantly higher levels of PG-PS in all tissues than did group III (PBS + PG-PS). Group III (PBS + PG-PS) did not have higher levels of immunoreactive PG-PS than control tissues. Positive values for control tissue homogenates probably represent cross-reactivity of endogenous PG-PS or tissue antigens with the group A streptococcal polysaccharide epitope. The data in Table 3 demonstrate that the colon-injured rats that received PG-PS (group I) had a higher percentage of injected cell wall within their organs than did noninjured rats (group III).

## DISCUSSION

The implications of transport of macromolecules across the normal and injured intestine have been discussed in several reviews (23, 41, 42). However, uptake of intestinal PG-PS complexes across colonic epithelium, a process of potential importance in inducing and maintaining intestinal and systemic inflammation, has not been previously shown. Our results indicate that small but detectable amounts of luminal group A streptococcal PG-PS were transported into the liver, spleen, and mesenteric lymph nodes of rats whose



FIG. 2. Photomicrograph of a control rat's colon injected with PBS and Na<sup>125</sup>I 48 h before tissue collection (group IV). No significant inflammation is apparent. (Hematoxylin plus eosin stain.)

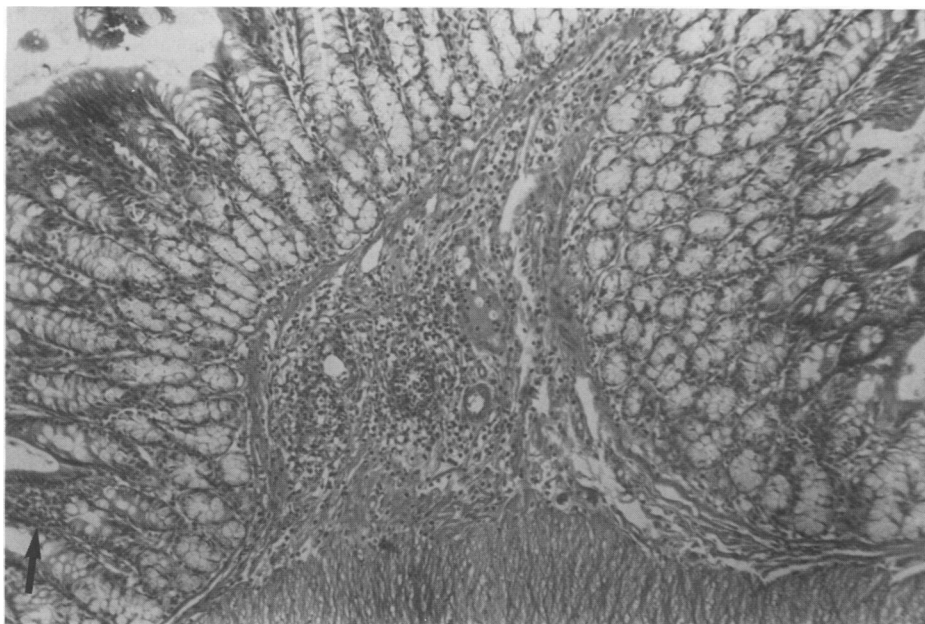


FIG. 3. Inflammation of a rat colon injected with PBS and intracecal sonicated group A streptococcal PG-PS polymers 48 h before tissue collection (group III). Acute and chronic inflammatory cells infiltrate the thickened submucosa, and a focal accumulation of lymphocytes is present in the lamina propria (arrow). (Hematoxylin plus eosin stain.)

colons were nonspecifically injured with 4% HAc. In a preliminary study we found that gavage-fed group A streptococcal PG-PS was detected within systemic organs of normal rats with noninjured intestines and that rats fed PG-PS had increased serum IgM antibodies to PG (26). In the present study, in which radiolabeled PG-PS was injected into the cecum, both tissue immunoassay and radiolabel results demonstrated enhanced transport of PG-PS across the acutely injured colon, but very little systemic uptake of PG-PS across the noninflamed colon. Presumably, after PG-PS is fed, most of the antigen is absorbed in the small intestine. These results are in agreement with those of Warsaw et al., who demonstrated that colonic absorption of <sup>3</sup>H-labeled bovine serum albumin was much less than small intestinal absorption: 0.13% versus 1.7% of the administered dose, respectively (43). It is probable that in the noninjured state, absorption of PG-PS is more efficient in the small intestine than in the colon because of increased surface area or increased permeability (or both) of the small intestinal epithelial cells. However, the concentration of indigenous bacteria and, presumably, soluble PG-PS is higher in

the colon than in the proximal small bowel by a factor of at least 10<sup>6</sup>.

The radioisotope method of measuring PG-PS transport produced a higher percentage of uptake of administered cell wall than the immunoassay method. This discrepancy probably reflects an overestimation of uptake due to luminal cleavage of the <sup>125</sup>I-PG-PS complex, with subsequent mucosal absorption of free <sup>125</sup>I (16, 37) and binding of <sup>125</sup>I (29) or partially degraded radiolabeled fragments (38) to serum and tissue proteins. We took the following measures to minimize and control for absorption and tissue binding of free <sup>125</sup>I. (i) The radiolabeled PG-PS injected into rats was extensively dialyzed to remove unbound <sup>125</sup>I and was shown to have very little free <sup>125</sup>I by column chromatography. (ii) We minimized nonspecific binding of absorbed free <sup>125</sup>I to tissue, serum, and luminal proteins by saturation with oral and intravenous NaI before injection of radiolabeled PG-PS (29). (iii) Control rats were injected with equal amounts of Na<sup>125</sup>I to control for the maximum possible unlabeled <sup>125</sup>I transport and tissue binding. In spite of these precautions, some of the radioactivity measured within the tissues probably repre-

TABLE 2. Tissue distribution of <sup>125</sup>I-labeled PG-PS after injection<sup>a</sup>

Group	cpm (10 <sup>3</sup> )/organ <sup>b</sup> :			% (10 <sup>-2</sup> ) of injected cpm in organ <sup>b</sup> :		
	Liver	Spleen	Mesenteric lymph nodes	Liver	Spleen	Mesenteric lymph nodes
Group I (HAc + PG-PS)	359 ± 103 <sup>c</sup>	21.4 ± 5.6 <sup>d</sup>	29.3 ± 9.5 <sup>d</sup>	67 ± 19 <sup>d</sup>	4.0 ± 1.0 <sup>d</sup>	5.4 ± 1.7 <sup>d</sup>
Group II (HAc + Na <sup>125</sup> I)	213 ± 43	13.1 ± 3.0	13.9 ± 4.0	39 ± 8	2.5 ± 0.6	2.6 ± 0.8
Group III (PBS + PG-PS)	26 ± 8	1.4 ± 0.2	1.3 ± 0.3	5 ± 1	0.3 ± 0.2	0.24 ± 0.06
Group IV (PBS + Na <sup>125</sup> I)	5 ± 1 <sup>c</sup>	0.3 ± 0.04 <sup>d</sup>	0.3 ± 0.02 <sup>d</sup>	1 ± 0.3 <sup>d</sup>	0.04 ± 0.02 <sup>d</sup>	0.06 ± 0.004 <sup>d</sup>

<sup>a</sup> Groups I and II were injected with 4% NAc into the ascending colon and <sup>125</sup>I-labeled PG-PS (5.4 × 10<sup>7</sup> cpm, 14.4 mg) or Na<sup>125</sup>I (5.4 × 10<sup>7</sup> cpm) into the cecum 48 h before harvesting. Groups III and IV were injected with PBS into the ascending colon, and then the same doses of <sup>125</sup>I-labeled PG-PS or Na<sup>125</sup>I as for groups I and II were injected into the cecum.

<sup>b</sup> Mean ± standard error of the mean.

<sup>c</sup> P ≤ 0.003 versus group III.

<sup>d</sup> P ≤ 0.001 versus group III.

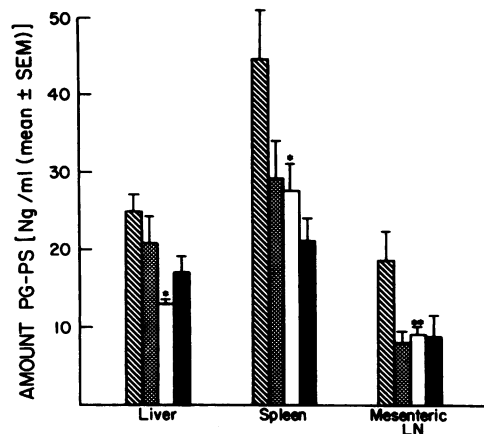


FIG. 4. Measurement of systemically absorbed group A streptococcal PG-PS antigen within organs. PG-PS was measured by ELISA using affinity-purified antibody to group A streptococcal polysaccharide in tissues of rats with and without colonic injury with 4% HAc and injected intracinally with PG-PS (14.4 mg) or Na<sup>125</sup>I. \*,  $P = 0.002$  compared with group I; \*\*,  $P = 0.03$  compared with group I. Hatched bars, Group I (HAc + PG-PS); stippled bars, group II (HAc + <sup>125</sup>I); open bars, group III (PBS + PG-PS); solid bars, group IV (PBS + <sup>125</sup>I). Mesenteric LN, Mesenteric lymph nodes.

sents free <sup>125</sup>I cleaved from PG-PS by pancreatic, mucosal brush border, and bacterial enzymes within the intestinal lumen (37). Unlabeled PG-PS of group A streptococci is resistant to proteolysis by trypsin (3). Alternative reasons for the lower levels of antigen relative to radioactivity within tissues are that the *N*-acetyl-D-glucosamine epitope of PG-PS measured in the ELISA could have been cleaved by intestinal *N*-acetylglucosamidase (35) derived from luminal bacteria and mucosal lysosomes or that PG-PS antigen was poorly extracted from tissues. Measurement of <sup>125</sup>I was performed on whole organs, while the immunoassay was performed on supernatants of homogenized organs. Therefore, the immunoassay may have understated the true amount of PG-PS within tissues. However, both the radiolabeling and ELISA techniques demonstrate clearly that nonspecific mucosal injury with HAc enhances systemic uptake of luminal PG-PS.

Luminal macromolecules are absorbed in small amounts by the normal intestine, while increased absorption of high-MW compounds follows gut injury. Small amounts of horseradish peroxidase (MW 40,000) and intact bovine serum albumin (MW 68,000) are transported by small intestinal epithelial cells into the portal vein and intestinal lymphatics (44). Owen et al. have demonstrated that particles ranging in size from horseradish peroxidase (19) to intact bacteria (21) and *Giardia muris* (20) are transported by specialized epi-

thelial cells (M cells) to adjacent macrophages within Peyer's patches of normal laboratory rodents. Talbot et al. (36) showed enhanced uptake of horseradish peroxidase into the portal blood of guinea pigs whose small intestines were perfused with 0.05 to 0.2% lysolecithin and 5% ethanol in the absence of morphological evidence of mucosal damage, while Worthington and Syrotuck demonstrated ferritin (MW 650,000) and adenovirus type 5 (MW <1,000,000) in the lamina propria and between epithelial cells of rats kept on a low-protein diet for 4 months (47). Seidman et al. (28) have shown increased recovery of rectally administered polyethylene glycol (MW 4,000) from the urine of rabbits with immune complex-mediated colitis. Crohn's disease patients and their clinically unaffected relatives had increased absorption of polyethylene glycol (average MW of 400), which suggests a primary defect of barrier function in this disorder (13). Our observations confirm that experimental colitis enhances the systemic transport of luminal macromolecules, and they extend the previous studies by investigating the absorption of biologically active compounds rather than inert markers serving only as indicators of transport.

These results are plausible, based on the considerable evidence that luminal bacteria and bacterial antigens can cross the intestinal epithelium. We have documented normalization of the cell-mediated immune response of germ-free mice fed PG-PS (C. J. Woolverton et al., *Gastroenterology*, 94:A503, 1988), a rise in serum IgM antibodies to peptidoglycan in normal rats gavage-fed PG-PS (26), and increased levels of serum IgA and IgM to peptidoglycan in Crohn's disease patients as compared with patients with other gastrointestinal disorders and normal controls (R. B. Sartor et al., *Gastroenterology*, 88:1571, 1985). Crohn's disease patients have increased serum antibodies to a variety of indigenous bacterial species (24, 34), indicating increased absorption of, or enhanced immunoresponsiveness to, bacterial antigens. Park et al. (22) suggested that soluble peptidoglycan in the urine of normal human volunteers treated with oral penicillin was derived from the intestinal bacteria; however, they could not exclude the possibility of vaginal bacterial contamination. There is indirect evidence of intestinal lipopolysaccharide (endotoxin; MW >300,000) absorption in mice (12) and detection of plasma lipopolysaccharide in 17 of 18 Crohn's disease patients in a recent trial of intestinal lavage (45). Berg and co-workers have recovered viable normal enteric flora bacteria from the mesenteric lymph nodes, livers, and spleens of rodents under a variety of experimental conditions, including administration of ricinoleic acid in concentrations approximating therapeutic doses of castor oil (17). Thus it is logical to assume that PG-PS polymers with an MW of  $5 \times 10^6$  to  $5 \times 10^8$  could be transported across ulcerated colonic mucosa, particularly if the polymers are partially degraded by luminal enzymes.

Sufficient absorption of intestinal PG-PS in an immunologically active form could have profound local and systemic inflammatory and immunological consequences. Aqueous suspensions of group A streptococcal PG-PS produce chronic, spontaneously relapsing granulomatous inflammation leading to fibrosis in a variety of tissues in laboratory animals (3, 33), including the intestine after intramural injection (27). Associated with the inflammatory reactions in these animal models is a characteristic chronic immunologic response (33). In the present study PG-PS injected into the cecum potentiated injury induced by HAc and produced focal increases of mucosal and submucosal inflammatory cells in noninjured rats. We used group A streptococcal PG-PS because of its resistance to *in vivo* degradation (7)

TABLE 3. Tissue distribution of colon-injected PG-PS by ELISA<sup>a</sup>

Group	% (10 <sup>-4</sup> ) injected PG-PS <sup>b</sup>		
	Liver	Spleen	Mesenteric lymph nodes
I (HAc + PG-PS)	16 ± 2 <sup>c</sup>	1.6 ± 0.3	0.60 ± 0.12
III (PBS + PG-PS)	11 ± 1	1.5 ± 0.3	0.38 ± 0.05

<sup>a</sup> See Table 2 footnotes.

<sup>b</sup> Mean ± standard error of the mean.

<sup>c</sup>  $P = 0.03$  compared with group III.

and because our ELISA could distinguish it from rat normal flora bacterial antigen within tissues. It is important to note that PG-PS polymers occur in nearly all gram-positive bacterial species and that PG-PS from bacteria found within normal rodent and human intestines also has the ability to produce protracted inflammation. We have produced chronic granulomatous enterocolitis persisting at least 8 weeks with the intramural injection of *Streptococcus faecium* (group D *Streptococcus*) PG-PS (27). Stimpson et al. (31) induced arthritis in rats by intraperitoneal injection of sonicated PG-PS derived from two strains of *S. faecium* and *Peptostreptococcus productus*, a gram-positive anaerobe which is 1 of the 10 most commonly isolated bacterial species from human feces. The recent observations that systemically injected lipopolysaccharide can reactivate PG-PS-induced arthritis (10, 32) and that formylated peptides (formylmethionyl-leucyl-phenylalanine [FMLP] and formyl-norleucyl-leucyl-phenylalanine [FNLP]) can produce acute colitis (2) are important because it is likely that many luminal bacterial products, including PG-PS, lipopolysaccharide, and FMLP, are absorbed concurrently after gut injury. In addition to their inflammatory role, enhanced local and systemic absorption of bacterial products could produce many of the immunological changes associated with intestinal inflammation (9, 14). Although the amount of PG-PS transported across the normal and inflamed intestine is small, accumulation of these poorly degradable polymers within tissues could be sufficient to produce protracted intestinal and systemic inflammation and immunologic alterations in the genetically predisposed host, for example, inflammatory bowel disease or reactive arthritis patients. We postulate that transport of luminal PG-PS derived from normal enteric bacteria induces or perpetuates the intestinal and extraintestinal inflammation of Crohn's disease and ulcerative colitis.

#### ACKNOWLEDGMENTS

Technical assistance by David Cleland, Robert Cheek, and Roger Brown, statistical analysis by Leah Bennett of the Biostatistics Core of the Core Center for Diarrheal Diseases, and secretarial support by Shirley Willard are gratefully acknowledged.

This work was supported by Public Health Service grants K01 AM 01112, AM 25733, and AM 34987 from the National Institutes of Health and by the National Foundation for Ileitis and Colitis.

#### LITERATURE CITED

- Anderle, S. K., J. B. Allen, R. L. Wilder, R. A. Eisenberg, W. J. Cromartie, and J. H. Schwab. 1985. Measurement of streptococcal cell wall in tissues of rats resistant or susceptible to cell wall-induced chronic erosive arthritis. *Infect. Immun.* **49**:836-837.
- Chester, J. F., J. S. Ross, R. A. Malt, and S. A. Weitzman. 1985. Acute colitis produced by chemotactic peptides in rats and mice. *Am. J. Pathol.* **121**:284-290.
- Chetty, C., and J. H. Schwab. 1984. Endotoxin-like products of gram-positive bacteria, p. 376-410. *In* E. T. Rietschel (ed.), *Handbook of endotoxin*, vol. 1. Elsevier Biomedical Press, Amsterdam.
- Cromartie, W. J., S. K. Anderle, J. H. Schwab, and F. G. Dalldorf. 1978. Experimental arthritis, carditis and pinnitis induced by systemic injection of group A streptococcal cell walls into guinea pigs, p. 50-52. *In* M. T. Parker (ed.), *Proceedings of the VIIth International Symposium on Streptococci and Streptococcal Diseases*. Reedbooks, Windsor, Berks, England.
- Cromartie, W. J., J. G. Craddock, J. H. Schwab, S. K. Anderle, and C. Yang. 1977. Arthritis in rats after systemic injection of streptococcal cells or cell walls. *J. Exp. Med.* **146**:1585-1602.
- Dische, A., and L. R. Shettles. 1948. A specific color reaction of methyl pentoses and a spectrophotometric micromethod for their determination. *J. Biol. Chem.* **175**:595-603.
- Eisenberg, R. A., A. Fox, J. J. Greenblatt, S. K. Anderle, W. J. Cromartie, and J. H. Schwab. 1982. Measurement of bacterial cell wall in tissues by solid-phase radioimmunoassay: correlation of distribution and persistence with experimental arthritis in rats. *Infect. Immun.* **38**:127-135.
- Eisenberg, R. A., and J. H. Schwab. 1986. Arthropathic group A streptococcal cell wall requires specific antibody for activation of human complement by both the classical and alternative pathways. *Infect. Immun.* **53**:324-330.
- Elson, C. O., M. F. Kagnoff, C. Fiocchi, A. D. Befus, and S. Targan. 1986. Intestinal immunity and inflammation: recent progress. *Gastroenterology* **91**:746-768.
- Esser, R. E., S. A. Stimpson, W. J. Cromartie, and J. H. Schwab. 1985. Reactivation of streptococcal cell wall-induced arthritis by homologous and heterologous cell wall polymers. *Arthritis Rheumatism* **28**:1402-1411.
- Fox, A., R. R. Brown, S. K. Anderle, C. Chetty, W. J. Cromartie, H. Gooder, and J. H. Schwab. 1982. Arthropathic properties related to the molecular weight of peptidoglycan-polysaccharide polymers of streptococcal cell walls. *Infect. Immun.* **35**:1003-1010.
- Goris, H., F. DeBoer, and D. van der Waaij. 1985. Myelopoiesis in experimentally contaminated specific-pathogen-free and germfree mice during oral administration of polymyxin. *Infect. Immun.* **50**:437-441.
- Hollander, D., C. M. Vadheim, E. Brettholz, et al. 1986. Increased intestinal permeability in patients with Crohn's disease and their relatives. *Ann. Intern. Med.* **105**:883-885.
- Jewell, D. P., and C. Patel. 1985. Immunology of inflammatory bowel disease. *Scand. J. Gastroenterol.* **20**(Suppl. 114):119-126.
- Krawisz, J. E., P. Sharon, and W. F. Stenson. 1984. Quantitative assay for acute intestinal inflammation based on myeloperoxidase activity. *Gastroenterology* **87**:1344-1350.
- Lim, P. L., and D. Rowley. 1985. Intestinal absorption of bacterial antigens in normal adult mice. *Int. Arch. Allergy Appl. Immunol.* **76**:30-36.
- Morehouse, J. L., R. D. Specian, J. J. Stewart, and R. D. Berg. 1986. Translocation of indigenous bacteria from the gastrointestinal tract of mice after oral ricinoleic acid treatment. *Gastroenterology* **91**:673-682.
- Morisaki, I., S. Kimura, M. Torii, et al. 1985. Cell wall preparation consisting of group A carbohydrate and peptidoglycan moieties from *Streptococcus pyogenes* activates murine B lymphocytes. *Immunobiology* **170**:293-304.
- Owen, R. L. 1977. Sequential uptake of horseradish peroxidase by lymphoid follicle epithelium of Peyer's patches in the normal unobstructed mouse intestine. An ultrastructural study. *Gastroenterology* **72**:440-451.
- Owen, R. L., C. L. Allen, and D. P. Stevens. 1981. Phagocytosis of *Giardia muris* by macrophages in Peyer's patch epithelium in mice. *Infect. Immun.* **33**:591-601.
- Owen, R. L., N. F. Pierce, R. T. Apple, and W. C. Cray, Jr. 1986. M cell transport of *Vibrio cholerae* from the intestinal lumen into Peyer's patches: a mechanism for antigen sampling and for microbial transepithelial migration. *J. Infect. Dis.* **153**:1108-1118.
- Park, H., A. R. Zeiger, and H. R. Schumacher. 1984. Detection of soluble peptidoglycan in urine after penicillin administration. *Infect. Immun.* **43**:139-142.
- Reinhardt, M. C. 1984. Macromolecular absorption of food antigens in health and disease. *Ann. Allergy* **53**:597-601.
- Roder, A. A., F. Wensinck, and J. P. Van de Merwe. 1983. Selected bacterial antibodies in Crohn's disease and ulcerative colitis. *Scand. J. Gastroenterol.* **18**:217-223.
- Sartor, R. B. 1986. Animal model of granulomatous enterocolitis induced by bacterial cell wall polymers, p. 55-64. *In* D. Rachmilewitz (ed.), *Inflammatory bowel disease*. Martinus Nijhoff Publishers, Dordrecht, The Netherlands.
- Sartor, R. B., T. M. Bond, K. Y. Compton, and D. R. Cleland. 1987. Intestinal absorption of bacterial cell wall polymers in rats, p. 835-840. *In* J. Mestecky (ed.), *Recent developments in*

- mucosal immunology. Plenum Publishing Corp., New York.
27. Sartor, R. B., W. J. Cromartie, D. W. Powell, and J. H. Schwab. 1985. Granulomatous enterocolitis induced in rats by purified bacterial cell wall fragments. *Gastroenterology* **89**:587-595.
  28. Seidman, E. G., D. G. Hanson, and W. A. Walker. 1986. Increased permeability to polyethylene glycol 4000 in rabbits with experimental colitis. *Gastroenterology* **90**:120-126.
  29. Skogh, T. 1982. Overestimate of <sup>125</sup>I-protein uptake from the adult mouse gut. *Gut* **23**:1077-1080.
  30. Smialowicz, R., and J. H. Schwab. 1977. Cytotoxicity of rat macrophages activated by persistent or biodegradable bacterial cell walls. *Infect. Immun.* **17**:599-606.
  31. Stimpson, S. A., R. R. Brown, S. K. Anderle, D. G. Klapper, R. L. Clark, W. J. Cromartie, and J. H. Schwab. 1986. Arthropathic properties of cell wall polymers from normal flora bacteria. *Infect. Immun.* **51**:240-249.
  32. Stimpson, S. A., R. E. Esser, P. B. Carter, R. B. Sartor, et al. 1987. Lipopolysaccharide induces recurrence of arthritis in rat joints previously injured by peptidoglycan-polysaccharide. *J. Exp. Med.* **165**:1688-1702.
  33. Stimpson, S. A., J. H. Schwab, M. J. Janusz, S. K. Anderle, R. R. Brown, and W. J. Cromartie. 1986. Acute and chronic inflammation induced by peptidoglycan structures and polysaccharide complexes, p. 273-290. *In* H. P. Seidl and K. H. Schleifer (ed.), *Biological properties of peptidoglycan*. Walter deGruyter, Berlin.
  34. Tabaqchali, S., D. P. O'Donoghue, and K. A. Bettelheim. 1978. *Escherichia coli* antibodies in patients with inflammatory bowel disease. *Gut* **19**:108-113.
  35. Tagesson, C., and C. Edling. 1984. Influence of surface-active food additives on the integrity and permeability of rat intestinal mucosa. *Food Chem. Toxicol.* **22**:861-864.
  36. Talbot, V., J. R. Foster, J. Hermon-Taylor, and D. A. W. Grant. 1984. Increased mucosal penetration and transfer to portal blood of luminal horseradish peroxidase after exposure of mucosa of guinea pig small intestine to ethanol and lysolecithin. *Dig. Dis. Sci.* **29**:1015-1022.
  37. Tolo, K., P. Brandtzaeg, and J. Jonsen. 1977. Mucosal penetration of antigen in the presence or absence of serum-derived antibody. An in vitro study of oral and intestinal mucosa. *Immunology* **33**:733-734.
  38. Udall, J. N., K. J. Bloch, L. Fritze, and W. A. Walker. 1981. Binding of exogenous protein fragments to native proteins: possible explanation for the overestimation of uptake of extrinsically labelled macromolecules from the gut. *Immunology* **42**:251-257.
  39. Ulevitch, R. J. 1978. The preparation and characterization of a radiiodinated bacterial lipopolysaccharide. *Immunochemistry* **15**:157-164.
  40. Wahl, S. M., D. A. Hunt, J. B. Allen, R. L. Wilder, L. Paglia, and A. R. Hand. 1986. Bacterial cell wall-induced hepatic granulomas. An in vivo model of T cell-dependent fibrosis. *J. Exp. Med.* **163**:884-902.
  41. Walker, W. A. 1981. Antigen uptake in the gut: immunologic implications. *Immunol. Today* **2**:30-34.
  42. Walker, W. A., and K. J. Isselbacher. 1974. Uptake and transport of macromolecules by the intestine: possible role in clinical disorders. *Gastroenterology* **67**:531-550.
  43. Warshaw, A. L., C. A. Belini, and W. A. Walker. 1977. The intestinal mucosal barrier to intact antigenic protein. Difference between colon and small intestine. *Am. J. Surg.* **133**:55-58.
  44. Warshaw, A. L., W. A. Walker, R. Cornell, and K. J. Isselbacher. 1971. Small intestinal permeability to macromolecules. *Lab. Invest.* **25**:675-684.
  45. Wellmann, W., P. C. Fink, F. Benner, and F. W. Schmidt. 1986. Endotoxaemia in active Crohn's disease. Treatment with whole gut irrigation and 5-aminosalicylic acid. *Gut* **27**:814-820.
  46. Wells, A., G. Pararajasegaram, M. Baldwin, C. Yang, M. Hammer, and A. Fox. 1986. Uveitis and arthritis induced by systemic injection of streptococcal cell walls. *Invest. Ophthalmol. Vis. Sci.* **27**:921-925.
  47. Worthington, B. S., and J. Syrotuck. 1976. Intestinal permeability to large particles in normal and protein-deficient adult rats. *J. Nutr.* **105**:20-32.