

Pulmonary Renal Syndromes—A Review

RICHARD A. MATTHAY, M.D., SUSAN I. BROMBERG, M.D., AND
CHARLES E. PUTMAN, M.D.

*Pulmonary Section, Department of Internal Medicine, Yale University School of
Medicine, New Haven, Connecticut, and the Department of Radiology, Duke
University School of Medicine, Durham, North Carolina*

Received July 30, 1980

Several systemic diseases share clinical, pathologic and radiologic characteristics. This article emphasizes similarities and differences in the clinical and chest radiographic manifestations of six diseases with both pulmonary and renal abnormalities—Goodpasture's syndrome, Wegener's granulomatosis, lymphomatoid granulomatosis, Churg-Strauss syndrome, systemic lupus erythematosus, and scleroderma.

This article reviews and discusses the clinical, pathologic, and radiographic features of a group of systemic diseases which share pulmonary and renal abnormalities. Emphasized are similarities and differences in the clinical and chest radiographic manifestations of Goodpasture's syndrome, Wegener's granulomatosis, lymphomatoid granulomatosis, Churg-Strauss syndrome, systemic lupus erythematosus, and scleroderma. Wegener's granulomatosis, lymphomatoid granulomatosis, and Churg-Strauss syndrome are each considered under one category of diseases with pulmonary/renal pathology, the systemic granulomatous vasculitides. Systemic lupus erythematosus and scleroderma belong to a group of disorders known as the connective tissue diseases. However, all six of these diseases have in common the propensity to present with pulmonary abnormalities which may provide problems in differential diagnosis. It is our purpose to detail the characteristics of these diseases, particularly the pulmonary findings, which aid in diagnosis and management.

GOODPASTURE'S SYNDROME

Goodpasture's syndrome is characterized by pulmonary hemorrhage with hemoptysis, diffuse alveolar filling on the chest radiograph, anemia, and glomerulonephritis (often rapidly progressive) [1-3]. Wilson and Dixon [6] extended this definition to include the presence of antiglomerular basement-membrane (anti-GBM) antibodies, which are found in most patients with Goodpasture's syndrome [6,10,11]. Clinical and experimental studies suggest that the disorder usually is caused by such antibodies reacting with both glomerular and alveolar basement membranes [6,8,9]. While the catalyst is unknown, production of these antibodies is usually self-limited [6], and the syndrome apparently is inactive when the antibody is not detected [6,13].

Clinico-Pathologic Features

Early reports on Goodpasture's syndrome indicated a marked male predominance of 9:1 [1], but more recent studies describe lower male-to-female ratios of 3.5:1 [14]

and 2:1 [3]. Seventy-five percent of patients are between the ages of 17 and 27 years at the onset of the illness [3,15,16], while the remainder range in age up to 75 years [3].

In most cases, the initial symptom is hemoptysis which occurs at some point during the course of the disease in 99 percent of cases [1,3]. Bouts of hemoptysis range in severity from slightly blood-streaked sputum to massive hemorrhage [1]. In about one-fifth of the patients, upper respiratory tract infections of a non-specific (viral) nature precede the appearance of the syndrome [1]. Chills and fever occur acutely with pulmonary hemorrhage but are not otherwise prominent. Substernal chest pain occurs without relation to activity, although it can be aggravated by coughing.

Renal abnormalities may occur before pulmonary symptoms. In the Wilson and Dixon study, 8 of 32 patients initially had renal abnormalities 0.2 to 13 months before pulmonary symptoms [6]. Urinary findings, present on admission in over 80 percent of patients [3], include proteinuria, microscopic hematuria, and, less commonly, pyuria [1,3,6]. In 26 of Wilson and Dixon's patients (81 percent), renal failure requiring dialysis occurred within one to 14 months of onset (mean 3.5 months) [6].

Anemia is universally present early in the disease [1,3]. In Benoit's review [1], initial hemoglobin levels averaged 7.7 g/100 ml (range, 3.8 to 14.5), with the lowest levels usually related to severe pulmonary hemorrhage. The anemia is apparently not hemolytic, although a decreased erythrocyte life span has been demonstrated [1]. Neither hemolysis nor jaundice is present.

Chest Radiographic Findings The radiographic appearance of Goodpasture's syndrome (Figs. 1,2) is closely related to the distribution, volume, and time sequence of pulmonary hemorrhage. Both interstitial and alveolar involvement occur [4]. Confluent densities are seen shortly after hemorrhage and may be indistinguishable from hypervolemia associated with azotemia or from noncardiogenic pulmonary edema of other origin. All these conditions produce rapid alterations in the chest radiograph. Localized air space changes may progress to diffuse opacification within hours, while complete clearing may occur during remission. However, accentuated interstitial markings tend to persist in Goodpasture's syndrome after repeated

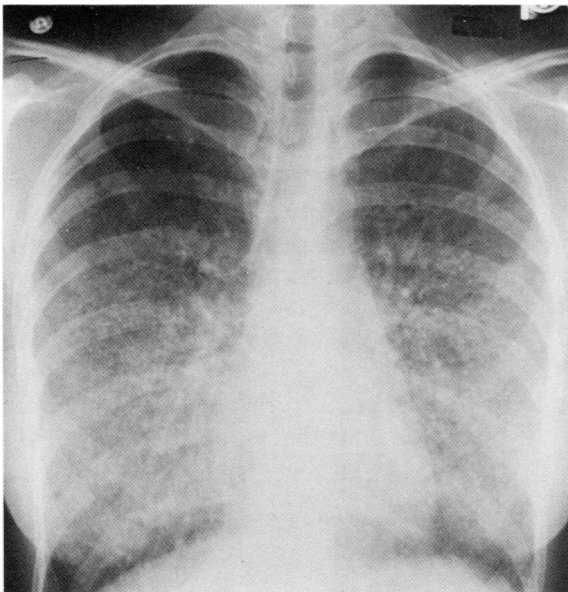


FIG. 1. Goodpasture's Syndrome—Posteroanterior (PA) chest radiograph shows characteristic acinar pattern. Heart, pulmonary vascularity, and pleura are normal. Also note even distribution of the alveolar process.

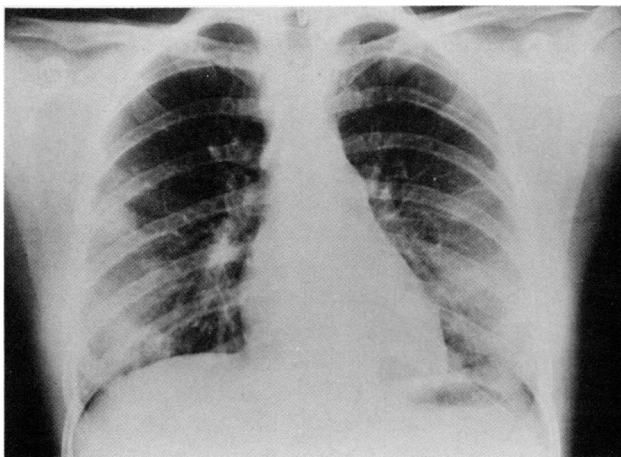


FIG. 2. Goodpasture's Syndrome—PA chest radiograph, unlike Fig. 1, shows predominantly lower lobe peripheral opacification. This may be the predominant pattern in many patients with Goodpasture's syndrome.

episodes of bleeding due to the presence of siderophages in the interstitium [4,17]. If the bleeding is of sufficient duration, permanent reticulonodular infiltrates develop, resembling the appearance of idiopathic pulmonary hemosiderosis [4,18,19,20]. Generally, these changes are diffuse, but they may be localized. The superimposition of fluffy alveolar densities on a reticulonodular background suggests recurrent pulmonary hemorrhage.

In contrast to the pulmonary venous congestion and edema of left ventricular failure, Goodpasture's syndrome demonstrates a predilection for perihilar involvement while Kerley B lines and pleural effusions are not characteristic [4].

Diagnosis and Pathologic Findings Diagnosis of Goodpasture's syndrome depends on presence of the characteristic glomerular lesions and anti-GBM antibodies, together with evidence of lung hemorrhage in patients who typically present with recurrent hemoptysis, dyspnea, and anemia [3,6].

Histologically, the renal abnormality in Goodpasture's patients is an actively proliferating, often necrotizing, crescent-forming type of glomerulonephritis [6]. This is accompanied by variable, probably secondary, tubular alterations and interstitial infiltrative processes.

Electron microscopic examination of glomeruli reveal widespread, irregular thickening of the lamina rara interna [18] together with a poorly defined, mottled increase in electron density along the central portion of the basement membrane in the region of the lamina densa [3,9,11,12]. Thickening of the lamina rara interna, ubiquitous in Goodpasture's syndrome, is seen also in other glomerular diseases such as toxemia of pregnancy [3].

Etiology and Pathogenesis

The presence of anti-GBM antibodies is clearly involved in the glomerulonephritis and probably the pulmonary hemorrhage of Goodpasture's syndrome [6,21,23]. The mechanism mediating this damage, however, is not known although environmental factors are thought to be instrumental in triggering their production [6]. For example, antigens such as the influenzae A2 virus might cause the production of antibodies that cross react with the basement membrane structures [21]. Many patients have a history of preceding viral syndromes, either of the upper respiratory tract or gastrointestinal tract. Infectious agents or chemical substances such as hydrocarbon solvents might uncover or alter some self antigens so that they become

immunogenic [6]. Environmental factors also may work in a non-antigenic way; noxious stimuli (infectious or chemical) might alter the anatomic integrity of the lung and expose basement membrane antigens, which normally are sequestered from the circulation [6].

Therapy and Prognosis

The prognosis for Goodpasture's syndrome is generally poor. Fifty of the 52 patients in Benoit's 1964 review died, 23 of renal failure and 27 of lung hemorrhage [1]. In Wilson and Dixon's study [6], in which the diagnosis was based on the presence of circulating anti-GBM antibodies, 28 of 32 patients developed renal failure and over one-half died within one year of diagnosis.

The most promising therapy includes plasmapheresis and immunosuppressive therapy with cyclophosphamide and prednisone [13,25-29]. Because of the lack of controlled studies, the exact effects of this combined therapy are not clear. Since production of anti-GBM antibodies may be short-lived, plasma exchange should reduce damage to the glomerulus by lowering the levels of circulating antiglomerular basement membrane antibody. Lockwood et al. [13] reported on seven patients treated with plasma exchange, cytotoxic drugs, and corticosteroids. Renal function improved in three who were not already receiving dialysis at the initiation of therapy. Five patients had pulmonary hemorrhage, which appeared to respond to therapy. These investigators reported that although the fall in anti-GBM antibody titer was variable, there was also depletion of fibrinogen and complement. They believed that the reduction of the latter two substances could have been important therapeutically. Swainson et al. [29] noted a rebound increase in anti-GBM antibody levels following periods of plasma exchange. They concluded that plasma exchange was only effective in substantially reducing the circulating amounts of complement or fibrinogen when performed on consecutive days. The rapid rise in concentrations after exchange reflects rapid turnover and distribution from extravascular pools.

In general, plasma exchange may be useful in the early treatment of severe forms of Goodpasture's syndrome by controlling pulmonary hemorrhage and preventing irreversible renal damage from the high anti-GBM antibody levels. However, the removal of anti-GBM antibodies does not lead to recovery of renal function. Furthermore, there is considerable variation in the amount of reduction of anti-GBM levels in the serum produced by serial plasma exchange and immunosuppression. A controlled clinical study is urgently needed to justify the considerable expense of extensive plasma exchange before its wider use can be encouraged.

SYSTEMIC GRANULOMATOUS VASCULITIDES: WEGENER'S GRANULOMATOSIS

Wegener's granulomatosis has a distinctive clinico-pathologic triad of necrotizing granulomatous vasculitis of the upper and lower respiratory tracts, glomerulonephritis, and variable degrees of disseminated small vessel vasculitis [7,30-32]. A localized form of Wegener's limited primarily to the respiratory tract has been reported [7,33] but probably represents an early stage that, if not treated, eventually would involve the kidney and become a generalized Wegener's. However, some patients may have a "forme fruste" of the disease that never disseminates [7].

Clinico-Pathologic Features

Wegener's granulomatosis can occur at any time, but the average age of onset is 40 years. The disease occurs in males twice as frequently as in females [7].

Initially, clinical presentations vary widely among patients, but generally are related to the upper respiratory tract. Typical findings include rhinorrhea, severe sinusitis, and, frequently, nasal mucosal ulcerations and otitis media, usually secondary to blockage of the eustachian tube resulting from upper airway disease [7]. Some patients present with primary middle ear disease, and hearing loss may be the initial complaint [7]. Fever occurs in almost 80 percent of cases, but in approximately one-half, it is secondary to a detectable infection, usually of the paranasal sinuses [30].

Pulmonary symptoms include cough, hemoptysis, and, less frequently, chest discomfort [7,30]. Pulmonary function studies generally show loss of lung volumes with a restrictive ventilatory defect in association with significant parenchymal lesions [2]. More than 50 percent of patients with Wegener's also have an obstructive ventilatory abnormality that cannot be related to cigarette smoking [2]. In patients with obstructive changes, granulomatous lesions that have blocked an airway may be found during fiberoptic bronchoscopy. The presence of these lesions also may be suggested by abnormalities found on flow-volume curves.

Renal disease is the sine qua non of generalized Wegener's granulomatosis. Prior to the use of cytotoxic agents as therapy in this disorder, most patients succumbed to renal disease, with a mean survival of five months from the onset of clinically evident renal involvement [7]. The urinary findings in generalized Wegener's are those of acute glomerulonephritis with hematuria, red blood cells casts, and proteinuria.

Any of the other organ systems involved in Wegener's may also be the focus of initial complaints. Arthralgias frequently are part of the presenting symptomatology, as are other generalized manifestations of systemic inflammatory disease, such as fatigue, malaise, anorexia, and weight loss [7,30].

Wegener's granulomatosis presents a characteristic complex of laboratory findings. The mild anemia of subacute or chronic diseases is seen frequently, as is mild leukocytosis. Thrombocytosis (up to 1,000,000 platelets/mm³) can be present and probably represents an acute reaction [7]. Bentonite flocculation test findings are mildly elevated in about 50 percent of patients, whereas results of antinuclear antibody and lupus erythematosus (LE) cell preparation tests are uniformly negative. Whole complement levels are normal or mildly elevated. Mild hyperglobulinemia, particularly involving the serum immunoglobulin A fraction, occurs commonly [34]. Almost all patients have strikingly elevated erythrocyte sedimentation rates, usually 100 mm/hour or more (Westergren method) [7].

Chest Radiographic Manifestations The pulmonary infiltrates of Wegener's granulomatosis are heterogeneous, and may be any size, shape, or lobar location (Figs. 3-5) [2,7,30-43]. The most characteristic, although not the most common, patterns are solitary (Fig. 5) or multiple nodular densities (Figs. 3,4) or infiltrates, either poorly defined or sharply circumscribed [2,30]. These opacities vary in size from less than 1 cm to greater than 9 cm [30,36,37]. The infiltrates may be unilateral, but usually involve both lungs [37]. Unilocular or multilocular cavitation with irregular walls is common [30,36,37], and occasionally air-fluid levels are found [38]. Some investigators have described these cavities as thick-walled [36], but others [37] maintain that thin-walled cavities are the rule. They suggest that the walls appear thick on plain chest films due to infiltration of the surrounding lung. The infiltrates may be quite transient with one disappearing in one lung field and other appearing in a different location [37].

Atypical radiographic manifestations of Wegener's include focal areas of collapse adjacent to infiltrates [37] and mediastinal lymph node enlargement [38]. The

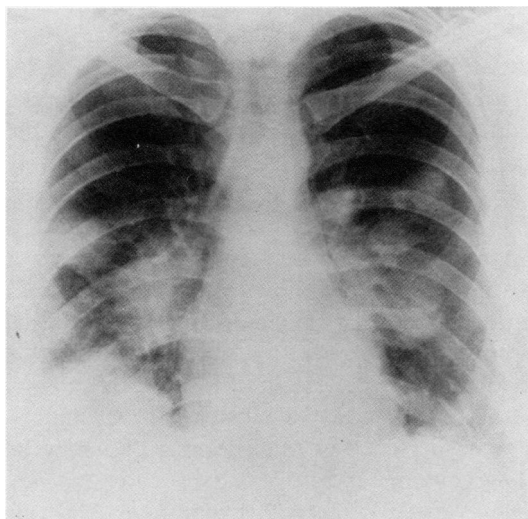


FIG. 3. Wegener's Granulomatosis—PA chest radiograph with multiple, large confluent nodules. No cavitation, adenopathy, or pleural effusion is present.

combination of hilar and mediastinal adenopathy on the chest radiograph should suggest an alternate diagnosis [2]. Other occasional signs include bronchopleural fistula; narrow areas in the larger airways, which may lead to lobar collapse [39]; and pleural thickening and pleural effusions [2,36]. Maguire et al. [39] recently reviewed 31 pathologically proven cases of Wegener's granulomatosis and identified so-called unusual radiographic findings in 16 patients. These included endobronchial disease resulting in atelectasis of either a lobe or a complete lung and pleural disease with thickening or effusion, which was massive in some cases.

Diagnosis and Pathologic Findings An important aspect of Wegener's granulomatosis is its pathologic and clinical similarity to a variety of other disorders characterized by granulomatous inflammation, vasculitis, or both [7,30]. These

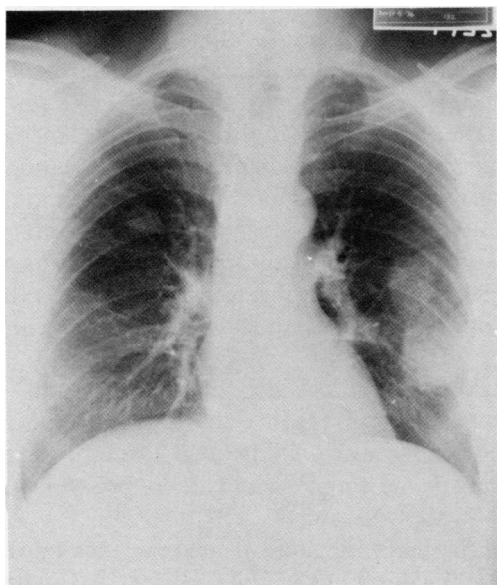


FIG. 4. Wegener's Granulomatosis—PA chest radiograph shows three nodules. There is a suggestion of cavitation in the right upper lung nodule which was confirmed by tomography.

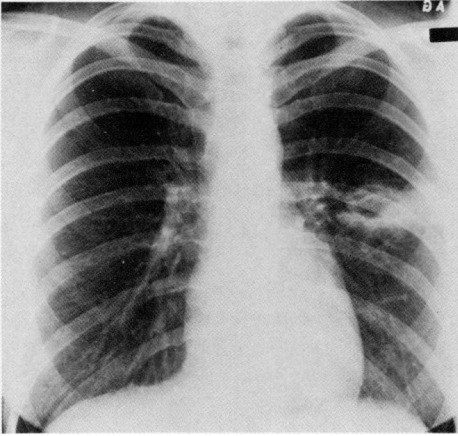


FIG. 5. Wegener's Granulomatosis—PA chest radiograph in patient with hemoptysis. There is a solitary, irregular patchy density in the anterior segment of the left upper lobe. The apparent cavity represents compressed normal lung.

include vasculitic disorders such as polyarteritis nodosa; hypersensitivity vasculitis; the spectrum of connective tissue diseases; granulomatous diseases, such as sarcoidosis and midline granuloma; mixed granulomatous and vasculitis diseases, such as allergic granulomatosis; infectious granulomatous diseases, such as tuberculosis, leprosy, and fungal disease; Goodpasture's syndrome; and a variety of neoplasms accompanied by a granulomatous or vasculitis inflammatory response [7].

Open lung biopsy is the procedure of choice in approaching the pulmonary infiltrates of Wegener's granulomatosis. The outstanding pathologic feature in all cases is the presence of inflammatory masses (.5 to 5 cm) within the parenchyma of one or both lungs [44]. Generally, the masses are few and sharply circumscribed on gross examination. Microscopically, they consist of necrotic areas surrounded by zones of granulation tissue.

The earliest lesion in the kidney is a focal and segmental glomerulitis [7,45]. If not treated properly, the lesions progress to a fulminant, necrotizing, and proliferative glomerulonephritis, and eventually can lead to renal failure. At very early stages, glomerulitis may go undetected because the urinary sediments and renal function may be normal. Therefore, percutaneous renal biopsies are recommended when there is a high index of suspicion of Wegener's, even when the urinary sediments are normal [7]. Renal biopsies not only aid in establishing a diagnosis, but also serve to monitor response to therapy as measured by subsequent biopsies.

Etiology and Pathogenesis

The etiology of Wegener's is unknown, although hypersensitive reaction to an unidentified antigen is strongly indicated [31]. Circulating immune complexes occur during the active process [46], and immune reactants and complex-like deposits have been seen in some renal biopsies of patients with Wegener's granulomatosis and active glomerulonephritis [31,30,45]. The role of these immune complexes in the pathogenesis of the disease is not known.

Therapy and Prognosis

Untreated, Wegener's granulomatosis rapidly pursues a fatal course with a mean survival time of five months in most cases [47,48]. Eighty-two percent of patients die within one year and more than 90 percent within two years. Although corticosteroids increase mean survival to 12.5 months [49], the long-term prognosis is not signifi-

cantly altered by this therapy, especially in patients with clinically apparent renal disease.

The current drug of choice in treating Wegener's granulomatosis is cyclophosphamide [2,7,30,31,34]. This drug produces long-term remission in most patients. The drug is administered orally or, in cases of rapidly progressive disease, intravenously. A clinical reponse is usually seen after one to three weeks of therapy. The dose of cyclophosphamide must be monitored continually and adjusted to keep the white blood cell count above 3,000 cells per mm³ [2,31].

In patients who cannot tolerate cyclophosphamide because of severe leukopenia or hemorrhagic cystitis, or in young women who are not willing to accept the ovarian damage associated with cyclophosphamide, azathioprine is an alternative cytotoxic agent. However, generally experience has shown that azathioprine is not as effective as cyclophosphamide [2,31].

SYSTEMIC GRANULOMATOUS VASCULITIDES: LYMPHOMATOID GRANULOMATOSIS

Lymphomatoid granulomatosis is a systemic disease characterized by an angiocentric, angiodestructive, and lymphoreticular granulomatous vasculitis primarily of the lungs, but also frequently involving the kidneys (45 percent), skin (45 percent), and central nervous system (20 percent) [2,41,42,50,51]. Although any organ system can be involved, the spleen, lymph nodes, and bone marrow usually are spared. This disorder resembles an indolent lymphoma, and, in many instances, it progresses to an atypical disseminated lymphoproliferative disease (Fig. 8) [2,41,50,51].

Clinico-Pathologic Features

The male-to-female ratio is about 2:1, and most patients are in early middle age [41,51]. Lung involvement is a sine qua non of lymphomatoid granulomatosis and usually is manifested as multiple nodular infiltrates of various sizes that tend to cavitate [2,41,50,51]. Most patients present with chest symptoms (cough and shortness of breath) or systemic complaints (fever, weight loss, malaise) or both. Presenting complaints in 142 cases are listed in Table 1 [50].

Most patients have a normal or only slightly reduced hematocrit. In Katzenstein's series [50], the presenting leukocyte count was normal in 50 percent, elevated in 30

TABLE 1
Presenting Complaints in 142 Patients with Lymphomatoid Granulomatosis*

	Total	Percent
Fever	82	57.7
Cough	79	55.6
Malaise	50	35.2
Weight loss	49	34.5
Shortness of breath	41	28.9
Neurological	30	21.1
Chest pain	19	13.4
Arthralgias	9	6.3
Myalgias	4	2.8
Gastrointestinal †	4	2.8
Asymptomatic	4	2.8

*From Katzenstein et al. [50]

†Includes nonspecific gastrointestinal complaints such as nausea and vomiting, diarrhea, and abdominal pain

percent (range, 9,000–38,000), and reduced in 20 percent (range, 1,200–3,900). A relative lymphocytopenia was noted in 33 percent and lymphocytosis in 6 percent. Serum immunoglobulins were normal in 53 percent of cases and nonspecific increases, usually in IgG or IgM, were seen in the remainder [50].

Chest Radiographic Manifestations The chest radiographic manifestations of lymphomatoid granulomatosis (Figs. 6–8) depend in part on the duration of the disease. Lesions may appear and disappear without relation to therapy, as also occurs in Wegener's granulomatosis [2,31,41]. The pulmonary lesions predominate in the lower lung fields peripherally (Figs. 7,8A) and are usually bilateral [41]. Typically, the early lesions present as multiple, bilateral, ill-defined densities [2,50]. Later, they become better defined and resemble nodular metastases of various malignancies (Fig. 8B) [2,41]. The lesions also may coalesce (Fig. 6B), especially in the lung bases, and resemble a mass-like or pneumonic process [2]. Cavitation was seen in 30 percent of the original patients studied by Leibow et al. [51]. Hemorrhage secondary to cavitation was the cause of death in 14 percent of the 40 patients in this study [51]. Hilar adenopathy is unusual in lymphomatoid granulomatosis and occurs only in a few patients whose disease ultimately pursues the course of lymphoma [41]. Pleural effusions may or may not be present (Fig. 7).

Diagnosis and Pathologic Findings The definitive diagnosis of lymphomatoid granulomatosis is made histologically. Plasma cells, lymphocytic cells, and large "atypical" mononuclear cells in various stages of maturity infiltrating perivascular tissue are characteristic [52]. Occlusion by infiltration of the vessels and subsequent tissue necrosis are frequent findings. With peripheral nerve involvement, the infiltrate is seen surrounding the nerve, and spotty demyelination is present. When the skin is involved, the small vessel destruction with a lymphoreticular infiltrate is most often seen surrounding the dermal appendages [52].

This disorder is often confused clinically with Wegener's granulomatosis. However, granulomata are less copious and less distinct, and the vasculitis is remarkable

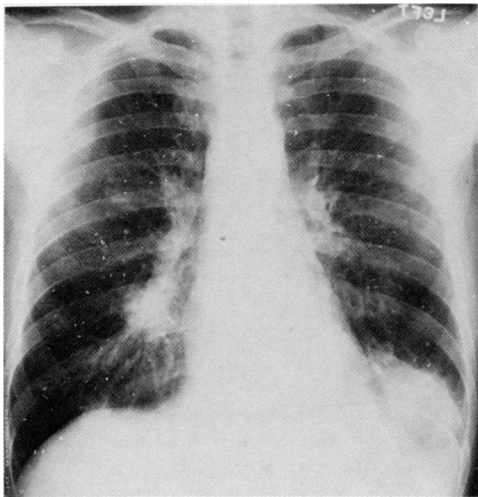


FIG. 6A. Lymphomatoid granulomatosis—PA chest radiograph with irregular nodular-like densities in the right mid lung and also at the base of the left lung. A smaller density is noted in the right upper lung zone.

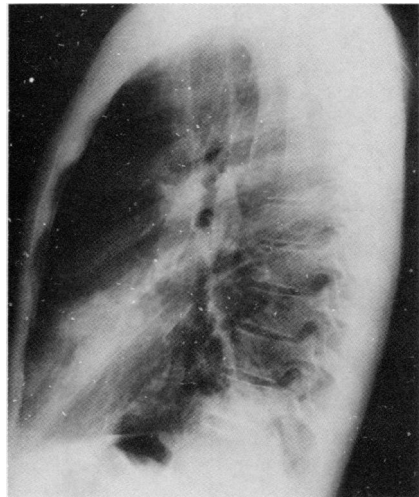


FIG. 6B. A lateral radiograph confirms nodular aspect of the lesions. In the middle lobe, the nodules appear confluent. The hilar structures are normal.

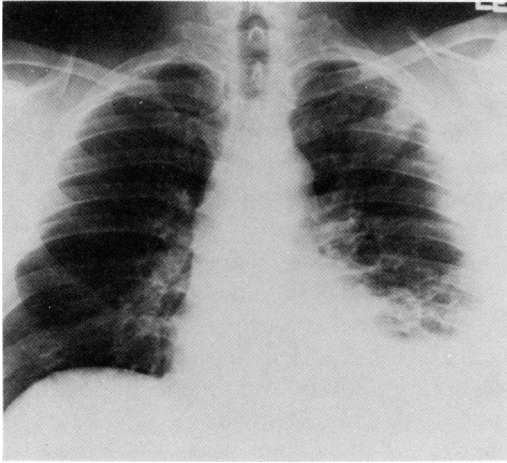


FIG. 7. Lymphomatoid granulomatosis—PA radiograph reveals obscuration of the left hemidiaphragm and linear densities left lower lobe. A lateral decubitus film confirmed a small free effusion. Also note the indistinct mass density left upper lung zone.

in that it is not the characteristic leukocytoclastic or fibrinoid necrotic type seen in Wegener's and other systemic vasculitides [2,31,41]. In contrast, there is an angiotrophic invasion of blood vessels of various sizes with a bizarre cellular infiltrate. Blood supply through the involved vessels is compromised, and infarction and necrosis occur as in other vasculitides.

In addition to its characteristic histopathologic features, lymphomatoid granulomatosis differs from Wegener's in several other ways [2]. Sinus and upper airway

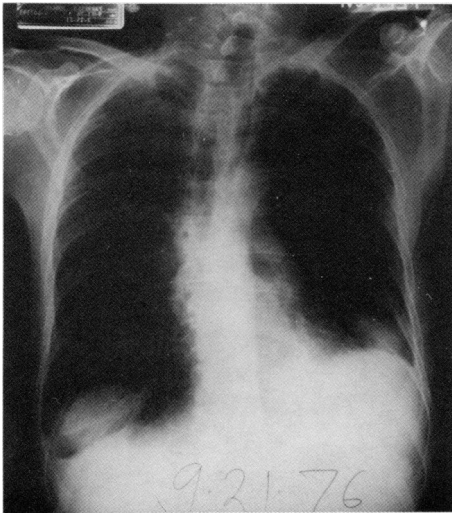


FIG. 8A. Lymphomatoid granulomatosis—PA chest radiograph shows bibasilar large lung nodules. Right open lung biopsy revealed lymphomatoid granulomatosis.

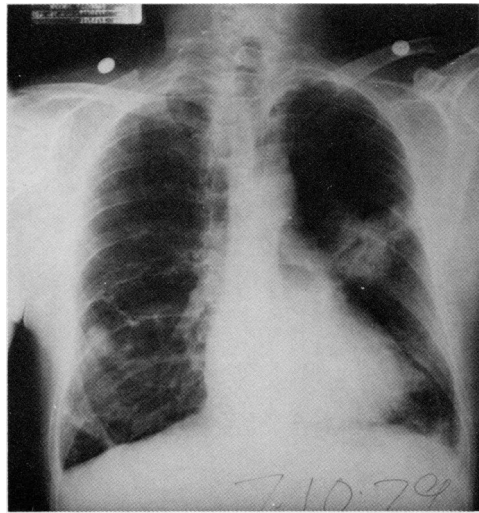


FIG. 8B. PA chest radiograph done almost three years later, after therapy with corticosteroids and chlorambucil, shows clearing of the bibasilar densities and appearance of at least two new lesions, one in the left mid lung zone, the other in the lower one-third of the right lung. The left-sided lesion contains a distinct air bronchogram. Also note the enlarged cardiac silhouette and likely third new lesion at left heart border. Open lung biopsy of the new large left lung mass revealed lymphoma.

involvement is unusual in lymphomatoid granulomatosis. In addition, renal involvement in lymphomatoid granulomatosis is a diffuse nodular infiltrate of the renal parenchyma with a characteristic cellular infiltrate in contrast to the necrotizing glomerulonephritis seen in Wegener's granulomatosis [7,41,47,51]. Leukopenia and anergy before therapy are rare in Wegener's but are seen frequently in lymphomatoid granulomatosis [3,31]. Also, contrary to the condition of patients with Wegener's granulomatosis [30,31,34], the erythrocyte sedimentation rate may be normal in some patients during disease activity [47].

Etiology and Pathogenesis

The etiology of lymphomatoid granulomatosis is unknown. It may be an acquired abnormality of the lymphocyte in a susceptible host, such as Sjogren's syndrome [53]. Evidence for this includes absent delayed hypersensitivity as demonstrated by non-reactivity to skin test antigens and the response of the lung lesions to the corticosteroids [52]. As in Sjogren's syndrome, lymphomatoid granulomatosis can terminate in a neoplastic disease [51,52].

Other disease, such as lymphoma and mycosis fungoides, can have years of symptoms with a biopsy showing nonspecific lymphoid and plasma cell infiltrates before it assumes the usual features of a neoplastic disease. Renal homotransplantation can be followed by lymphoreticular proliferation with involvement of the central nervous system [54–56]. Antigenic exposure in an immunosuppressed host may alter the cell membrane and produce an auto-immune disease [51,57–63]. With continued immunosuppression, neoplastic disease may result [64,65].

Therapy and Prognosis

Untreated, lymphomatoid granulomatosis is usually rapidly progressive and fatal [31]. Death is often related to pulmonary or central nervous system complications [51]. Nevertheless, preliminary reports indicate that a relatively high rate of long-term remissions can be achieved if patients are treated early with cyclophosphamide and corticosteroids in the same regimen as used for Wegener's granulomatosis [66].

SYSTEMIC GRANULOMATOUS VASCULITIDES: ALLERGIC ANGIITIS AND GRANULOMATOSIS (CHURG-STRAUSS SYNDROME)

Churg and Strauss [67] in 1951, and Rose and Spencer [68] in 1957, described an uncommon granulomatous inflammation and vascular necrosis primarily involving the heart, lungs, skin, nervous system, and kidneys. This entity, commonly referred to as allergic angiitis and granulomatosis, occurs primarily in patients with an allergic background or asthma or both.

Clinico-Pathologic Features

In 30 cases of the Churg-Strauss syndrome reported by Chumbley [69], 21 were men and nine were women. Ages ranged from 15 to 69 years; the average was 47. The mean duration of asthma was eight years. It began at the same time as the manifestations of systemic vasculitis in six cases, but preceded it in all others. Allergic rhinitis occurred in 21 of the 30 cases (70 percent) [69].

Most patients have a fever at some point in their clinical course [67,69]. Anemia and weight loss are common, as is leukocytosis and elevation of the erythrocyte sedimentation rate [69]. Peripheral blood eosinophilia is seen at some time in each

case [69]. The degree of eosinophilia and erythrocyte sedimentation rate elevation are good indicators of disease activity [69].

Chest Radiographic Manifestations Chest radiographic abnormalities range from transient patchy densities to massive bilateral nodular infiltrates without cavitation to diffuse interstitial disease (Fig. 9) [69–71]. New lesions may appear while older ones are disappearing; some remain stable after an initial period of improvement, while others stabilize without improvement [71]. Complete radiographic regression of a widespread active pulmonary process is sometimes seen with corticosteroids [72].

Diagnosis and Pathologic Findings Histologically, the lungs typically show fibrinoid, necrotizing, and eosinophilic granulomatous lesions which frequently involve the pulmonary arteries [71]. In about one-half of their cases, Churg and Strauss [67] found parenchymatous lesions in the form of an extensive pneumonic process involving septa and alveoli. In the acute stage, exudate in the lungs had a predominance of eosinophilic leukocytes mixed with giant cells. Histologic evidence of bronchial asthma (hyalinization of basement membrane, increased mucus secretion, and eosinophilic infiltration of the bronchial walls) was present in most cases, but generally was not very marked [67].

Allergic granulomatosis (Churg-Strauss syndrome) strongly resembles classic polyarteritis nodosa with some obvious distinguishing features. Churg-Strauss syndrome almost invariably is associated with an allergic diathesis, particularly severe asthma [31]. Reports of the incidence of asthma with polyarteritis nodosa have ranged from 4 percent to as high as 54 percent [69]. In general, unlike classic polyarteritis nodosa in which pulmonary abnormalities are rare, lung involvement is a sine qua non of the Churg-Strauss syndrome. Also, this syndrome is characterized by high levels of peripheral eosinophilia (usually higher than 1,500 per mm^3), eosinophilic tissue infiltration and granulomatous reactivity [31,67–69]. In contrast, the predominant cellular infiltrate in polyarteritis nodosa is the neutrophilic leukocyte [69]. In addition to the fibrinoid necrosis of small and medium-sized muscular arteries that is the hallmark of classic polyarteritis nodosa, a substantial degree of

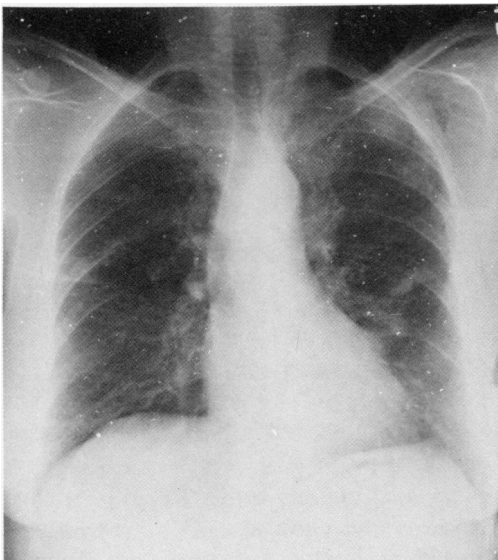


FIG. 9. Churg-Strauss syndrome—PA chest radiograph with scattered subsegmental infiltrates in both lungs. The subcutaneous air in left superior-lateral chest is secondary to closed lung biopsy. There is no evidence of hilar adenopathy or pleural disease.

involvement of small vessels, such as capillaries and venules, is present in Churg-Strauss syndrome [31].

The "overlap syndrome" of the systemic vasculitides combines many features that are characteristic of classic polyarteritis nodosa, other systemic vasculitides of the small and medium-sized vessels, such as allergic angiitis and granulomatosis (Churg-Strauss syndrome), and the small-vessel hypersensitivity vasculitides [2,31]. Large and small arteries, as well as capillaries and venules, may be involved in the vasculitis process. One patient may have features that would be considered characteristic, or even pathognomonic, of either classic polyarteritis nodosa or allergic granulomatosis. The "overlap syndrome" is a multisystem disease with the associated protean clinical manifestations. The same patient may have small-vessel involvement (arterioles, capillaries, and venules), as well as the classic small-and-medium-sized muscular artery involvement with characteristic angiographically demonstrable small aneurysms. A history of allergy, peripheral eosinophilia, eosinophilic tissue infiltration [2], granulomatous reactions, and lung involvement described for Churg-Strauss syndrome may all be seen in the same patient, or one or more of these may be seen to the exclusion of the others [31]. This syndrome is the most difficult to classify.

Therapy and Prognosis

Well controlled experience with therapy for the Churg-Strauss syndrome is lacking. Chumbley and co-workers treated 27 of their 30 patients with prednisone [69]; most received 40 to 60 mg daily, others 100 to 120 mg daily. Fifteen of these patients died, three within a year after symptoms of vasculitis appeared [69]. The interval from onset of signs and symptoms of vasculitis to death ranged from 6 months to 15 years, average 4.6 years. Cyclophosphamide and azathioprine therapy have theoretical rationale since they are effective in treating another necrotizing vasculitis, Wegener's granulomatosis. However, experience with these agents is minimal [69].

CONNECTIVE TISSUE DISEASES

The connective tissue (collagen vascular) diseases are a heterogeneous group of chronic inflammatory and immunologically mediated disorders. They share certain clinical characteristics including inflammation of joints, serosal membranes, connective tissue, and blood vessels in various organs [2]. The lung is particularly vulnerable to this group of diseases because of its abundant vasculature and connective tissue [2]. Two of the classic collagen vascular diseases, systemic lupus erythematosus (SLE) and scleroderma, frequently involve both the lungs and the kidneys.

SYSTEMIC LUPUS ERYTHEMATOSUS

Systemic lupus erythematosus is a multisystem disease associated with auto-immune antibodies and circulating immune complexes. It is characterized by widespread inflammatory changes in connective tissues, vessels, and serosal surfaces. In contrast to rheumatoid arthritis (RA), another connective tissue disease, renal involvement is common in SLE, and, together with central nervous system disease and infections, often determines survival of these patients [2].

Although infections are the most common cause of infiltrates in the lungs of patients with SLE, many patients develop infiltrates apparently independent of infection [2,73-90]. In fact, the lungs and pleura together are affected more frequently in SLE than in the other connective tissue diseases, the incidence varying in reported series from 50 to 70 percent [2,73,90-96].

Clinico-Pathologic Features

Pathologically, 90 to 100 percent of patients with SLE have some microscopic renal abnormality. The nephrotic syndrome and uremia are the clinical features. With use of the light microscope, patterns of minimal change, focal proliferative glomerular lesions (33 percent), membranous glomerulopathy (15 percent), or diffuse proliferative glomerulonephritis (50 percent) may be observed. Immunofluorescence findings are variable, but nodular deposits of various immunoglobulins, complement components, fibrin, and DNA may be seen in mesangium and capillary loops. The prognosis of SLE is considerably worsened with increasing degrees of renal involvement. Corticosteroids are useful in controlling the extrarenal manifestations of the disease but cytotoxic drugs and anticoagulants are sometimes necessary to control severe renal disease.

The clinical manifestations of pleuropulmonary involvement vary but usually include cough with or without sputum, dyspnea, and pleuritis [2,73]. Pleural disease is more frequently painful in SLE than RA, and is often associated with fever [2]. Rarely, patients present with mild or overwhelming hemoptysis [79,97-99], and pulmonary involvement may be the initial feature of SLE [73,77], as well as one associated with an exacerbation of previously recognized disease [2].

Hunninghake and Fauci have classified the chest radiographic features of primary pleuropulmonary disease in SLE under six separate categories [2]. Frequently, more than one of these entities is present in an individual patient. Figures 10 and 11 provide typical examples of chest radiographic abnormalities.

(1) *Pleuritis and/or Effusion* Pleuritis and/or effusion are the most common pleuropulmonary abnormalities in SLE and are probably present at some stage of the disease in at least 50 to 75 percent of patients (Fig. 10) [96]. Frequently painful, pleural disease is often associated with exacerbation of the underlying disorder. Winslow and co-workers [96] stressed the importance of pleuritis as an early manifestation in the diagnosis of SLE. Pleural effusion occurred in 42 of their 57 cases. Although usually bilateral and small, these pleural effusions may be massive [2,91,93,100]. The pleural fluid in SLE is usually an exudate with protein in excess of 3 gm per 100 ml. As in RA, concentrations of complement are generally depressed in the effusion [2]. However, in contrast to RA, pleural fluid glucose concentrations are not markedly depressed [101], and the total leukocyte count is usually less than in RA

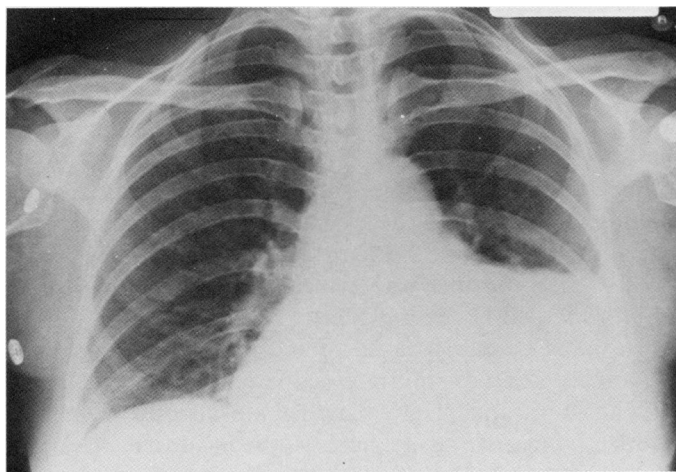


FIG. 10. Systemic lupus erythematosus—A PA chest radiograph reveals prominence of the cardiac shadow; echocardiography confirmed a moderate-sized pericardial effusion. Also note the large left pleural effusion.

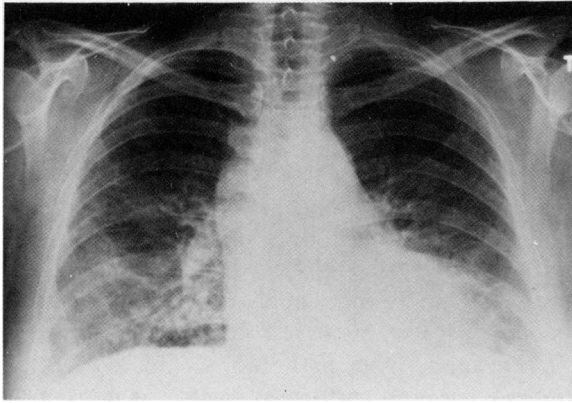


FIG. 11A. Systemic lupus erythematosus—A PA chest radiograph shows reticulonodular densities in both lower lung zones. An open lung biopsy consistent with “lupus pneumonitis”; no evidence of infection was found.

[102]. In addition, lupus erythematosus cells are occasionally found [2,103]. When pleural effusions are present in patients with SLE, it is prudent to obtain samples of this fluid for diagnostic studies because there may be co-existing infection. When another underlying process has been excluded, the patient should be started on corticosteroid therapy, or the current dosage of corticosteroids should be increased [2].

(2) *Atelectasis* Atelectasis, usually in the bases and situated peripherally, is commonly seen on chest radiographs in patients with SLE [73,75–90]. The basilar infiltrates frequently are associated with pleuritis, effusion, and/or diaphragmatic dysfunction [104]. The development of basilar atelectasis is analogous to that occurring after abdominal surgery; many of these patients have prolonged pleural pain and splinting [2]. In numerous cases dyspnea and pulmonary function abnormalities are disproportionate to the chest radiographic changes.

(3) *Uremic Pulmonary Edema* Uremic pulmonary edema is readily established by the presence of a markedly increased concentration of blood urea nitrogen. The chest radiographic findings include fluffy acinar infiltrates that are more pronounced in the perihilar areas and the lower lung zones [2]. Pleural effusion may or may not be present.

(4) *Acute Lupus Pneumonitis* Acute lupus pneumonitis is a well-recognized manifestation of SLE [73,82]. The diagnosis, however, is one of exclusion since this entity may be mimicked by atelectasis, uremic pulmonary edema, and secondary

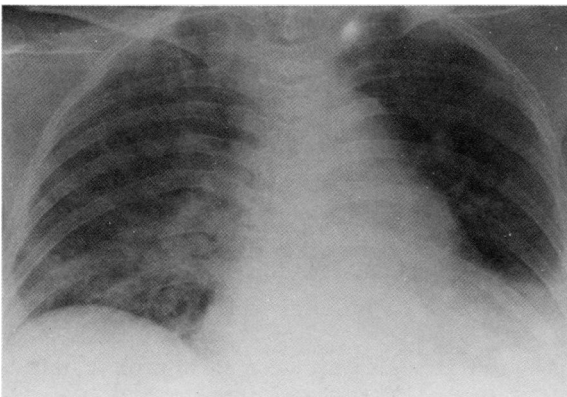


FIG. 11B. An AP chest radiograph taken two weeks later during corticosteroid therapy shows further extension of the parenchymal changes and a probable left pleural effusion. At post-mortem, focal areas of hemorrhage and cytomegalic virus were identified.

infections [2]. These lesions usually appear on chest radiographs as poorly defined areas of increased density or extensive unilateral or bilateral acinar infiltrates (Figs. 11 A,B) [73,77-79,82]. Associated findings include cardiomegaly and pleuritis with or without effusion. Patients with acute lupus pneumonitis characteristically are extremely ill with severe dyspnea, a nonproductive cough, temperature of 100-104°F., tachypnea, and hypoxia [72,82]. There is no evidence of infection and antimicrobial drugs are ineffective. Although most of these patients respond dramatically to corticosteroids alone, some have improved only after the addition of cytotoxic agents such as azathioprine [73,77,79]. Despite adequate therapy and clinical improvement of the acute disease, many individuals experience recurrent episodes of pneumonitis and frequently have residual restrictive lung disease of varying severity [81,82,85,105-107]. The underlying pathology in this disorder is unclear because most histologic studies have been performed either postmortem or after therapy with corticosteroids. Histologic alterations include acute vasculitis, hemorrhage, interstitial pneumonitis, and other nonspecific changes [73,78,108,109].

(5) *Diffuse Interstitial Lung Disease* Diffuse interstitial lung disease [63] is significantly less common than the other pleuropulmonary abnormalities of SLE. Eisenberg and co-workers [86] reported 18 SLE patients whose chest radiographs demonstrated diffuse reticulonodular, interstitial infiltrates which were located predominantly in the lower lung zones. These investigators noted that the frequency of these lesions in their outpatient clinic was less than 3 percent [86]. Pulmonary symptoms were dyspnea, a non-productive cough, and pleuritic chest pain. Physical findings included poor diaphragmatic movement and basilar rales. Clubbing was not a feature in these patients. Pulmonary function studies showed a restrictive ventilatory defect with loss of volume, decreased diffusing capacity for carbon monoxide, and hypoxia. Some of these patients responded favorably to corticosteroids [86].

(6) *Diaphragmatic Dysfunction* Diaphragmatic dysfunction with loss of lung volume only recently has been described as an SLE abnormality [2,104]. However, elevated diaphragms with "sluggish" movement and loss of lung volume on chest radiographs have been noted in previous studies [81,105,110]. Although fixation of the diaphragms by pleural adhesions was not ruled out conclusively in these studies, the etiology of this disorder is now believed to be diffuse myopathy affecting the diaphragmatic muscles. In addition to decreased lung volumes and diffusing capacity, these patients generally have reduced values for lung elastic recoil pressures at total lung capacity and decreased maximal transdiaphragmatic pressures [2]. An interesting clinical feature of this disorder is dyspnea in the supine position, a symptom associated with diaphragmatic paralysis [2,111]. Although the natural history of diaphragmatic dysfunction is not entirely clear, the restrictive ventilatory defect is reported to have remained static during periods of four to six years [104].

Therapy and Prognosis

As noted, pleuritis, acute lupus pneumonitis, and interstitial lung disease all warrant therapy with corticosteroids [2,73,77,79,86]. Although no controlled clinical trials are available, generally the response to this therapy is favorable [2,73].

At least 50 percent of the pleuropulmonary abnormalities in SLE are secondary to an infectious process [2,82]. Because infections and renal disease are an important cause of death in such cases, it is critical to obtain appropriate cultures and to perform histopathologic studies.

Pleural effusions and pulmonary infiltrates also are seen in approximately 50 percent of cases of *drug-induced*, SLE-like syndromes [2,112-117]. In fact, the

incidence of pleuropulmonary abnormalities in the drug-induced disorder is second only to that of diffuse arthralgias and myalgias, which occur in 75 to 90 percent of patients with this disease. In contrast to cases of idiopathic SLE, once the nature of this disorder is recognized and the offending agent is discontinued, the prognosis, with few exceptions [118], is excellent [2].

PROGRESSIVE SYSTEMIC SCLEROSIS (SCLERODERMA)

Progressive systemic sclerosis [2,119–146] is a multisystem disease of unknown etiology characterized by varying degrees of vascular change and fibrosis and inflammation of skin and internal organs. The skin, gastrointestinal tract, musculoskeletal system, kidneys, heart, and lungs are affected frequently [2,119,120]. Although the cutaneous features may dominate the clinical picture, it is the visceral involvement that determines survival.

Among the visceral organs involved in scleroderma, pulmonary disease is second only to esophageal involvement [119]. The true incidence of pulmonary involvement is difficult to determine; however, chest radiographic abnormalities have been described in up to 25 percent of cases [119–121]. Pulmonary symptoms occur at some time during the course of the illness in 50 percent of patients [119–121]. In one series utilizing pulmonary function tests, abnormalities were present in 21 of 22 patients [119]. Interstitial fibrosis is found at postmortem examination in nearly all cases [120,126–136]. In one postmortem study of 196 cases [120], pulmonary fibrosis was found in 77 percent, pulmonary vascular disease in 30 percent, and pleural disease in 32 percent.

Clinico-Pathologic Features

The majority of patients are affected in their fourth through sixth decades, and this disease occurs three times more frequently in females than in males [119,120]. The most prominent symptoms of pulmonary involvement are dyspnea and, less commonly, a cough, which may be slightly productive [119,120]. Frequently there are fine basilar rales and limited expansion of the chest [119]. Signs of cor pulmonale may appear as a result of pulmonary vascular and interstitial disease. Renal involvement may be extensive, and complications of renal disease ultimately may cause the demise of the patient. Raynaud's phenomenon, often with trophic finger changes, occurs in 80 to 90 percent of patients and may precede other systemic involvement by years [122,123]. Initial laboratory findings may be nonspecific. Fifty percent of patients have hyperglobulinemia, and positive antinuclear antibodies occur in 50 to 80 percent, often in a nucleolar or speckled pattern [124].

Sackner and co-workers [121] noted increased pulmonary vascular resistance in all patients who underwent cardiac catheterization. In about one-half of these patients, the increased pulmonary vascular resistance was slight and did not produce clinical or radiographic signs of right ventricular hypertrophy. In the remainder, pulmonary hypertension was accompanied clinically by signs of right ventricular hypertrophy and right ventricular failure [121,127].

Pulmonary function abnormalities include a restrictive pattern with reduction of vital capacity [119–121] and reduced lung compliance. A reduced diffusing capacity for carbon monoxide is often the earliest abnormality noted and may be present prior to recognized chest radiographic abnormalities [126]. Recently, Guttadauria and colleagues [137] noted that 19 of 45 patients (42 percent) with scleroderma had evidence of small airways disease on pulmonary function tests.

Chest Radiographic Findings The most common abnormality on the chest

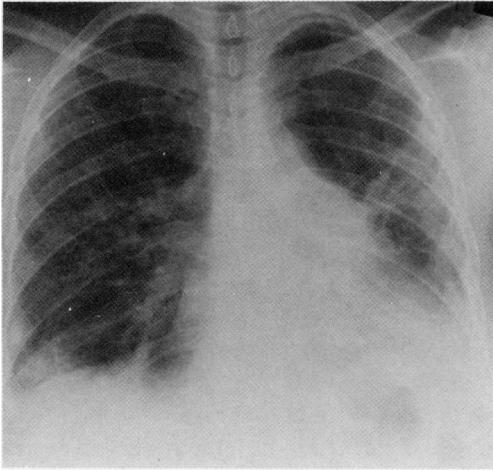


FIG. 12. Scleroderma—A PA chest radiograph reveals decreased lung volumes, most pronounced on the left; pleuro-pericardial adhesions, and bibasilar interstitial disease. The main pulmonary artery segment is prominent, and pulmonary artery pressure measurements were elevated.

radiograph is an interstitial reticular pattern (Fig. 12) particularly affecting the lung bases [119]. These basilar changes are due mainly to the recurrent aspiration pneumonia that occurs and in part to the primary disease process. As the disease progresses, the pulmonary infiltration becomes more dense, with subsequent honeycombing and cyst formation. The cysts are most often subpleural in the basal and paravertebral areas and are usually bilateral. Although they tend to be small (5 mm or less in diameter), large cysts may occur and rupture, which produces a pneumothorax [2,119,138]. Other findings include micronodulation, increased vascular markings, and pulmonary edema [2,120]. Disseminated pulmonary calcification or calcification of the soft tissue of the thorax may be seen on chest radiograph. The latter may also demonstrate the presence of pleural thickening, pleural effusion, and signs of pulmonary hypertension secondary to sclerodermatous lung disease (Fig. 12) [119,120]. Disturbance of esophageal motility may result in retention of food and recurrent aspiration pneumonia.

Pathologic Findings Pathologic changes in the lungs frequently occur with or without clinical abnormalities [120,126,139–141]. In an autopsy study, Weaver and co-workers [141] found pulmonary abnormalities in all 28 cases of scleroderma. The most prominent finding was a progressive and nonspecific bilateral interstitial fibrosis of the lower lobe with bronchiolectasis and cyst formation. Marked intimal thickening by loose myxomatous connective tissue occurred in small pulmonary arteries and arterioles. Norton and Nardi emphasized that involvement of the arterioles and capillary bed in many tissues, particularly in the lungs and kidneys, is the basis of scleroderma [139]. They concluded that scleroderma must be regarded as a vascular disease. It is clear that the pulmonary vascular lesions are not merely an extension of interstitial fibrosis, since many scleroderma lungs have areas of severe interstitial fibrosis without arterial lesions, as well as areas of vascular changes without interstitial disease [140]. Other thoracic pathology in patients with scleroderma includes pleural thickening or effusion, cardiomegaly, vascular congestion, pulmonary edema, enlarged pulmonary arteries, and pneumonitis [119].

Therapy and Prognosis

Unfortunately, no effective therapy has been found for cases of scleroderma [129,146]. There is no evidence that corticosteroids or cytotoxic agents alter outcome

TABLE 2
Differential Diagnosis of Pulmonary Renal Syndromes: Clinical Features

Clinical Data	Goodpasture's Syndrome	Wegener's Granulomatosis	Lymphomatoid Granulomatosis	Churg-Strauss Syndrome	Systemic Lupus Erythematosus	Scleroderma
Sex (M:F)	3.5:1	2:1	2:1	2:1	1:4	1:3
Peak age (yr)	17-27	30-50	40-50	40-50	20-40	30-50
Symptoms and signs:						
Hemoptysis	Predominant symptom (99%)	Frequent	Not a major feature	Rare	Rare	Rare
Rhinorrhea/sinusitis	Not a feature	Typical feature	Rare	Common (70%)	Rare	Not a feature
Wheezing	Not a feature	Not a feature	Not a feature	Usual	Not a feature	Not a feature
Arthritis/arthralgia	Rare	Frequent	May occur	Unusual	Frequent	Frequent
Raynaud's phenomenon	Absent	Absent	Absent	Absent	Often present	Present in over 95%
Chills and/or fever	Frequent	Usual (80%)	Frequent	Frequent	Usual on presentation (90%)	Not a feature
Cor pulmonale	Uncommon	Uncommon	Uncommon	Uncommon	Uncommon	Frequent in advanced disease

TABLE 3
Differential Diagnosis of Pulmonary Renal Syndromes: Laboratory and Pathologic Features

	Goodpasture's Syndrome	Wegener's Granulomatosis	Lymphomatoid Granulomatosis	Churg-Strauss Syndrome	Systemic Lupus Erythematosus	Scleroderma
Anemia	Almost invariably present (<i>frequently severe</i>)	Usual (mild)	Usual (mild)	Usual (mild)	Usual (mild to moderate)	Present late in disease course
Leukocytosis	Not uncommon	Usual (mild)	Common (30%); leukopenia (20%)	Common	Unusual; leukopenia (17%)	Uncommon
Eosinophilia	Unusual	Unusual	Unusual	Special disease feature	Unusual	Unusual
Erythrocyte sedimentation rate	Elevated	Strikingly elevated	May be normal during disease activity	Elevated	Elevated	Frequently normal
Renal abnormalities on presentation	Usual	Usual	Often present	Often present (30%)	Often present (50%)	May be present, especially with rapidly progressive disease
Anti-nuclear factor	Negative	Negative	Negative	Negative	Almost invariably positive	Positive in 50-60% (speckled or nucleolar pattern)
LE cell preparation	Negative	Negative	Negative	Negative	Positive	Negative
Serum complement	Normal	Normal or slightly elevated	Not widely evaluated	Not widely evaluated	Low during active disease (70%)	Usually normal

Circulating anti-glomerular basement membrane antibodies	Usual	Absent	Absent	Absent	Absent	Absent
<i>Pulmonary function abnormalities:</i>						
restrictive ventilatory defect	Present; may be severe in advanced disease	Present with significant lung parenchymal lesions	Present with significant lung parenchymal lesions	Frequent	Invariable with acute or chronic lupus lung disease	Invariable, especially in advanced disease
obstructive ventilatory defect	May be present	Present in over 50% of cases	Frequent	Major feature	Frequent	Frequent
decreased diffusing capacity for carbon monoxide	Frequent	Frequent	Frequent	May occur	Major early finding	Major early finding
Pathology	<i>Lung:</i> pulmonary hemorrhage <i>Kidney:</i> proliferative, crescent forming glomerulonephritis	<i>Lung:</i> masses with necrotizing glomerulonephritis <i>Kidney:</i> focal segmental glomerulonephritis progressing to necrotizing and proliferative glomerulonephritis	<i>Lung and kidney:</i> angiotrophic non-necrotic vasculitis	<i>Lung and kidney:</i> fibrinoid necrotizing and eosinophilic granulomatous lesions of small and medium-sized arteries	<i>Lung:</i> organizing and fibrosing interstitial pneumonia, GLMN <i>Kidney:</i> focal, nephritis, diffuse proliferative nephritis, mesangial nephritis, interstitial nephritis, membranous nephritis	<i>Lung:</i> diffuse alveolar, interstitial, and peribronchial fibrosis <i>Kidney:</i> intimal hyperplasia of interlobular arteries, fibrinoid necrosis of afferent arterioles, thickening of glomerular basement membrane cortical infarcts

TABLE 4
Differential Diagnosis of Chest Radiographic Findings in Pulmonary Renal Syndromes

Chest Radiographic Characteristics	Good-pasture's Syndrome	Wegener's Granulomatosis	Lymphomatoid Granulomatosis	Churg-Strauss Syndrome	Systemic Lupus Erythematosus	Scleroderma
Alveolar Filling pattern	+++	++	+	++	++	+
Interstitial infiltrates	++	++	++	++	++	+++
Large nodular lesions	0	++	+++	0	0	0
Cavitary lesions	0	++	++	0	0	0
Hilar adenopathy	0	+	+	0	+	0
Mediastinal adenopathy	0	0	+	0	+	0
Pleural effusion	0	+	++	0	+++	+
Atelectasis	+	++	++	+	++	++
Pulmonary hypertension	0	+	0	+	+	++
Cardiac enlargement	++	++	+	0	++	++

+++ Predominant finding

++ Frequently present

+ Rarely present

0 Not described

in this disease. Prognosis is unfavorable, and survival in scleroderma appears to depend primarily on the degree of involvement of the heart, kidneys, and lungs [119,120,125].

DIFFERENTIAL DIAGNOSIS OF THE PULMONARY RENAL SYNDROMES

Distinguishing features of the individual pulmonary renal syndromes are outlined in Tables 2,3,4 and 5. In general, lung or renal biopsy is required to distinguish most

TABLE 5
Differential Diagnosis of Pulmonary Renal Syndromes: Therapeutic Implications

	Good-pasture's Syndrome	Wegener's Granulomatosis	Lymphomatoid Granulomatosis	Churg-Strauss Syndrome	Systemic Lupus Erythematosus	Scleroderma
Corticosteroids	May be useful temporarily	May be useful	May be useful	Useful	Useful	Not useful
Cytotoxic agents	May be useful	Very useful (Cytosan treatment of choice)	May be useful	Unproven benefit	May be useful	Not useful
Plasmaphoresis	May be transiently helpful	Not useful	Not useful	Not useful	Not proven useful	Not useful
Bronchodilators	Limited usefulness	Limited usefulness	Limited usefulness	May be useful	Not useful	Not useful

of the pulmonary renal syndromes from each other. However, in some cases the diagnosis may be evident without tissue confirmation. In patients with skin changes characteristic of scleroderma biopsy may not be required. Similarly, patients with Wegener's granulomatosis who present with hemoptysis, hematuria, multinodular and/or cavitating lung lesions, and nasal or sinus lesions are distinguishable from patients with Goodpasture's syndrome. The latter generally do not have cavitating, large nodular lung lesions, and nasal or sinus lesions (Tables 2,3).

A patient with frank hemoptysis, hematuria with renal failure, and a diffuse, bilateral alveolar filling process is most likely to have Goodpasture's syndrome. Rarely, SLE is associated with this clinical constellation, including hemoptysis. However, the LE cell preparation and/or antinuclear factor are positive in SLE but negative generally in Goodpasture's syndrome (Tables 2,3,4).

Tissue is required in most cases to distinguish lymphomatoid granulomatosis from Wegener's granulomatosis. However, Churg-Strauss syndrome can be differentiated from the other five pulmonary renal syndromes by the presence of peripheral blood eosinophilia and wheezing (Tables 3,4).

REFERENCES

1. Benoit FL, Rulon DB, Theil GB, et al: Goodpasture's syndrome. *Am J Med* 37:424-444, 1964
2. Hunninghake GW, Fauci AS: Pulmonary involvement in the collagen vascular diseases. *Am Rev Respir Dis* 119:471-503, 1979
3. Teague CA, Doak PB, Simpson IJ, et al: Goodpasture's syndrome: an analysis of 29 cases. *Kidney Int* 13:492-504, 1978
4. Schwartz EE, Teplick JG, Onesti G, et al: Pulmonary hemorrhage in renal disease: Goodpasture's syndrome and other causes. *Radiology* 122:39-46, 1977
5. Goodpasture EW: The significance of certain pulmonary lesions in relation to the etiology of influenza. *Am J Med Sci* 158:863-870, 1919
6. Wilson CB, Dixon FJ: Antiglomerular basement membrane antibody induced glomerulonephritis. *Kidney Int* 3:74-89, 1973
7. Fauci AS, Wolf SM: Wegener's granulomatosis and related diseases. *Disease-A-Month* 23:1-36, 1977
8. Lerner R, Glasscock RJ, Dixon FJ: The role of anti-glomerular basement membrane antibody in the pathogenesis of human glomerulonephritis. *J Exp Med* 126:989-1004, 1967
9. Poskitt TR: Immunologic and electron microscopic studies in Goodpasture's syndrome. *Am J Med* 49:250-257, 1970
10. Wilson DB, Dixon FJ: Diagnosis of immunopathologic renal disease (editorial). *Kidney Int* 5:389-401, 1974
11. McPhaul JJ Jr, Dixon FJ: The presence of antiglomerular basement membrane antibodies in peripheral blood. *J Immunol* 103:1168-1175, 1969
12. Matthew TH, Hobbs JB, Kalowski S, et al: Goodpasture's syndrome: normal renal diagnostic findings. *Ann Intern Med* 82:215-218, 1975
13. Lockwood CM, Boulton-Jones JM, Lowenthal RM, et al: Recovery from Goodpasture's syndrome after immunosuppressive treatment and plasmapheresis. *Br Med J* 2:252-254, 1975
14. Whitworth JA, Lawrence JR, Meadows R: Goodpasture's syndrome: a review of nine cases and an evaluation of therapy. *Aust NZ J Med* 4:167-177, 1974
15. Heptinstall RH: Lung hemorrhage and glomerulonephritis, or Goodpasture's syndrome. In *Pathology of the Kidney*. 2nd ed. Boston, Little, Brown and Company, 1974, pp 580-599
16. Dunnill MS: Goodpasture's syndrome. In *Pathological Basis of Renal Disease*. London, WB Saunders Company Ltd, 1976, pp 49-57
17. Heitzman ER: *The Lung*. St. Louis, Mosby, 1973, p 154
18. Neo O, Schubert H: Various studies in roentgen morphology of essential pulmonary hemosiderosis. *Radiologie* 11:186-189, 1971
19. Soergel KH, Sommer SC: Idiopathic pulmonary hemosiderosis and related syndromes. *Am J Med* 32:499-511, 1962
20. Proskey AJ, Weatherbee L, Easterling RE, et al: Goodpasture's syndrome: a report of five cases and review of the literature. *Am J Med* 48:162-173, 1970
21. Wilson CB, Smith RC: Goodpasture's syndrome associated with influenzae A2 virus infection. *Ann Intern Med* 76:91-94, 1972

22. Willoughby WF, Dixon FJ: Experimental hemorrhagic pneumonitis produced by heterologous anti-lung antibody. *J Immunol* 104:28-37, 1970
23. McPhaul JJ Jr, Dixon FJ: Immunoreactive basement membrane antigens in normal human urine and serum. *J Exp Med* 130:1395-1409, 1969
24. Lerner RA, Dixon FJ: The induction of acute glomerulonephritis in rabbits with soluble antigens isolated from normal homologous and autologous urine. *J Immunol* 100:1277-1287, 1968
25. Lang CH, Brown DC, Staley N, et al: Goodpasture syndrome treated with immunosuppression and plasma exchange. *Arch Intern Med* 137:1076-1078, 1977
26. McLeish S, Maxwell DR, Luft FC: Failure of plasma exchange and immunosuppression to improve renal function in Goodpasture's syndrome. *Clin Nephrol* 10:71-73, 1978
27. Cove-Smith JR, McLeod AA, Blamey RW, et al: Transplantation, immunosuppression and plasmapheresis in Goodpasture's syndrome. *Clin Nephrol* 9:126-128, 1978
28. Swainson CP, Robson JS, Urbaniak SJ, et al: Treatment of Goodpasture's disease by plasma exchange and immunosuppression. *Clin Exp Immunol* 32:233-242, 1978
29. Johnson JP, Whitman W, Briggs A, et al: Plasmapheresis and immunosuppressive agents in antibasement membrane antibody-induced Goodpasture's syndrome. *Am J Med* 64:354-359, 1978
30. Fauci AS, Wolff SM: Wegener's granulomatosis: studies in 18 patients and a review of the literature. *Medicine* 52:535-561, 1973
31. Fauci AS, Haynes BF, Katz P: The spectrum of vasculitis: clinical, pathologic, immunologic, and therapeutic considerations. *Ann Intern Med* 89:660-676, 1978
32. Wolff SM, Fauci AS, Hom RG, et al: Wegener's granulomatosis. *Ann Intern Med* 81:513-525, 1974
33. Carrington CB, Liebow AA: Limited forms of angitis and granulomatosis of Wegener's type. *Am J Med* 41:497-527, 1966
34. Fauci AS, Wolff SM, Johnson JS: Effect of cyclophosphamide upon the immune response in Wegener's granulomatosis. *N Engl J Med* 285:1493-1497, 1971
35. Flye MW, Mundinger GH, Fauci AS: Diagnostic and therapeutic aspects of the surgical approach to Wegener's granulomatosis. *J Thorac Cardiovasc Surg* 77:331-337, 1979
36. Felson B: Less familiar roentgen patterns of pulmonary granulomas. *Am J Roentgenol* 81:211-223, 1959
37. McGregor MB, Sandler G: Wegener's granulomatosis. A clinical and radiological survey. *Brit J Radiol* 37:130-160, 1964
38. Kornblum D, Feinberg R: Roentgen manifestations of necrotizing granulomatosis and angitis of lungs. *Am J Roentgenol* 74:587-592, 1955
39. Maguire R, Fauci AS, Doppman JL, et al: Unusual radiographic features of Wegener's granulomatosis. *Am J Roentgenol* 130:233-238, 1979
40. Landman S, Burgener F: Pulmonary manifestations of Wegener's granulomatosis. *Am J Roentgenol* 122:750-757, 1974
41. Liebow AA: The J Burns Amberson Lecture: Pulmonary angitis and granulomatosis. *Am Rev Respir Dis* 108:1-18, 1973
42. Gonzales L, Van Ordstrand HS: Wegener's granulomatosis: review of 11 cases. *Radiology* 107:295-298, 1973
43. Israel HL, Patchefsky AS: Wegener's granulomatosis of lung: diagnosis and treatment. *Ann Intern Med* 74:881-891, 1971
44. Godman GC, Churg J: Wegener's granulomatosis: pathology and review of the literature. *AMA Arch Path* 58:533-553, 1954
45. Horn RH, Fauci AS, Rosenthal AS, et al: Renal biopsy pathology in Wegener's granulomatosis. *Am J Pathol* 74:423-434, 1974
46. Howell SB, Epstein WV: Circulating immunoglobulin complexes in Wegener's granulomatosis. *Am J Med* 60:259-268, 1976
47. Israel HL, Patchefsky AS, Saldama MJ: Wegener's granulomatosis, lymphomatoid granulomatosis, and benign lymphocytic angitis and granulomatosis of lung. Recognition and treatment. *Ann Intern Med* 87:691-699, 1977
48. Walton EW: Giant-cell granuloma of the respiratory tract (Wegener's granulomatosis). *Br Med J* 2:265-270, 1958
49. Hollander D, Manning RT: The use of alkylating agents in the treatment of Wegener's granulomatosis. *Ann Intern Med* 67:393-398, 1967
50. Katzenstein AA, Carrington CB, Liebow AA: Lymphomatoid granulomatosis: a clinicopathologic study of 152 cases. *Cancer* 43:360-373, 1979
51. Liebow AA, Carrington CR, Friedman PJ: Lymphomatoid granulomatosis. *Human Path* 3:457-558, 1972

52. Bone RC, Vernon M, Sobonya RE, et al: Lymphomatoid granulomatosis: report of a case and review of the literature. *Am J Med* 65:709-716, 1978
53. Kays FU YS, Minors N, Brady HW: Lymphomatoid granulomatosis of the skin. Light microscopic and ultra structural studies. *Cancer* 34:1675-1682, 1974
54. Schnek SA, Penn I: Cerebral neoplasms associated with renal transplantation. *Arch Neurol* 22:226-233, 1970
55. Doak PB, Montgomerie JZ, Noth JDD, et al: Reticulum cell sarcoma after renal hemotransplantation and azathioprine and prednisone therapy. *Br Med J* 47:746, 1968
56. Pierce JC, Madge GE, Lee HM, et al: Lymphoma: a complication of renal allotransplantation in man. *JAMA* 219:1593-1597, 1972
57. Porter DD, Larsen A: Virus-host interactions in Aleutian disease of mink. *Perspect Virol* 6:173-178, 1968
58. Porter DD, Larsen A, Porter HG: Pathogenesis of Aleutian disease of mink. I. in vivo replication and host antibody response to viral antigens. *J Exp Med* 130:575-589, 1969
59. Eklund CM, Hadlow WJ, Kennedy RC, et al: Aleutian disease of mink: properties of the etiologic agent and the host responses. *J Infect Dis* 118:510-526, 1968
60. East J, Branca M: Autoimmune reactions and malignant changes in germ-free New Zealand black mice. *Clin Exp Immunol* 4:621-635, 1969
61. Mellors RC: Autoimmune disease in NZB/BL mice. II. Autoimmunity and malignant lymphoma. *Blood* 27:435-448, 1966
62. East J: Viruses and autoimmunity. *Vox Sang* 16:317-324, 1968
63. Crystal JG, Fulmer JD, Roberts WC, et al: Idiopathic pulmonary fibrosis. *Ann Intern Med* 85:769-788, 1976
64. Davis CR, Min B, Rochester DF, et al: Histochemical and electron microscopic studies on induced granulomatosis disease in dog lung. *Am J Pathol* 83a:82-86, 1976
65. Laviates MH, Min B, Rochester DF, et al: Diffuse pulmonary granulomatosis disease in the dog: relation between pressure-volume behavior and morphologic features. *Am Rev Respir Dis* 116:907-917, 1977
66. Fauci AS: Granulomatous vasculitides: distinct but related (editorial). *Ann Intern Med* 87:782-783, 1977
67. Churg J, Strauss L: Allergic granulomatosis, allergic angiitis and periarteritis nodosa. *Am J Pathol* 27:277-294, 1951
68. Rose GA, Spencer H: Polyarteritis nodosa. *Q J Med* 26:43-81, 1957
69. Chumbley LC, Harrison EG Jr, De Remee RA: Allergic granulomatosis and angiitis (Churg-Strauss Syndrome): report and analysis of 30 cases. *Mayo Clin Proc* 52:477-484, 1977
70. Levin DC: Pulmonary abnormalities in the necrotizing vasculitides and their rapid response to steroids. *Radiology* 97:521-526, 1970
71. Bischoff ME: Noninfectious necrotizing granulomatosis: the pulmonary roentgen signs. *Radiology* 75:752-756, 1960
72. Churg J: Allergic granulomatosis and granulomatous-vascular syndromes. *Ann Allergy* 21:619-628, 1963
73. Matthay RA, Schwarz MI, Petty TL, et al: Pulmonary manifestations of systemic lupus erythematosus: review of 12 cases of acute lupus pneumonitis. *Medicine* 54:397-409, 1975
74. Inoue T, Kanayama Y, Ohe A, et al: Immunologic pathologic studies of pneumonitis in systemic lupus erythematosus. *Ann Intern Med* 91:30-33, 1979
75. Clark RA, Kimball HR, Decker JL: Neutrophil chemotaxis in systemic lupus erythematosus. *Ann Rheum Dis* 33:167-172, 1974
76. Staples PJ, Gerding DN, Decker JL, et al: Incidence of infection in systemic lupus erythematosus. *Arthritis Rheum* 17:1-20, 1970
77. Matthay RA, Hudson LD, Petty TL: Acute lupus pneumonitis: Response to azathioprine therapy. *Chest* 63:117-120, 1973
78. Levin DC: Proper interpretation of pulmonary roentgen changes in systemic lupus erythematosus. *Am J Roentgenol Ther Nucl Med* 111:510-517, 1971
79. Matthay RA, Petty TL: Treatment of acute lupus pneumonitis with azathioprine. *Chest* 66:219-220, 1974
80. Israel HC: The pulmonary manifestations of disseminated lupus erythematosus. *Am J Med Sci* 226:387-392, 1953
81. Hoffbrand BI, Beck ER: Unexplained dyspnea and shrinking lungs in systemic lupus erythematosus. *Br Med J* 12:1273-1276, 1965
82. Harvey AM, Schulman LE, Tumulty PA, et al: Systemic lupus erythematosus: Review of the

- literature and clinical analysis of 138 cases. *Medicine* 33:291-437, 1954
83. Gould DM, Daves MC: Roentgenologic findings in systemic lupus erythematosus. An analysis of 100 cases. *J Chron Dis* 2:136-146, 1955
 84. Estes D, Christian CL: The natural history of systemic lupus erythematosus by prospective analysis. *Medicine* 50:85-95, 1971
 85. Ellman P, Cudkowicz L: Pulmonary manifestations of diffuse collagen diseases. *Thorax* 9:46-57, 1954
 86. Eisenberg H, Dubois EL, Sherwin RP, et al: Diffuse interstitial lung disease in systemic lupus erythematosus. *Ann Intern Med* 79:37-45, 1973
 87. Dubois EL: The clinical picture of systemic lupus erythematosus. In *Lupus Erythematosus: A review of the current status of discoid and systemic lupus erythematosus and their variants*. 2nd ed. Los Angeles, University of Southern California Press, 1974, p 380
 88. Dubois EL, Tuffanelli DL: Clinical manifestations of systemic lupus erythematosus. *JAMA* 190:104-109, 1964
 89. Divertie MB: Systemic lupus erythematosus. *Med Clin North Am* 49:1016-1030, 1964
 90. Alarcon-Segovia D, Alarcon DG: Pleuropulmonary manifestations of systemic lupus erythematosus. *Dis Chest* 39:7-17, 1961
 91. Huang CT, Lyons HA: Comparison of pulmonary function in patients with systemic lupus erythematosus, scleroderma, and rheumatoid arthritis. *Am Rev Respir Dis* 93:865-875, 1966
 92. Gould DM, Daves ML: A review of the roentgen findings in systemic lupus erythematosus (SLE). *Am J Med Sci* 235:596-610, 1958
 93. Bulgrin JG, Dubois EL, Jacobson G: Chest roentgenographic changes in systemic lupus erythematosus. *Radiology* 74:42-49, 1960
 94. Garland LH, Sissin MA: Roentgen findings in the "collagen" diseases. *Am J Roentgenol* 71:581-598, 1954
 95. Huang CT, Hennigar GR, Lyons HA: Pulmonary dysfunction in systemic lupus erythematosus. *N Engl J Med* 272:288-292, 1965
 96. Winslow WA, Ploss LN, Loitman B: Pleuritis in systemic lupus erythematosus: Its importance as an early manifestation in diagnosis. *Ann Intern Med* 49:70-88, 1958
 97. Byrd RD, Trunk G: Systemic lupus erythematosus presenting as pulmonary hemosiderosis. *Chest* 64:128-129, 1973
 98. Mintz G, Galindo LF, Fernandez-Diez J, et al: Acute massive pulmonary hemorrhage in systemic lupus erythematosus. *J Rheumatol* 5:39-50, 1978
 99. Gamsu G, Webb WR: Pulmonary hemorrhage in systemic lupus erythematosus. *J Can Assoc Radiol* 29:66-68, 1978
 100. Taylor TL, Ostrum H: The roentgen evaluation of systemic lupus erythematosus. *Am J Roentgenol* 82:95-107, 1959
 101. Carr DT, Mayne JG: Pleural fluid glucose in systemic lupus erythematosus. *Mayo Clin Proc* 45:409-425, 1970
 102. Decker JL, Steinberg AD, Gershwin ME, et al: Systemic lupus erythematosus: Contrasts and comparisons. *Ann Intern Med* 82:391-404, 1975
 103. Walker WC, Wright V: Pulmonary lesions and rheumatoid arthritis. *Medicine* 47:501-520, 1968
 104. Gibson GJ, Edmonds JP, Hughes GRV: Diaphragm function and lung involvement in systemic lupus erythematosus. *Am J Med* 63:926-928, 1977
 105. Huang C, Hennigar GR, Lyons HA: Pulmonary dysfunction in systemic lupus erythematosus. *N Engl J Med* 272:288-298, 1976
 106. Gold WM, Jennings DB: Pulmonary dysfunction in patients with systemic lupus erythematosus. *Am Rev Respir Dis* 93:556-567, 1966
 107. Wohlgernter D, Loke J, Matthay RA, et al: Systemic and discoid lupus erythematosus: Analysis of pulmonary function. *Yale J Biol Med* 51:157-164, 1978
 108. Gross M, Esterly JR, Earle RH: Pulmonary alterations in systemic lupus erythematosus. *Am Rev Respir Dis* 105:572-577, 1972
 109. Olsen EG, Lever JV: Pulmonary changes in systemic lupus erythematosus. *Br J Dis Chest* 66:71-77, 1972
 110. Mybre JR: Pleuropulmonary manifestations in lupus erythematosus disseminatus. *Acta Med Scand* 165:55-65, 1959
 111. McCredie M, Lovejoy FW, Kaltreider NL: Pulmonary function in diaphragmatic paralysis. *Thorax* 17:213-217, 1962
 112. Lee SL, Chase DH: Drug-induced systemic lupus erythematosus: A critical review. *Semin Arthritis* 5:83-87, 1975
 113. Dubois EL: Procainamide induction of a systemic lupus erythematosus-like syndrome: Presentation

- of six cases, review of the literature, and analysis and follow-up of reported cases. *Medicine* 42:217-228, 1969
114. Blomgren SE, Condemni JJ, Vaughan JH: Procainamide-induced lupus erythematosus: Clinical and laboratory observations. *Am J Med* 52: 338-348, 1972
 115. Auerbach RC, Snyder NE, Bragg DG: The chest roentgenographic manifestations of pronestyl-induced lupus erythematosus. *Radiology* 109:287-290, 1973
 116. Selroos G, Edgren J: Lupus-like syndrome associated with pulmonary reaction to nitrofurantoin. *Acta Med Scand* 297:1250-1257, 1975
 117. Chandrasekhar AJ, Robinson J, Barr L: Antibody deposition in the pleura: A finding in drug induced lupus. *J Allergy Clin Immunol* 61:399-410, 1978
 118. Byrd RB, Schanger B: Pulmonary sequelae in procaine amide induced lupus-like syndrome. *Dis Chest* 55:170-172, 1969
 119. Barnett AJ: Scleroderma. Springfield, IL, Charles C Thomas, 1974
 120. Sackner MA: Scleroderma. New York, Grune and Stratton, 1966
 121. Sackner MA, Akgun N, Kimball P, et al: The pathophysiology of scleroderma involving the heart and respiratory system. *Ann Intern Med* 60:611-630, 1964
 122. Rodnan G: The natural history of progressive systemic sclerosis (diffuse scleroderma). *Bull Rheum Dis* 13:301-310, 1963
 123. DeTakats G, Fowler EF: Raynaud's phenomenon. *JAMA* 179:1-10, 1962
 124. Winklemann RK: Pathogenesis and staging of scleroderma. *Acta Derm Venereol (Stockh)* 56:83-92, 1976
 125. Medsgar TA, Masi AT, Rodnan GP, et al: Survival with systemic sclerosis (scleroderma): A life-table analysis of clinical and dermographic features in 309 patients. *Ann Intern Med* 75:369-376, 1971
 126. Wilson RJ, Rodnan GP, Robin EP: An early pulmonary physiologic abnormality in progressive systemic sclerosis (diffuse scleroderma). *Am J Med* 36:361-369, 1964
 127. Salerni R, Rodman GP, Leon DF, et al: Pulmonary hypertension in the CREST syndrome variant of progressive systemic sclerosis (scleroderma). *Ann Intern Med* 86:394-414, 1977
 128. D'Angelo WA, Fries JF, Masi AT, et al: Pathologic observations in systemic sclerosis (scleroderma): A study of fifty-eight autopsy cases and fifty-eight matched controls. *Am J Med* 46:428-440, 1969
 129. Colp CR, Riker J, Williams MH: Serial changes in scleroderma and idiopathic interstitial lung disease. *Arch Intern Med* 132:506-512, 1973
 130. Trell E, Lindstrom C: Pulmonary hypertension in systemic sclerosis. *Ann Rheum Dis* 30:390-400, 1971
 131. Godfrey S, Bluestone R, Higgs BE: Lung function in response to exercise in systemic sclerosis. *Thorax* 24:427-434, 1969
 132. Hughes DTD, Lee FI: Lung function in patients with systemic sclerosis. *Thorax* 18:16-20, 1963
 133. Ritchie B: Pulmonary function in scleroderma. *Thorax* 19:28-36, 1964
 134. Adhakari PK, Bianchi FA, Boushy SF, et al: Pulmonary function in scleroderma: Its relation to changes in the chest roentgenogram and in the skin in the thorax. *Am Rev Respir Dis* 86: 823-831, 1962
 135. Spain DM, Thomas AG: The pulmonary manifestations of scleroderma: An anatomic-physiologic correlation. *Ann Intern Med* 32:152-161, 1950
 136. Miller RD, Fowler RD, Helmholtz FH: Scleroderma of the lungs. *Proc Mayo Clin* 34:66-77, 1959
 137. Guttadauria M, Ellman N, Emanuel G: Pulmonary function in scleroderma. *Arthritis Rheum* 20:107-109, 1977
 138. Gondos B: Roentgen manifestations in progressive systemic sclerosis (diffuse scleroderma). *Am J Roentgenol* 84:235-247, 1960
 139. Norton WL, Nardi JM: Vascular disease in progressive systemic sclerosis (scleroderma). *Ann Intern Med* 73:317-324, 1970
 140. Naeye RL: Pulmonary vascular lesions in systemic scleroderma. *Dis Chest* 44:374-385, 1963
 141. Weaver AL, Divertie MB, Titus JL: Pulmonary scleroderma. *Dis Chest* 54:490-498, 1968
 142. Sostman HD, Matthay RA, Putman CE: Cytotoxic drug-induced lung disease. *Am J Med* 62:608-615, 1977
 143. Spain DM: The association of terminal bronchiolar carcinoma with chronic interstitial inflammation and fibrosis of the lungs. *Am Rev Tuberc* 76:559-567, 1957
 144. Montgomery RD, Stirling GA, Hamer NA: Bronchiolar carcinoma in progressive systemic sclerosis. *Lancet* 1:586-587, 1964
 145. Richards RL, Milne JA: Cancer of the lung in progressive systemic sclerosis. *Thorax* 13:328-332, 1958
 146. Siltzbach LE: Progressive systemic sclerosis with pulmonary involvement. *Dis Chest* 54:1-12, 1968