

INTERSTITIAL DESOXYRIBONUCLEIC ACID FOLLOWING CELL DEATH*

HENRY BUNTING

In regions of necrosis there are commonly seen in histological preparations hematoxylin-stained areas in the interstitium. These sometimes surround cells of the exudate which may be disintegrating, or they may be found immediately around the necrotic parenchymal cells of the particular organ. The nature of these areas for which hematoxylin has such a strong affinity has been investigated by several histochemical procedures.

Methods

Tissues were fixed in 10% formalin, Zenker's fluid, and Helley's fluid. They were dehydrated in the usual manner and imbedded in paraffin. Hematoxylin and eosin preparations were made on all. Progressive staining for several hours with dilute methylene blue, $10^{-4}M$, in phosphate-sodium hydroxide buffer at pH 6.6, followed by drying in air and clearing in toluol, was used to determine the locations of basophilia. Such sections served as controls for those exposed to ribonuclease for the identification of ribonucleic acids. Sections were incubated for 2 hours at 58-60°C. in a solution of the enzyme† (6 mg. enzyme per 20 ml. of distilled water). Progressive staining in a dilute solution of aniline blue, $5 \times 10^{-5}M$, in citric buffer at pH 5.2 for several hours was used to determine areas of acidophilia. Feulgen reactions for desoxyribonucleic acids were carried out by exposing sections to Schiff's reagent (fuchsin-sulfurous acid) after hydrolysis in 1N HCl at 60°C. for intervals of from 10 to 60 minutes. (For details of the method, cf. Lison⁸ or Stowell.⁹) Control sections were treated similarly except that water was substituted for HCl. Of the various basic fuchsin used in the preparation of Schiff's reagent (pararosanilin, C.I. no. 676; the mixture known as basic fuchsin, C.I. no. 677; and "new fuchsin," the trimethyl fuchsin, C.I. no. 678²), "new fuchsin" gave the deepest color and hence appeared to be the most sensitive reagent.

Inorganic phosphorus was sought in those tissues that had been fixed in formalin (the mercuric chloride in Zenker's or Helley's made them unsuitable). The method which has been used with success in control sites has been adapted from that of Feigl¹: hydrolysis has been carried out for 5 minutes with 0.5% HNO₃ in the presence of

* From the Department of Pathology, Yale University School of Medicine. Supported by a research grant from the National Cancer Institute, U. S. Public Health Service.

† Ribonuclease from Armour & Co., prepared by Kunitz' method and with the non-specific proteolytic activity destroyed as per M. R. McDonald (J. Gen. Physiol., 1948, 32, 39).

Received for publication April 17, 1950.

2.5 ammonium molybdate solution; benzidine and sodium acetate solutions have been used as in the original.

Results

Examples of necrosis showing areas of hematoxylin-stained interstitial material have been selected from different sites. Sixteen have been studied as follows: 9 of the myocardium, 3 in the pancreas, 2 in the kidney, and 2 of tuberculous exudate. The uniformity of the histochemical findings made it seem unnecessary to enlarge further this group before reporting the results. The data will be described in the categories listed above.

Myocardium. Surrounding the necrotic muscle in an infarct of the myocardium there is a zone of edema and inflammatory cells. Many of the polymorphonuclear leukocytes are necrotic with pyknotic and karyorrhectic nuclei. It is in this area that hematoxylin stains conspicuously the granular or stringy-appearing substance, apparently precipitated protein, which lies between the cells of the exudate and extends into the adjacent connective tissue septa (Fig. 1). The hematoxylin staining of the intercellular material is not found to extend for any distance either into the area of necrotic or that of the intact myocardium. Methylene blue (Fig. 2) and aniline blue stain the same intercellular material intensely, indicating the existence of both acid and basic groups. Digestion in ribonuclease does not alter the staining by methylene blue of this granular and fibrillar material, indicating that ribonucleic acids probably do not contribute to the basophilia. The material gives the Feulgen reaction (Fig. 3), allowing the conclusion that desoxyribonucleic acid is present; this is consistent with the affinity shown for hematoxylin and methylene blue. These same reactions as a rule are not given by the necrotic muscle fibers, although in rare instances they are, suggesting that the desoxyribonucleic acids have diffused from the nucleus but are still confined within the cell membrane.

Pancreas. Small foci of necrosis of the parenchyma and fat cells of the pancreas are not an uncommon finding at autopsy. The granular or fibrous material that occupies most of the necrotic area stains deeply with hematoxylin (Fig. 4). Around the margin, leukocytes and other cells are frequently pyknotic. Fat cells are altered and show a granular rim of cytoplasm; this also stains with hematoxylin. All the above loci are basophilic, staining readily with methylene blue; the intensity is not diminished by exposure to ribonuclease. There is also acidophilic material present, as it stains with aniline blue to about the same intensity as do nuclei. The Feulgen reaction is given strongly by nuclei and by the granular and fibrous appearing necrotic material (Fig. 5) and somewhat less

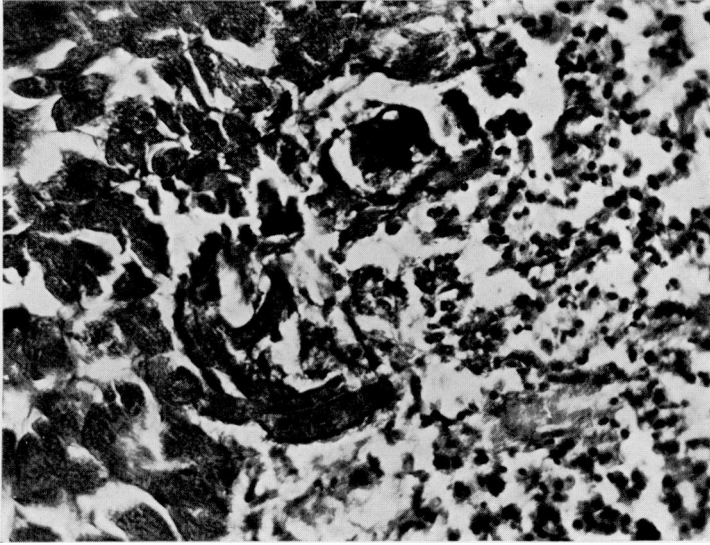


FIG. 1. Margin of myocardial infarct. Leukocytes and hematoxylin-stained precipitate in the interstitial region between the necrotic muscle fibers. Hematoxylin and eosin. x 380.

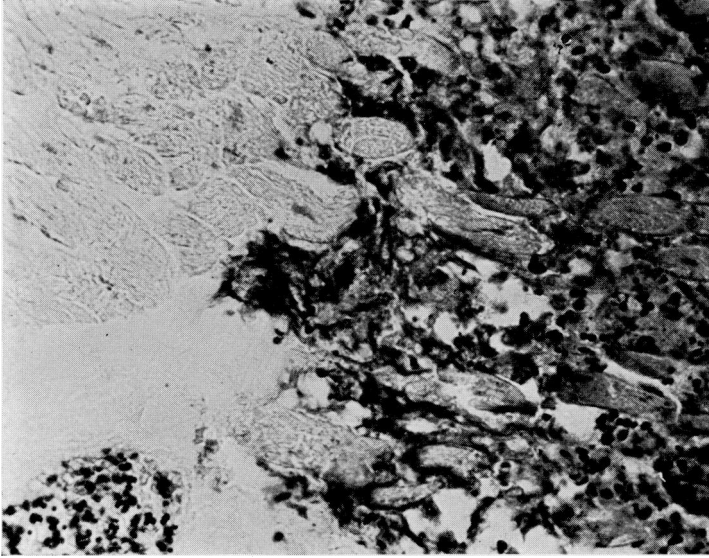


FIG. 2. Same field and magnification as preceding figure. Stained with methylene blue alone.

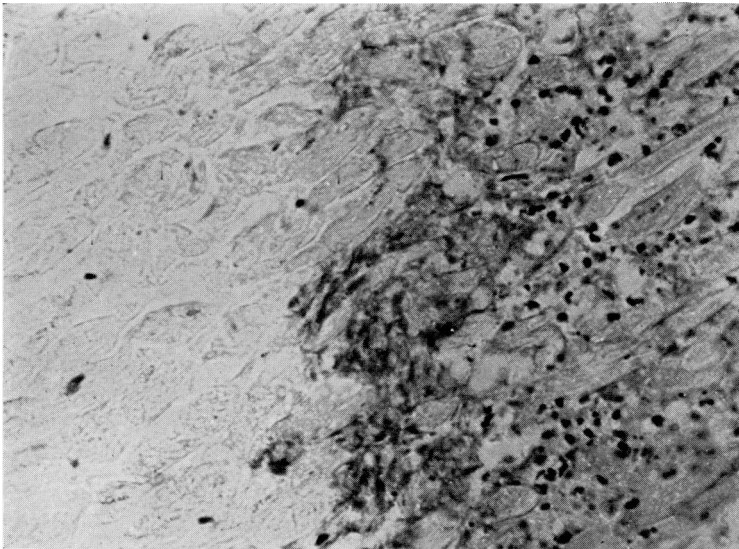


FIG. 3. Same field and magnification as preceding figures. Feulgen reaction, no counterstain.

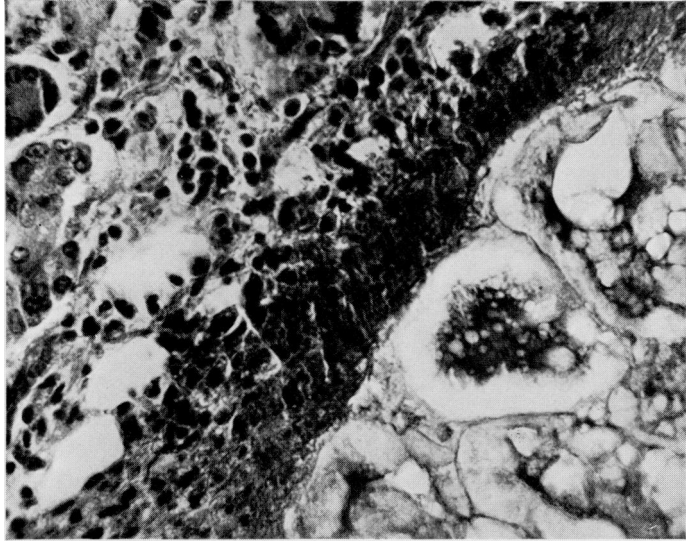


FIG. 4. Focal area of necrosis in pancreas. Hematoxylin staining of necrotic center and granular margin containing cell debris; leukocytes and intact parenchyma beyond. Hematoxylin and eosin. x 380.

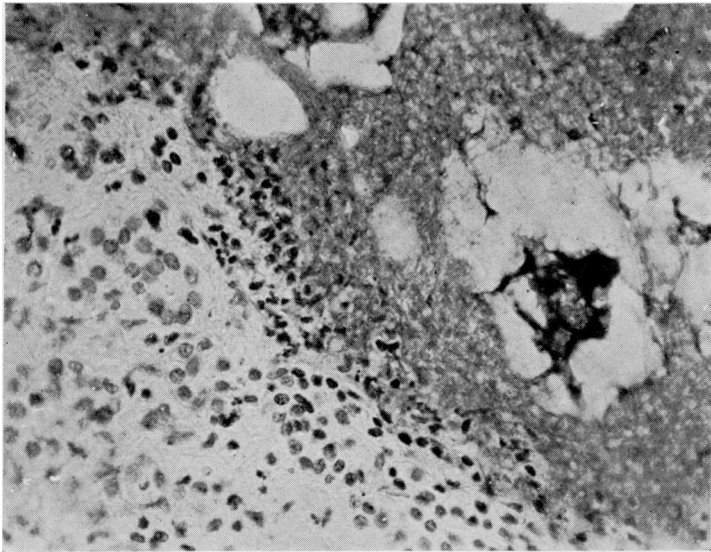


FIG. 5. Same field and magnification as preceding figure. Feulgen reaction, no counterstain.

intensely by the granular rim of the fat cells. It should be noted that the Feulgen reaction is absent in the basophilic material (which is also stained by hematoxylin) normally present in the basal portion of the cytoplasm of unaltered acinar cells or which may be found diffusely spread throughout their cytoplasm as a result of post-mortem autolytic changes; this basophilia being diminished or removed by treatment with ribonuclease is probably due to the presence of ribonucleic acids.

Kidney. Infarcts in the kidney give much the same picture as seen in the myocardium. At the margin is a band of intact and disintegrating polymorphonuclear leukocytes. The nuclear fragments are Feulgen positive and a faint reaction is also present in the intervening framework and necrotic epithelial structures. The cellular debris that is identifiable within the preëxisting tubular basement membranes also is strongly Feulgen positive. The material that gives the Feulgen reaction also stains with hematoxylin and is basophilic as judged by affinity for methylene blue.

Tuberculous exudate. Examples of tuberculous exudate have been chosen from the leptomeninges in tuberculous meningitis and a caseous lymph node. Pyknotic nuclei and karyorrhectic fragments are recognizable in the zone of necrosis; these as expected give the Feulgen reaction. The granular necrotic material, unrecognizable except as being cellular debris, in certain caseous areas stains faintly with hematoxylin and methylene blue; affinity for the latter is not affected by previous treatment with ribonuclease. Tests for inorganic phosphorus were negative. Aniline blue stains these areas conspicuously. Significantly, these basophilic regions give a Feulgen reaction. It may be of some interest that they may be separated for some distance from nuclear debris and also from the fibrous capsule around the caseous tissue.

Discussion

In the present studies various histochemical tests have been applied to extracellular areas which are often associated with necrosis and which characteristically show an affinity for hematoxylin. These regions were found to have reactive acidic groups as evidenced by their staining with the basic dye, methylene blue. This staining was not altered by ribonuclease as was that of certain intracellular sites of basophilia which were, therefore, concluded to be due to ribonucleic acid; these latter also showed an affinity for hematoxylin. While the basophilia of the extracellular areas, as determined by combination with methylene blue at a fairly high pH of 6.6, could be due to many kinds of acid radicals, it might be expected to be phosphoric acid. The Feulgen reaction presumably consists of a combination

between Schiff's reagent and the aldehyde groups of the desoxyribose molecules which have been freed from the nucleic acids by acid hydrolysis.⁸ Since in all instances the regions under discussion gave a positive Feulgen reaction, they probably represent areas rich in desoxyribonucleic acid. Whether the nucleic acids are combined with the protein moiety, the histones, cannot be stated. That the latter are present, however, is suggested by the strong affinity these areas have for the acidic dye, aniline blue, a reaction comparable in intensity to that shown by the nuclei themselves. The staining of chromatin by hematoxylin (actually hematein, the oxidized form in combination with a mordant) has, of course, been known for a great many years, but no chemical explanation has been given for the linkage other than the assumption that a lake is formed through the divalent cation constituting the mordant;¹ this reaction cannot be considered of histochemical significance.

The origin of the extracellular interstitial desoxyribonucleic acids is obvious from the close proximity of pyknotic and karyorrhectic nuclear fragments, whether of cells of the organ parenchyma or the exudate. It is suggested that the nucleic acids diffuse from the nucleus through the cell membrane upon the loss of its selective permeability or actual destruction associated with necrosis. In the interstitial regions the nucleic acids appear often to be associated with a granular precipitate undoubtedly derived from cell debris or the fluid components of the exudate. In some instances, such as infarcts, interstitial desoxyribonucleic acids are found only where cell death has been of fairly recent origin. Here it can be surmised that loss of nucleic acids from the area may occur by way of the lymphatics along with the edema fluid or that degradation beyond the level of recognition by these methods may result. Elsewhere, as in tuberculous caseation, detectable desoxyribonucleic acids remain for what must be relatively long periods of time, since they are found in the midst of caseous tissue; this is not wholly unexpected since tuberculous tissue is non-vascularized.

The changes described in the present studies are almost identical with those reported by Sherry, Tillett, and Christensen⁷ of the occurrence of desoxyribonucleoprotein in pleural exudates. Feulgen stainable nuclear fragments and other material were present in the granular debris of the sediment. Klemperer⁸ has identified Feulgen positive material as being responsible for the faint hematoxylin staining of the cytoplasm of certain necrotic cells characteristic of lupus erythematosus. All of these studies give a better understanding of certain regressive phenomena associated with cell death.

Summary

The hematoxylin-stained material commonly seen extracellularly in the interstitium of regions of necrosis, such as infarcts or caseous exudate, has been subjected to various histochemical tests; the material exhibits both basophilia and acidophilia, is not affected by ribonuclease, and gives the Feulgen reaction. The staining qualities are concluded to be consistent with the presence of desoxyribonucleic acids and associated histones derived from nuclei of necrotic cells of the exudate and the parenchyma.

Appreciation is expressed for the technical assistance of Miss Patricia Reynolds.

REFERENCES

- 1 Baker, J. R.: *Cytological technique*. London, Methuen & Co., 1945, p. 157.
- 2 Conn, H. J.: *Biological stains*. 5th ed. Geneva, N. Y., Biotech Publications, 1946, p. 122.
- 3 DiStephano, H. S.: A cytochemical study of the Feulgen nuclear reaction. Proc. National Acad. Sc. U.S., 1948, 34, 75.
- 4 Feigl, Fritz: *Qualitative analysis by spot tests*. New York, Elsevier Pub. Co., 1946, p. 250.
- 5 Klemperer, P., Gueft, B., and Lee, S. L.: Cellular changes in systemic lupus erythematosus. Am. J. Path., 1949, 25, 778 (abstract).
- 6 Lison, L.: *Histochimie animale, méthodes et problèmes*. Paris, Gauthier-Villars, 1936.
- 7 Sherry, S., Tillett, W. S., and Christensen, L. P.: The presence and significance of desoxyribose nucleoprotein in the purulent pleural exudates of patients. Proc. Soc. Exp. Biol., N. Y., 1948, 68, 179.
- 8 Stowell, R. E.: Feulgen reaction for thymonucleic acid. Stain Tech., 1945, 20, 45.