

EFFECT OF LOCAL FREEZING ON THE ELECTRICAL ACTIVITY OF THE CEREBRAL CORTEX

LESLIE F. NIMS, CLYDE MARSHALL, AND AAGE NIELSEN*

Openchowski² first observed that dogs developed generalized convulsions some hours after a small portion of their cerebral cortices had been frozen. Speransky³ confirmed and extended this observation and noted that the administration of morphine greatly increased both the incidence and severity of the convulsions. He also pointed out the striking resemblance of these disturbances in the dog to those seen in clinical epilepsy in man.

The methods employed by these investigators appeared to offer certain advantages for the study of the convulsive state and of the disturbed electrical activity of the brain associated with it. Accordingly, small regions of the cerebral cortices of cats, dogs, and monkeys were frozen and observations of the subsequent clinical condition of the animals and of the electrical activity of the brain were made. The results of these studies are reported here.

Procedures

The experiments were divided into two groups. In one, the freezing of the cerebral cortex was done under aseptic conditions extradurally, through a small trephine opening in the skull, and the clinical condition of the operated animals was observed for periods up to three weeks. In the other, the cerebral cortices were widely exposed, the dura was reflected, and freezing was done either locally as above with a small metal bucket containing carbon dioxide snow and ether, or more extensively with an ethyl chloride spray. The electrical activity of the traumatized and non-traumatized regions was then followed continuously for periods up to 36 hours. Some of the animals used in the first group of experiments were also used in the second, so that these had both an old and a freshly frozen area when examined electrically.

* From the Laboratories of Physiology, Neuro-Anatomy, and Neurophysiology, Yale University School of Medicine. Aided by grants from the Fluid Research Fund of the Yale University School of Medicine and from the Josiah Macy, Jr. Foundation.

Results

Clinical observations. Three cats were anesthetized with sodium amytal and frozen over the left frontal pole, the left suprasylvian gyrus, and the left occipital pole, respectively. The first died several hours after operation. The second and third were very slow in awakening from the anesthesia and were lethargic for several days. They eventually recovered fully without at any time showing convulsive seizures.

One dog, anesthetized with nembutal, was frozen over the posterior end of the left sylvian fissure. The animal was completely out of the anesthesia by the next day and seemed relatively unaffected by the operation. On the second postoperative day a convulsive seizure was observed. It began with jerking movements of the jaws and eyes, and this was followed by arching of the back. The animal fell to its side and vigorous running movements of the legs developed. The attack lasted for about one minute and the animal was drowsy for some time thereafter. Four hours later a second seizure, similar to the first but lasting for a somewhat longer time, was seen. No further convulsive episodes were noted during the following two weeks. At autopsy a lesion located in the aforementioned region was found. It was about 1.5 cm. in diameter and extended for a short distance into the gray matter.

A second dog was treated in the same way with the exception that morphine (20 mg. per kg. subcutaneously) and ether were used instead of amytal as the anesthetic. Two and one-half hours following the freezing the first convulsion occurred. It began with a twitching of head and eyes to the right, and progressively extended to involve the right fore leg, right hind leg, left hind leg, and left fore leg so that finally a generalized convulsion developed. Thirty minutes later a second attack occurred and other attacks followed at shorter intervals. During the following eight hours 50 seizures were seen, after which the animal was sacrificed and the brain removed. The frozen area was found to be on the anterior portions of the ecto- and supra-sylvian gyri and was roughly circular in shape with a diameter of about 1 cm. It was easily distinguishable from the rest of the cortex by its dull red color and appeared to extend some 3 mm. in depth just into the white matter.

Various areas of the cortex were frozen in four monkeys (*Macacus rhesus*) while anesthetized with ether. None developed convulsions, though for a time two showed a rapid "tic-like" movement of

the head and upper extremities. The "tic" began about seven hours after the operation and persisted with varying intensity for the next twelve hours. Apart from this they made uneventful recoveries. One of these animals, however, when frozen a second time, with morphine alone as the anesthetic, did develop a "Jacksonian" seizure. The freezing was done in the arm portion of area 4 on the right side. The seizure began in the right shoulder and arm and progressively involved the right leg and left leg. The left arm, which was apparently paralyzed by the freezing, was not affected. This animal had repeated seizures, and an electrical record of one of the convulsive episodes is given in Fig. 3.

Electrical activity. While the cats showed no clinical evidences of convulsions, the electrical activity of their brains was profoundly modified by the freezing procedure. Strips 1 to 6 of Fig. 1 were taken from a single cat, anesthetized with nembutal, which had been frozen widely over one hemisphere. Strips 1, 2, 3, and 4 show the

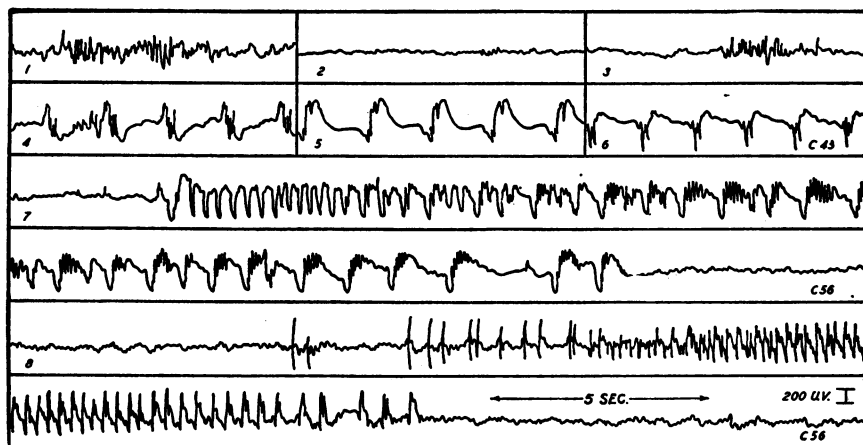


FIG. 1. Strips 1-6. Cat. Nembutal anesthesia. Left cerebral cortex frozen widely with ethyl chloride. Records taken from within frozen zone. Strips 1-4, from anterior part of middle suprasylvian gyrus, before, 2 minutes after, 10 minutes after, and 35 minutes after freezing. Strip 5, posterior part of same gyrus 36 minutes after freezing. Strip 6, posterior part of marginal gyrus 50 minutes after freezing.

Strips 7-8. Cat. Nembutal and morphine anesthesia. Anterior part of middle suprasylvian gyrus on right frozen with CO_2 snow and ether. Records from posterior part of same gyrus 3 and 28 hours later.

electrical activity of the anterior part of the middle suprasylvian gyrus before and 2, 10, and 34 minutes after the freezing. It is seen that the initial effect of freezing was to produce electrical silence (strip 2), but as the tissue warmed up the electrical activity returned toward an essentially normal pattern (strip 3). Later, however, bizarre patterns consisting of slow waves and spikes developed not only in the original area studied (strip 4), but in other areas throughout the frozen zone (strips 5 and 6). These abnormal patterns persisted for long periods of time.

Strips 7 and 8 of Fig. 1 were obtained from the posterior part of the middle suprasylvian gyrus of a cat 3 hours and 28 hours, respectively, after the cortex anterior to this zone had been frozen. They demonstrate that dysrhythmias may develop in regions outside the frozen zone. These seizure patterns appeared at infrequent intervals, but were constant in character when they did appear.

Figure 2 contains excerpts from an electrical convulsion produced in a dog. This animal was frozen while anesthetized with morphine and nembutal. The area frozen was centered over the middle suprasylvian gyrus; the electrical recordings were made from the same gyrus behind the frozen zone. The sequence of events was as follows: Superimposed upon the background activity of essentially normal character occasional "spikes" appeared. These gradually increased in frequency and merged with the enhanced background activity (strips 1 and 2). A regular rhythmic discharge of decreasing frequency appeared for a short time (strip 3) suddenly breaking into a very irregular pattern (strips 4 and 5), and then replaced by rhythmic bursts (strips 6 to 10). The seizure terminated with large spike-like potentials (strip 11). The records in Fig. 2 are 20-second excerpts from each minute of the eleven that the convulsion lasted. This animal was deeply anesthetized and no movements were apparent during the electrical seizure in the brain, so that the record is uncomplicated by potentials arising from muscular activity.

Figure 3 is a similar record taken from a monkey anesthetized with morphine alone. In this animal the arm portion of area 4 on the right side was frozen, and the record was taken from the arm portion of area 4 on the left. Convulsive movements of the limbs were seen associated with the electrical disturbance taking place in the cortex. The electrical signs of the convulsion appeared in the brain before the muscular activity began, and as the electrical dis-

turbance swept across the cortex the muscular groups came into action in proper sequence.

Three of the four monkeys studied electrically did not develop any such convulsive patterns although they were watched continuously up to 36 hours after freezing. Various areas, however, did show some disturbance, characterized by sporadic spike-like potentials of large amplitude similar to those seen in Fig. 2, strip 11, the

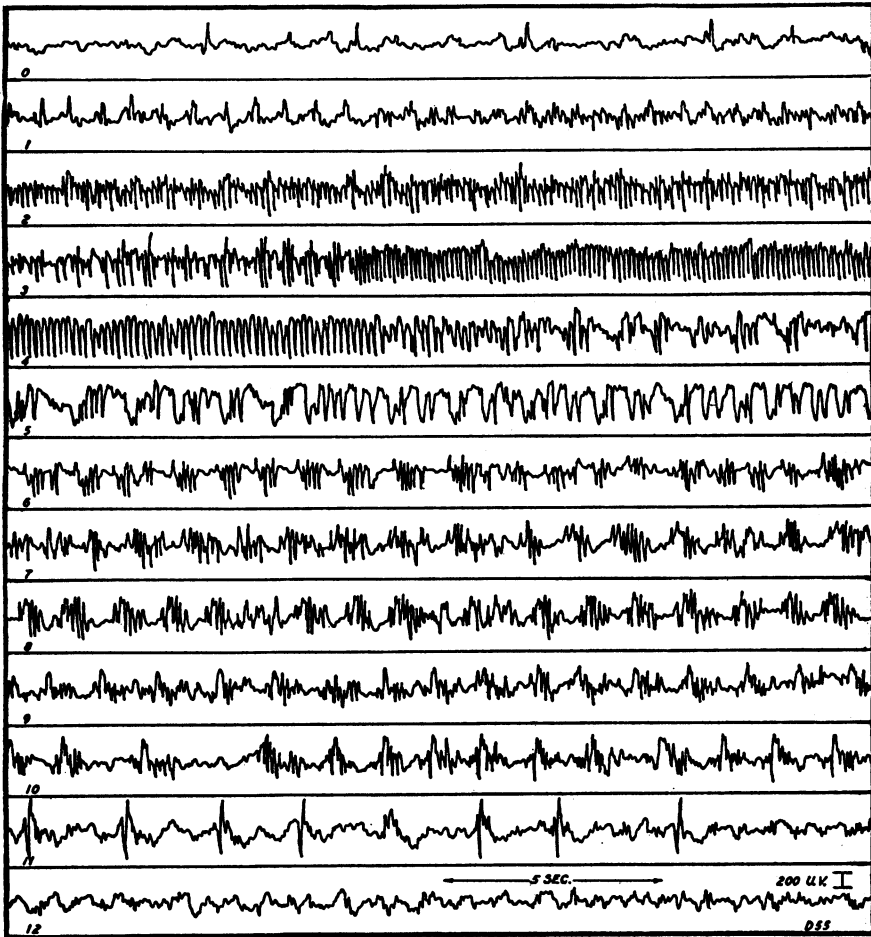


FIG. 2. Dog. Anesthetized with morphine and nembutal. Frozen over center of right middle suprasylvian gyrus. Record from same gyrus behind the frozen area, $3\frac{1}{2}$ hours later.

terminal event in the seizure recorded in the dog. Often these spike potentials would gradually increase in frequency, suggesting that an electrical "blow up" was on the way, only to fade out and leave essentially normal activity.

Pathological changes. The age of the lesions, i.e., the time from the application of freezing until the death of the animal,

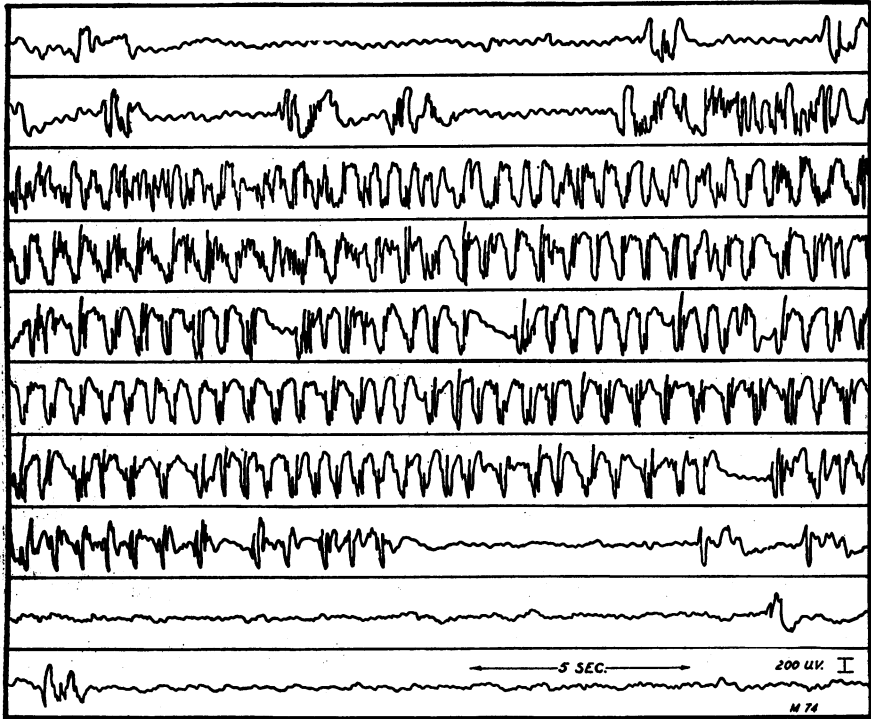


FIG. 3. Monkey. Anesthetized with morphine. Frozen on arm portion of area 4 on right. Record from contralateral area on the left, 8 hours later.

varied from several hours to three weeks. In the young lesion, when death took place within a day or two after the freezing, the brain showed a sharply demarcated area of brownish discoloration corresponding to the size of the freezing bucket used. The tissue within this area showed a distinct softening to a depth which just involved the white matter. On superficial microscopic examination the meninges appeared thickened and hemorrhagic, and they were

invaded by numerous acute inflammatory cells. The nerve cells in the center of the lesions were completely destroyed and in the periphery they showed evidence of injury to a varying degree,—loss of tigroid substance, peripherally placed nuclei, increase of satellites, etc. Numerous hemorrhagic areas were seen throughout the sections.

The older lesions showed gross loss of brain substance in the center of the lesion. In dog 1, for example, sacrificed two weeks after the initial freezing, the actual loss of tissue was evidenced by an excavation, at the site of the lesion, measuring 1.3 by 1.6 cm. at the surface and reaching well within the white matter of the brain. A microscopic section from this area showed complete destruction of cells and fibers, gradually becoming less marked as healthy brain tissue was approached peripherally.

Summary and conclusions

The experiments reported here confirm the findings of earlier investigators that freezing of a small area of the cerebral cortex tends to produce convulsions in the dog, and that this tendency is greatly increased if morphine is given at the time that the freezing is carried out. This observation cannot be generalized to include the cat and the monkey, for in these animals the likelihood of convulsions following freezing is much less pronounced.

Local freezing produces disturbances in the electrical activity of the cerebral cortex not only in the frozen zone itself but also in untreated areas. In the frozen zone the initial effect is a complete obliteration or a severe depression of the electrical activity. After a variable length of time, however, partial recovery takes place and still later abnormal patterns are seen. Outside the frozen area electrical disturbances may also appear. These dysrhythmias take various forms, but certain types are perhaps more commonly seen in the different animal species. Thus, high voltage, high frequency discharges not unlike those of grand mal in man¹ are seen quite characteristically in the dog, while slower wave forms as well as spike and wave patterns (*petit mal*?) are more common in the cat. In the monkey high voltage spikes repeated at rather long intervals form the essential feature of the disturbed electrical pattern.

The mechanism of production of these abnormal rhythms is unknown. Certain features of the disorder, particularly the time sequences of the phenomena, suggest that slowly developing chem-

ical changes may be involved. Some of the changes in the chemistry of the brain following freezing are reported in the following paper.

REFERENCES

- 1 Gibbs, F. A., Gibbs, E. L., and Lennox, W. G.: Cerebral dysrhythmias of epilepsy. *Arch. Neurol. & Psychiat.*, 1938, 39, 298-314.
- 2 Openchowski: Sur l'action localisée du froid, appliqué a la surface de la région corticale du cerveau. *Compt. rend. Soc. de biol.*, 1883, 35, 38-43.
- 3 Speransky, A. D.: *A basis for the theory of medicine*. International Publishers, New York. 1935.

We wish to express our appreciation for the aid and encouragement received from the late Professor J. G. Dusser de Barenne in whose laboratory this work was done.