

# Campylobacter Fetus Infection in Humans

## Analysis of Three Cases

CALVIN C. SAMPSON, M.D.,  
CLOTILDE D. SMITH, B.S., M.T., A.S.C.P.,  
and

CATHERINE DEANE, M.T., A.S.C.P.,  
*Department of Pathology and Clinical Laboratories,  
Howard University Medical Center,  
Washington, D.C.*

**C**ampylobacter fetus, previously classified as *Vibrio fetus*, has been incriminated as the causative agent in infectious abortions and infertility in ungulates.<sup>1</sup> First isolated from cattle by McFadyean and Stockman<sup>2</sup> in 1909, it was not until 1947 that Vinzent, et al.<sup>3</sup> reported the first case of human infection caused by the organism. To date, less than 100 cases of *C. fetus* infections in humans have been reported in the world literature.<sup>4</sup>

Due to its pathogenicity for humans, its propensity for "opportunism" in debilitated patients and patients receiving corticosteroids and or immunosuppressive therapy, and the problems inherent in its isolation from human material, the authors were prompted to review the three cases of vibriosis isolated from three patients—two from blood and one from a cul de sac aspiration—at Howard University Hospital, during the period July 1966 through December 1974

### CASE STUDIES

*Isolation from blood.* One patient was a 71-year-old male who was being treated for multiple myeloma. He had a persistent unexplained fever. Three blood cultures were positive for *C. fetus*. Following specific antibiotic therapy, all subsequent blood cultures were negative. He died several months later, apparently from his major disease.

The second patient was a 44-year-old male who had been asymptomatic until he presented with fever and chills. Three blood cultures were positive for *C. fetus*. He responded to specific antibiotic therapy. All subsequent blood cultures were negative. He is living and well.

*Isolation from cul de sac aspiration.* A 38-year-old lady had vague pain and fullness in the pelvic area. Bimanual examination suggested adnexal disease. A cul de sac aspiration was positive for pure cultures of *C. fetus*. Following specific antibiotic therapy she became asymptomatic and was discharged as well.

### MATERIALS AND METHODS

In our laboratory, blood cultures are col-

lected in trypticase soy agar containing 0.1% agar and are incubated at 35°C. with daily observation for growth. Positive cultures are smeared, plated on selected media, and two loops transferred to a tube of thioglycollate broth. The cellular morphology observed in gram stains determines the suitable plates and atmosphere to be used in subcultures. Cultures suspected of containing *C. fetus* are inoculated on chocolate and blood agar plates for two to five days in a candle jar, and on MacConkey plates, aerobically, for three days.

Aspirated fluids are centrifuged and the sediment is used to inoculate media selected on the basis of the body site from which it was obtained. Cul de sac aspirates are inoculated on blood, chocolate and MacConkey agar plates and two loops are placed into thioglycollate broth. A gram stain is prepared. The chocolate plate is incubated in a candle jar for 48 hours and the blood and MacConkey agar plates are incubated aerobically for 18 to 48 hours. The thioglycollate remains at 35°C. for three days if negative for growth.

If *C. fetus* is suspected, the plates are incubated at least five days before interpreting them as negative.

### BACTERIOLOGY

Colonies of *C. fetus* are tiny, punctate, and nonhemolytic on blood agar. The organism is a microaerophilic to anaerobic gram negative, slender curved bacillus, which may appear with one curve, or be "S" or "gull" shaped with a flagellum at one or both poles. It exhibits a corkscrew motion. *C. fetus* does not ferment or oxidize carbohydrates. M.R., V.P., gelatin, indole and H<sub>2</sub>S reactions are negative. It is,

however, catalase and oxidase positive. The organism reduces nitrate.

The organism's reaction to antibiotics is shown in Table I.

Table I. ANTIBIOTIC SENSITIVITIES OF *C. FETUS*

<i>Antibiotic</i>	<i>Reaction</i>
Colimyxin	R
Pencillin	R
Polycillin	R
Kantrex	R
Streptomycin	S
Keflin	R
Tetracycline	S
Chloromycetin	S
Furadantin	S
Polymyxin B	R
Negram	R

\*R-Resistant S-Sensitive

#### DISCUSSION

*C. fetus* has been known to cause abortion and infertility in cattle and sheep.<sup>2</sup> It has been suggested that sheep are natural carriers for vibriosis and that they harbor the organisms in the gall bladder. The organisms also remain alive for long periods in the testes of bulls without causing symptoms.

Human infection by *C. fetus* has been well established. The organisms have been isolated from patients with septicemia<sup>4,5</sup>, septic arthritis,<sup>6</sup> meningitis,<sup>7</sup> endocarditis,<sup>8</sup> lung abscess,<sup>9</sup> acute dysentery,<sup>10</sup> enteritis and pericarditis.<sup>1</sup> Of interest, the organism has not been isolated from the stool.

Patients infected with this organism usually present with a febrile illness, often associated with chills and relapsing illnesses. Small infants, elderly people, patients with debilitating diseases, and patients receiving steroids and immunosuppressive therapy are particularly susceptible to vibriosis. Leukemia, diabetes mellitus, cirrhosis of the liver, lymphosarcoma, etc, have been implicated as underlying diseases which are complicated by *C. fetus* infections.

People without preexistent diseases are rarely infected by this organism. A patient with acute dysentery and another with skin pustules were otherwise healthy before they developed *C. fetus* infections.<sup>10</sup> The organism has been

isolated from the vagina in asymptomatic women during pregnancy.

The transmission of the disease in humans is obscure. In animals, coitus has been suggested but not conclusively proved. Infected patients, having worked with animals, suggest a possible mode of transmission of the organism to humans. Soonattrakul, et al.<sup>11</sup> suggested that raw liver may be the source of *C. fetus* infection in humans.

In the patients described by the authors, one was on therapy for multiple myeloma and the other two were apparently in good health before the organism was isolated. A direct correlation between the patient with multiple myeloma and *C. fetus* infection is noted, but it is impossible to correlate the findings in the remaining two patients.

Since interest has been generated in human infection caused by *C. fetus*, Franklin and Bruce<sup>4</sup> feel that it may become more important as an "opportunistic invader." They state that the incidence of human infections by *C. fetus* may increase because of greater use of immunosuppressive drugs and an increase in the number of transplant services.

All physicians must be aware of the infectious potential of this organism, since it may complicate the clinical course of patients with debilitating illnesses.

#### SUMMARY

*Campylobacter fetus* was isolated from three patients at Howard University Hospital during a nine year period. The bacteriology, clinical course of the disease, and a brief literature review are presented.

#### LITERATURE CITED

1. LENNETTE, E.H. and E.H. SPAULDING and J.P. TRUANT. Manual of Clinical Microbiology. Second edit. American Society for Microbiol., Wash., D.C. 1974, pp. 390-392.
2. McFADYEAN, F and S. STOCKMAN. Report of the Departmental Committee Appointed by the Board of Agriculture and Fisheries to Inquire into Epizootic Abortion. Appendices to Parts 1 and 3, London, Her Majesty's Stationary Office, 1909.
3. VINZENT, R., J. Dumas and N.P. CARD. Septicemic Grave au Cours de la Grasseuse due a un Vibron. Avortement Consecutif. Bull. Acad. Nationale Med., 131:90-92, 1947.

(Concluded on page 127)

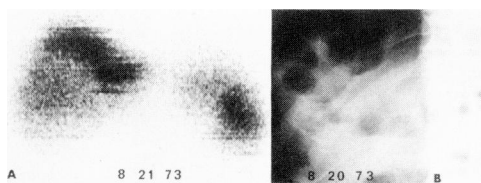


Fig. 2. Anterior view (A) of liver scan shows large area of decreased uptake involving the lower two-thirds of the right lobe. Flat plate (B) of abdomen demonstrates loop of large intestine in right upper quadrant.

4. inferior vena cava<sup>7</sup>
5. prominent rib cage
6. porta hepatis<sup>7</sup>
7. lordotic spine<sup>7</sup>
8. right kidney<sup>7</sup>
9. prominent right psoas muscle<sup>7</sup>
10. interposition of colon with or without stool

#### C. Extrahepatic disease processes

1. empysema, subphrenic abscess, phrenic nerve injury
2. massive splenomegaly, dilatation of splenic vein<sup>4</sup>
3. ascites
4. hematoma following trauma
5. adrenal tumor (primary, secondary) and cyst<sup>2</sup>
6. right renal tumor (primary, secondary)

#### cyst and polycystic kidney<sup>2</sup> 7. retroperitoneal nodal enlargement<sup>2</sup>

Awareness of the above mentioned causes for false defect in <sup>99m</sup>Tc sulfur colloid liver scan will significantly reduce false positive scan interpretations. When there is suspicion of such possibilities, examination of the patient after the scan, repeat scan after removal of possible causes and roentgenographic correlation are recommended.<sup>1</sup>

#### LITERATURE CITED

1. SEYMOUR, Q. and S.E. PUCKETT, SR. and J. EDWARDS. Pseudoabnormal Liver Scans Secondary to Residual Barium in the Bowel. *Amer. J. Roentgen.*, 107: 54-55, 1969.
  2. BOLICH, P.R. and I.B. TYSON. False-positive Liver Image due to Localized Hepatic Thinning. *Radiology*, 109: 139-140, 1973.
  3. WEINRAUB, J.M. False-positive Liver Scan caused by Dilated Splenic Vein. *J. Nucl. Med.*, 15: 142-143, 1974.
  4. FREEMAN, L.M. and C.H. MENG, P.M. JOHNSON, et al. False-positive Liver Scans caused by Disease Processes in Adjacent Organs and Structures. *Br. J. Radiol.*, 42: 651-656, 1969.
  5. MESCHAN, I. *Roentgen Signs in Clinical Practice*. Philadelphia, Pennsylvania, W. B. Saunders Company, 1966, pp. 1200.
  6. FRIMANN-DAHL, J. *Roentgen Examinations in Acute Abdominal Diseases*. Springfield, Illinois, Charles C Thomas, Publisher, 1960, pp. 55-56.
  7. COVINGTON, E.D. Pitfalls in Liver Photoscans. *Amer. J. Roentgen.*, 109: 745-748, 1970.
- 
- (Sampson et al., from page 136)
4. FRANKLIN, B. and D.D. ULMER. Human Infection with *Vibrio Fetus*. *West. J. Med.*, 120:200-204, 1974.
  5. PUBLIO, T. and A. McDONALD and E.H. KASS. Septicemia Caused by *Vibrio Fetus*. *Arch. Intern. Med.*, 126:306-308, 1970.
  6. KILO, C. and P.O. HAGEMANN and J. MARZI. Septic Arthritis and Bacteremia due to *Vibrio fetus*. *Am. J. Med.*, 38:962-971, 1965.
  7. COLLINS, H.S. and A. BLEVINS and E. BENTER. Protracted Bacteremia and Meningitis due to *Vibrio fetus*. *Arch. Intern. Med.*, 113:361-364, 1964
  8. LOEB, H. and J. BETTAG, N. YUNG, et al. *Vibrio fetus* Endocarditis. *Am. Heart J.*, 71:381-386, 1966.
  9. LAURENCE, R. and A.F. NIBBLE and S. LEVIN. Lung Abscess Secondary to *Vibrio fetus*. Malabsorption Syndrome and Acquired Agammaglobulinemia. *Chest*, 60:191-194, 1971.
  10. MANDEL, A.D. and R.C. ELLISON. Acute Dysentery Syndrome Caused by *Vibrio fetus*. *J.A.M.A.*, 185:536-539, 1963.
  11. SOONATTRAKUL, W. and B. ANDERSON and J. BRYNER. Raw Liver as a Possible Source of *Vibrio fetus* Septicemia in Man. *Am. J. Med., Sci.*, 261:245-249, 1971.

#### INTERNATIONAL SICKLE CELL ANEMIA SYMPOSIUM IN ABIDJAN

The interest and activity of African physicians and research workers in medical problems related to sickle cell anemia was reflected in an international symposium on sickle cell anemia held in Abidjan, capital of the Ivory Coast, West Africa, January 27-29, 1975. Countries represented were Ivory Coast, Togo, Italy, Algeria, France, Nigeria, Belgium, Dahomey, Ghana, England, Greece, Cameroon, Senegal, Zaire, Switzerland and the United States.

Physicians from American based Sickle Cell Centers in Los Angeles, Chicago, Detroit, Cincinnati, Atlanta, Boston and Washington, D.C. presented papers at the meeting. These included Dr. Roland B. Scott of Howard University and Dr. Paul McCurdy of Georgetown University.