

## Malignant Islet Cell Adenoma in a Pancreatic Cyst\*

### Report of a Case

JOHN H. WINSTON, JR., M.D.

*Staff Surgeon, Veterans Administration Hospital,  
Tuskegee, Alabama*

**C**YSTIC lesion of the pancreas are relatively uncommon. Malignant islet cell adenomas of the pancreas occurring in cysts are extremely rare. Its occurrence was reported in only one instance in Thigpen's series.<sup>1</sup> Because of the rarity of this lesion, the following case study is presented.

#### CASE REPORT

On February 20, 1963, a 44-year-old male veteran was admitted to the hospital with a two-day history of nausea and vomiting. Vomitus was bright red in color, consisting of about 1000 cc and preceded a mild bout of alcoholism. There was a history of two other episodes of hematemesis, none of which required transfusions. Recurrent epigastric pain for four to five years prior to this admission with an x-ray diagnosis of duodenal ulcer were prominent features of his past history. The patient had also been hospitalized on several previous occasions for recurrent psychotic episodes.

Physical examination revealed a well nourished, well developed male in no acute distress. Blood pressure 120/80, pulse 88, respirations 20. All physical findings were within the limits of normal except for mild epigastric pain on deep palpation.

Laboratory findings were within normal range except for his 12-hour night gastric secretions, which revealed a quantity of 1700 cc, total acidity 45 degrees, and free Hcl 35 degrees. Radiographic examination revealed a duodenal ulcer.

Hospital course: After symptomatic and supportive care, the patient was explored on March 15, 1963, and a large cystic mass was noted presenting through the gastro-hepatic ligament. A cystogastrostomy, gastroenterostomy, vagotomy, and a biopsy of cyst were performed.

The patient's postoperative course was uneventful except that he presented signs of afferent loop obstruction and subsequently was re-explored on April 5, 1963, and revision of the gastroenterostomy was performed. At this exploration the previously noted cystic mass was completely drained, leaving only a stalk of fibrous tissue extending from the stomach to the body of the pancreas—just distal to the superior mesenteric vessels.

In the operative interval, the pathological diagnosis of malignant islet cell carcinoma of the pancreas was

made. The patient was thus discharged and followed up at frequent intervals. He gained weight and returned to his job. His only complaint was a periodic sense of epigastric fullness which lasted for a brief period, with occasional vomiting.

The patient was readmitted to the hospital on March 17, 1964 at which time there were no unusual physical findings. His laboratory work was normal. The patient was reexplored on April 8, 1964, and a partial pancreatectomy, subtotal gastrectomy, and splenectomy were performed. At exploration, no evidence of regional or distant spread was present. An orange size cystic-like meaty mass was present, extending from and attached to the lesser curvature of the stomach to the body of the pancreas located just distal to the superior mesenteric vessels. Again, his postoperative course was uneventful. The pathological study of the removed specimen confirmed the original diagnosis.

#### DISCUSSION

Malignant islet cell adenoma with cystic formation or in a pancreatic cyst is a rare lesion, seldom seen pathologically and is almost never diagnosed preoperatively unless associated with functioning

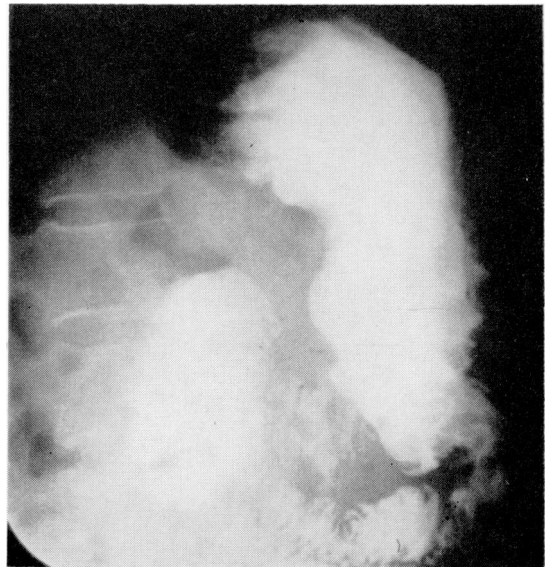


Fig. 1. Preoperative upper GI revealing increased retrogastric space. (Right lateral of abdomen.)

\* Published with the permission of the Chief Medical Director, Veterans Administration, who assumes no responsibility for opinions expressed by the author.

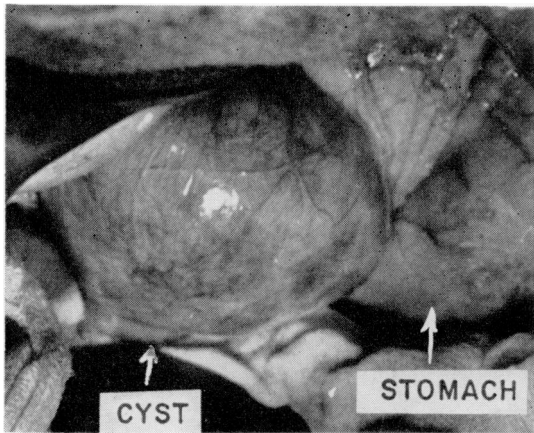


Fig. 2. Appearance of cyst during first surgical procedure.

islet cell tissue manifested by the hypoglycemic syndrome or ulcerogenic diathesis. The presence of a cyst can be suspected by a palpable cystic-like upper abdominal mass with x-ray findings of typical displacement of the stomach. In retrospect, this patient did have suggestive x-ray findings and his recurrent episodes of psychosis made one suspicious of a functioning adenoma with hypoglycemic episodes manifested as and mistaken for psychotic behavior. Repeated studies in an attempt to elicit Whipple's triad did not bear this out. The presence of a duodenal ulcer with an associated cystic malignant islet cell adenoma without the high gastric acidity and with no recurrence of ulcer postoperatively would mitigate against the prospect of an ulcer diathesis secondary to pancreatic adenoma.

It is apparent from this case that this type of neoplasm is slow in growth. Pathologically, differentiation as to the malignancy or benignancy is difficult, and at times impossible. Malignancy can only be proved if there is spread to contiguous or distant organs. Even though proof of malignancy is lacking, surgical excision following the principles of good cancer surgery is indicated.

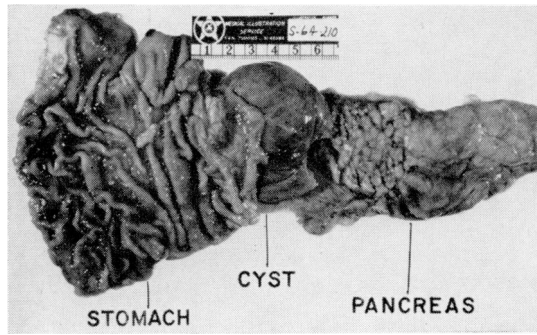


Fig. 3. Removed specimen one year following original procedure.

#### SUMMARY

A case of malignant islet cell adenoma occurring in a cyst has been presented. The lesion is rare and many cases over an extended period of time must be accumulated before its life history and best method of treatment can be formulated.

#### LITERATURE CITED

1. THIGPEN, F. M. A Pathologic Study of Cyst of the Pancreas (Thesis). Mayo Foundation, Graduate School, University of Minnesota, 1940.

#### SEE ALSO

1. DUFF, G. L. Pathology of Islet Cell Tumors of Pancreas. *Am. J. Med. Sci.* 203:437, 1942.
2. FRANTZ, V. K. Tumors of Islet Cells with Hyperinsulinism—Benign, Malignant and Questionable. *Ann. Surg.* 112:161, 1940.
3. HANSEN, J. R. Islet Cell Carcinoma of Pancreas. *Ann. Surg.* 155, no. 4, 1962.
4. HARDY, J. D. On the Causes of Death in Cancer. *Surg. Clinic of North America* 42:305, 1962.
5. HOWARD, M. R. Hyperinsulinism and Islet Cell Tumors of Pancreas. *Internat'l Abstr. Surg.* 90, 1950.
6. MCCLURE, R. D. and B. E. BUSH. Experiences with Islet Cell Tumors. *Arch. of Surg.* 50:59, 1949.
7. SURARKI, MARSHALL and HORN. Tumors of Pancreatic Islet Cancer 13:349, 1960.
8. WARREN, K. W. Islet Cell Tumors and Hyperinsulinism. *Surg. Clinic of North Am.* 42:709, 1962.
9. WHIPPLE, A. O. Tumors of Pancreas. *Canad. Med. J.* 66, 1952.

**FUN FOR THE ENTIRE FAMILY**  
**70th Annual Convention,**  
**National Medical Association,**  
**Cincinnati, Ohio, August 9-12, 1965**