

The Use of Mice in the Sereny Test as a Virulence Assay of Shigellae and Enteroinvasive *Escherichia coli*

SOMAY YAMAGATA MURAYAMA,† TAKASHI SAKAI, SOUICHI MAKINO, TAKESHI KURATA, CHIHIRO SASAKAWA, AND MASANOSUKE YOSHIKAWA*

Institute of Medical Science, University of Tokyo, Minato-ku, Tokyo 108, Japan

Received 16 September 1985/Accepted 31 October 1985

We examined the possibility that mice could be used in the Sereny test instead of guinea pigs or rabbits. Although the reactions in mice were more transient and not as pronounced as those in guinea pigs, mice indeed could be used to distinguish even macroscopically between virulent and avirulent shigellae. Virulent enteroinvasive *Escherichia coli* strains were also positive for the mouse Sereny test. We described the macroscopic and microscopic appearance of the mouse eyes. Thus, mice are recommended for use in the Sereny test, particularly when a large number of samples are to be tested.

The pathogenic potential of shigellae is associated with their ability to invade and proliferate in the epithelial cells of the colonic mucosa (1, 3). However, humans and subhuman primates are the only natural hosts for shigellae. Efforts to find an alternative laboratory assay for shigellae were partially realized with the development of tests such as the provocation of keratoconjunctivitis in guinea pigs (Sereny test) (6, 7).

Recent application of genetic and recombinant DNA technology to the studies on the virulence determinants of the shigellae have revealed that at least three regions on the chromosome and the gene(s) on the large 100- to 140-megadalton plasmid (4) are required for full virulence for bacillary dysentery to be provoked. Intraepithelial invasion and proliferation require only the large plasmid (8). Since the plasmid is required but not sufficient for a positive Sereny test, it presumably represents the requirements of bacillary dysentery more strictly and in this sense would be more suitable as the model for human bacillary dysentery than any other method testing the invasiveness. However, guinea pigs and rabbits are not suitable for genetic and molecular biological studies of the virulence determinants because they are large and expensive and require a large space for breeding. The purpose of this study is to show that mice can be used in the Sereny test instead of guinea pigs or rabbits.

Fresh bacteria grown overnight at 37°C on Penassay agar plates (antibiotic medium No. 3; Difco Laboratories, Detroit, Mich.) were harvested and suspended in Penassay broth to give approximately 5×10^{10} cells per ml. The mice were infected with about 1×10^8 to 5×10^8 viable cells per eye. The right eye received the bacterial inoculum, and the left eye received sterile saline as a control. First, we tentatively used C3H brown mouse strain for Sereny test, but this was done in vain. Then we proceeded to select a suitable mouse strain from commercially available female albino strains BALB/c, DDD, ICR, dd, ddY, and ddN at 6 weeks of age. *Shigella flexneri* 2a 50 carrying a 140-megadalton invasive plasmid, designated as pMYSH6000, was used. BALB/c (specific pathogen-free [SPF]), DDD (SPF), ICR (SPF) and

conventional ICR and ddN strains were highly susceptible to eye infection with *Shigella* cells. All mice tested (five of five) were macroscopically positive. The conventional ddY strain was macroscopically less susceptible (four positive of five tested), and the conventional dd strain was insensitive. The conventional ddY and ddN strains gave macroscopically weak inflammatory reactions. Thus, three conventional strains, dd, ddY, and ddN, were all less suitable for this purpose than the three SPF strains. No difference in susceptibility to shigellae was observed when mice were grouped by sex and by age (within 4 to 21 weeks of age). Even retired mice after delivery could be used. The strains other than the albino strain also gave good results, but albino strains were preferable to the others for observation. We never encountered any type of infection in the left eye which was dripped with sterile saline as a control, indicating that the infection does not shift from the right to the left eye. We bred a group of five mice in a cage and never encountered any type of infection in the left eye, indicating that no shift occurs from the infected eye of a mouse to the uninfected eye of another mouse in the same cage.

The macroscopic changes in mice eyes were those characteristic of conjunctivitis. Redness and swelling of the palpebra, hyperemic bulbar conjunctiva, and bulbo-palpebral adhesion are those commonly observed in SPF mice strains. BALB/c and DDD strains most often provoked stronger conjunctivitis than the other strains. In addition, epidermal hyperemia from eyes to nose, presumably due to nasolacrimal inflammation was observed, particularly more often in DDD and ICR strains than in the others. These inflammatory changes culminated at 18 to 24 h after infection and disappeared as determined macroscopically within 3 to 7 days. No protection was detected against the second challenge with the same shigellae cells even in the infected eye of mice at 2 weeks after the initial infection.

For histopathological observation, eyes of mice, including conjunctiva and cornea, were removed at 24 and 48 h after infection, respectively, fixed in 10% buffered Formalin, and embedded in paraffin. The sections were stained with hematoxylin plus eosin, Gram stain, and periodic acid-Schiff stain. Submucosal areas of palpebral conjunctiva and the fornix were edematously swollen, and infiltration of inflammatory cells, dominant in polymorphonuclear leukocytes,

* Corresponding author.

† Present address: Department of Microbiology, Meiji College of Pharmacy, Setagaya-ku, Tokyo 154, Japan.

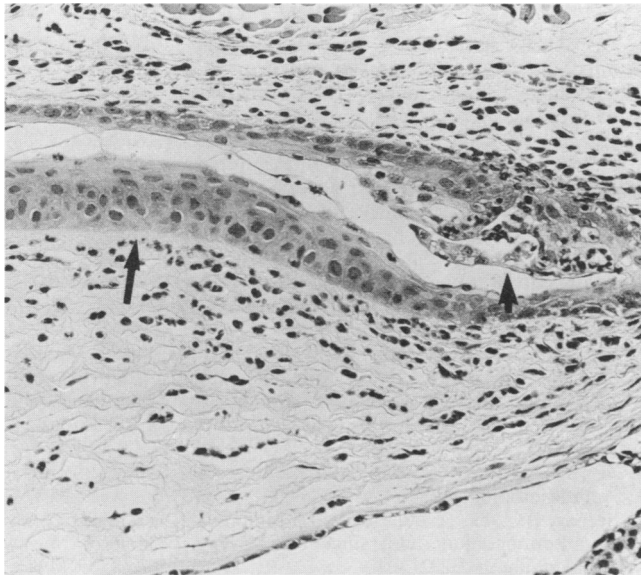

FIG. 1. Histology of palpebral conjunctiva, fornix, and cornea. Infiltration of polymorphonuclear leukocytes into the epithelial layer of fornix (◆) and submucosal areas of conjunctiva and cornea (◀). Magnification, ×66.

and small loci of hemorrhages were observed at 24 h after infection with Sereny-positive strains. Gram stain revealed the presence of accumulated gram-negative bacilli in the submucosal connective tissue. Degeneration with or without invasion of polymorphonuclear leukocytes and desquamation of epithelial layers of palpebral conjunctiva and fornix were found (Fig. 1). These pathological changes were more prominent in the fornix. In the cornea, degeneration of epithelial cells and infiltration of inflammatory cells in the substantia propria, especially at 48 h after infection, were observed without clear change of corneal endothelia. Inflam-

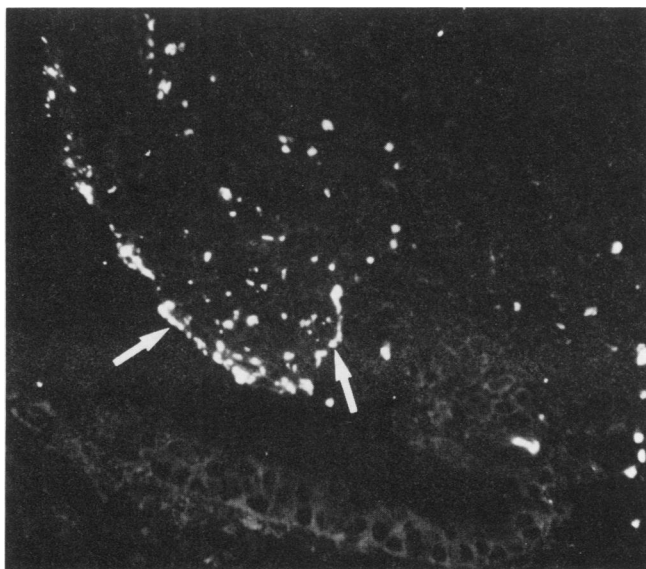


FIG. 2. Indirect immunofluorescence of a paraffin section of the epithelial layer of the fornix. Specific antigen (◁) to *S. flexneri* 2a. Magnification, ×132.

TABLE 1. Mouse Sereny test with shigellae and enteroinvasive *E. coli* strains

Organism and serovar	Strain code	Results of Sereny test	Type of plasmid	Source ^a
<i>S. flexneri</i>				
1a	35	-	None	A. Nakamura
1b	33	-	None	A. Nakamura
2a	1	+	Intact	Ebara Hospital
2a	2	+	Intact	Ebara Hospital
2a	4	+	Intact	Ebara Hospital
2a	7	+	Intact	Ebara Hospital
2a	34	+	Intact	A. Nakamura
2a	50	+	Intact	M. Takasaka
2a	6	-	Deleted	Ebara Hospital
2a	32	-	None	A. Nakamura
3b	67	-	Deleted	Our collection
3c	56	-	Deleted	M. Takasaka
4a	47	-	Deleted	M. Takasaka
4a	48	-	Deleted	M. Takasaka
4a	54	-	Deleted	M. Takasaka
5b	65	-	None	M. Takasaka
<i>S. dysenteriae</i>	73	+	Intact	H. Watanabe
<i>S. boydii</i>	74	+	Intact	A. Nakamura
<i>S. sonnei</i>	75	+	Intact	H. Watanabe
<i>E. coli</i>				
0124	931-78	+	Intact	B. R. Davis
0124	1457-75	+	Intact	B. R. Davis
0124	3144-67	-	None	B. R. Davis
028ac	14185-83 HU	+	Intact	L. R. Trabulsi
029	127-82 FAV	+	Intact	L. R. Trabulsi
0124	280-83 FAV	+	Intact	L. R. Trabulsi
0136	282-83 FAV	+	Intact	L. R. Trabulsi
0143	267-83 FAV	+	Intact	L. R. Trabulsi
0144	88-82 FAV	+	Intact	L. R. Trabulsi
0152	2855-83 HU	+	Intact	L. R. Trabulsi
0164	Saigon	+	Intact	L. R. Trabulsi
0167	226-83 FAV	+	Intact	L. R. Trabulsi

^a Sources: Ebara Hospital, Ebara Hospital, Tokyo, Japan; A. Nakamura, Department of Bacteriology, National Institute of Health, Tokyo, Japan; M. Takasaka, Department of Veterinary Science, National Institute of Health, Ibaraki, Japan; H. Watanabe, Department of Microbiology, Institute of Public Health, Tokyo, Japan; B. R. Davis, via T. Pal, Institute of Microbiology, University Medical School, Pecs, Hungary; L. R. Trabulsi, via T. Pal, Institute of Microbiology, University Medical School, Pecs, Hungary.

matory cell infiltration was also seen in the ciliary body and iris, but no pathological changes were observed in the retina. For the indirect immunofluorescence assay, the sections were picked up on the neoprene-coated slides (2), dried, and used for protease digestion. *S. flexneri* 2a-specific rabbit antibody, a kind gift from Denka-Seiken Co., Tokyo, Japan, was applied at a 1:20 dilution for the first step of the reaction, and goat anti-rabbit immunoglobulin G conjugated with fluorescein isothiocyanate (Miles-YEDA Ltd., Rehovot, Israel) was used with dilution at 1:20 for the second step. Thus, specific antigen of *S. flexneri* 2a was detected in the epithelial layer of the fornix at 24 h after infection (Fig. 2) but not at 48 h. Isolation and characterization of the plasmid DNA was as described previously (5).

S. flexneri 2a 50, as described above, and each strain of *Shigella dysenteriae*, *Shigella boydii*, and *Shigella sonnei* gave positive results both in guinea pigs (Hartley albino; body weight, 300 g) and in mice. Additional strains of *S. flexneri* and enteroinvasive *Escherichia coli* were collected, and the correlation between positive Sereny tests and the possession of the intact invasion plasmid was examined.

Only when strains carried the intact invasion plasmid were the Sereny tests in mice positive, and either loss or deletion of the plasmid resulted in negative Sereny tests (Table 1).

The results presented above seem to be satisfactory for our original purpose. The evidence for bacterial invasion and proliferation in epithelia, key characteristics of the virulence of shigellae (1, 3), was provided by the fluorescent antibody technique and histopathological observations. The parallelism between the possession of the intact invasion plasmid and positive Sereny tests in mice was complete. In the past no successful results have been reported. This was presumably because previously no critical technique existed which could easily detect such a large invasion plasmid in shigellae, and a moderately virulent culture consisting of a mixture of a large number of avirulent and a small number of virulent cells might be used because in our experience, it is rather difficult to obtain by chance fully virulent broth cultures consisting only of plasmid-bearing cells (5).

This study was supported by grant B 59480159 provided by the Ministry of Education, Science, and Culture of the Japanese government.

We are grateful to the individuals and the hospital listed in Table 1 for their generous gifts of strains and also to Akiko Nakamura, Haruo Watanabe, and Masao Takasaka for fruitful discussion and valuable technological advice.

LITERATURE CITED

1. **Gemski, P., Jr., and S. B. Formal.** 1975. Shigellosis: an invasive infection of the gastrointestinal tract, p. 165-169. *In* D. Schlesinger (ed.), *Microbiology—1975*. American Society for Microbiology, Washington, D.C.
2. **Kurata, T., R. Hondo, S. Sato, A. Oda, and Y. Aoyama.** 1983. Detection of viral antigens in formalin-fixed specimens by enzyme treatment. *Ann. N.Y. Acad. Sci.* **420**:192-207.
3. **LaBrec, E. H., H. Schneider, T. J. Magnani, and S. B. Formal.** 1964. Epithelial cell penetration as an essential step in the pathogenesis of bacillary dysentery. *J. Bacteriol.* **88**:1503-1518.
4. **Sansonetti, P. J., D. J. Kopecko, and S. B. Formal.** 1982. Involvement of a plasmid in the invasive ability of *Shigella flexneri*. *Infect. Immun.* **35**:852-860.
5. **Sasakawa, C., K. Kamata, T. Sakai, S. Murayama, S. Makino, and M. Yoshikawa.** 1986. Molecular alteration of the 140-megadalton plasmid associated with the loss of virulence and Congo red binding activity in *Shigella flexneri*. *Infect. Immun.* **51**:470-475.
6. **Sereny, B.** 1957. Experimental keratoconjunctivitis shigellosa. *Acta Microbiol. Hung.* **4**:367-376.
7. **Sereny, B.** 1959. Acquired natural immunity following recovery from keratoconjunctivitis shigellosa. *J. Hyg. Epidemiol. Microbiol. Immunol.* **3**:292-304.
8. **Watanabe, H., and A. Nakamura.** 1985. Large plasmids associated with virulence in *Shigella* species have a common function necessary for epithelial cell penetration. *Infect. Immun.* **48**:260-262.