

Retinal Capillary Hemangioma Treated with Verteporfin Photodynamic Therapy and Intravitreal Triamcinolone Acetonide

Shin Cho Suh, MD, Sun Young Jin, MD, Seon Hee Bae, MD,
Chul Gu Kim, MD, Jong Woo Kim, MD

Department of Ophthalmology, College of Medicine, Konyang University, Myung Gok Eye Research Institute, Daejeon, Korea

Purpose: To report a case of retinal capillary hemangioma treated with verteporfin photodynamic therapy combined with intravitreal triamcinolone acetonide.

Methods: A 15-year-old female presented with metamorphopsia in the left eye for 7 days. Examination showed peripheral endophytic retinal capillary hemangioma, macular edema, and a best-corrected visual acuity of 20/50. The hemangioma and macular edema were treated with verteporfin photodynamic therapy and intravitreal triamcinolone acetonide.

Results: After 5 months of follow-up, involution of the hemangioma, reduction of macular edema, decrease of the feeder and draining vessel diameter, and improvement of best-corrected visual acuity to 20/25 was seen.

Conclusions: This verteporfin photodynamic therapy combined with intravitreal triamcinolone acetonide appeared to cause involution of the hemangioma with reduction in macular edema and improvement in visual acuity.

Korean Journal of Ophthalmology 21(3):178-184, 2007

Key Words: Retinal Capillary Hemangioma, Triamcinolone Acetonide, Verteporfin Photodynamic Therapy

Retinal capillary hemangioma (RCH) is an uncommon benign vascular tumor of the retina that can occur sporadically or in association with von Hippel-Lindau (VHL) syndrome. It was first described by Fuchs in 1882.¹⁻³ RCH is the most frequent and the earliest manifestation of VHL disease. Therefore, an ophthalmologist is frequently involved in the care of patients with VHL.⁴ It is not clear whether RCH that occurs without a family history⁵ is most commonly sporadic or most commonly represents an initial manifestation of VHL.^{6,7} RCH lesions often lead to visual loss secondary to hemorrhage into the vitreous, retina, or subretinal space. They can also lead to macular edema or exudative retinal detachment.⁸ Various forms of therapy have been attempted, but all have inherent problems with efficacy or with side effects such as transiently increased exudation or epiretinal membrane formation.⁸ A wide variety of treatment methods have been described for angiomas

lesions of the retina.⁸ Laser photocoagulation is effective for small angiomas proliferations but is not effective for large lesions, particularly those associated with pronounced exudation and hemorrhage.⁸ Even without overlying media opacity, thermal laser photocoagulation probably has a limited depth of treatment, leaving a large amount of viable and potentially problematic vessels.⁹ Cryotherapy may be more effective in eventually closing the vessels in thicker lesions, but this treatment is associated with a transient increase in the amount of exudation present.¹⁰ Radiation therapy has been used, but it has the potential for causing significant long-term complications. Photodynamic therapy (PDT) with verteporfin has been used for the treatment of choroidal neovascularization in age-related macular degeneration.¹⁰ When activated, verteporfin appears to cause oxidative damage to the vascular endothelial cells.⁹ This damage leads to vascular occlusion, although the surrounding tissue is preserved.⁸

We report the first case of retinal capillary hemangioma treated with verteporfin photodynamic therapy combined with intravitreal triamcinolone injection.

Case Report

A 15-year-old female presented with metamorphopsia in the left eye for 7 days. Her best-corrected visual acuity

Received: January 26, 2007 Accepted: August 6, 2007

Reprint requests to Seon Hee Bae, MD. Department of Ophthalmology, Konyang University Hospital, 685 Gasooon-dong, Seo-gu, Daejeon, 302-718, Korea. Tel: 82-42-600-8816; Fax: 82-42-600-9176, E-mail: ophthal73@hanmail.net

* This paper was presented as a poster at the 96th annual meeting of the Korean Ophthalmological Society in November 2006.

(BCVA) was 20/20 in the right eye and 20/50 in the left eye. The intraocular pressure was within normal limits bilaterally, and the results of anterior segment examinations were unremarkable. The right fundus was normal. The left fundus revealed mild macular edema and hard exudates (Fig. 1A). At the 5 o'clock periphery lay a circumscribed exophytic

retinal capillary hemangioma approximately 2.5 disc diameter (DD) with a prominent dilated and tortuous feeding artery and draining vein (Fig. 1B). Fluorescein angiography was performed, and fluorescein was evident in the dilated feeder arteriole (Fig. 1C,1D). The retinal tumor had fine capillary filling, which rapidly became homogeneous (Fig. 1C).

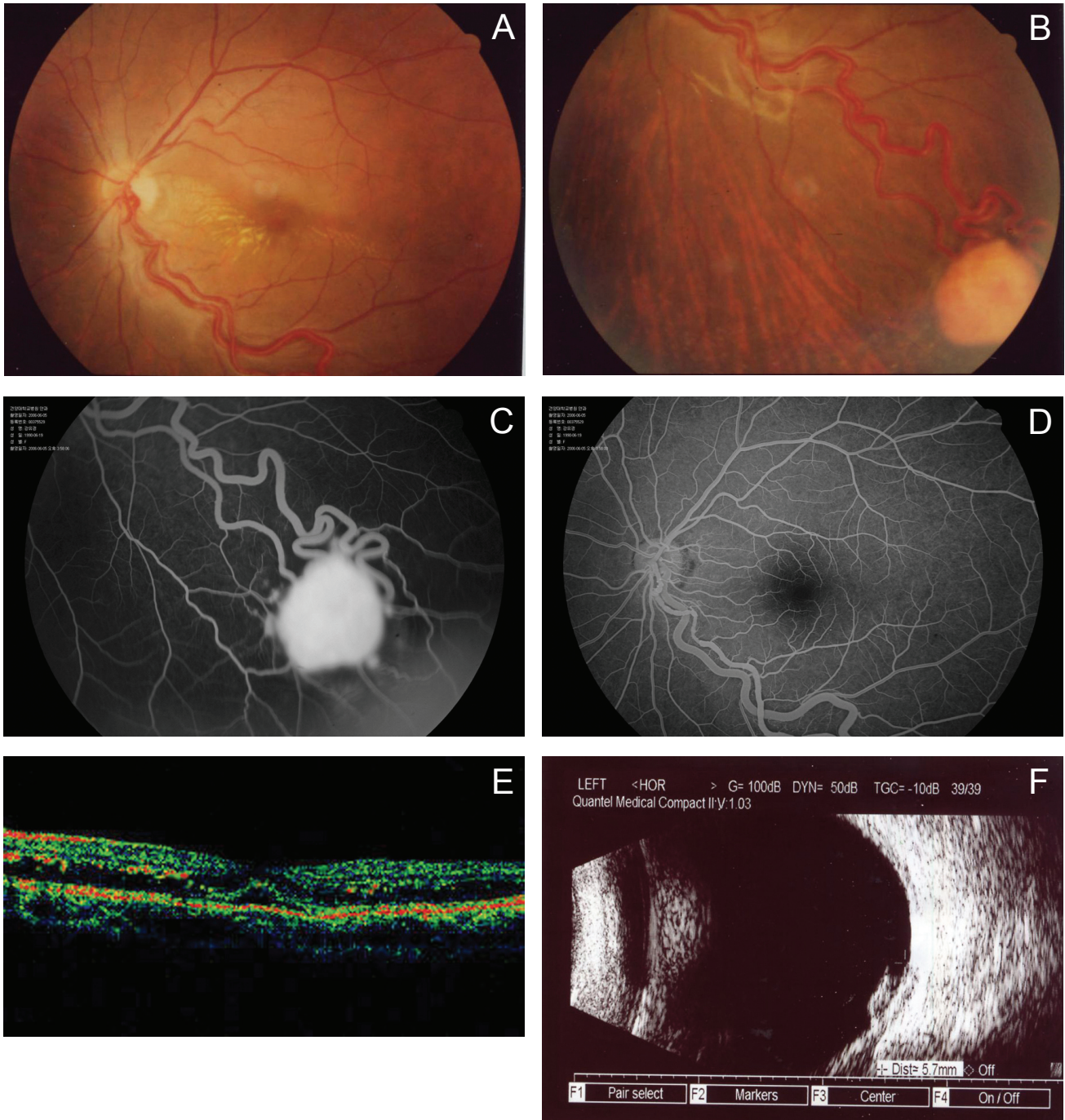


Fig. 1. First visit (pre-treatment). (A) The left fundus reveals mild macular edema and hard exudates with tortuous dilated vessel. (B) Circumscribed endophytic retinal capillary hemangioma appears at the 5 o'clock periphery with a prominent dilated and tortuous feeding artery and draining vein. (C, D) Progressive and complete filling of the hemangioma and the retinal vein becomes prominent. (E) OCT image demonstrating cystic macular edema at first visit. (F) B-scan shows a well-demarcated endophytic retinal lesion without choroidal effects.

The drainage vein became prominent in the venous phase, while the tumor demonstrated progressive hyperfluorescence with late leakage of dye into the surrounding structures (Fig. 1C). Optical coherence tomogram (OCT) of the fovea demonstrated cystic intraretinal edema (Fig. 1E).

B-scan ultrasonography demonstrated a well-demarcated exophytic retinal lesion without choroidal effects (Fig. 1F). The patient had no family history of ocular or systemic disease. Since retinal capillary hemangioma seemed a likely diagnosis, a systemic examination for VHL syndrome - including magnetic resonance imaging of the brain, abdominal computed tomography scan, and urine tests for catecholamines - was performed. Results were negative. Genetic testing for VHL syndrome was not performed.

Three days after initial PDT, intravitreal triamcinolone (IVTA) was planned. Verteporfin photodynamic therapy was performed using 6 mg/m² body surface area (BSA) of intravenous verteporfin delivered over 10 minutes. Fifteen minutes after the start of infusion, a laser light at 689 nm delivered 50 J/cm² at an intensity of 600 mW/cm² over 83 seconds using a spot size of 7500 μm directed to the hemangioma with a Mainster widefield contact lens.¹⁰

Three days after PDT, the patient returned to the hospital for IVTA. BCVA declined to 20/160 in the left eye and cystic intraretinal edema worsened, shown by optical coherence tomogram of the fovea (Fig. 2B). A pre-injection single drop of povidone-iodine (5%) solution was applied to the eye followed by thorough cleaning of the eyelashes and

application of a lid speculum. 0.5% proparacaine hydrochloride drops (Alcaine[®], Alcon) was applied topically. Triamcinolone acetonide in a single-use bottle (40 mg/ml, 1 ml bottle) was drawn into a 1-cc tuberculin syringe after cleansing the top of the bottle with an alcohol wipe. A separate 30-gauge needle was placed onto the syringe, which was then inverted to remove air bubbles. The excess triamcinolone was discarded until 0.1 ml (4 mg) remained in the syringe. The stab was given 3.5 mm from the limbus (pas plana) in the inferotemporal quadrant. The needle was removed simultaneously with the application of a cotton-tipped applicator over the entry site to prevent regurgitation of the injected material. Indirect ophthalmoscopy was used to check for central retinal artery (CRA) pulsation, a drop of topical antibiotic solution was administered, and the eye was patched. The patient was put on a post-injection course of topical antibiotic eye drops for a week.

Twelve days after PDT, BCVA had improved to 20/100 in the left eye and the retinal capillary hemangioma had undergone partial involution (approximately 2.5 DD). The feeder and draining vessel diameters had decreased by approximately 50% and 30%, respectively (Fig. 3A). Optical coherence tomogram of the fovea demonstrated improvement of cystic intraretinal edema (Fig. 2C).

Twenty-two days after PDT, BCVA had improved to 20/40 in the left eye and the retinal capillary hemangioma had regressed approximately 1.5 DD. The feeder and draining vessels were straighter but the diameter remained the same

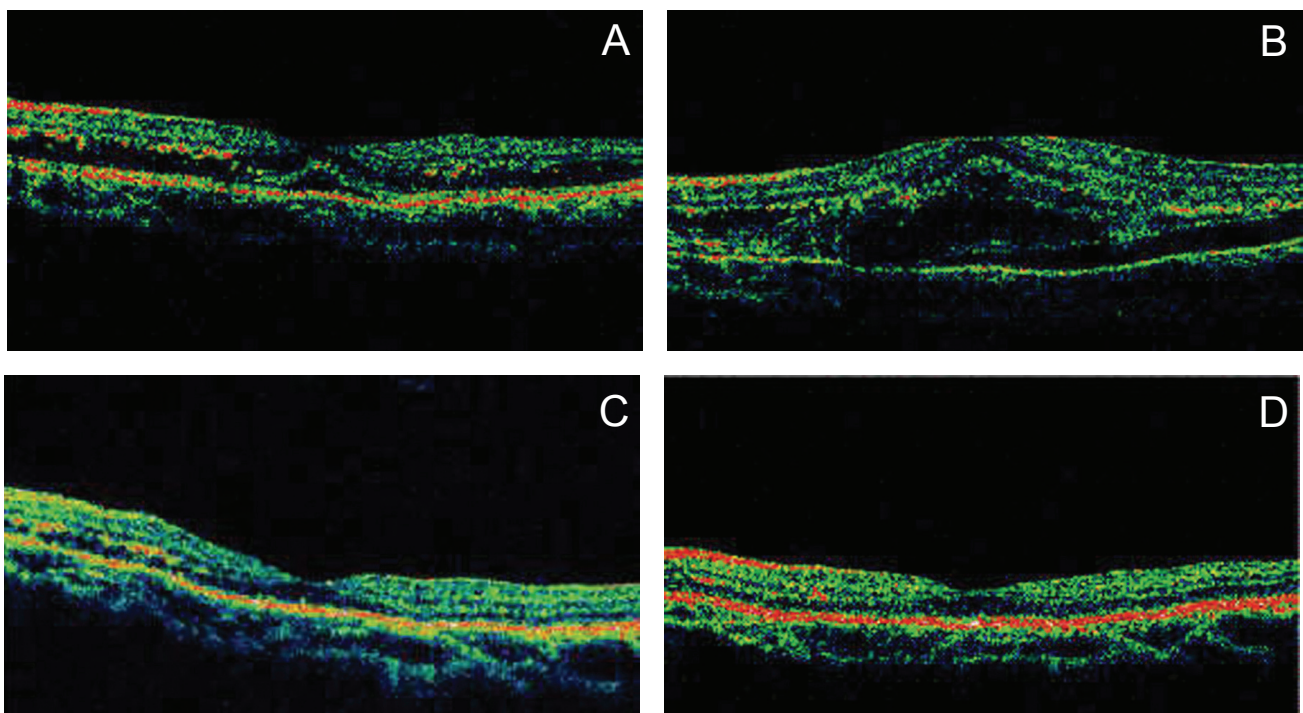


Fig. 2. Optical coherence tomogram images. (A) OCT image demonstrating cystic macular edema at first visit. (B) Worsened cystic macular edema after PDT treatment. (C) 12 days after PDT, improvement of cystic intraretinal edema after intravitreal triamcinolone acetonide. (D) 22 days after PDT, OCT image of the forvea shows restoration of the foveal contour.

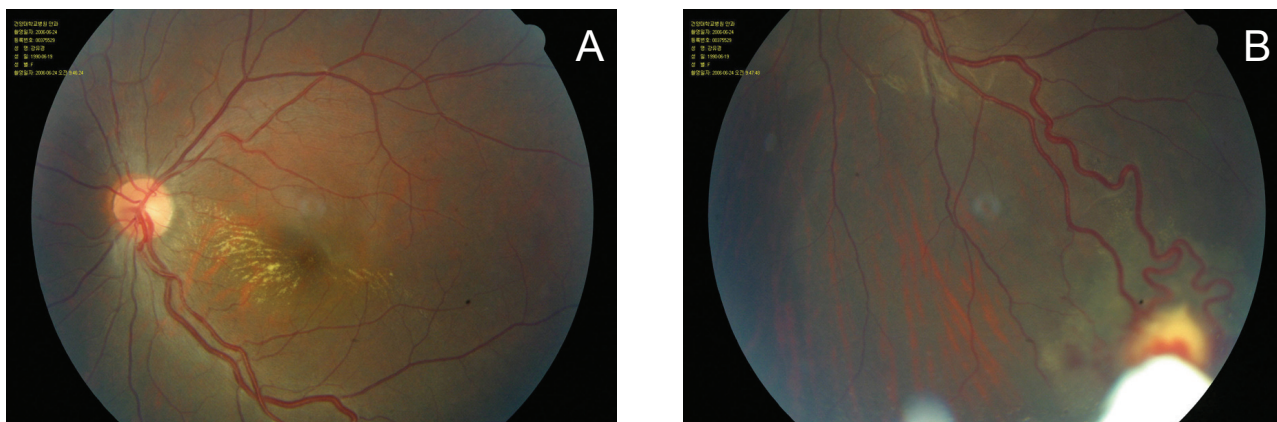


Fig. 3. 12 days after PDT. (A) The feeder and draining vessel diameters decreased. (B) The retinal capillary hemangioma underwent partial involution (approximately 2.5 DD). The whitish mass is triamcinolone acetonide.

(Fig. 4A). Fluorescein angiography demonstrated decreased early filling and late leakage of the hemangioma (Fig. 4C). The optical coherence tomogram demonstrated restoration of the foveal contour (Fig. 2D).

Three months after PDT, BCVA had improved to 20/30 in the left eye and the retinal capillary hemangioma had regressed approximately 1.0 DD (Fig. 5B). The macular hard exudate and edema had improved (Fig. 5A).

Five months after PDT, BCVA had improved to 20/25 in the left eye and the macular hard exudates had disappeared (Fig. 6A). Regular follow-up of the patient is planned.

Discussion

Retinal capillary hemangiomas (RCH) are capillary angiomatous hamartomas of the retina and optic nerve head.⁴ Capillary hemangioma (angiomas retinae) of the retina occurs in two ophthalmoscopically distinct forms: the peripheral lesion (known as the von Hippel tumor) and the juxtapapillary tumor.⁴ These tumors can occur anywhere in the fundus, although most commonly they are peripheral and endophytic.⁹ Either type of tumor may be either an isolated retinal vascular abnormality or one of the many systemic abnormalities in von Hippel-Lindau disease (VHL).⁴

Regardless of systemic association, the retinal tumors appear identical clinically and histopathologically.⁴ But patients with solitary retinal capillary hemangioma present a serious dilemma because RCH may or may not be associated with VHL disease. In a recent study, the probability of VHL disease in patients with solitary retinal capillary hemangioma was mathematically estimated to be 30% to 46%, but it varied from 45% in the preteen patients to less than 1% in those over 60 years old.^{11,12} Because the patient described in this paper is a young woman who showed peripheral exophytic retinal capillary hemangioma, she must be regularly and systemically examined for VHL syndrome.

Most RCH progressively enlarge and there is progressive subretinal exudation, frequently leading to total retinal

detachment and eventual blindness.¹³ Therefore, early detection and treatment of RCH is associated with good visual outcome.¹⁴ In general, the decision to treat RCH and the method of management is determined by the size, location, and associated findings, such as the extent of subretinal fluid, evidence of retinal traction, and overall effect or threat of clinical findings on the visual potential of the eye.² Most commonly, RCH is managed by observation, laser photocoagulation, cryotherapy, plaque radiotherapy, and vitreoretinal surgery.² All treatment options were discussed in detail with the patient. Because of the risk of hemorrhage and proliferative vitreoretinopathy with cryotherapy, and the limitations of laser photocoagulation in the presence of a large hemangioma with extensive subretinal fluid, verteporfin photodynamic therapy (PDT) was offered to the patient. The successful use of PDT in RCH has been reported by several authors.^{8,10} Atebara described three sessions of PDT for RCH in one patient, which resulted in decreased leakage during fluorescein angiography, but did not mention the degree of the tumor involution.¹⁰ Rodriguez-Coleman et al. reported two patients treated with PDT who showed marked and rapid regression of the angiomatous proliferation of vessels, but made no mention of the change in tumor size.⁸

Verteporfin PDT in the treatment of exudative RCH has theoretical advantages over conventional treatments of laser photocoagulation and cryotherapy.^{15,16} But the use of direct photocoagulation can potentially cause hemorrhage and exudative retinal detachment (ablatio fugax).^{4,17,18} On the other hand, the infrared-wavelength laser of PDT effectively penetrates through subretinal fluid and deeper into a large hemangioma than does laser photocoagulation.¹⁹ PDT may be less likely to result in hemorrhage and PVR than would cryotherapy.¹⁹ PDT actually represents the combination of pharmacologic therapy and laser-based therapy.²⁰ Photosensitizers have biophysical properties well-suited to the thrombotic closure of abnormal neovascularization while preserving normal physiologic vessels.²⁰

Photosensitizers also bind selectively to abnormal

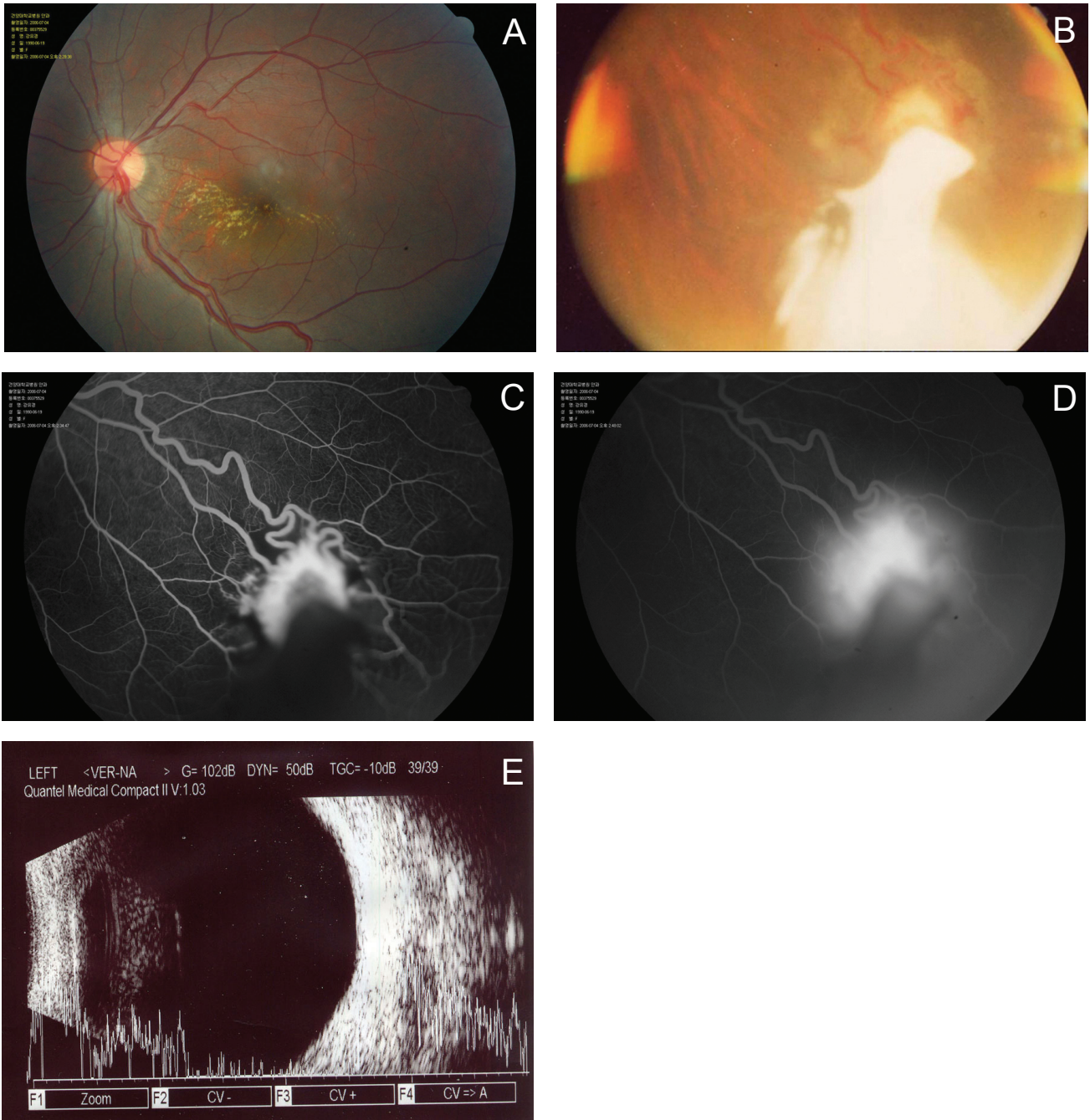


Fig. 4. 22 days after PDT. (A) The left fundus reveals decreased macular edema and hard exudates with a straighter vessel. (B) The retinal capillary hemangioma regressed approximately 1.5 DD. (C, D) Fluorescein angiogram demonstrating decreased early filling and late leakage of the hemangioma. (E) B-scan showing decreased endophytic retinal lesion.

neovascularization, the vessels of which express more lipoprotein receptors than do normal mature vessels.²⁰

During this patient's therapy, a temporary increase in macular exudation occurred after PDT, but other complications such as exudative retinal detachment were not found. Intravitreal triamcinolone acetonide was performed as a treatment for the increased exudation, whether the vascular tumor itself or the PDT caused the increase.²¹

Corticosteroids have a significant anti-angiostatic capacity.²² The primary mechanism of action of angiostatic steroids appears to be in aiding breakdown and blockage of the formation of capillary endothelial basement membranes.²² Triamcinolone acetonide appears to modulate the permeability and adhesion of human choroidal endothelial cells in culture.²³ Penfold et al. demonstrated that cytokine-induced expression of intracellular adhesion

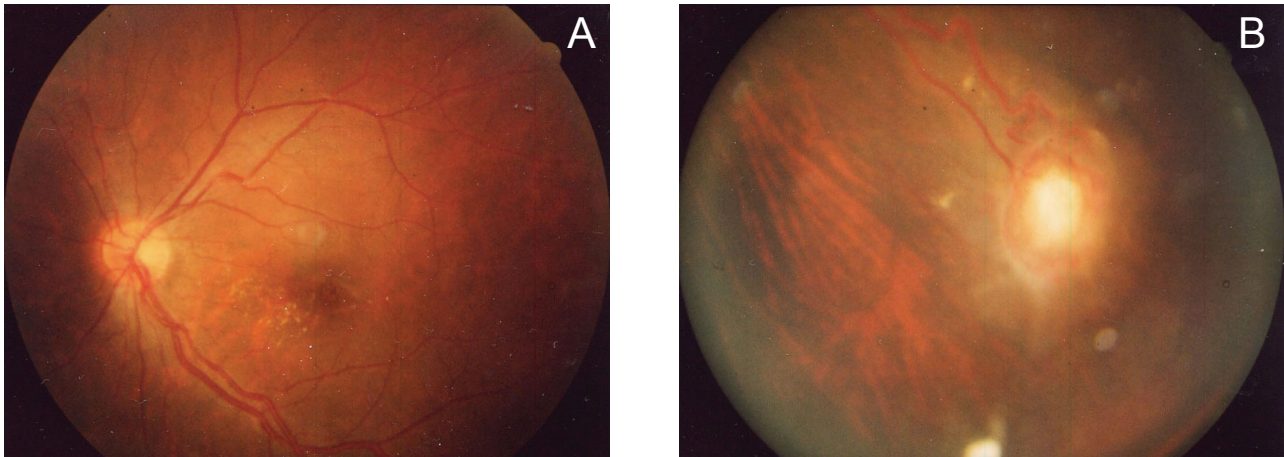


Fig. 5. 3 months after PDT. (A) The macular hard exudate and edema improved. (B) The retinal capillary hemangioma regressed approximately 1.0 DD.

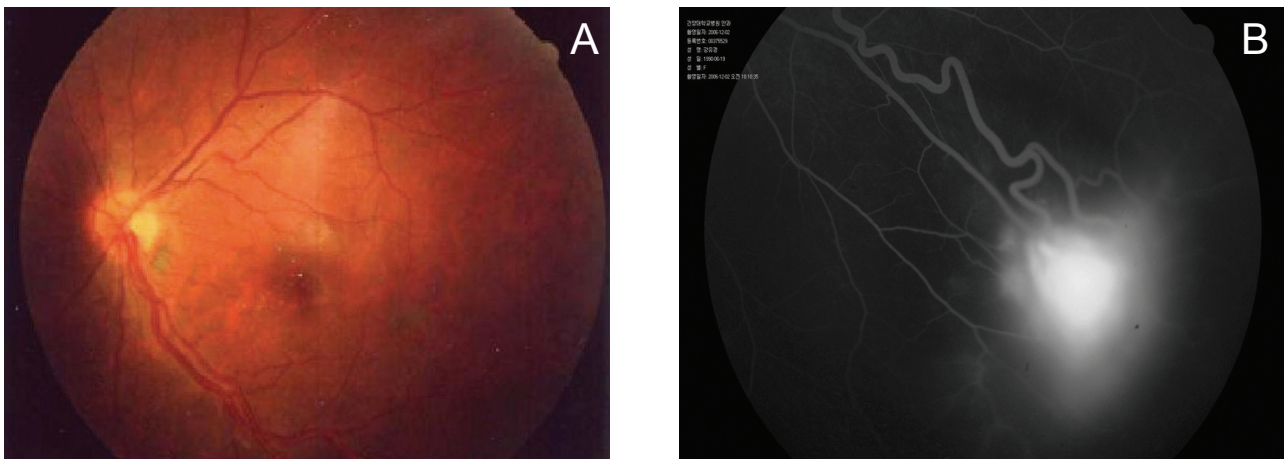


Fig. 6. 5 months after PDT. (A) The macular hard exudate and edema nearly disappeared. (B) Fluorescein angiogram demonstrating reduced fluorescence and leakage associated with the lesion.

molecule-1 is down-regulated by triamcinolone acetonide.²³ Wang et al. demonstrated that matrix metalloproteinases were down-regulated following incubation with triamcinolone, suggesting that the active remodeling of the extracellular matrix necessary for neovascularization can be inhibited.²⁴ Ciulla et al. showed that intravitreal triamcinolone acetonide completely inhibited laser-induced choroidal neovascularization in rats.²⁵ These experiments provide rationale for using triamcinolone acetonide to treat choroidal neovascularization in exudative macular degeneration and other retinal vascular diseases. RCH is a benign vascular tumor of the retina,¹⁻³ therefore, the rationale for this approach is to decrease the number of photodynamic treatments by combining the angiostatic properties of triamcinolone acetonide with the vascular occlusion induced by ocular PDT.

In this report of a single case of retinal capillary hemangioma with short follow-up, verteporfin PDT combined with intravitreal triamcinolone acetonide appeared to cause involution of the hemangioma with reduction in macular

edema and improvement in visual acuity. The authors believe the treatment modality used in this case was more effective than verteporfin PDT alone would have been.

References

1. Singh AD, Nouri M, Shield CL, et al. Retinal capillary hemangioma: a comparison of sporadic cases and cases associated with von Hippel-Lindau disease. *Ophthalmology* 2001;108:1907-11.
2. Singh AD, Shields CL, Shields JA. von Hippel-Lindau disease. *Surv Ophthalmol* 2001;46:117-42.
3. Moskowitz C, Edelstein C, Oh M, et al. Retinal capillary hemangioma in von Hippel-Lindau disease. *Can J Ophthalmol* 2005;40:192-4.
4. Ryan SJ. Capillary hemangioma of the retina and von Hippel-Lindau disease. In : Hinz BJ, Schachat AP, eds. *Retina*, 4th ed. Mosby: Elsevier Inc., 2006; v. 1. chap. 24
5. Gass JDM. *Stereoscopic atlas of macular disease. Diagnosis and treatment*, 4th ed. St. Louis: Mosby, 1997;850-65
6. Ridley M, Green J, Johnson G. Retinal angiomas: the ocular manifestations of von Hippel-Lindau disease. *Can J*

- Ophthalmol* 1986;21:276-83.
7. McDonald HR, Schatz H, Johnson RN, et al. Vitrectomy in eyes with peripheral retinal angioma associated with traction macular detachment. *Ophthalmology* 1996;103:329-35.
 8. Rodriguez-Coleman H, Spaide RF, Yannuzzi LA. Treatment of angiomatous lesions of the retina with photodynamic therapy. *Retina* 2002;22:228-32.
 9. Photodynamic therapy of subfoveal choroidal neovascularization in age-related macular degeneration with verteporfin. *Arch Ophthalmol* 1999;117:1329-45.
 10. Verteporfin in Photodynamic Therapy Study Group. Verteporfin therapy of subfoveal choroidal neovascularization in age-related macular degeneration: two-year results of a randomized clinical trial including lesions with occult with no classic choroidal neovascularization-verteporfin in photodynamic therapy report 2. *Am J Ophthalmol* 2001;131:541-60.
 11. Singh AD, Shields JA, Shields, CL. Solitary retinal capillary hemangioma: hereditary (von Hippel-Lindau disease) or non hereditary? *Arch Ophthalmol* 2001;119:232-4.
 12. Webster AR, Maher ER, Bird AC, Moore AT. Risk of multisystem disease in isolated ocular angioma (haemangioblastoma). *J Med Genet* 2000;37:62-3.
 13. Annesley WH Jr, Leonard BC, Shield JA et al. Fifteen year review of treated cases of retinal angiomatosis. *Trans Am Acad Ophthalmol Otolaryngol* 1977;83:446-53.
 14. Ridley M, Green J, Johnson G: Retinal angiomatosis: the ocular manifestations of von Hippel-Lindau disease. *Can J Ophthalmol* 1986;21:276-83.
 15. Shields JA, Shields CL. *Intraocular tumors, A text and atlas*. Philadelphia: WB Saunders, 1992;393-419
 16. Husain D, Gragoudas ES, Miller JW. *Principles and practice of ophthalmology*, 2nd ed. Philadelphia: WB Saunders, 2000;577-87
 17. Gass JDM. Treatment of retinal vascular anomalies. *Trans Am Acad Ophthalmol Otolaryngol* 1977;83:432-42.
 18. Welch RB. von Hippel-Lindau disease: the recognition and treatment of early angiomatosis retinae and the use of cryosurgery as an adjunct to therapy. *Trans Am Ophthalmol Soc* 1970;68:367-424.
 19. Atebara NH. Retinal capillary haemangioma treated with verteporfin photodynamic therapy. *Am J Ophthalmol* 2002;134:788-90.
 20. Ryan SJ. Capillary hemangioma of the retina and von Hippel-Lindau disease. In : Hinz BJ, Schachat AP, eds. *Retina*, 4th ed. Mosby: Elsevier Inc., 2006; v. 1. chap. 65
 21. Spaide RF, Sorenson J, Maranan L. Combined photodynamic therapy with verteporfin and intravitreal triamcinolone acetonide for choroidal neovascularization. *Ophthalmology* 2003;110:1517-25.
 22. Ryan SJ. Capillary hemangioma of the retina and von Hippel-Lindau disease. In : Hinz BJ, Schachat AP, eds. *Retina*, 4th ed. Mosby: Elsevier Inc., 2006; v. 1. chap. 55
 23. Penfold PL, Wen L, Madigan MC et al. Modulation of permeability and adhesion molecules expression by human choroidal endothelial cells. *Invest Ophthalmol Vis Sci* 2002;3125-30.
 24. Wang YS, Friedrichs U, Eichler W et al. Inhibitory effects of triamcinolone acetonide on bFGF-induced migration and tube formation in choroidal microvascular endothelial cells. *Graefes Arch Clin Exp Ophthalmol* 2002;240:42-8.
 25. Ciulla TA, Criswell MH, Danis RP, Hill TE. Intravitreal triamcinolone acetonide inhibits choroidal neovascularization in a laser-treated rat model. *Arch Ophthalmol* 2001;119:399-404.