

Role of Tetracycline in Pathogenesis of Chronic Candidiasis of Rat Tongues

CARL M. ALLEN,* FRANK M. BECK, FREDRICK A. LURIE,† AND H. MARK PINSKY‡

Ohio State University College of Dentistry, Columbus, Ohio 43210

Received 5 June 1984/Accepted 23 October 1984

Forty female Sprague-Dawley rats were randomly divided into two groups. Group 1 animals received tetracycline solution (0.1% during week 1 and 0.01% thereafter) as drinking water, as in previous studies. Group 2 animals received double-distilled demineralized water. Animals in both groups were inoculated orally with an equal number of viable, mucosally pathogenic *Candida albicans* organisms. After 20 weeks, inspection of the tongues showed gross lesions in 16 of the 20 animals in group 1 and 17 of the 20 in group 2. These lesions were confirmed histologically. No significant difference in the number of lesions was noted between the two groups. However, the lesions in group 1 animals were significantly larger than those in group 2 animals. These results suggest that, given this mucosally pathogenic strain of *C. albicans*, the establishment of a chronic infection of the rat tongue is apparently not influenced by tetracycline-treated drinking water as administered in this study. This suggests that antibiotic exposure is not an essential factor in the pathogenesis of this lesion. A larger lesion area, however, does appear to be related to the use of tetracycline solution as drinking water.

Candidiasis of the human oral cavity has typically been related to either a change in the host defense mechanism (e.g., patients receiving steroid therapy) or a change in the microbial ecology (e.g., patients receiving antibiotics) (5, 10). Due to the latter relationship, the induction of experimental oral candidiasis in the rat has been considerably enhanced, according to some investigators (7-9), by the administration of tetracycline in the drinking water of the animals.

Previous studies (1-3) have included tetracycline-treated drinking water as a component of the experimental design. However, after the identification of possible strain-related differences in the mucosal pathogenicity of *Candida albicans* (1), we felt that the role of tetracycline in the pathogenesis of chronic oral candidiasis in the rat should be examined again, using a strain of *C. albicans* with known ability to cause mucosal infection.

MATERIALS AND METHODS

Animals. Forty female Sprague-Dawley rats (average weight, 200 g) were randomly divided into two groups, marked with ear notches, and housed at five animals per stainless steel cage. Standard laboratory chow was provided ad libitum. The rats in group 1 received a 0.1% tetracycline hydrochloride solution as drinking water ad libitum during week 1 of the study, and this was reduced to a 0.01% solution thereafter. Group 2 rats received double-distilled demineralized water ad libitum for the duration of the experiment.

Inoculation. A strain of *C. albicans* which had produced infection in 80% of the animals in an earlier study (P. L. Pike, C. M. Allen, and F. M. Beck, *J. Dent. Res.* 63:192, 1984) was used for the inoculations. A slant of Sabouraud agar was streaked with the organism 72 h before inoculation

and allowed to incubate at room temperature (23°C). The yeast cells were rinsed from the slant with sterile physiologic saline, centrifuged for 10 min at $70 \times g$, and suspended to a concentration of approximately 5×10^7 CFU/ml.

A 0.1-ml volume of this suspension was introduced into the oral cavity of each rat with a tuberculin syringe fitted with a blunted 18-gauge needle. Inoculations were performed on three alternate days during week 2 of the study and at weekly intervals thereafter.

Culture. Cultures were obtained from all animals before the study was begun by gently rotating a sterile cotton swab in the oral cavity of each rat and streaking this onto a plate of Pagano-Levin agar for presumptive identification of *C. albicans*. Cultures were then obtained at 2-week intervals for the duration of the study, allowing at least 5 days to elapse from the time of the preceding inoculation to the time of culture. The number of candidal colonies per plate was recorded for each animal.

Observations and tissue handling. After 20 weeks, the animals were killed by N_2 - CO_2 asphyxiation, and the heads were removed. The palate and skull were split midsagittally, and the halves were reflected, resulting in a view of the tongue in situ from a dorsal aspect. After gentle rinsing of each tongue with water, photographs were taken, and the heads were then immersed in 10% buffered Formalin. After fixation, the tongues were excised, hemisected sagittally, and submitted for routine processing. Histologic sections (6 μ m) were prepared and stained with hematoxylin and eosin and by the periodic acid-Schiff method.

The photographs of the tongues were taken as color transparencies with a 35-mm camera mounted on a Zeiss OPMI microscope. Since the transparencies were taken at a standard magnification (10 \times), comparisons could be made regarding the relative sizes of the lesions. The transparency of each lesion was projected onto a sheet of paper taped to a wall at a set distance (1 m) from the slide projector. A tracing of the lesion was made and transferred to a sheet of acetate (7.5 mil [200 μ m]; C-Line Co., Des Plaines, Ill.). This tracing of the lesion was then cut from the sheet of acetate and weighed with a Mettler H 45 balance. Standard areas of

* Corresponding author.

† Present address: 1800 E. 105th St., Cleveland, OH 44106.

‡ Present address: York and Tabor Roads, Philadelphia, PA 19141.

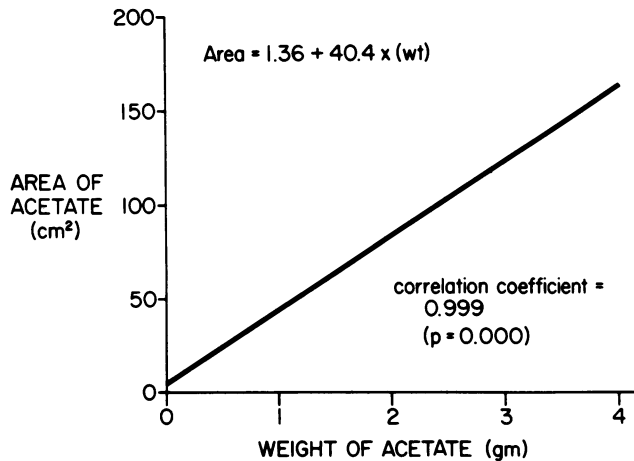


FIG. 1. Relationship of area to weight in 7.5-mil (200- μ m) acetate strips.

acetate, ranging from 9 to 144 cm², were also cut out and weighed. The relation between the standard areas and the weight of the acetate is shown in Fig. 1. By plotting the weights and areas of the standard acetate pieces, we could calculate the lesional areas by weighing the acetate cutouts (6).

Statistical analysis. Differences between groups in the proportion of candidal lesions were assessed by the Fisher exact probability test (11). Differences between mean estimated lesional areas were assessed by the independent Student *t* test (12).

RESULTS

Culture. Before the study was begun, *C. albicans* could not be recovered from the oral cavity of any animal. During weeks 2 to 4, virtually all of the animals were positive for *C. albicans* upon culture; however, the colony counts for a few animals dropped considerably during week 6 and remained at a low level for the remainder of the study. No apparent

difference was seen in the culture results between groups 1 and 2.

Gross observations. The rats in group 1 displayed grossly observable lesions in 16 of 20 animals (80%), whereas the rats in group 2 displayed lesions in 17 of 20 animals (85%). There was no significant difference ($P > 0.05$) in the proportion of candidal lesions between the tetracycline group (group 1) and the nontetracycline group (group 2). These lesions were consistently located on the midline dorsal area of the tongue in the region of the giant conical papillae (Fig. 2 and 3), and they appeared to be identical to lesions seen in previous studies (1, 2). No apparent differences were seen in the location, shape, or surface characteristics of lesions in group 1 animals compared with those in group 2 animals. However, after the mean lesion sizes were compared, group 1 animals had a significantly larger mean lesion area than group 2 animals (64.1 versus 45.8 cm²; $t = 2.18$, $df = 31$, $P < 0.05$).

Histologic observations. Microscopic evidence of candidal infection was seen only in those animals with grossly observable lesions. As reported previously (1, 2), these lesions exhibited hyperparakeratosis with a flattened epithelial surface morphology, acanthosis, and chronic inflammation involving the subepithelial connective tissue (Fig. 4). Fungal pseudohyphae could be demonstrated by staining by the periodic acid-Schiff method, and the organisms were consistently confined to the parakeratin layer (Fig. 5).

DISCUSSION

Antibiotic therapy, particularly tetracycline therapy, is frequently mentioned as a cause of human oral candidiasis (10). Reduction in the number of competing bacterial organisms is thought to allow an overgrowth of the yeasts and result in an overt fungal infection. It seems reasonable to assume that, if an animal model for oral candidiasis were to be developed, treating an animal with an antibiotic such as tetracycline might help establish such an infection. Russell et al. came to this conclusion in their studies with rats (7-9). Other investigators (1-3), basing their experimental design

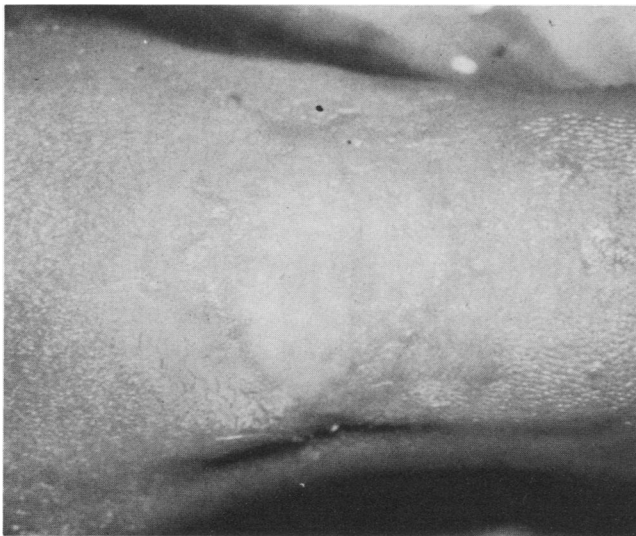

FIG. 2. Typical candidal dorsal tongue lesion seen in group 1 rats (tetracycline), with loss of normal papillary surface morphology.

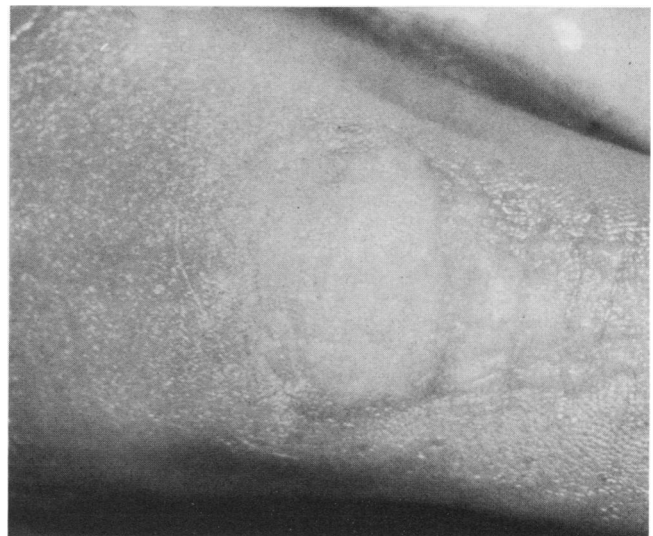

FIG. 3. Typical lesion observed in group 2 rats (no tetracycline). The similarity to the group 1 lesion is apparent.

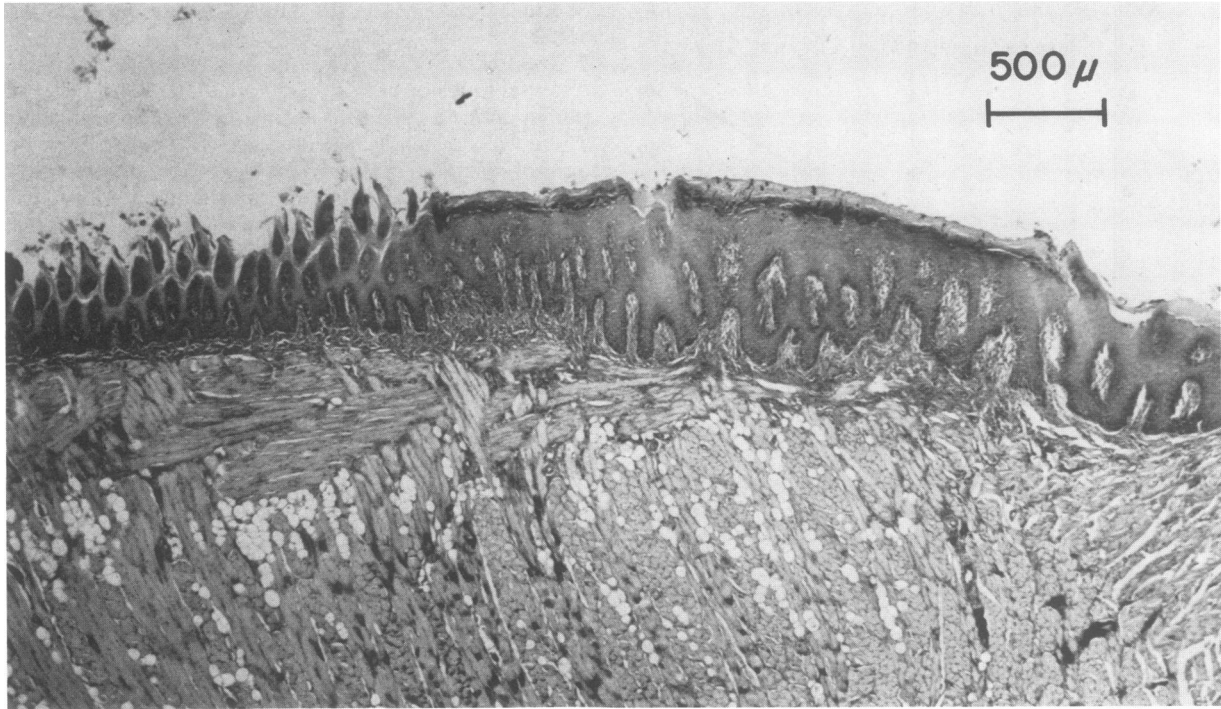


FIG. 4. Low-power photomicrograph of normal filiform papillae (left) merging with the flattened lesion mucosa which shows the characteristic hyperparakeratosis and acanthosis (periodic acid-Schiff method; original magnification, $\times 6.25$).

on that hypothesis, have included tetracycline solution as drinking water in their studies.

Previous work (1) has demonstrated an apparent spectrum of *C. albicans* pathogenicity for rat oral mucosa; some

strains show little ability to cause mucosal infection, whereas others exhibit a definite ability to induce mucosal lesions. It was postulated that, given a mucosally virulent strain of *C. albicans*, infection of the rat tongue mucosa might occur

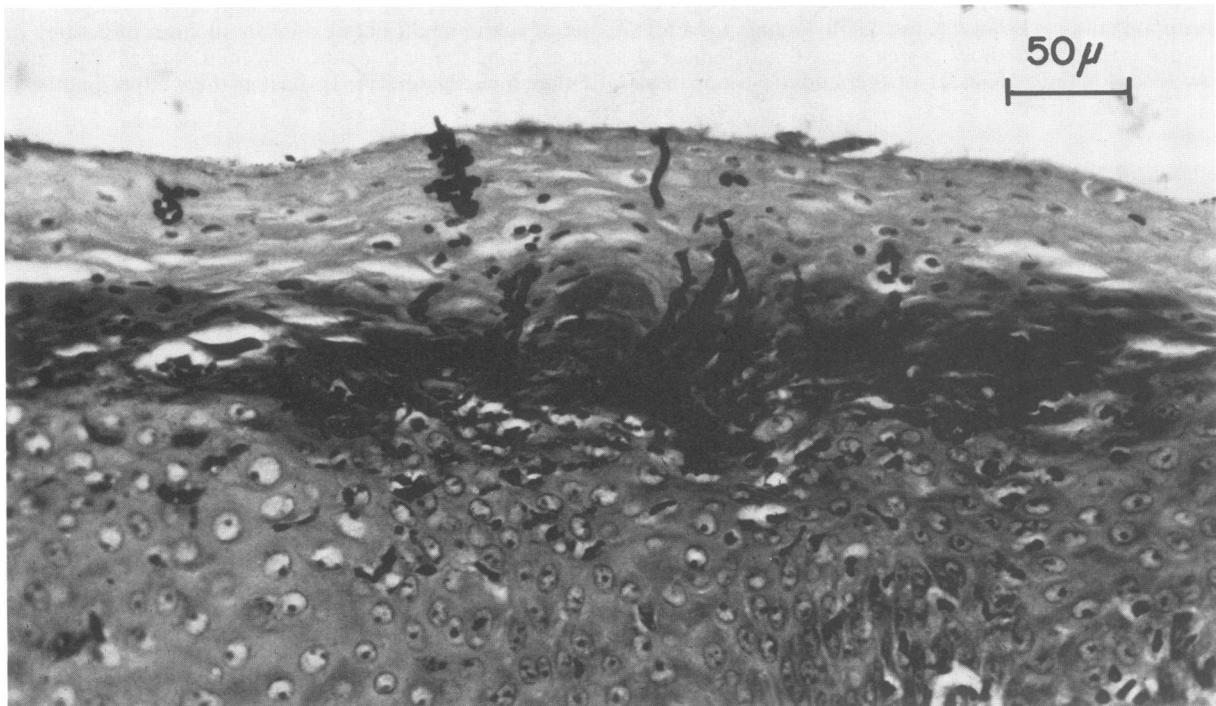


FIG. 5. High-power photomicrograph showing fungal hyphae penetrating the thickened keratin layer of the epithelium (periodic acid-Schiff method; original magnification, $\times 62.5$).

whether or not an antibiotic was used. Thus, group 1 animals received the usual schedule of tetracycline in their drinking water, while group 2 animals were given only water. Both groups were then inoculated on an identical schedule with the same concentration and quantity of *C. albicans*.

The results of this study demonstrated no significant difference between groups 1 and 2 in the number of animals infected both grossly and histologically. This indicates that tetracycline solution, when administered as drinking water as described above, has no apparent effect on the establishment of infection by a mucosally pathogenic strain of *C. albicans* administered as described above. The fact that the organism was able to cause infection without antibiotic suppression of the oral microflora is significant, particularly since it has been suggested that rats are less likely than humans to harbor *C. albicans* in the oral cavity (4).

The tetracycline solution apparently affected the size of the lesions as measured at 20 weeks of inoculation. This discrepancy in mean lesion area may reflect an increase in the growth rate of the tetracycline-associated lesions, since the number of competing bacteria was probably reduced. Furthermore, these results may be valid only for those strains of *C. albicans* exhibiting this particular degree of mucosal pathogenicity. Other less virulent strains of *C. albicans* may indeed require reduction in the number of the competing oral microflora by an antibiotic before infection can occur.

ACKNOWLEDGMENTS

We would like to express our appreciation for the technical support of Jacquelyn Shepherd, Patricia Bronsdon, and Eric Beck.

LITERATURE CITED

1. Allen, C. M., and F. M. Beck. 1983. Strain-related differences in pathogenicity of *Candida albicans* for oral mucosa. *J. Infect. Dis.* **147**:1036-1040.
2. Allen, C. M., G. G. Blozis, S. Rosen, and J. S. Bright. 1982. Chronic candidiasis of the rat tongue: a possible model for human median rhomboid glossitis. *J. Dent. Res.* **61**:1287-1291.
3. Fisker, A. V., C. R. Schiott, and H. P. Philipsen. 1982. Short-term oral candidosis in rats, with special reference to the site of infection. *Acta Pathol. Microbiol. Scand. Sect. B* **90**:49-57.
4. Jones, J. H., and C. Russell. 1974. The histology of chronic candidal infection of the rat tongue. *J. Pathol.* **113**:97-100.
5. Odds, F. C. 1979. *Candida* and candidosis, p. 82-86. University Park Press, Baltimore.
6. Ohashi, M., J. B. Woelfel, and G. C. Paffenbarger. 1966. Pressures exerted on complete dentures during swallowing. *J. Am. Dent. Assoc.* **73**:625-630.
7. Russell, C., and J. H. Jones. 1973. Effects of oral inoculation of *Candida albicans* in tetracycline-treated rats. *J. Med. Microbiol.* **6**:275-279.
8. Russell, C., and J. H. Jones. 1973. The effects of oral inoculation of the yeast and mycelial phases of *Candida albicans* in rats fed on normal and carbohydrate-rich diets. *Arch. Oral. Biol.* **18**:409-412.
9. Russell, C., J. H. Jones, and A. C. C. Gibbs. 1975. The carriage of *Candida albicans* in the mouths of rats treated with tetracycline briefly or for a prolonged period. *Mycopathologia* **58**:125-129.
10. Shafer, W. G., M. K. Hine, and B. M. Levy. 1983. *A textbook of oral pathology*, 4th ed., p. 393-394. The W. B. Saunders Co., Philadelphia.
11. Siegel, S. 1956. *Nonparametric statistics for the behavioral sciences*, p. 96-104. McGraw-Hill Book Co., New York.
12. Winer, B. J. 1971. *Statistical principles in experimental design*, 2nd ed., p. 26-41. McGraw-Hill Book Co., New York.