

## *Propionibacterium acnes* as a Cause of Aggressive Aortic Valve Endocarditis and Importance of Tissue Grinding: Case Report and Review

HULDRYCH GÜNTARD,<sup>1\*</sup> ADOLF HANY,<sup>2</sup> MARKO TURINA,<sup>3</sup> AND JÜRIG WÜST<sup>4</sup>

Division of Infectious Diseases, Department of Medicine,<sup>1</sup> and Clinic of Cardiovascular Surgery, Department of Surgery,<sup>3</sup> University Hospital of Zürich, CH-8091 Zürich, Department of Internal Medicine, Kantonsspital Winterthur, CH-8401 Winterthur,<sup>2</sup> and Department of Medical Microbiology, University of Zürich, CH-8028 Zürich,<sup>4</sup> Switzerland

Received 7 February 1994/Returned for modification 23 June 1994/Accepted 4 August 1994

**A case of prosthetic valve endocarditis with *Propionibacterium acnes* is described. The diagnosis was documented by histology and isolation of *P. acnes* from both blood and anulus tissue. Grinding of the tissue, which was first omitted to avoid contamination, was indispensable for cultivating the agent. The literature for *P. acnes* endocarditis is reviewed.**

*Propionibacterium acnes* is a microorganism that usually has a low level of virulence. Nevertheless, it is associated with serious infections like brain abscesses (14), osteomyelitis (2), endophthalmitis after intraocular surgery and lens implantation (21, 23), subdural empyema (4, 11, 25), cerebral shunt infection (6), parotid and dental infections (8), and infective endocarditis (IE) (1, 5, 7, 10, 12, 13, 15-17). The strongest risk factor for serious infection is the presence of foreign bodies (1). As a member of the normal skin flora, *P. acnes* is mostly a contaminant in cultures of wound and blood specimens. In clinical settings it is often difficult to distinguish between contamination and infection. We describe here a case of a prosthetic valve endocarditis with *P. acnes*. Furthermore, the methods of processing tissue samples to increase sensitivity for growth of bacteria are discussed and the literature of IE caused by *P. acnes* is reviewed.

A 73-year-old man underwent aortic valve implantation with a St. Jude Medical prosthesis to replace a biologic aortic valve implanted in 1985 for degenerative aortic insufficiency.

Three weeks postoperatively he developed fever, tiredness, headache, and right-side pleural effusion. Seven weeks after discharge, he again presented with chills and left-side hemiparesis. Transthoracic echocardiography showed free-floating masses on the St. Jude Medical valve. A first computed tomography scan of the skull was normal. A second computed tomography scan performed 2 weeks later showed subacute right-side supratentorial parietal and left-side infratentorial infarctions. On admission, his temperature was 36.8°C, his pulse was 76 beats per min, and his blood pressure was 125/75 mm Hg. Skin and lung examinations revealed no abnormalities. Cardiovascular examination showed a lateralized elevated maximum impulse, crisp prosthetic valve opening and closing sounds, and a grade 4/6 systolic ejection murmur over the entire precordium. Neurologic examination showed signs of sensorimotor left-side hemiparesis and urinary bladder retention. Vegetations and a paravalvular abscess in the region of the noncoronary sinus Valsalvae with a paravalvular aortic insufficiency were seen upon transesophageal echocardiography. Abnormal laboratory findings included a sedimentation

rate of 35 mm/h, a C-reactive protein concentration of 60 mg/liter, and a hemoglobin level of 11.1 g/dl. The leukocyte count was  $9.63 \times 10^6/\mu\text{l}$  with no shift to the left but a few toxic granules.

Three sets of blood samples for culture (one set consisting of an aerobic and an anaerobic bottle) were taken 1 day before the operation, and five sets were taken on the day of the operation. The St. Jude Medical aortic valve was replaced by an aortic homograft. The aortic anulus showed signs of prosthetic endocarditis, and an annular abscess, previously diagnosed by transesophageal echocardiography, was opened and debrided and tissue was sent for histologic and microbiologic investigations. Postoperatively, intravenous antibiotic therapy with amoxicillin-clavulanate (2.2 g every 8 h) and netilmicin (100 mg every 12 h) was started. At 7 and 8 days, respectively, after taking the blood cultures, three bottles (two anaerobic, one aerobic) of the first three sets and three bottles (two anaerobic, one aerobic) of the five sets of blood for culture taken 1 day later showed gram-positive rods that were later identified as *P. acnes* (see below). Fourteen days after the operation, the anaerobic cultures of the ground anulus tissue became positive with the same bacterium. The histologic staining of the anulus tissue showed large amounts of gram-positive rods which were morphologically consistent with *Propionibacterium* species (Fig. 1). After the MICs became known (penicillin, 0.016 mg/liter; amoxicillin-clavulanate, 0.032 mg/liter; cefoxitin, 0.016 mg/liter; chloramphenicol, 0.25 mg/liter; clindamycin, 0.047 mg/liter) the antibiotic therapy was changed to penicillin G (3 million IU every 4 h). This therapy was continued for another 6 weeks. The hemiparesis improved markedly. One year after implantation of the homograft and a double-chamber pacemaker because of bradycardic atrioventricular junctional heart rhythm the patient was found to be in good cardiac condition.

Blood (5 ml of blood per bottle) was cultured with the Septi-Chek (BCB) system (Roche Diagnostics, Basel, Switzerland). The aerobic bottle was vented, and a BCB slide was added, inverted, and observed daily. The anaerobic bottle was incubated anaerobically and subcultured only onto anaerobically incubated brucella sheep blood agar, kanamycin-vancomycin laked blood agar, and phenylethyl alcohol blood agar (18) (all media from Becton Dickinson [BBL], Basel, Switzerland) when growth could be observed macroscopically or when

\* Corresponding author. Mailing address: Department of Internal Medicine, Stadtspital Triemli, Birmensdorferstrasse 497, CH-8063 Zürich, Switzerland.

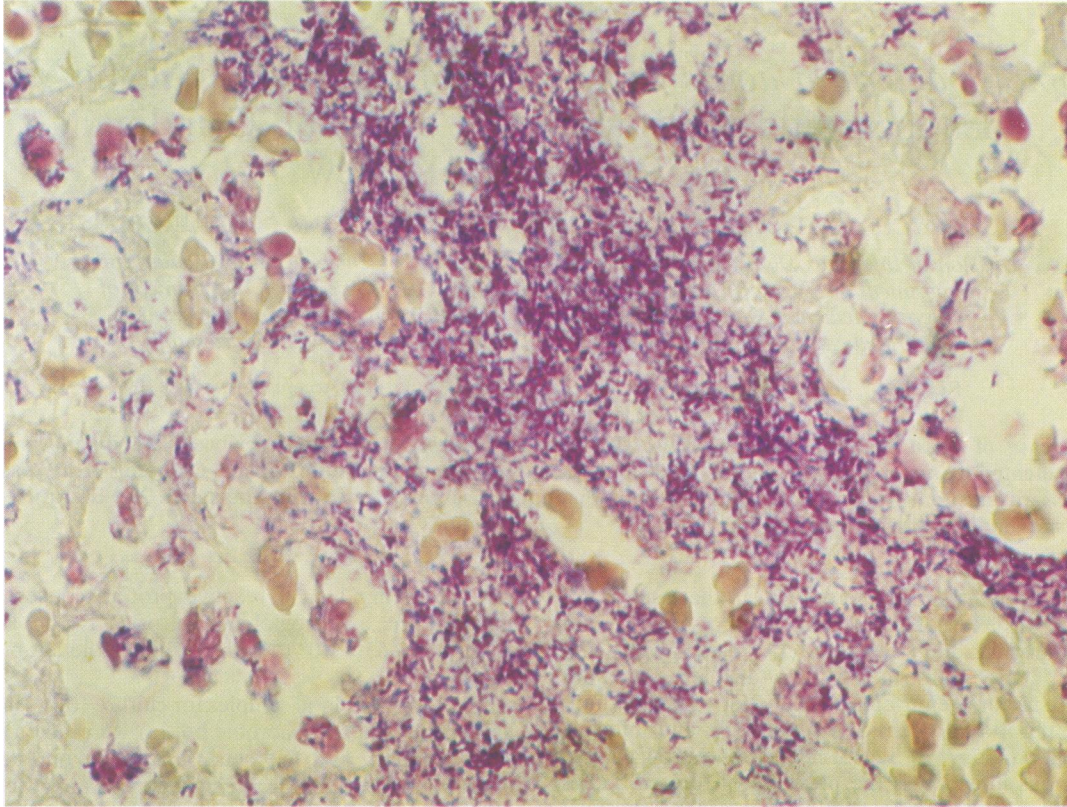


FIG. 1. Gram-stained section of the aortic anulus showing numerous gram-positive rods between fibrous tissue. Magnification  $\times 630$ .

the corresponding aerobic blood culture bottle was positive for growth.

The valves and tissues were transported in sterile containers without any medium. Unfortunately, transport was delayed 36 h by a transportation problem. Cultures of tissue samples were first done in brain heart infusion broth (BHI) incubated aerobically at 37°C without grinding to avoid contamination. Seven days after the operation, when histologic and blood culture results became positive but cultures of tissues and valves showed no growth, one-half of the tissue incubated in BHI was ground with a Ten Broeck tissue grinder and was cultured aerobically at 37°C with 5% CO<sub>2</sub> on Columbia sheep blood agar as well as on Columbia chocolate agar. Anaerobic cultures were set up on brucella sheep blood agar. Eventually, at 7 days after grinding and 14 days postoperatively, *P. acnes* was isolated from the ground tissue; the unground fraction remained negative.

Identification was done by using the RapID ANA II System (Innovative Diagnostic Systems, Atlanta, Ga.) in combination with gas-liquid chromatography of volatile and nonvolatile fatty acids from prerduced, anaerobically sterilized chopped meat broth containing carbohydrates (9). All isolates produced predominantly propionic acid and showed the same enzymatic pattern (RapID ANA code 004 655, resulting in *P. acnes* with an identification level of >99.9% and a biofrequency of 1 of 37). MICs were determined by the E-test procedure (AB Biodisk, Solna, Sweden) on brucella blood agar, which has been shown to have a good correlation with the methods of the National Committee for Clinical Laboratory Standards (24).

*P. acnes* is a rare cause of serious infections, and it is difficult to prove that it is the causative agent of serious infections in

general and of IE in particular (1). Of the 10 cases of *P. acnes* infection described in Table 1, only one case was undoubtedly caused by *P. acnes* (13). For three cases there were few details (1, 15). The remaining seven cases of IE seemed to be possibly or probably caused by *P. acnes* (5, 7, 10, 12, 16, 17).

In our patient two blood cultures each were found to be positive for *P. acnes* 7 and 8 days postoperatively. The tissue sample in BHI showed no growth at those times. The anulus tissue sample was ground only then. Seven days later the anaerobic cultures revealed growth of *P. acnes*, and the organism was biochemically identical to those from the blood cultures.

Recently, another patient underwent surgery for a mycotic aneurysm of the ascending aorta. Blood cultures showed *Salmonella enteritidis*, as did the crushed second half of the aortic tissue sample, in contrast to the compact first fragment, which did not. These two cases point out that grinding of tissue samples is necessary.

In our laboratory, during 1 year, we found *Propionibacterium* species in 138 blood culture sets from 129 patients (0.8% of all blood culture sets processed, or 5.1% of all positive blood cultures within 1 year). Contrary to the results of other investigators (1), two blood cultures positive for *Propionibacterium* species, found in 6 of 129 patients, were not found to prove serious infections. The present case report with four positive blood culture sets showed the only clinically significant infection caused by *P. acnes* during 1 year.

*Propionibacterium* spp. grew more often in anaerobic bottles ( $n = 95$ ), but nevertheless, they were isolated 66 times in aerobic bottles ( $P = 0.004$ ; chi-square test) and 25 times in both anaerobic and aerobic bottles. This finding supports the

TABLE 1. Review of the literature<sup>a</sup>

Reference	No. of cases	Valve type	Blood culture	Histology	Tissue culture	Therapy	Outcome	Quality of diagnosis
1	1	Prosthetic, aortic	All negative	Gram-positive rods	+	Pen, Gm	No follow-up	Probable
5	1	Native, aortic	3+ of ?	NA	NA	Cftx	Recovery	Possible
7	1	Prosthetic, aortic	3+ of 6	Gram-positive rods	+	Cm	Recovery	Proven
10	1	Prosthetic, aortic	2+ of 41	NA	NA	Pen, Gm	No follow-up	Possible
12	1	Prosthetic, aortic	4+ of ?	NA	NA	Pen, Gm, Vm, Tn	Recovery	Probable
13	1	Prosthetic, mitral	?	NA	NA	Tn	NA	Few details
15	2	NA	2+ of	NA	NA	NA	NA	Few details
16	1	Native, mitral	4+ of 12	NA	NA	Pen, Gm	Recovery	Probable
17	1	Prosthetic, mitral	3+ of ?	NA	NA	Pen, Gm	Relapse, recovery	Probable

<sup>a</sup> +, growth of *P. acnes*; ?, unknown total of bottles taken; NA, not available; Pen, penicillin; Cm, clindamycin; Em, erythromycin; Vm, vancomycin; Tn, teicoplanin; Cftx, cefotaxim; Gm, gentamicin.

<sup>b</sup> Not specified for endocarditis: penicillin, clindamycin, erythromycin, or a cephalosporin.

fact that *Propionibacterium* spp. can no longer be considered strict anaerobes (3). In the literature, even in large series of blood culture analyses (19, 20, 22), there are no available comparable data concerning the frequency of growth of *Propionibacterium* spp. in anaerobic or aerobic bottles.

The mean time of detecting growth of *Propionibacterium* species in blood cultures was 6.4 days in anaerobic bottles and 6.1 days in aerobic bottles (range, 2 to 15 days). In our case, blood cultures needed 7 and 8 days, respectively, to become positive, in contrast to the tissue sample, which needed 14 days. This points out the importance of incubating blood cultures as well as tissue samples 3 weeks or more in cases in which *Propionibacterium* infection is suspected. Therefore, communication between clinicians and the laboratory is very important.

We thank J. Schneider for providing the histologic stains. A. Sixth for the photographs, and A. von Graevenitz for careful review of the manuscript.

#### REFERENCES

1. Brook, I., and E. H. Frazier. 1991. Infections caused by *Propionibacterium*. Rev. Infect. Dis. 13:819-822.
2. Brook, I., and E. H. Frazier. 1993. Anaerobic osteomyelitis and arthritis in a military hospital—a 10-year experience. Am. J. Med. 94:21-28.
3. Cummins, C. S., and J. L. Johnson. 1986. Genus *Propionibacterium*, p. 1346-1353. In P. H. A. Sneath, N. S. Mair, M. E. Sharpe, and J. G. Holt (ed.). Bergey's manual of systematic bacteriology, vol. 2. The Williams & Wilkins Co., Baltimore.
4. Davidson, R. I. 1982. Intracranial epidural suppuration. The occult empyema. Neurosurgery 11:390-394.
5. Demachy, M. C., A. Eme, P. Charon, and J. F. Lefort. 1988. A propos d'un cas d'endocardite a *Propionibacterium acnes*. Med. Mal. Infect. 5:288-289.
6. Everett, E. D., T. C. Eickhoff, and R. H. Simon. 1976. Cerebrospinal fluid shunt infections with anaerobic diphtheroids (*Propionibacterium* species). J. Neurosurg. 44:580-584.
7. Fornaciari, G., E. Castagnetti, S. Maccari, P. Ragni, G. Carmeli, M. A. Parmeggiani, and A. C. Plancher. 1985. Un caso di endocardite infettiva da *Propionibacterium acnes*. Clin. Ter. 115:389-392.
8. Goldberg, M. H. 1971. *Corynebacterium*: an oral-systemic pathogen. Report of cases. J. Oral Surg. 29:349-351.
9. Holdeman, L. V., E. P. Cato, and W. E. C. Moore (ed.). 1977. Anaerobe laboratory manual, 4th ed. Department of Anaerobe Microbiology, Virginia Polytechnic Institute and State University, Blacksburg.
10. Horner, S. M., M. F. Sturridge, and R. H. Swanton. 1992. *Propionibacterium acnes* causing an aortic root abscess. Br. Heart J. 68:218-220.
11. Kaufman, D. M., M. H. Miller, and N. H. Steigbigel. 1975. Subdural empyema: analysis of 17 recent cases and review of the literature. Medicine (Baltimore) 54:485-498.
12. Lazar, J. M., and D. S. Schulman. 1992. *Propionibacterium acnes* prosthetic valve endocarditis: a case of severe aortic insufficiency. Clin. Cardiol. 15:299-300.
13. Lewis, J. F., and J. H. Abramson. 1980. Endocarditis due to *Propionibacterium acnes*. Am. J. Clin. Pathol. 74:690-692.
14. Mathisen, G. E., R. D. Meyer, W. L. George, D. M. Citron, and S. M. Finegold. 1984. Brain abscess and cerebritis. Rev. Infect. Dis. 6(Suppl. 1):101-106.
15. Nathwani, D., T. M. S. Reid, I. M. Gould, D. Golder, C. C. Smith, and J. G. Douglas. 1991. An open study of teicoplanin in the treatment of gram-positive infections. J. Chemother. 3:315-320.
16. O'Neill, T. M., R. Hone, and S. Blake. 1988. Prosthetic valve endocarditis caused by *Propionibacterium acnes*. Br. Med. J. 296:1444.
17. Scheel, O., A. Sundsfjord, P. Lunde, and B. M. Andersen. 1992. Endocarditis after acupuncture and injection—treatment by a natural healer. JAMA 267:218.
18. Sutter, V. L., D. M. Citron, M. A. C. Edelstein, and S. M. Finegold. 1985. Wadsworth anaerobe bacteriology manual, 4th ed. Star Publishing Company, Belmont, Calif.
19. Washington, J. A., II. 1975. Blood cultures: principles and techniques. Mayo Clin. Proc. 50:91-99.
20. Washington, J. A., II, and D. M. Ilstrup. 1986. Blood cultures: issues and controversies. Rev. Infect. Dis. 8:792-802.
21. Whitcup, S. M., R. Belfort, M. D. Desmet, A. G. Palestine, R. B. Nussenblatt, and C. C. Chan. 1991. Immunohistochemistry of the inflammatory response in *Propionibacterium-acnes* endophthalmitis. Arch. Ophthalmol. 109:978-979.
22. Wilson, W. R., W. J. Martin, C. J. Wilkowske, and J. A. Washington II. 1972. Anaerobic bacteremia. Mayo Clin. Proc. 47:639-646.
23. Winward, K. E., S. C. Pflugfelder, H. W. Flynn, T. J. Roussel, and J. L. Davis. 1993. Postoperative *Propionibacterium* endophthalmitis—treatment strategies and long-term results. Ophthalmology 100:447-451.
24. Wüst, J., and U. Hardegger. 1992. Comparison of the E test and reference agar dilution for susceptibility testing of anaerobic bacteria. Eur. J. Clin. Microbiol. Infect. Dis. 11:1169-1173.
25. Yoshikawa, T. T., A. W. Chow, and L. B. Guze. 1975. Role of anaerobic bacteria in subdural empyema. Report of four cases and review of 327 cases from the English literature. Am. J. Med. 58:99-104.