

# SPINAL MANIPULATION AND ANTERIOR HEADWEIGHTING FOR THE CORRECTION OF FORWARD HEAD POSTURE AND CERVICAL HYPOLORDOSIS: A PILOT STUDY

MARK W MORNINGSTAR, DC, CPBM<sup>a</sup>, MEGAN N. STRAUCHMAN, BS<sup>b</sup>, AND DARIN A WEEKS, ASCT<sup>a</sup>

<sup>a</sup>Private Practice of Chiropractic, Grand Blanc, MI. <sup>b</sup>DO Candidate, Kirksville College of Osteopathic Medicine, Kirksville, MO.  
Submit requests for reprints to: Mark Morningstar, DC, CPBM, 2393 Wildwood Circle Dr., Grand Blanc, MI 48439.  
Paper submitted December 10, 2002.

## ABSTRACT

**Objective:** To evaluate the effectiveness of Pettibon spinal manipulation and anterior headweighting for correct cervical hypolordosis and forward head posture, quantified by measurements taken from pre and post intervention lateral cervical radiographs.

**Methods:** A total of 15 subjects were selected for investigation at random. An initial seated lateral cervical radiograph was taken to evaluate forward head posture and the amount of cervical lordosis. A series of 3 manipulative procedures were performed, followed immediately by introduction of an anterior headweight device. This headweight device was worn for 5 minutes while walking on a treadmill. A post intervention seated lateral cervical radiograph was taken while each subject wore the headweight. Measurements of cervical lordosis and forward head posture were again quantified and compared to the initial radiographs.

**Results:** The average overall decrease in forward head posture among all subjects was 0.83 inches. The largest reduction in forward head posture was 1.25 inches. One subject failed to show any reduction. The largest and smallest improvements in the cervical lordosis were 23° and 4°, respectively. The average increase in cervical lordosis for all subjects was 9.9°.

**Conclusions:** This specific protocol was able to provide measurable improvement in cervical lordosis and reduction of forward head posture after only 1 session. However, it is not known which component, the spinal manipulation or the anterior headweighting, made the biggest impact. This study shows the immediate effects of spinal manipulation and headweighting combined. Future research should focus on the headweighting effects over a longer period of time. Additionally, anterior headweighting alone needs to be tested to evaluate its effective-

ness as a sole treatment intervention. (*J Chiropr Med* 2003;2: 51-54)

**KEY INDEXING TERMS:** Posture; Cervical Spine; Chiropractic Manipulation

## INTRODUCTION

Recent preliminary literature has suggested that the combined use of spinal manipulation and a novel headweight device may correct forward head posture and cervical hypolordosis (1,2). While there is still little evidence to demonstrate the pathognomonic factors resulting in these postural disorders, recent literature has shown the structural and functional consequences of these disease processes (3-9).

The purpose of the present study is to further evaluate the effectiveness of Pettibon spinal manipulation and anterior headweighting for restoring the normal cervical lordosis and reducing forward head posture after a single intervention.

## METHODS

Fifteen subjects were selected at random from a private spine clinic in Grand Blanc, MI. Since the present study does not consider the correlation of clinical symptoms, subjective complaints are not presented. An initial lateral cervical radiograph was taken of each subject. The subject was seated during the imaging procedure, consistent with the patient positioning procedures outlined by Jackson et al. (10).

The lateral cervical radiograph was evaluated for forward head posture and cervical hypolordosis. The forward head posture was analyzed according to analytical procedures outlined by Kapandji (11). Superior and inferior stress lines were drawn from the posterior body margins of the second and seventh cervical vertebrae

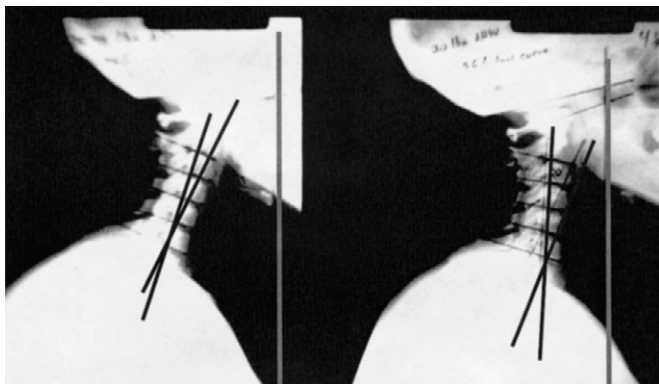


Figure 1. As an example, this subject, prior to intervention, had a 10° cervical lordosis when measured from the posterior vertebral bodies of C2 and C7 (radiograph on the left). Additionally, the initial forward head posture measured 1.88" or approximately equal to 28.75 lbs of head weight. Incidentally noted were 3 kyphotic cervical segments (C3, C4, C5). After the treatment intervention, the follow up radiograph revealed a 20° cervical lordosis and forward head posture that had been reduced to 1.00" or 20.00 lbs of head weight. Only 2 cervical segments were kyphotic post intervention (C3, C4).

(12,13). The angle created by the intersection of these 2 lines should be in the range of 34–42° (13). The same practitioner, to eliminate interexaminer variability, drew all of the lines on both the pre and post lateral cervical radiographs (Figure 1).

After the initial lateral cervical radiograph was taken, 3 manipulative procedures were administered to each subject. These manipulative procedures are specific to the Pettibon Technique (14), and are not taught in the main curricula at any of the various chiropractic colleges. The first manipulative procedure utilized is designed to force the atlanto-occipital joint into flexion, and is termed the -Z flexion adjustment. The second manipulative procedure was used to correct any extension restrictions at the cervicothoracic junction, and is called the -Z extension adjustment. These 2 adjustments were delivered with the aid of a drop piece designed by Pettibon. The third and final adjustment administered was designed to mobilize each of the cervical spinal joints so that all of the joints are involved in the curve restoration equally. This adjustment was delivered using a percussive instrument designed by Pettibon.

Immediately after the third adjustment, each patient was fitted with a headweight device containing 4 lbs of weight. The headweight is designed to cause a reaction by the cervicocollic and vestibulocollic reflexes (15), as well as the cervical mechanoreceptors located within

the uncovertebral joints of Luschka (16). Each subject proceeded to walk on a treadmill for 5 minutes to allow the cervical spine time for neuromuscular adaptation. After the treadmill exercise was completed, a post lateral cervical radiograph was taken with the headweight still on the subject. The same methods of positioning were used, and measurements for forward head posture and the cervical curve were recorded. If the position of the hard palate line was deviated up or down more than 2° compared to the initial radiograph, the post lateral cervical was immediately repeated.

## RESULTS

Once measurements were made on both pre and post lateral cervical radiographs on all 15 subjects, the pre and post values were compared to determine the change or correction, in degrees, of the cervical lordosis. The amount of reduced forward head posture was measured and recorded in inches.

When analyzing forward head posture reduction, the largest decrease was 1.25 inches. Only 1 of the subjects failed to show any reduction in forward head posture. The average reduction among all subjects was 0.83 inches. Table 1 provides the forward head posture reduction each of the 15 subjects. The largest restoration in the cervical lordosis was 23°, with the smallest being 4°. The average amount of restoration among all 15 subjects was 9.9°.

Prior to any chiropractic intervention, only 2 of the 15 subjects had a cervical lordosis within the normal range outlined by Harrison et al. (4,13). Once the manipulative and headweighting procedures were administered, a total of 6 subjects fell within the range of a normal cervical lordosis. Additionally, 2 subjects reached a cervical lordosis of 45°. With 2 exceptions, the largest increases in cervical lordosis restoration were accompanied by the largest reductions in forward head posture.

## DISCUSSION

Loss of the normal cervical curve has been linked with certain clinical presentations, such as tension and cervicogenic headaches. Patients experience faster recovery periods and receive better prognoses when a cervical curve is intact after certain types of surgical procedures. There should be little doubt, based on a growing body of evidence (17–21), that forward head posture and cervical hypolordosis are significant pathologic processes that should be corrected if they are diagnosed. Furthermore, there is a significant amount of research available concerning different methods of correcting these clinical

**TABLE 1**  
**PRE AND POST X-RAY MEASUREMENTS**

SUBJECT	PRE-TREATMENT RADIOGRAPH		POST-TREATMENT (STRESS) RADIOGRAPH		AMOUNT OF CORRECTION	
	FHP	CCURVE (DEGREES)	FHP	CCURVE (DEGREES)	FHP	CCURVE
1	1.25"	21	0	35	-1.25	14
2	0.63"	40	0	45	-0.63	5
3	2.75"	23	1.50"	40	-1.25	17
4	1.00"	29	0.50"	35	-0.5	6
5	2.00"	19	1.25"	25	-0.75	6
6	1.88"	10	1.00"	20	-0.88	10
7	1.25"	13	0.63"	36	-0.63	23
8	1.25"	36	0.25"	38	-1	2
9	1.00"	11	0.25"	27	-0.75	16
10	0.88"	31	0.88"	36	0	5
11	1.50"	24	1.00"	30	-0.5	6
12	2.25"	2	1.00"	12	-1.25	10
13	1.50"	28	0.75"	32	-0.75	4
14	1.25"	16	0	29	-1.25	13
15	1.00"	33	0	45	-1	12

FHP = FORWARD HEAD POSTURE  
CCURVE = CERVICAL CURVE OR LORDOSIS

findings (1,2,22–26). This provides some evidence that more interdisciplinary health professionals are becoming interested in these structural disorders.

In the present study, 4 lbs of weight was used in the headweight device. This weight was kept constant to help minimize variability. However, in instances where subjects whose forward head posture and cervical hypolordosis did not correct as much, it may be possible that additional weight in the headweight device may have had a more corrective effect. This effect has been observed during clinical application of this device by the author. One physician administered all of the manipulative procedures to each subject to eliminate differences in skill level among multiple practitioners.

This study appears to be only the third study on anterior headweighting that has been published, to our knowledge, in the peer-reviewed literature (1,2). All 3 studies have shown similar, beneficial results. However, no long-term studies have been conducted to date, so any claim on the permanency of this treatment is, as yet, unfounded. One weakness of this study is that there were no matched controls involved, nor a group who received either the Pettibon adjustments or headweighting alone. However, previous authors have reported that spinal manipulation alone is not enough to restore the cervical lordosis (27). Research using the headweight as a sole treatment modality is not yet available for comparative purposes. Follow-up studies should also expand the headweighting concept to include the effect of varying the amounts of weight in the headweight. Using the Pettibon headweight in conjunction with Pet-

tibon shoulderweighting and hipweighting also needs to be scientifically tested.

**CONCLUSION**

The present study demonstrates the effectiveness of the combined use of spinal manipulation and anterior headweighting for the correction of forward head posture and cervical hypolordosis. With 1 exception, both effects were demonstrated in all 15 subjects. However, this study evaluated only the immediate effects of this treatment intervention. This effectiveness has yet to be demonstrated for an extended period of time. Follow-up studies should consider testing the effectiveness of this protocol on a more long-term basis. It is also difficult to report which portion of the protocol, the spinal manipulation or the headweighting, had the bigger impact in terms of outcome measures. Additional research will need to consider these 2 modalities separately to determine their relative importance for cervical lordosis correction and forward head posture reduction. Clinical guidelines need to be established and peer-reviewed before inexperienced practitioners implement this protocol into the clinical setting.

**REFERENCES**

1. Saunders ES, Woggon D, Cohen C, Robinson DH. Improvement of cervical lordosis and reduction of forward head posture with anterior headweighting and proprioceptive balancing protocols. *J Vertebral Sublux Res* (Accepted for publication)
2. Morningstar M. Cervical curve restoration and forward head posture reduction for the treatment of mechanical thoracic pain using the pettibon corrective and rehabilitative procedures. *J Chiropr Med* 2002;1:113–15.
3. Harrison DE, Jones EW, Janik TJ, Harrison DD. Evaluation of the axial and flexural stresses in the vertebral body cortex and trabecular bone in lor-

- dosis and two sagittal cervical translation configurations with an elliptical shell model. *J Manipulative Physiol Ther* 2002;25:391-401.
4. Harrison DE, Harrison DD, Troyanovich SJ, Harmon S. A normal spinal position: it's time to accept the evidence. *J Manipulative Physiol Ther* 2000;23:632-44.
  5. Harrison DE, Cailliet R, Harrison DD, Troyanovich SJ, Harrison SO. A review of biomechanics of the central nervous system-part III: Spinal cord stresses from postural loads and their neurologic effects. *J Manipulative Physiol Ther* 1999;22:399-410.
  6. Harrison DE, Cailliet R, Harrison DD, Troyanovich SJ, Harrison SO. A review of biomechanics of the central nervous system-part II: Spinal cord strains from postural loads. *J Manipulative Physiol Ther* 1999;22:322-32.
  7. Harrison DE, Cailliet R, Harrison DD, Troyanovich SJ, Harrison SO. A review of biomechanics of the central nervous system-part I: Spinal canal deformations resulting from changes in posture. *J Manipulative Physiol Ther* 1999;22:227-34.
  8. Cailliet R, Gross L. *The rejuvenation strategy*. New York, NY: Doubleday & Company, Inc; 1987. p. 50-9.
  9. Cailliet R. *Neck and arm pain*. F.A. Davis and Company; 1964. p. 9-59.
  10. Jackson BL, Barker WF, Pettibon BR, Woggon D, Bentz J, Hamilton D, Wiegand M, Hester R. Reliability of the pettibon patient positioning system for radiographic production. *J Vertebral Sublux Res* 2000;4:1.
  11. Kapandji IA. *The physiology of the joints, vol 3: the trunk and vertebral column*. 2nd ed. Churchill Livingstone; 1974. p. 216.
  12. Cote P, Cassidy JD, Yong-Hing K, Sibley J, Loewy J. Apophyseal joint degeneration, disc degeneration, and sagittal curve of the cervical spine. Can they be measured reliably on radiographs? *Spine* 1997;22:859-64.
  13. Harrison DD, Janik TJ, Troyanovich SJ, Harrison DE, Colloca CJ. Evaluations of the assumptions used to derive an ideal normal cervical spine model. *J Manipulative Physiol Ther* 1997;20:246-54.
  14. Woggon D. *The Science of Pettibon Biomechanics System Adjusting* 2001. Gig Harbor, WA: Pettibon Biomechanics Institute; 2000. p. 39-43, 57-61.
  15. Mergner T, Hlavacka F. Multisensory control of posture. Proceedings of an international symposium on sensory interaction in posture and movement control. Plenum Press, New York 1995 pgs 69-94, 269-288.
  16. Seaman DR, Winterstein JF. Dysafferentation: a novel term to describe the neuropathophysiological effects of joint complex dysfunction. a look at likely mechanisms of symptom generation. *J Manipulative Physiol Ther* 1998;21:267-80.
  17. Visscher CM, de Boer W, Naeije M. The relationship between posture and curvature of the cervical spine. *J Manipulative Physiol Ther* 1998;21:388-91.
  18. Takeshima T, Omokawa S, Takaoka T, Araki M, Ueda Y, Takakura Y. Sagittal alignment of cervical flexion and extension: lateral radiographic analysis. *Spine* 2002;27:E348-55.
  19. Harrison DD, Troyanovich SJ, Harrison DE, Janik TJ, Murphy DJ. A normal sagittal spinal configuration: A desirable clinical outcome. *J Manipulative Physiol Ther* 1996;19:398-405.
  20. Harrison DD, Troyanovich SJ, Harrison DE. Three-dimensional spinal coupling mechanics: Part II implications for chiropractic theories and practice. *J Manipulative Physiol Ther* 1998;21:177-86.
  21. Harrison DD, Harrison DE, Troyanovich SJ. Structural Rehabilitation of the spine and posture: rationale for treatment beyond the resolution of symptoms. *J Manipulative Physiol Ther* 1998;21:37-50.
  22. Reynolds C. Reduction of hypolordosis of the cervical spine and forward head posture by specific upper cervical adjustment and use of a home therapy cushion. *Chiro Res J* 1998;5:23-7.
  23. Harrison DE, Cailliet R, Harrison DD, Janik TJ, Holland B. A new 3-point bending traction method for restoring cervical lordosis and cervical manipulation: a nonrandomized clinical controlled trial. *Arch Phys Med Rehabil* 2002;83:447-53.
  24. Katsuura A, Hukuda S, Imanaka T, Miyamoto K, Kanemoto M. Anterior cervical plate used in degenerative disease can maintain cervical lordosis. *J Spinal Disord* 1996;9:470-6.
  25. Coleman RR, Troyanovich SJ, Plaughner G, Hagen JO. Lateral cervical curve changes in patients receiving chiropractic adjustments using an activator adjusting instrument following motor vehicle collision. *J Chiro Ed* 2002;16:69.
  26. Wiegand R. Analysis of chiropractic adjusting to effect improved sagittal plane spinal geometry, gravitational loading, cervical dynamic function, and patient subjective complaints. *J Chiro Ed* 2002;16:103.
  27. Harrison DD, Jackson BL, Troyanovich SJ, Robertson G, DeGeorge D, Barker WF. The efficacy of cervical extension-compression traction combined with diversified manipulation and drop table adjustments in the rehabilitation of cervical lordosis: a pilot study. *J Manipulative Physiol Ther* 1994;17:454-64.