

Case Report

Rapid Spontaneous Redistribution of Acute Epidural Hematoma : Case Report and Literature Review

Ki Seong Eom, M.D., Jong Tae Park, M.D., Tae Young Kim, M.D., Jong Moon Kim, M.D.

Department of Neurosurgery, Wonkwang University College of Medicine, Iksan, Korea

Acute epidural hematoma (AEDH) occurring as a result of traumatic head injury constitutes one of the most critical emergencies in neurosurgery. However, there are only several reports that show the rapid disappearance of AEDH without surgical intervention. We suggest redistribution of hematoma through the overlying skull fractures as the mechanism of rapid disappearance of AEDH. A 13-year-old female fell from a height of about 2 m and presented with mild headache. A computed tomography (CT) scan performed 4 hours after the injury revealed an AEDH with an overlying fracture in the right temporal region and acute small hemorrhagic contusion in the left frontal region. A repeat CT scan 16 hours after injury revealed that the AEDH had almost completely disappeared and showed an increase in the epicranial hematoma. The patient was discharged 10 days after injury with no neurological deficits. This case is characterized by the rapid disappearance of an AEDH associated with an overlying skull fracture. We believe that the rapid disappearance of the AEDH is due to the redistribution of the hematoma, rather than its resolution or absorption, and fracture plays a key role in this process.

KEY WORDS : Acute epidural hematoma · Rapid disappearance · Redistribution.

INTRODUCTION

A rational therapeutic approach for treating an acute epidural hematoma (AEDH) is based on clinical and radiological parameters. Although there have been several reports of asymptomatic AEDH cured through non-operative treatment in a period of weeks⁸⁾, early spontaneous disappearance of an AEDH within 24 hours is very rare and, to the best of our knowledge, has been reported only for eight cases^{1-6,9,11)}. Here, we describe a case of AEDH that disappeared rapidly without surgical intervention and review the literature about this rare phenomenon.

CASE REPORT

A 13-year-old female fell from a height of about 2 m and hit her right temporal region against the floor. She reportedly lost consciousness for a few minutes. On admission, she complained only of a mild headache. Physical examina-

tion revealed swelling in the right temporal area. However, the results of neurological examination were unremarkable. A computed tomography (CT) scan performed 4 hours after the injury revealed an AEDH (about 1.8 cm in maximum thickness) of heterogeneous density with an overlying fracture in the right temporal region and acute small hemorrhagic contusion in the left frontal region. Air bubbles in the AEDH were noted (Fig. 1). Although she remained alert after admission, a repeat CT scan was obtained 16 hours after injury in an effort to rule out

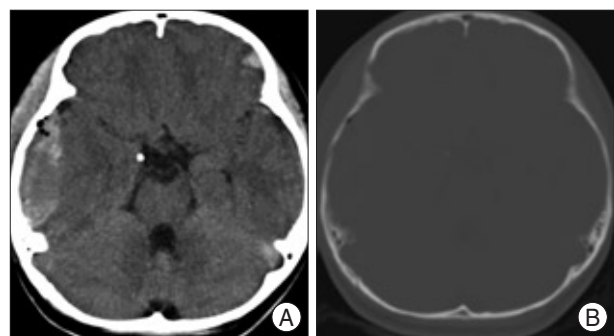


Fig. 1. Computed tomography scans without contrast medium (A) and with bone setting (B) obtained 4 hours after injury reveals an acute epidural hematoma of heterogeneous density with an overlying fracture in the right temporal region and acute small hemorrhagic contusion in the left frontal region. Air bubbles in the acute epidural hematoma are noted.

• Received : August 12, 2008 • Accepted : January 27, 2009
 • Address for reprints : Jong Moon Kim, M.D.
 Department of Neurosurgery, Wonkwang University College of
 Medicine, 344-2 Sinyong-dong, Iksan 570-749, Korea
 Tel : +82-63-859-1461, Fax : +82-63-852-2606
 E-mail : jmkim@wonkwang.ac.kr

delayed occurrence of intracranial hematoma. At this time, the AEDH had almost completely disappeared, and there was an increase in the size of the epicranial hematoma (Fig. 2). The patient was discharged after 10 days with no neurological deficits.

DISCUSSION

The spontaneous resolution process during the natural course of AEDH starts in the second week⁷. Therefore, disappearance of an AEDH within 24 hours after trauma is extremely rare and only nine cases have been reported in the English literature, in addition to our present case^{1-6,9,11} (Table 1). Although various mechanisms of disappearance of hematoma have been suggested, the underlying mechanism is still unclear. Aoki² emphasized the potential

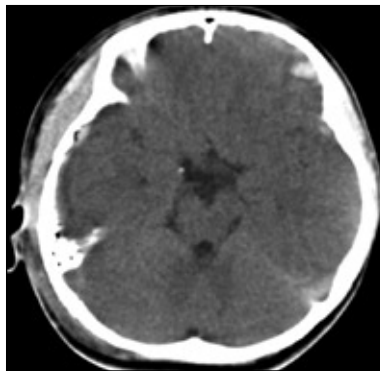


Fig. 2. Computed tomography scan obtained 16 hours after injury reveals a marked decrease in the acute epidural hematoma and increase in the epicranial hematoma.

for communication between intracranial and epicranial hematomas through a fracture; this communication provides useful information for predicting a favorable prognosis. Kuroiwa et al.⁴ hypothesized that the hematoma may be forced out of the intracranial region

through the fracture line due to the pressure gradient between the venous EDH in the transverse sinus and the intradural space. Malek et al.⁵ proposed that the hematoma may be caused by an increase in epicranial/subcutaneous pressure after focal head trauma, which causes sero-sanguinous fluid to leak into the epidural space through an underlying skull fracture. When the epicranial tissue pressure subsides, the fluid would leak back out through the fracture into the epicranial space. Ugarriza et al.¹¹ hypothesized that the AEDH communicated with the fractured external auditory canal, making possible its ultraearly drainage without any need to postulate intracranial hypertension. Kang et al.³ emphasized that the pressure gradient between the subgaleal and epidural space may be important in the rapid disappearance of AEDH. Neely et al.⁶ postulate that bleeding from the diploic space of the calvarium initially extends into both the subgaleal and epidural compartments in these patients, with the blood preferentially decompressing into the subgaleal space as it increases in volume in the immediate posttraumatic period, aided by CSF pulsation. In our case, a follow-up CT 16 hours after injury revealed that the hematoma had almost completely disappeared, while the size of the epicranial hematoma had increased. Therefore, we speculate that the mechanism underlying the rapid disappearance of the AEDH in our case is the redistribution of the hematoma through overlying skull fractures that commonly accompany AEDH. Consistent with this hypothesis, other studies have reported a higher rate of spontaneous resorption in patients with additional skull

Table 1. Literature review of cases of spontaneous disappearance of an acute epidural hematoma within 24 hours

Authors, year	Age/Sex	Cause of Injury	LOC	Location/Maximum thickness of AEDH	Overlying skull fracture	Time to disappearance after injury	Epicranial hematoma	Outcome
Aoki ² , 1988	8 y/Male	Fall (2 m)	Transient	Left TP/1.5 cm	Present	23 h	Increase	Discharged on HD 2
	17 y/Male	BA	Transient	Left O/1 cm	Present	5 h	Increase	Discharged on HD 17
Servadei et al. ⁹ , 1991	65 y/Male	MVA	Persistent (DAI)	Right P/1.5 cm	Present	4 h	NA	Died 48 h after injury
Kuroiwa et al. ⁴ , 1993	17 y/Male	Fall (1 m)	Transient	Right O & posterior fossa/2 cm	Present	12 h	NA	Discharged on HD 14
Malek et al. ⁵ , 1997	17 m/Male	Fall (1.5 m)	Absent	Right T/0.8 cm	Present	20 h	Increase	NA
Akagami & Cochrane ¹ , 1999	3.5 y/Male	Fall (1.5 m)	Absent	Left T/1.5 cm	Present	16 h	Increase	Discharged on HD 2
Ugarriza et al. ¹¹ , 1999	43 y/Male	Fall (1.5 m)	PTA	Right T/2.2 cm	Present	6 h	Increase	Discharged on HD 15
Kang et al. ³ , 2005	34 y/Male	Fall (2.5 m)	NA	Bilateral posterior Fossa/NA	Present	21 h	Increase	Died HD 11 after injury
Neely et al. ⁶ , 2008	2.5 y/Female	Strike (softball)	Absent	Left P/1 cm	Present	10 h	Increase	Discharged without neurological deficit
present case, 2008	13 y/Female	Fall (2 m)	Transient	Right T/1.8 cm	Present	16 h	Increase	Discharged on HD 10

BA : bicycle accident, MVA : motor vehicle accident, LOC : loss of consciousness, DAI : diffuse axonal injury, PTA : posttraumatic amnesia, NA : non available, HD : hospital day

fracture compared to patients with isolated EDH¹⁰.

CONCLUSION

This report describes the mechanism underlying the rapid disappearance of an AEDH associated with an overlying skull fracture. We believe that the rapid disappearance of the AEDH is due to redistribution of a hematoma, rather than its resolution or absorption, and there is no doubt that the fracture plays a key role in this process.

• Acknowledgements

This paper was supported by Wonkwang University in 2008.

References

1. Akagami R, Cochrane DD : Does it leak in or does it leak out. *Pediatr Neurosurg* 30 : 109-110, 1999
2. Aoki N : Rapid resolution of acute epidural hematoma : report of two cases. *J Neurosurg* 68 : 149-151, 1988
3. Kang SH, Chung YG, Lee HK : Rapid disappearance of acute posterior fossa epidural hematoma. *Neurol Med Chir (Tokyo)* 45 : 462-463, 2005
4. Kuroiwa T, Tanabe H, Takatsuka H, Arai M, Sakai N, Nagasawa S, et al : Rapid spontaneous resolution of acute extradural and subdural hematomas. Case report. *J Neurosurg* 78 : 126-128, 1993
5. Malek AM, Barnett FH, Schwartz MS, Scott RM : Spontaneous rapid resolution of an epidural hematoma associated with overlying skull fracture and subgaleal hematoma in a 17-month-old child. *Pediatr Neurosurg* 26 : 160-165, 1997
6. Neely JC II, Jones BV, Crone KR : Spontaneous extracranial decompression of epidural hematoma. *Pediatr Radiol* 38 : 316-318, 2008
7. Pang D, Horton JA, Herron JM, Wilberger JE Jr, Vries JK : Nonsurgical management of extradural hematomas in children. *J Neurosurg* 59 : 958-971, 1983
8. Pozzati E, Tognetti F : Spontaneous healing of acute extradural hematoma : study of twenty-two cases. *Neurosurgery* 18 : 696-700, 1986
9. Servadei F, Staffa G, Pozzati E, Piazza G : Rapid spontaneous disappearance of an acute extradural hematoma : case report. *J Trauma* 29 : 880-882, 1989
10. Tuncer R, Açıkbaz C, Uçar T, Kazan S, Karasoy M, Saveren M : Conservative management of extradural haematomas : effects of skull fractures on resorption rate. *Acta Neurochir (Wien)* 139 : 203-207, 1997
11. Ugarriza LF, Cabezudo JM, Fernandez-Portales I : Rapid spontaneous resolution of an acute extradural hematoma : case report. *Br J Neurosurg* 13 : 604-605, 1999