

Nonmycetomic *Actinomadura madurae* Infection in a Patient with AIDS

MICHAEL M. McNEIL,^{1*} JUNE M. BROWN,¹ GIORGIO SCALISE,² AND CLAUDIO PIERSIMONI³

Mycotic Diseases Branch, Division of Bacterial and Mycotic Diseases, National Center for Infectious Diseases, Centers for Disease Control, Atlanta, Georgia 30333,¹ and Institute of Infectious Diseases, University of Ancona, General Hospital "Umberto I^o-Torrette," 60021 Ancona,² and Department of Clinical Microbiology, General Hospital "Umberto I^o-Torrette," 60020 Ancona,³ Italy

Received 15 July 1991/Accepted 26 December 1991

***Actinomadura madurae* is an aerobic actinomycete which is best known worldwide as the cause of actinomycotic mycetomas. It has not previously been reported to have caused invasive pulmonary or disseminated infection in humans. We describe an AIDS patient with opportunistic *A. madurae*-induced pneumonia and bacteremia. The isolate from the patient's blood was subjected to dilutional antimicrobial susceptibility tests with 12 antimicrobial agents and was found to have a wide spectrum of susceptibility. This unusual microorganism may be a cause of infections in severely immunosuppressed patients.**

Actinomadura madurae, an aerobic actinomycete of the order Actinomycetales, inhabits soil worldwide and has been well known as a cause of actinomycotic mycetomas (11). Recently, however, *A. madurae*-induced peritonitis has been reported in a patient undergoing long-term ambulatory peritoneal dialysis (13). To our knowledge, this species has not been reported to cause either invasive pulmonary or disseminated infection in humans. We describe our experience with a patient with AIDS with pneumonia caused by *A. madurae* and review the microbiology and biochemical characteristics of this aerobic actinomycete.

A 39-year-old white man with an 8-year history of intravenous heroin abuse presented in January 1987 with esophageal candidiasis and was found to be human immunodeficiency virus type 1 antibody positive by Western blot (immunoblot) and enzyme-linked immunosorbent assay. The patient was hospitalized in May 1987 and April 1988 with two episodes of *Pneumocystis carinii*-induced pneumonia, which resolved after intravenous therapy with trimethoprim-sulfamethoxazole.

On 6 June 1988, after 1 week of progressive unproductive cough, dyspnea, and intermittent fever ($\geq 39^{\circ}\text{C}$) and a weight loss of approximately 3 kg, he was readmitted. On examination, the patient was febrile (38.5°C) and was noted to have oropharyngeal candidiasis. A chest radiograph was normal. Laboratory examination showed a hemoglobin level of 10.3 g/dl, hematocrit of 31%, erythrocyte count of $3.2 \times 10^6/\text{mm}^3$, leukocyte count of $2,200/\text{mm}^3$ (polymorphonuclear leukocytes, 1,620; lymphocytes, 410), erythrocyte sedimentation rate of 55 mm/h, alanine transaminase level of $66 \mu\text{g}/100 \text{ ml}$, aspartate transaminase level of $51 \mu\text{g}/100 \text{ ml}$, 39 CD4 cells per mm^3 , and 168 CD8 cells per mm^3 . Results of tests for human immunodeficiency virus p24 antigen were positive (60 pg/ml), and tests for anticytomegalovirus immunoglobulin G (high index) and anti-cytomegalovirus immunoglobulin M (low index) were positive. He was given empiric therapy with intramuscular netilmicin at 150 mg two times a day, and after a 4-day course, this therapy was changed to 500 mg of intravenous imipenem four times a day for another 5 days without apparent effect.

On June 18, a slide blood culture (Septi-Check, Roche Diagnostic Systems Inc., Nutley, N.J.) performed on June 8 was reported to be positive after 10 days of incubation at 37°C . Stained smears showed gram-positive, non-acid-fast, filamentous bacilli that morphologically resembled a *Nocardia* sp. The isolate was sent to the Centers for Disease Control for identification. On the same day, intravenous therapy with trimethoprim-sulfamethoxazole (10 + 50 mg/kg of body weight per day) was initiated. On June 28, the patient's level of consciousness deteriorated, and he developed dysarthria, unilateral left facial paresis, and fecal and urine incontinence. A computed tomographic scan of his brain showed small subcortical, supratentorial, and periventricular areas of reduced uptake. Cerebrospinal fluid was macroscopically clear and on microscopic examination had 6 cells per mm^3 (mainly lymphocytes), a protein level of 50 mg/100 ml, and a glucose level of 52 mg/100 ml.

Intravenous trimethoprim-sulfamethoxazole was continued for 4 weeks, but there was gradual deterioration in the patient's level of consciousness, and he became progressively dyspneic. Repeated cultures of his blood (between June 9 and 25 and July 2 and 15) (eight cultures) and cultures of sputum (eight cultures), urine (three cultures), and cerebrospinal fluid (one culture) performed prior to and during his trimethoprim-sulfamethoxazole therapy remained sterile after 60 days. He remained comatose with mild respiratory insufficiency. His chest radiograph showed nonspecific changes. Imipenem at 500 mg three times a day and amikacin at 500 mg two times a day were administered intravenously. On 3 August 1988 (2 months after admission and 19 months after the diagnosis of AIDS), the patient had a respiratory arrest and died. On postmortem examination, there was macroscopic evidence of bilateral necrotizing pneumonia. Histologic examination showed disseminated cytomegalovirus infection with cytomegalic inclusions in brain and lung tissues. Histologic examination of the pulmonary tissues also showed coexisting widespread bacterial pneumonia. No cultures were obtained at the time of the postmortem examination.

The isolate was examined according to the procedures routinely used in the Actinomycete Laboratory of the Centers for Disease Control (3). Analysis of whole-cell hydrolysate for the stereoisomer of diaminopimelic acid was per-

* Corresponding author.

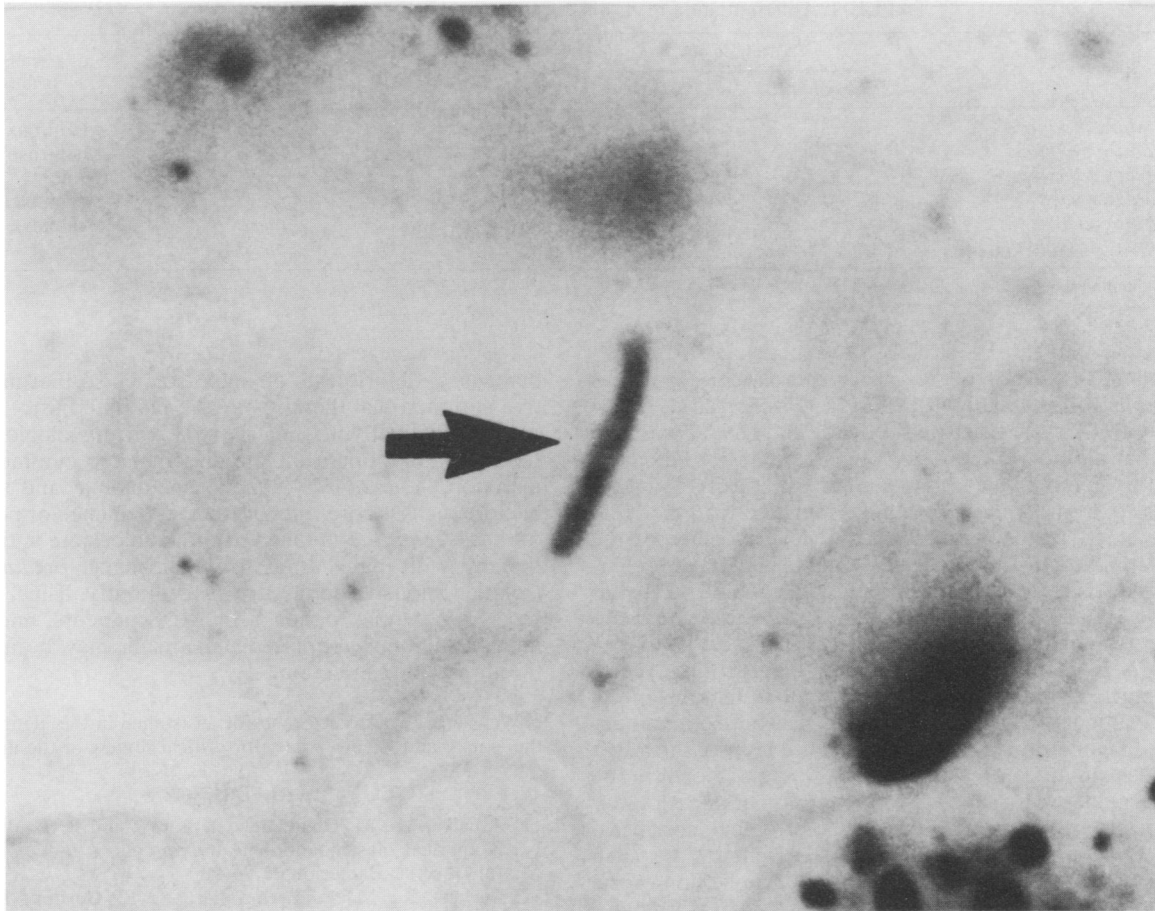


FIG. 1. Section of lung, showing gram-positive short filament of *A. madurae* (Brown and Brenn stained; magnification, $\times 1,400$).

formed according to the method of Becker et al. (2), and for monosaccharides according to the method of Lechevalier (7). Antimicrobial susceptibility tests were carried out at 35°C by the Mueller-Hinton broth microdilution method (8). The hematoxylin and eosin, Gomori methenamine, and Brown and Brenn staining methods were used to demonstrate and study the organism in tissue.

Microscopically, the blood culture isolate of June 18 was found to have formed branched filaments without production of spores. The culture was white, mucoid, and molar toothed after 2 days of incubation at 35°C. Aerial hyphae were not produced until 2 weeks of incubation. The isolate decomposed casein, esculin, and tyrosine but did not decompose adenine, hypoxanthine, and xanthine. It did not grow in the presence of lysozyme. When an oxidative basal medium was used, it produced acid from adonitol, erythritol, glucose, mannose, and trehalose but did not produce acid from arabinose, cellobiose, dulcitol, fructose, galactose, glycerol, inositol, lactose, maltose, mannitol, melibiose, raffinose, rhamnose, salicin, sorbitol, starch, sucrose, and xylose. *meso*-Diaminopimelic acid was found in the whole-cell hydrolysate, and the whole-cell extract contained the characteristic sugar madurose (3-*O*-methyl-D-galactose). No mycolic acids were demonstrated. On the basis of these characteristics, the isolate was identified as *A. madurae*. These results were comparable to those of previous reports [3, 6, 11–13].

In vitro antimicrobial susceptibility test results for the

isolate, obtained by using the National Committee for Clinical Laboratory Standards' MIC interpretive standards (10), were as follows: susceptible to amikacin (≤ 0.25 $\mu\text{g/ml}$), amoxicillin-clavulanate ($\leq 0.5/0.25$), cefotaxime (≤ 0.5), ceftriaxone (≤ 1), doxycycline (≤ 0.13), imipenem (≤ 0.25), minocycline (≤ 0.13), sulfamethoxazole (4), and trimethoprim-sulfamethoxazole (0.25/4.8) and moderately susceptible to ampicillin (≤ 0.25), ciprofloxacin (1), and erythromycin (0.5).

Histologic examination showed intra- and extracellular short filaments on the Gomori methenamine-stained section of lung, and gram-positive short filaments were also seen on the Brown and Brenn-stained preparation (Fig. 1).

A. madurae is a mesophilic, gram-positive, non-acid-fast, aerobic actinomycete with a branched substrate and an aerial mycelium. Its primary reservoir is soil. The microorganism's pathogenic potential was first recognized in 1894 by Vincent, who named it *Streptothrix madurae* and described it as the causative agent of "Madura foot" (12). In 1896, Blanchard transferred it to the genus *Nocardia* as *Nocardia madurae* (4). In 1970, on the basis of cell wall studies, Lechevalier and Lechevalier proposed the genus *Actinomadura* to include this species and two other species, *Nocardia pelletieri* and *Nocardia dassonvillei* (6). However, those authors also characterized the proposed *A. madurae* and *Actinomadura pelletieri* as closely related species and emphasized the morphologic and chemical differences between them and *Actinomadura dassonvillei*. In 1976, Meyer trans-

TABLE 1. Differentiation of *A. madurae* from related species and genera^a

Species	Hydrolysis of:		Growth in lysozyme	Isomer of DAP	Characteristic whole-cell sugar(s)
	Casein	Esculin			
<i>Actinomadura madurae</i>	+	+	-	meso	Madurose
<i>Actinomadura pelletieri</i>	+	-	-	meso	Madurose
<i>Streptomyces somaliensis</i>	+	-	-	levo	None
<i>Nocardia asteroides</i>	-	+	+	meso	Arabinose, galactose
<i>Nocardia brasiliensis</i>	+	+	+	meso	Arabinose, galactose
<i>Nocardiopsis dassonvillei</i>	+	V	-	meso	None

^a DAP, diaminopimelic acid; V, variable.

ferred *A. dassonvillei* to the new genus *Nocardiopsis*, as *Nocardiopsis dassonvillei* (9). In 1983, Fischer et al. determined by DNA-rRNA cistron similarity and DNA homology values that although *Actinomadura* is genetically heterogeneous, this genus is clearly separated genetically and phenotypically from *Nocardiopsis dassonvillei* (5). In 1985, Athalye et al. further confirmed the heterogeneity of the genus *Actinomadura* by numerical data using 102 unit characters (1). Also, these authors were clearly able to distinguish the genus *Actinomadura* from *Nocardiopsis dassonvillei* by using numerical data.

A. madurae is a frequent cause of actinomycotic mycetomas, superficial and/or deep suppurating tumefactions of the skin and subcutaneous tissues that result from soil contamination of a penetrating wound and usually involve the lower extremities. In mycetomas, the etiologic agents occur in the form of granules. The majority of the reports of infections by this species are from tropical and subtropical countries. However, the higher incidence and prevalence of such infections in warm climates may be only a reflection of the increased tendency for people in those areas to walk barefoot. We are aware of only one recent report of a nonmycotic infection with this microorganism, i.e., a case of *A. madurae* peritonitis that developed in a patient undergoing long-term ambulatory peritoneal dialysis who had no history of travel to tropical regions. This infection responded to intraperitoneal therapy with amikacin (13). To our knowledge, there have been no reports of either invasive pulmonary or disseminated *A. madurae* infections.

A recent review of the aerobic actinomycete species identified by the Actinomycete Laboratory of the Centers for Disease Control from October 1985 through February 1988 from clinical specimens found that *A. madurae* accounted for 42 (11.5%) of 366 of the referred isolates and was second in frequency only to *Nocardia asteroides*, which accounted for 98 (26.8%) of 366 of these isolates (8). In this study, we found that the majority of these isolates were from sputum (24 isolates; 57.1%) and wounds (13 isolates; 31%). One (2.4%) of the 42 isolates was a blood isolate, which supports the role of *A. madurae* as a potential colonizer or infectious microorganism in some patients.

The finding that *A. madurae*, usually an agent of mycetomas, was an opportunistic pathogen capable of causing serious life-threatening infection in a severely immunocompromised patient suggests that clinical laboratories become proficient in the identification of this opportunistic actinomycete. The physiologic characteristics helpful in differentiating *A. madurae* from *A. pelletieri* and species in related genera are given in Table 1. The recent finding that aerobic actinomycete isolates from clinical specimens have demonstrated inter- and intraspecies variability on antimicrobial susceptibility tests supports the need to perform antimicro-

bial susceptibility tests on such isolates so that more-effective antimicrobial therapy may be instituted (8).

In our patient with underlying AIDS, histologic examination confirmed opportunistic disseminated cytomegalovirus infection, *A. madurae*-induced pneumonia, and secondary bacteremia. Of note, there was also evidence of persistence of the *A. madurae*-induced pneumonia despite antimicrobial therapy with many drugs to which his *A. madurae* blood isolate demonstrated in vitro susceptibility. Thus, *A. madurae* is a potential pathogen in AIDS patients, and in these heavily immunosuppressed patients, it may be a cause of life-threatening infection.

We thank A. M. Tortorano for assistance in the identification of the isolate and Libero Ajello for critical review of the manuscript.

REFERENCES

- Athalye, M., M. Goodfellow, J. Lacey, and R. P. White. 1985. Numerical classification of *Actinomadura* and *Nocardiopsis*. *Int. J. Syst. Bacteriol.* **35**:86-98.
- Becker, B., M. P. Lechevalier, R. E. Gordon, and H. A. Lechevalier. 1964. Rapid differentiation between *Nocardia* and *Streptomyces* by paper chromatography of whole-cell hydrolysates. *Appl. Microbiol.* **12**:421-423.
- Berd, D. 1973. Laboratory identification of clinically important aerobic actinomycetes. *Appl. Microbiol.* **25**:665-681.
- Blanchard, R. 1896. Parasites végétaux à l'exclusion des bactéries, p. 811-932. In C. Bouchard (ed.), *Traité de pathologie générale*, vol. II. G. Masson, Paris.
- Fischer, A., R. M. Kroppenstedt, and E. Stackebrandt. 1983. Molecular-genetic and chemotaxonomic studies on *Actinomadura* and *Nocardiopsis*. *J. Gen. Microbiol.* **129**:3433-3446.
- Lechevalier, H. A., and M. P. Lechevalier. 1970. A critical evaluation of the genera actinomycetales, p. 393-405. In H. Prauser (ed.), *The Actinomycetales*. Gustav Fischer Verlag, Jena, Germany.
- Lechevalier, M. P. 1968. Identification of aerobic actinomycetes of clinical importance. *J. Lab. Clin. Med.* **71**:934-944.
- McNeil, M. M., J. M. Brown, W. R. Jarvis, and L. Ajello. 1990. A comparison of species distribution and antimicrobial susceptibility of aerobic actinomycetes from clinical specimens. *Rev. Infect. Dis.* **12**:778-783.
- Meyer, J. 1976. *Nocardiopsis*, a new genus of the order *Actinomycetales*. *Int. J. Syst. Bacteriol.* **26**:487-493.
- National Committee for Clinical Laboratory Standards. 1985. Methods for dilution antimicrobial susceptibility testing for bacteria that grow aerobically. Approved standard M7-A. National Committee for Clinical Laboratory Standards, Villanova, Pa.
- Tight, R. R., and M. S. Bartlett. 1981. Actinomycetoma in the United States. *Rev. Infect. Dis.* **3**:1139-1150.
- Vincent, M. H. 1894. Étude sur le parasite du "pied de madura." *Ann. Inst. Pasteur* **8**:129-151.
- Wust, J., H. Lanzendorfer, A. von Graevenitz, H. J. Gloor, and B. Schmid. 1990. Peritonitis caused by *Actinomadura madurae* in a patient on CAPD. *Eur. J. Clin. Microbiol. Infect. Dis.* **9**:700-701. (Letter.)