

Focused abdominal sonography for trauma in the emergency department for blunt abdominal trauma

Chi Leung Tsui · Hin Tat Fung · Kin Lai Chung ·
Chak Wah Kam

Received: 15 July 2008 / Accepted: 20 July 2008 / Published online: 26 September 2008
© Springer-Verlag London Ltd 2008

Abstract

Background Blunt abdominal trauma (BAT) is a diagnostic challenge to the emergency physician (EP). The introduction of bedside ultrasound provides another diagnostic tool for the EP to detect intra-abdominal injuries.

Aims To evaluate the performance of EP in a local emergency department in Hong Kong to perform the ‘focused abdominal sonography for trauma’ (FAST) in BAT patients.

Methods This was a retrospective cohort study including all the trauma team cases in a 36-month period in the emergency department of a public hospital in Hong Kong. The results of FAST scans were analyzed and compared with CT scans when the FAST was positive or followed by a period of clinical observation when the FAST was negative. Descriptive statistics and sensitivity, specificity, and predictive values were calculated.

Results There was a total of 273 cases, and FAST scans were performed in 242 cases. The sensitivity and specificity were 86% and 99%, respectively. The negative predictive value was 0.98, while the positive predictive value was 0.94. The overall accuracy was 97%.

Conclusions The performance of the EP in using FAST scans in BAT patients was encouraging. The high specificity (99%), positive predictive value (0.98), and likelihood ratio for positive tests (86) make it a good ‘rule in’ tool for BAT patients. The high negative predictive value also makes the FAST scan a useful screening tool. However, ultrasound examination is operator dependent, and FAST

scan has its own limitations. For negative FAST scan cases, we recommend a period of monitoring, serial FAST scans, or further investigations, such as CT scan or peritoneal lavage.

Keywords Blunt abdominal injury · Emergency medicine · Ultrasound · FAST

Introduction

Abdominal injuries rank third as a cause of traumatic death just after head and chest injuries. Unrecognized abdominal injuries are frequently the cause of preventable death, which constitutes a significant diagnostic challenge to emergency physicians (EP) [1]. In the past, we relied on clinical signs that have relatively low diagnostic accuracy (47% to 87%), especially when the patient had a decreased consciousness level, neurological deficit, other associated injuries, or was under the influence of drugs or medications [2]. In case of doubt, we might proceed to diagnostic peritoneal lavage (DPL), which is an invasive procedure. The introduction of bedside ultrasonography provides another non-invasive, readily available, and time-saving option for patients with blunt abdominal trauma.

In fact, there was an over 30-year history of using ultrasound in the evaluation of abdominal trauma. As early as 1971, Kristensen [3] described the use of ultrasound scanning in the diagnosis of abdominal trauma. After that, the use of ultrasound in abdominal trauma grew gradually, and the term ‘focused abdominal sonography for trauma’ (FAST) scan has been used since the early 1990s. In Hong Kong, the use of FAST for blunt abdominal trauma (BAT) became popular after the first case was reported in 1995 [4]. Nowadays, FAST is the standard practice for BAT in most emergency departments in Hong Kong.

The views expressed in this paper are those of the author(s) and not those of the editors, editorial board or publisher.

C. L. Tsui (✉) · H. T. Fung · K. L. Chung · C. W. Kam
Accident and Emergency Department, Tuen Mun Hospital,
Tsing Chung Koon Road,
Tuen Mun, N.T., Hong Kong
e-mail: cltsui333@netvigator.com

With the introduction of FAST scan in BAT, there were many studies concerning the sensitivity and specificity. However, there were minimal studies in Hong Kong for the performance of FAST scans in BAT. The objective of this article is to study the performance of FAST scan in BAT patients by the emergency physicians in a regional hospital in Hong Kong. The pitfalls of FAST scan and the means of improvement are also discussed.

Patients and methods

This was a retrospective cohort study including all the trauma team cases in a 36-month period (January 2004 to December 2006) in a local emergency department (ED) in Hong Kong. Patients with penetrating abdominal injury were excluded from the study. In all other cases, FAST scans were performed by the attending emergency physician using the same ultrasound machine (Toshiba Capasee II Model SSA-220A) with a 3.75-MHz curvilinear probe.

The scans were done after the primary survey with the patient in supine position. Four standard views were performed in each case, namely, (1) right upper quadrant view to include Morrison's pouch; (2) left upper quadrant view to include the splenorenal recess; (3) transverse pelvis view; (4) longitudinal pelvis view to visualize the cul-de-sac. In some instances, examination of the subxiphoid view was also performed. The main focus of the FAST scan was to detect free intra-peritoneal fluid secondary to injury of abdominal organs.

Positive scan was defined as the presence of free intra-peritoneal fluid, regardless of the fluid volume and location. The absence of any free intra-abdominal fluid was considered as negative scan. No further investigations (e.g., DPL or CT scan) would be warranted for negative scan, unless the patient clinical condition deteriorated or experienced persistent abdominal pain. Methods used to confirm the ultrasound results included laparotomy, CT scans, and clinical progress. All the patients were admitted to hospital for monitoring of at least 24 h.

Result

There were totally 273 trauma team cases in this 36-month period; 14 cases of penetrating abdominal injury were excluded from the study. FAST scans were performed in 242 cases. The 17 cases without FAST scan performed were isolated injuries from the head, neck, and/or limbs. The age range of these 242 cases was from 16 to 82 years old.

In these 242 cases, 33 (13.6) of them showed intra-abdominal free fluid; 27 patients with unstable hemodynamics were immediately transferred to the operation room for emergency laparotomy without undergoing other inves-

tigations such as CT scan or DPL. All of them showed positive results in laparotomy.

The remaining six cases with stable hemodynamics were further evaluated by CT scans. Four cases showed hemoperitoneum with liver, spleen, or mesenteric laceration. Three of them underwent emergency laparotomy, and one was treated conservatively. After CT scans, two cases were found to be false-positive FAST scans.

For those cases with negative FAST scans, five were ultimately found to have hemoperitoneum by subsequent CT scans after admission. CT scans were done in these cases either because of change in clinical conditions or the patients were experiencing persistent abdominal pain. Two cases showed liver lacerations; three cases showed mesenteric hematomas with bowel thickening. All cases showed small amounts of free intra-peritoneal fluid. One case of liver laceration was treated conservatively, while the other four patients required laparotomies for hemostasis (Fig. 1).

In this study, the sensitivity and specificity of the FAST scan were 86% and 99%, respectively, with the accuracy of 97% (Table 1).

The negative predictive value was 0.98, while the positive predictive value was 0.94. The likelihood ratio was 86 for a positive scan and 0.14 for a negative scan. The overall accuracy was 97%.

Discussion

In BAT, rapid determination of which patients should require emergency laparotomy is crucial for life saving, especially for those with unstable haemodynamics. On the other hand, avoidance of unnecessary laparotomy, which is an invasive procedure with inherent complications, is also important. The FAST scan provides a useful initial diagnostic tool for this kind of patient.

In this study, the high specificity (99%), positive predictive value (0.94), and likelihood ratio for positive test (LR+ve 86) made the FAST scan a good 'rule in' tool for BAT patients.

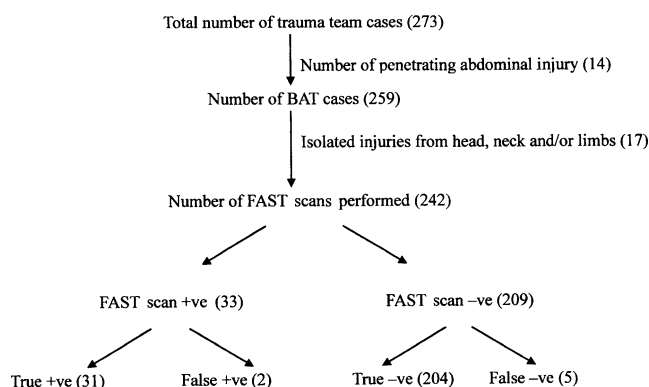


Fig. 1 Flow chart of the subject

Table 1 The result of FAST scans in BAT

	Intra-abdominal injury +ve	Intra-abdominal injury -ve	Total
FAST +ve	31	2	33
FAST -ve	5	204	209
Total	36	206	242

Other international studies also showed similar specificity with a range of 83%–100% [5–7, 10, 14–15, 20–21, 25–28].

The sensitivity was 86%, corresponding to many similar studies (Table 2). Literature review showed that the sensitivity of FAST scan performed by EP for BAT patients ranged from 42% to 95% [5–7, 10, 14–15, 20–21, 25–28]. The FAST scan is also valuable as a screening tool considering its high negative predictive value of 0.98.

There are many factors that could influence the result of FAST scans. It is well known that ultrasound scanning is operator dependent. Although the technique of FAST scan could easily be acquired, physicians did need some training and practice to become familiarized with the skill. There is no universal agreement about how long and how many FAST scans an emergency physician should perform to be accredited to do the scan. An international consensus conference in 1999 [8] recommended a 4-h didactic component, a 4-h practical component, and 200 supervised examinations, while the American College of Emergency Physicians Ultrasound Guideline recommendations published in 2001 only recommended 25–40 supervised examinations [9]. Moreover, a study from Shackford et al. suggested that the error rate was stabilized after only ten scans [10]. As reflected by this discrepancy, the true required number for proficiency remains ill-defined.

In our study, the emergency physicians performing the FAST scan ranged from resident to senior medical officers, all of whom had undergone at least a basic emergency

ultrasonography course held by the department or by the Hong Kong College of Emergency Medicine. The result of this study showed that there was no statistically significant difference for the sensitivity or specificity of FAST scans performed by different ranks of emergency physicians.

The timing of the scan is also an important factor. The aim of FAST scan is to detect free intra-peritoneal fluid secondary to bleeding from abdominal organ injury; however, there is a time lag for the accumulation of a significant amount of blood in the peritoneal cavity to be detectable by the scan. Studies suggest that the average volume of fluid detectable by the FAST scan ranges from 250 ml to 620 ml [11–12], although Goldberg demonstrated that ultrasound could detect as little as 100 ml of free intra-peritoneal fluid [13]. In order to eliminate this drawback, patients with negative scans should be observed for at least 4–6 h, and if indicated, serial FAST scan or CT scan should be considered.

There were five false-negative cases in this study. The patients either experienced change in clinical condition or complained of persistent abdominal pain during observation. CT of the abdomen was performed in these cases, all showing small amounts of free intra-peritoneal fluid. Two cases showed liver lacerations; three cases showed mesenteric haematomas with bowel thickening. One case of liver laceration was treated conservatively, while the other four cases required laparotomies for hemostasis.

In fact, many studies showed that FAST scan was limited or unable to detect certain types of injuries, such as bowel/mesenteric injury, diaphragmatic injury, solid organ/retro-peritoneal organ injury (e.g., pancreatic, renal, and adrenal), vascular injury, and spinal/pelvic fracture [14–15]. Therefore, a high level of suspicion should be maintained. In case of doubt, physicians should proceed to further investigations, such as CT scan.

Other causes of false-negative scan include emptying the urinary bladder too early or without an adequately filled urinary bladder for ultrasonic window, failure to recognize intra-peritoneal blood clot, patient obesity, and surgical emphysema in the chest and/or abdominal wall.

Study showed that without a full urinary bladder as an ultrasonic window, free fluid in the pelvis region is easily missed [16]. It is not uncommon that a Foley catheter is inserted in trauma patients to look for hematuria and monitor urinary output. However, if it is performed before the FAST scan, it would decrease the sensitivity of the scan. To overcome this, we could either perform the scan before Foley insertion or re-fill the urinary bladder with saline through the Foley catheter.

As discussed before, abdominal trauma is a dynamic event; scanning too early might miss a significant abdominal injury as free intra-peritoneal fluid needs time to accumulate. However, scanning too late could also affect

Table 2 Comparison of results with similar international studies

Study	No. of subjects	Sensitivity (%)	Specificity (%)	NPV (%)
Our study	242	86	99	98
Nural (2005) [25]	454	86.5	95.4	98.7
Holmes (2004) [26]	447	79	95	93
Miller (2003) [27]	359	42	98	93
Matthew (2001) [15]	2,576	86	98	98
Mckenney (2001) [20]	996	88	99	98
Coley (2000) [28]	107	55	83	50
Boulangier (1999) [21]	400	81	97	96
Shackford (1999) [10]	234	69	98	98
Chiu (1997) [14]	772	71	100	78

the result as the blood could become clotted. Intra-peritoneal blood clot usually appears hyperechoic and sometimes isoechoic, which makes it difficult to recognize. Despite the timing of scanning, being familiar with the typical appearance of the peritoneal reflections and of the normal configuration of the solid organ could improve recognition of the intra-peritoneal blood clot, too [17].

Obesity and overlying surgical emphysema are the common reasons for technically inadequate examination causing false-negative scans. Other minor causes include excessive room lighting, limited patient maneuverability, and limited sonographic window due to dressings, wounds, and chest tubes [6].

In this study, there were two false-positive cases after CT scan. Perinephric fat was one of the common causes. Fluid in the stomach or bowel might be mistaken as free intra-peritoneal fluid also. Other causes of false-positive result include pre-existing ascites, intra-peritoneal fluid collection due to ruptured ovarian cyst, or pelvic inflammatory disease [18].

Many scoring systems have been proposed for FAST scans. In the Huang scoring system (1994), one point was given to each of the positive FAST scan regions of Morrison's pouch, Douglas's pouch, perisplenic space, paracolic gutter, and floating intestinal loops; 96% of patient with score ≥ 3 required exploratory laparotomy. However, 38% of patient with score < 3 still required surgery [19]. McKenney et al. (2001) also had a similar proposal for which five regions were assessed: right subphrenic space, subhepatic space, left subphrenic space, perisplenic area, and pelvis. One point was granted to each positive area, and the final score was the summation of total positive areas plus the depth of largest collection in centimeters. The score was compared with initial systolic blood pressure and base deficit to assess the ability of sonography to predict a therapeutic laparotomy. The conclusion was that 87% with a score ≥ 3 required a therapeutic laparotomy, and it was a better predictor of a therapeutic laparotomy than the initial systolic blood pressure and base deficit [20].

These scoring systems were easy to apply and relatively reproducible. However, as they relied solely on the FAST scan finding, we should also consider the clinical condition of the patient when applying the scoring system so as to avoid unnecessary invasive procedures like laparotomy.

With the introduction of FAST in BAT, the management of patients is expedited. A study by Boulanger showed that FAST in BAT reduced the mean time from ED arrival to hospital (151 min to 53 min). In the study, patients undergoing FAST scan also had a 60% reduced relative risk of delayed recognition of intra-abdominal trauma [21]. Another study, the SOAP-1 Trial, also showed that the time from ED arrival to operation room was significantly shorter

in the ultrasound group (median interval 60 min versus 157 min) [22].

With advanced skill and technology, the use of emergency ultrasonography is extended from blunt abdominal trauma to include chest trauma also. The term 'Focused Assessment with Sonography for Trauma' (FAST) was coined by Rozycki et al. in 1996. In such FAST scans, in addition to detecting free intra-peritoneal fluid, they also attempted to detect any fluid collection in the pericardium and lung bases through the subxiphoid, right upper quadrant, and left upper quadrant views. FAST scan, therefore, also played a significant role in early detection of cardiac tamponade and hemothorax in trauma patients [23]. In 2002, Dulchavsky further extended the use of FAST scan to involve extremity and respiratory evaluation and named it the FASTER examination. Such FASTER examination may play an important role in remote locations, such as military and aerospace applications [24].

There were several limitations to this study, including the small sample size. Also, it was a retrospective study and not randomized.

Conclusion

FAST scan is a useful diagnostic tool in the initial assessment of BAT patients. It is easy to learn, readily available, repeatable, and non-invasive. The performance of EPs in using FAST scans in BAT patients was very encouraging. The high specificity (99%), positive predictive value (0.98), and likelihood ratio for positive tests (LR+86) make it a good 'rule in' tool for BAT patients. The high negative predictive value also causes FAST scan to be a useful screening tool. However, ultrasound examination is operator dependent, and FAST scan has its own limitations. Therefore, for negative FAST scan cases, we recommend a period of monitoring, serial FAST scans, or further investigations, such as CT scan or peritoneal lavage.

Conflicts of interest None.

References

1. American College of Surgeons Committee on Trauma (1997) Abdominal trauma. In: Advanced Trauma Life Support Program for Doctors, (Instructor course manual), 6th edn. Chicago; American College of Surgeons Committee on Trauma
2. Perry JF (1965) A Five-year survey of 152 acute abdominal injuries. *J Trauma* 5:53–57
3. Kristensen JR, Bueman B, Keuhl E (1971) Ultrasonic scanning in the diagnosis of splenic haematomas. *Acta Chir Scand* 137:653–657

4. Chung KL, Kam CW (1995) Emergency ultrasonography in a patient of blunt traumatic haemoperitoneum". *Hong Kong Journal Emerg Med* 2:104–107
5. Griffin XL, Pullinger R (2007) Are diagnostic peritoneal lavages or focused abdominal sonography for trauma safe screening investigations for hemodynamically stable patients after blunt abdominal trauma? A review of the literature. *J Trauma* 62:779–784
6. Lingawi SS (2001) Focused abdominal sonography in trauma. *J HK Coll Radiol* 4:222–225
7. Yoshii H, Sato M, Yamamoto S et al (1998) Usefulness and limitation of ultrasonography in the initial evaluation of blunt abdominal trauma. *J Trauma* 45:45–51
8. Scalea TM, Rodriguez A, Chiu WC, Brenneman FD, Fallon WF, Kato K et al (1999) Focused Assessment with Sonography for Trauma (FAST): result from an international consensus conference. *J Trauma* 46(3):466–472
9. American College of Emergency Physicians (2001) Use of ultrasound imaging by emergency physicians. *Ann Emerg Med* 38:469–470
10. Shackford SR, Rogers FB, Osler TM et al (1999) Focused Abdominal Sonogram for Trauma: the learning curve of non-radiologist clinicians in detecting hemoperitoneum. *J Trauma* 46(40):492–498
11. Branney SW, Wolfe RE, Moore EE, Albert NP, Heinig M, Mestek M et al (1995) Quantitative sensitivity of ultrasound in detecting free intraperitoneal fluid. *J Trauma* 39(2):375–380
12. Gracias VH, Frankel HL, Gupta R, Malcynski J, Gandhi R, Collazzo L et al (2001) Defining the learning curve for the Focused Abdominal Sonogram for Trauma (FAST) examination: implications for credentialing. *Am Surg* 67(4):364–368
13. Goldberg GG (1970) Evaluation of ascites by ultrasound. *Radiology* 96(15):217–221
14. Chiu WC et al (1997) Potential limitation of FAST. *J Trauma* 42(4):617–622
15. Dolich MO, McKenney MG et al (2001) Ultrasounds for blunt abdominal trauma. *J Trauma* 50(1):108–112
16. McGahan JP, Rose J, Contes TC, Wisner DH, Neberry P (1997) Use of ultrasound in the patient with acute abdominal trauma. *J Ultrasound Med* 16:653–662
17. McKenney KL (1999) Role of US in the diagnosis of intra-abdominal catastrophes. *Radiographics* 19:1332–1339
18. American College of Emergency Physicians. Policy statement. Emergency ultrasound imaging criteria compendium. p 26
19. Huang MS, Liu M, Wu JK, Shih HC, Ko TJ, Lee CH (1994) Ultrasonography for the evaluation of haemoperitoneum during resuscitation: a simple scoring system. *J Trauma* 36(2):173–177
20. McKenney KL, McKenney MG, Mark G, Cohn SM, Compton R (2001) Hemoperitoneum score helps determine need for therapeutic laparotomy. *J Trauma* 50(4):650–656
21. Boulanger BR, McLedlan BA, Brennenan FD, Ochoa J, Kirkpatrick AW (1999) Prospective evidence of the superiority of a sonography-based algorithm in the assessment of blunt abdominal injury. *J Trauma* 47:632–637
22. Melniker L, Liebner E, McKenney MG, Lopez P et al (2006) Randomized controlled trial of Point-of-Care, Limited Ultrasonography (PLUS) for trauma in the emergency department: the first sonography outcomes assessment program trial. *Ann Emerg Med* 48(3):227–235
23. Rozycki GS, Ochsner MG, Schmidt JA, Frankel HL, Davis TP, Wang D et al (1995) A prospective study of surgeon-performed ultrasound as the primary adjuvant modality for injured patient assessment. *J Trauma* 39(3):492–498
24. Dulchavsky SA, Henry SE, Moed BR et al (2002) Advanced ultrasonic diagnosis of extremity trauma: the FASTER examination. *J Trauma* 53(1):28–32
25. Nural MS, Yordan T, Guven H, Baydin A, Bayrak IK, Kati C (2005) Diagnostic value of ultrasonography in the evaluation of blunt abdominal trauma. *Diagn Interv Radiol* 11(1):41–44, Mar
26. Holmes JF, Harris D, Battistella FD (2004) Performance of abdominal ultrasonography in blunt trauma patient with out-of-hospital or emergency department hypotension. *Ann Emerg Med* 43(3):354–361, Mar
27. Miller MT, Pasquale MD, Bromberg WJ, Wasser TE, Cox J (2003) Not so FAST. *J Trauma* 54(1):52–59, Jan
28. Coley BD, Mutabagani KH, Martin LC et al (2000) Focused abdominal sonography for trauma (FAST) in children with blunt abdominal trauma. *J Trauma* 48:902–906

Dr Chi Leung Tsui is a Medical Officer of the Accident and Emergency Department of Tuen Mun Hospital in Hong Kong. He is a member of the Royal College of Surgeons of Edinburgh. Having worked in emergency medicine for more than ten years, Dr Tsui has special interest in the emergency ultrasonography and is the instructor of the basic and advanced emergency ultrasound course of the Hong Kong College of Emergency Medicine. He is also one of the members of the emergency ultrasound team of the Accident and Emergency Department of Tuen Mun Hospital.