



Published in final edited form as:

Surg Gynecol Obstet. 1968 July ; 127(1): 125.

AN EVERTING TECHNIQUE FOR INTRALUMINAL VASCULAR SUTURING

THOMAS E. STARZL, M.D., F.A.C.S.,

Denver, Colorado

CARL G. GROTH, M.D., and

Stockholm, Sweden

LAWRENCE BRETTSCHEIDER, M.D.

Denver, Colorado

Not infrequently, it is necessary to perform a vascular anastomosis between 2 vessels which have such short cuffs or other limitations of exposure that the back walls must be sutured from within the lumens. The construction of either an end-to-side or a side-to-side portacaval shunt is a typical example. In the transplantation of entire organs, the same problem is often encountered. Numerous other situations could be cited in which the technical requisites are similar.

To have uniform intimal coaptation in the posterior part of such an anastomosis, it is necessary to have an everted suture line. To achieve this, Blalock and Taussig used a modification of Carrel's method. A continuous everting mattress suture was loosely placed across most of the back row, and the walls of the vessel were then approximated by pulling tight the 2 ends of the thread. Considerable skill and patience are required for the proper execution of this technique, and most surgeons have come to prefer the simpler, though less perfect, non-everting over-and-over continuous suture.

For many years, we have used an intraluminal technique of continuous over-and-over suturing which combines the advantages of both the foregoing methods. Its principle is the immediate formation of intraluminal shoulders in both vessels, as briefly mentioned in a previous report on homotransplantation of the liver (2). Stay sutures are placed at the ends of the anastomosis (Fig. 1A, 1). The needle is passed into the posterior part of the lumen of 1 of the vessels 1 or 2 millimeters from the line of incision (Fig. 1A, 2). A firm bite of the other vessel is then taken, making sure that the entry and exit sites of the needle pass through the intima at some distance from the cut edge (Fig. 1A, 2). The full thickness of the wall of the vessel is included. As the thread is pulled tight, a mound of protruding tissue presents, which makes similar placement of subsequent sutures easy (Fig. 1A, 3). When the opposite end of the posterior anastomotic line is reached, the needle is passed outside (Fig. 1A, 4), and the anterior row is completed with an everting over-and-over suture (Fig. 1A, 5).

With this method, anastomoses which would be difficult or impossible with external suturing techniques can easily be done. There are other advantages. The degree of eversion which is obtained is the same (Fig. 1A, 6) as if the sewing were done from the outside, and consequently, the amount of intraluminal suture material is not increased. If the orifices of branches of the anastomosed vessels are identified near the suture line, these can be incorporated into the shoulder, thereby circumventing later annoying para-anastomotic leaks. By the immediate

tightening of each stitch, placement of the next bite is facilitated by making it unnecessary to grasp or manipulate the wall of the vessel with forceps.

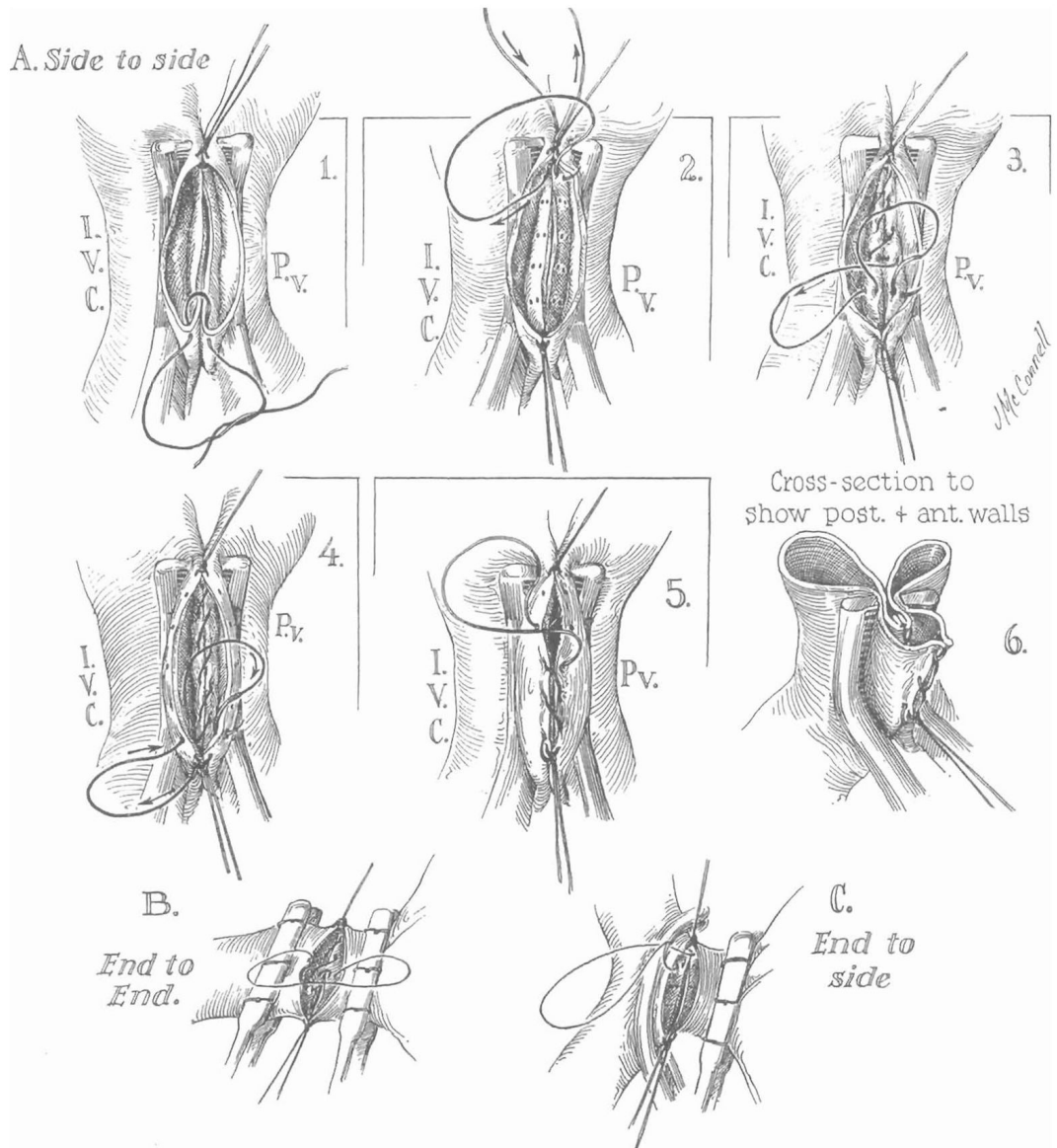
The technique is equally adaptable for end-to-end (Fig. 1B) or end-to-side (Fig. 1C) anastomoses. It is most easily performed with veins because of the greater pliability and thinness of the walls of the vessel, but it can also be useful for arterial anastomoses.

Acknowledgements

This work was supported by U.S. Public Health Service grants FO5-TW-1154, AM 06283, AM 06344, HE 07735, AM 07772, AI 04152, FR 00051, FR 00069, AM 12148, and AI AM 08898.

References

1. Blalock A, Taussig HB. The surgical treatment of malformations of the heart in which there is pulmonary stenosis or pulmonary atresia. *J A M A* 1945;128:189.
2. Starzl TE, Marchioro TL, von Kaulla K, Hermann G, Brittain RS, Waddell WR. Homotransplantation of the liver in humans. *Surg Gynec Obstet* 1963;117:659. [PubMed: 14100514]



An Everting Technique for Intraluminal Vascular Suture.—Thomas E. Starzl, Carl G. Groth, and Lawrence Brettschneider.

Fig. 1. Technique of intraluminal everting vascular suture. A, Side-to-side; B, end-to-end; and C, end-to-side.