

Safety and Effectiveness of Moderate Sedation for Radiologic Non-Vascular Intervention

Tae-Hoon Kim, MD

Objective: The purpose of this study was to prospectively characterize the safety and effectiveness of moderate sedation/analgesia for performing radiologic non-vascular abdominal intervention.

Materials and Methods: During a 3-month period, a total of 63 adult patients with a mean age of 64 years (range: 27–82) underwent moderate sedation for 72 radiologic non-vascular interventional procedures. A combination of fentanyl citrate and midazolam hydrochloride, based on the patient's body weight, was intravenously administered until the patient was drowsy and tranquil. The adverse events associated with this moderate sedation were assessed. The visual analog scale format was used to measure the subjective feelings of the patient's pre-procedural anxiety and intraprocedural pain.

Results: The mean total dose per kilogram of body weight of fentanyl used in PTBD was 1.148 μg , it was 1.157 μg for PTGBD, 1 μg for AD, 1 μg for PCN, 1.641 μg for TDC, 1 μg for DJS, 2 μg for BS, 1 μg for GS and 2 μg for RFA. The mean total dose per kilogram of body weight of midazolam was 0.035 mg in PTBD, PTGBD, AD, PCN, DJS, GS and RFA, 0.039 mg in TDC, and 0.043 mg in BS. A temporary reduction of systolic blood pressure to less than 80 mmHg was observed during 5 procedures (6.9%), whereas a temporary elevation of systolic blood pressure above 150 mmHg was observed during 10 procedures (13.8%). A reduction of arterial oxygen saturation to less than 90% was observed during 14 procedures (19.4%). None of the patients required pharmacologic reversal agents or cardiopulmonary resuscitation. The mean anxiety score recorded before all procedures was 5.2 (distressing). The mean pain score during the procedure, which was recorded after all procedures, was 2.9 (mild).

Conclusion: Moderate sedation allows performance of safe and effective radiologic non-vascular intervention, and it is also easy for an interventional radiologist to use. The patients should be continuously monitored to check their vital signs and arterial oxygen saturation during the procedures.

Index terms :

Anesthesia
Abdomen, interventional
procedures

Korean J Radiol 2006;7: 125-130

Received August 11, 2005; accepted after revision December 15, 2005.

Department of Radiology, Dankook University Hospital, Chungnam 330-715, Korea

Address reprint requests to:

Tae-Hoon Kim, MD, Department of Radiology, Dankook University Hospital, 16-5 Anseodong, Cheonan, Chungnam 330-715, Korea.
Tel. (8241)550-6921
Fax. (8241)552-9674
e-mail: radiology@dankook.ac.kr

Performing invasive therapeutic procedures in an interventional radiology suite can be painful and anxiety-provoking (1–5). It may be necessary to provide pharmacologic sedation and analgesia to decrease the patients' anxiety, reduce unwanted movements and to alleviate the patients' discomfort (6). However, achievement of safe and effective sedation and analgesia during interventional procedures is challenging and most radiologists have no formal training for this (7). Radiologists are often poorly informed about the drugs they use and the potential life-threatening problems that are associated with the induction of anesthesia due to drug synergism (8). Although anesthesiologists are the best equipped to provide sedation and analgesia, they are usually not available to attend all radiologic interventional procedures;

the responsibility of administering medication and patient care often falls on the shoulders of the interventional radiologist. However, the provision of sedation and analgesia by properly trained non-anesthesiologists is thought to be safe, if the proper methods of drug administration and patient monitoring are adhered to (6, 9–13). Moderate sedation provides sufficient anxiolysis and control of unwanted movements during most radiologic interventional procedures (6). The purpose of this study is to prospectively evaluate the safety and effectiveness of moderate sedation/analgesia, as performed by an interventional radiologist, during radiologic non-vascular abdominal intervention.

MATERIALS AND METHODS

All the patients who underwent radiologic non-vascular interventional procedures at our clinic during a 3-month period were asked to participate in this study. Patients were excluded from the study if (a) they were younger than 18 years, (b) they had received a sedative or analgesic within 4 hours before the procedure, (c) the procedure was performed on night duty, and (d) the patient was in a critically ill state such as having a systolic blood pressure less than 80 mmHg. A total of 63 adult patients (29 females and 34 males; mean age: 64 years; age range: 27–82 years) fit the selection criteria and they underwent moderate sedation for radiologic non-vascular interventional procedures. The following 72 radiologic non-vascular interventional procedures were performed in 63 adult patients: percutaneous transhepatic biliary drainage (PTBD, $n = 21$), percutaneous transhepatic gallbladder drainage (PTGBD, $n = 13$), percutaneous abscess drainage (AD, $n = 10$), percutaneous nephrostomy (PCN, $n = 10$), PTBD track dilatation for choledochoscopy (TDC, $n = 10$), implanting a ureteral double J stent (DJS, $n = 3$), implanting a biliary stent (BS, $n = 2$), implanting a gastric stent (GS, $n = 2$), and radiofrequency ablation of hepatocellular carcinoma (RFA, $n = 1$). Two different procedures were performed in nine patients at different times: PTBD ($n = 7$) prior to TDC ($n = 6$) and BS ($n = 1$), and PCN ($n = 2$) prior to DJS ($n = 2$).

All patients who underwent percutaneous procedures received a local skin anesthetic of 5–15 mL of 2% lidocaine (Huons, Hwaseong, Korea). The moderate sedation protocol mainly followed the staged-dose system proposed by Skehan et al. (7). The drugs were administered just before the procedure by nurses under the direction of the radiologist. Fentanyl citrate (Guju Pharm. Co., Hwasung, Korea) and midazolam hydrochloride (Roche, Fontenay-sous-Bois, France) were administered intravenously as a slow (30–60 second) bolus infusion in one to five steps (A, B, C, D, E) until the patient was drowsy and tranquil (7).

The doses per step were follows: A, fentanyl at 1 μg per kilogram of body weight; B, midazolam at 0.035 mg/kg; C, fentanyl at 1 μg /kg; D, midazolam at 0.015 mg/kg; E, midazolam as 1–2 mg boluses (maximum: 0.15 mg/kg) (7). The desired end point of sedation was drowsiness, tranquility and a reduced sensitivity to pain (7). The correct level of sedation had been achieved when the patient rested with their eyes closed, but the patient responded to verbal commands or mild physical stimulation; this was a state of moderate sedation (14). We used the first dose of fentanyl to estimate the lead time in our patient. The lead time is the time lapse between the drug injection and the clinical effect. We waited one lead time before proceeding with the next step in the protocol. We titrated the administration of the drug for effect and we stopped the administration of drug when moderate sedation was achieved. We evaluated the duration of the lead time in each procedure.

An interventional radiologist and radiology nurses were designated to monitor each patient and record the clinically important data on a standard form. A pulse oximeter was used to continuously monitor arterial oxygen saturation and ECG, while the blood pressure was automatically measured every 3 minutes. If the oxygen saturation decreased to between 90% and 95%, the patient was asked to take deep breaths. If the saturation decreased to 90% or less, supplemental oxygen was administered at a rate of 4 L/minute via a nasal cannula. As the doses of fentanyl citrate and midazolam hydrochloride were administered, the individual and cumulative doses were recorded on the procedural record form. Standard cardiopulmonary resuscitation equipment was available if needed. Reversal agents for the fentanyl (Naloxone hydrochloride, Samjin Pharm. Co. Ltd., Seoul, Korea), and midazolam (Flumazenil, Roche, Basel, Switzerland) were available during all procedures.

A visual analog scale, graded from 0 to 10, was used to measure the subjective feelings of anxiety and pain. The interventional radiologist questioned the patient about their pre-procedural anxiety before the procedure and about their their intraprocedural pain after the procedure. He asked the patients to describe their anxiety and pain with standardized adjectives that corresponded to numerical scores as follows: 0, none; 1–2, mild; 3–4, discomforting; 5–6, distressing; 7–8, horrible; and 9–10, excruciating. The differences in drug doses and the pain scores between the procedures were tested using one-way analysis of variance. A p -value of less than .05 indicated a statistically significant difference.

RESULTS

The mean procedure time, from the time of drug injection until the radiologist removed his surgical gloves just after

Moderate Sedation for Radiologic Non-Vascular Intervention

the procedure, was 41 minutes (range: 15–90 minutes). The mean total dose of fentanyl used per kilogram of body weight was 1.148 μg in PTBD, 1.157 μg in PTGBD, 1 μg in AD, 1 μg in PCN, 1.641 μg in TDC, 1 μg in DJS, 2 μg in BS, 1 μg in GS and 2 μg in RFA (Table 1). The mean total dose per kilogram of body weight of midazolam was 0.035 mg in PTBD, PTGBD, AD, PCN, DJS, GS and RFA, 0.039 mg in TDC and 0.043 mg in BS (Table 1). Significantly more fentanyl was required in the TDC procedure than in the PTBD, PTGBD, AD and PCN ($p < .05$). The dose of midazolam administered was not significantly different between the procedures. The number of required steps in the ABCDE protocol to achieve the moderate sedation is illustrated in Table 2. No patient was adequately sedated after step A, while 57 procedures were sufficiently drowsy after step B, 11 procedures after step C and four procedures after step D (Table 2). The duration of the lead time in each procedure was 2–5 minutes (mean: 3.8 minutes).

The mean anxiety score recorded before all procedures was 5.2 (distressing). The mean pain score during the procedure, which was recorded after all procedures, was 2.9 (mild). Figure 1 illustrates the distribution of the pre-procedural anxiety scores and the intraprocedural pain scores for all 72 procedures. Pain scores of 4 or less were recorded in 68 (94.4%) procedures. Four patients complained of pain scores greater than 5 during TDC (three patients) and BS (one patient). These patients received an incremental dose of sedative or analgesic and an incremental dose of lidocaine.

Patients received supplemental oxygen (4 L/min) via a nasal cannula in 14 (19.4%) of 72 procedures due to an arterial oxygen saturation level of less than 90%. Patients with an arterial oxygen saturation level between 90% and 95% were asked to take deep breaths in 11 (15.3%) of 72 procedures. All patients with arterial oxygen desaturation responded promptly to an increase in inspired oxygen.

Table 1. Procedures and the Drug Doses

Procedures	Mean BW (kg)	Mean Total Dose of F (μg)	Mean Total Dose of F per kg of BW ($\mu\text{g}/\text{kg}$)	Mean Total Dose of M (mg)	Mean Total Dose of M per kg of BW (mg/kg)
PTBD	54	62	1.148	1.9	0.035
PTGBD	51	59	1.157	1.8	0.035
AD	59	59	1	2.1	0.035
PCN	54	54	1	1.9	0.035
TDC	61	100	1.641	2.4	0.039
DJS	63	63	1	2.2	0.035
BS	36	72	2	1.7	0.043
GS	50	50	1	1.8	0.035
RFA	50	100	2	1.8	0.035

Note.—BW = body weight, F = fentanyl, M = midazolam, PTBD = percutaneous transhepatic biliary drainage, PTGBD = percutaneous transhepatic gallbladder drainage, AD = percutaneous abscess drainage, PCN = percutaneous nephrostomy, TDC = PTBD track dilatation for choledochoscopy, DJS = ureteral double J stent, BS = biliary stent, GS = gastric stent, RFA = Radiofrequency ablation of hepatocellular carcinoma

Table 2. The Number of Steps Required to Achieve the Moderate Sedation

Procedures	A	A+B	A+B+C	A+B+C+D	A+B+C+D+E
PTBD (21)		18	3		
PTGBD (13)		11	2		
AD (10)		10			
PCN (10)		10			
TDC (10)		3	4	3	
DJS (3)		3			
BS (2)			1	1	
GS (2)		2			
RFA (1)			1		
Total (72)	0	57	11	4	0

Note.—A, fentanyl 1 $\mu\text{g}/\text{kg}$; B, midazolam 0.035mg/kg; C, fentanyl 1 $\mu\text{g}/\text{kg}$; D, midazolam 0.015 mg/kg; E, midazolam 1–2 mg boluses, PTBD = percutaneous transhepatic biliary drainage, PTGBD = percutaneous transhepatic gallbladder drainage, AD = percutaneous abscess drainage, PCN = percutaneous nephrostomy, TDC = PTBD track dilatation for choledochoscopy, DJS = ureteral double J stent, BS = biliary stent, GS = gastric stent, RFA = Radiofrequency ablation of hepatocellular carcinoma, () = number

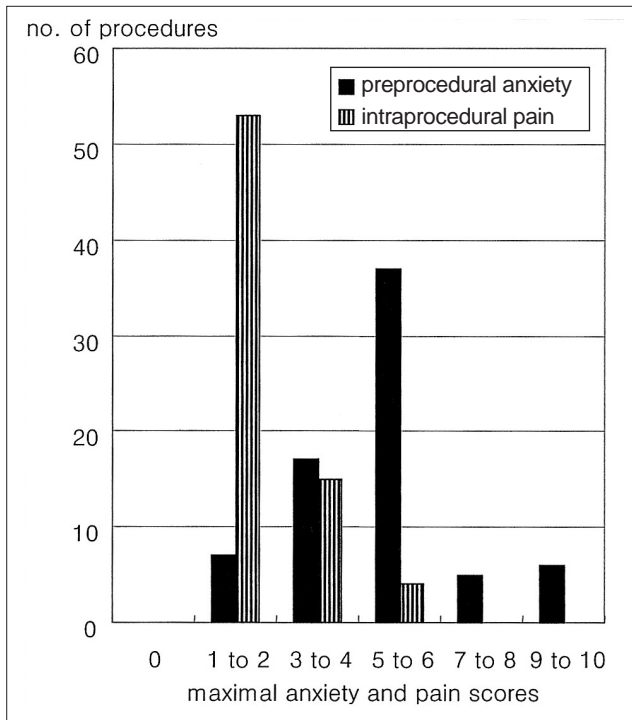


Fig. 1. The pre-procedural anxiety is mainly distributed in the mid-scores (distressing) and the intraprocedural pain is mainly distributed in low-scores (mild). (Note: 0, none; 1–2, mild; 3–4, discomforting; 5–6, distressing; 7–8, horrible; and 9–10, excruciating)

None of the patients required pharmacologic reversal of the sedation because of hypoxia.

In 5 PTBD procedures, the systolic blood pressure temporarily decreased to less than 80 mmHg during the procedure. In all of these patients, the temporal reduction of blood pressure was related to drug administration and the blood pressure decreased when the sedatives were administered. In 10 procedures, the systolic blood pressure increased to more than 150 mmHg during a painful portion of the following procedures: 2 PTBD, 3 TDC, 2 PTGBD, 2 PCN and 1 BS. All of the hemodynamic changes responded to increased intravenous fluid and/or to an incremental dose of sedative, analgesic or local anesthetic. None of the patients required cardiopulmonary resuscitation.

DISCUSSION

When performing procedures, interventional radiologists are responsible for administering safe, effective sedation and analgesia. A 1993 survey of interventional radiologic practices in the British Isles (15) showed that anesthesiologists were present for less than 10% of procedures. Even when patients are critically ill, most interventional procedures are performed without the assistance of anesthesiologists (7). General guidelines have been

published on the use of sedation by non-anesthesiologists (10), but no consensus exists for a single drug administration protocol that is suitable for the majority of interventional radiologic cases (7). Generally, benzodiazepines (BZDs) and opioids are used to achieve safe and effective sedation and analgesia during radiologic interventional procedures. Proper use of these agents improves the patient's satisfaction, reduces the procedure time and stabilizes the hemodynamic status; however, incorrect drug administration or inadequate patient monitoring can precipitate disastrous complications and even death (16–18). All the sedation procedures done in this study were performed by an interventional radiologist with the support of radiology nurses. Midazolam, a short-acting BZD, and fentanyl, a short-acting opioid, were used in this study as a sedative and analgesic, respectively.

Midazolam is a short-acting BZD (6). The onset of its effect is within 2 minutes, and it lasts between 45 and 60 minutes (6). The short-acting sedative effect with rapid recovery, the low risk of respiratory depression, and the antegrade amnesic effects associated with midazolam make it the favored sedative agent used by non-anesthesiologists to achieve moderate sedation during radiology procedures (19). Although this agent is relatively safe, more than 80 deaths have been reported after midazolam use for patients undergoing a variety of medical and surgical procedures (6). Apnea may occur with rapid injection of midazolam (10). The effects of midazolam can be quickly reversed with flumazenil.

Fentanyl is a short-acting opioid (6). The onset of its effect is 2–3 minutes, and the duration of the analgesic effect is between 30 and 60 minutes (6). Fentanyl is favored by most physicians over the other opioids when performing short, painful procedures because of its rapid onset and suitable duration of effect (6). Its principal adverse effect is profound respiratory depression due to depression of the carbon dioxide response and elimination of the hypoxemia response (10). The effects of fentanyl are rapidly reversed with naloxone hydrochloride. The mean procedure time in this study was 41 minutes. The durations of the effects of midazolam and fentanyl were quite adequate since less than 60 minutes was required for most of our non-vascular interventional procedures. The rapid onset of action was also advantageous.

When used in combination, fentanyl and midazolam provide effective analgesia, sedation and amnesia (15, 20–22). However, the two drugs have synergistic effects on respiration (18). As of 1989, there were reports of 49 deaths due to the use of midazolam and opiates in the United States (18). Respiratory depression or apnea is common during moderate sedation.

Moderate Sedation

Sedation refers to the use of pharmacologic and non-pharmacologic means to depress the central nervous system and to reduce patient anxiety and irritability (23). Analgesia is defined as the relief of pain without the intentional production of an altered mental state, the same as in sedation (23). Moderate sedation/analgesia is the depression of consciousness during which time the patients respond purposefully to verbal commands, either alone or the commands are accompanied by light tactile stimulation (6). The patient maintains airway patency and spontaneous ventilation, and the cardiovascular function is usually maintained. Moderate sedation provides sufficient anxiolysis and control of unwanted movements during most interventional radiology procedures (6). This level of sedation is therefore an appropriate target for procedures that are not supervised by an anesthesiologist. The term conscious sedation continues to be used in both the anesthesia and non-anesthesia literature (6). However, this term is no longer included in standards of the American Society of Anesthesiologists (ASA) (10), and its use is being discouraged because it is imprecise and potentially misleading (24–26).

To achieve moderate sedation in this study, the drugs were administered in a stepwise fashion according to the staged-dose system proposed by Skehan et al. (7). The mean total dose of fentanyl and midazolam used in each procedure to achieve the moderate sedation was 68 μg (range, 54–100 μg) and 1.9 mg (range, 1.7–2.4 mg) respectively. No patient was adequately sedated after step A, while the majorities were sufficiently sedated after step B to commence the procedure (Table 2).

Safety

Fentanyl and midazolam may be the ideal drugs for use in many interventional procedures because they have a rapid onset of action (usually less than 3 minutes) and a short duration of effect (usually less than 60 minutes). However, it is unwise to administer both of them simultaneously since they act synergistically (14, 18, 20). The principal concerns with the combination of fentanyl and midazolam are hypoxemia and/or respiratory arrest (7). In one study (18), fentanyl administered at a dose of 2 $\mu\text{g}/\text{kg}$ body weight produced hypoxia (oxygen saturation < 90%) in six of 12 healthy volunteers. The addition of midazolam at a dose of 0.05 mg/kg body weight increased the incidence of hypoxia to 11 (92%) volunteers (18). There is great inter-patient variation in susceptibility to these drugs and the concept of stepwise administration to achieve moderate sedation is a logical way to avoid hypoxia in the more susceptible patients (10).

No patient became apneic in this study. The important role of the radiology nurse is to detect bradypnea and apnea. This is consistent with the guidelines of the ASA, which recommends that “the ventilatory function should be continually monitored by observation” (10). We considered an oxygen saturation of less than 90% to be indicative of clinically significant hypoxemia. Below this level, further desaturation occurs along the steep portion of the oxyhemoglobin dissociation curve, and this causes a greater risk of hypoxia-related complications such as cardiac and cerebral ischemia, and arrhythmia (10). We stopped all the procedures when the oxygen saturation fell to 90% and we then administered supplemental oxygen at a rate of 4 L/minute via a nasal cannula to prevent clinically significant hypoxemia. The oxygen saturation decreased to 90% or lower in only 14 (19.4%) procedures, and all these patients improved after the administration of supplemental oxygen. In the study by Skehan et al. (7), the oxygen saturation decreased to 90% or lower in only 15 (13%) patients. Continuous monitoring of the oxygen saturation and blood pressure are essential for all patients and if possible, the administration of supplemental oxygen is recommended for all patients. Also, reversal agents must be available during all procedures.

Effectiveness

The patients during 68 (94.4%) procedures described pain scores of 4 or less on a scale of 0 to 10 (Fig. 1), with a score of 4 being indicative of discomforting pain. This score represented an acceptable level of analgesia. In total, four patients complained of pain scores in excess of 5 during TDC (three patients) and BS (one patient). Although the patients appeared to have been moderately sedated, they suddenly indicated pain; this occurred mainly during track dilatation for choledochoscopy, which is often a very painful procedure. Additional drugs were administered in a stepwise fashion to achieve moderate sedation subsequent to the painful episodes. Significantly more fentanyl was required during the TDC procedure than during the other procedures. A few other studies have reported on the effectiveness of analgesia during interventional radiologic procedures. Ayre-Smith (22) described achieving “favorable results” with fentanyl and midazolam in a preliminary report of 12 patients who underwent unspecified interventional radiologic procedures. Miller and Wall (27) reported effective analgesia in all 100 patients who underwent sedation and analgesia for radiologic procedures with a combination of fentanyl and diazepam. In one large study on pain control during interventional biliary procedures (2), epidural anesthesia was effective in 91% of the cases, while intravenous sedation was successful in only 50%. However,

this study may have been biased against intravenous sedation because most of the patients received single-agent therapy with a narcotic such as meperidine or morphine, without the synergistic benefit of a benzodiazepine.

It is important to stress that the effective use of local anesthetic is a vital component of interventional radiology, and particularly for percutaneous non-vascular intervention. Sufficient infiltration with a local anesthetic may markedly reduce the requirement for sedation and analgesic (28). Sufficient use of a local anesthetic may have substantially reduced the pain associated with track dilatation in the three patients of this study for whom the pain was poorly controlled.

The major limitation of this study was that we didn't make comparisons with the control groups such as a group using only lidocaine as a local anesthetic and a group using only demerol as an analgesic. Another limitation was the small number of cases of DJS, BS, GS and RFA; thus, these procedures were excluded from the statistical analysis.

In conclusion, moderate sedation during radiologic non-vascular intervention is both safe and effective. Moderate sedation is easy to achieve in patients and it is useful for interventional radiologists. However, all patients undergoing moderate sedation should be continuously monitored to check the vital signs and arterial oxygen saturation. Administering supplemental oxygen is also recommended for all patients, if possible.

Acknowledgements

The author thanks RNs G. J. Jung and S. O. Kim for assistance in performing this study.

References

- Mueller PR, Biswal S, Halpern EF, Kaufman JA, Lee MJ. Interventional radiologic procedures: patient anxiety, perception of pain, understanding of procedure, and satisfaction with medication—a prospective study. *Radiology* 2000;215:684-688
- Harshfield DL, Teplick SK, Brandon JC. Pain control during interventional biliary procedures: epidural anesthesia vs i.v. sedation. *AJR Am J Roentgenol* 1993;161:1057-1059
- Lang EV, Chen F, Fick LJ, Berbaum KS. Determinants of intravenous conscious sedation for arteriography. *J Vasc Interv Radiol* 1998;9:407-412
- Kennedy PT, Kelly IM, Loan WC, Boyd CS. Conscious sedation and analgesia for routine aortofemoral arteriography: a prospective evaluation. *Radiology* 2000;216:660-664
- Wagner HJ, Nowacki J, Klose KJ. Propofol versus midazolam for sedation during percutaneous transluminal angioplasty. *J Vasc Interv Radiol* 1996;7:673-680
- Martin ML, Lennox PH. Sedation and analgesia in the interventional radiology department. *J Vasc Interv Radiol* 2003;14:1119-1128
- Skehan SJ, Malone DE, Buckley N, Matsumoto S, Rawlinson J, Ting G, et al. Sedation and analgesia in adult patients: evaluation of a staged-dose system based on body weight for use in abdominal interventional radiology. *Radiology* 2000;216:653-659
- Whitwam JG. Minimally invasive therapy—implications for anesthesia. *Anesthesia* 1993;48:937-939
- Bluemke DA, Breiter SN. Sedation procedures in MR imaging: safety, effectiveness, and nursing effect on examinations. *Radiology* 2000;216:645-652
- American Society of Anesthesiologists Task Force on Sedation and Analgesia by Non-Anesthesiologists. Practice guidelines for sedation and analgesia by non-anesthesiologists. *Anesthesiology* 2002;96:1004-1017
- Innes G, Murphy M, Nijssen-Jordan C, Ducharme J, Drummond A. Procedural sedation and analgesia in the emergency department. Canadian Consensus Guidelines. *J Emerg Med* 1999;17:145-156
- Krauss B, Green SM. Sedation and analgesia for procedures in children. *N Engl J Med* 2000;342:938-945
- Arepally A, Oechsle D, Kirkwood S, Savader SJ. Safety of conscious sedation in interventional radiology. *Cardiovasc Intervent Radiol* 2001;24:185-190
- Monk TG. Clinical applications of monitored anesthesia care. *Minim Invasive Therapy* 1994;3:17S-20S
- McDermott VG, Chapman ME, Gillespie I. Sedation and patient monitoring in vascular and interventional radiology. *Br J Radiol* 1993;66:667-671
- Yaster M, Nichols DG, Deshpande JK, Wetzel RC. Midazolam-fentanyl intravenous sedation in children: case report of respiratory arrest. *Pediatrics* 1990;86:463-467
- Michalodimitrakis M, Christodoulou P, Tsatsakis AM, Askoxilakis I, Stiakakis I, Mouzas I. Death related to midazolam overdose during endoscopic retrograde cholangiopancreatography. *Am J Forensic Med Pathol* 1999;20:93-97
- Bailey PL, Pace NL, Ashburn MA, Moll JW, East KA, Stanley TH. Frequent hypoxemia and apnea after sedation with midazolam and fentanyl. *Anesthesiology* 1990;73:826-830
- Cragg AH, Smith TP, Berbaum KS, Nakagawa N. Randomized double-blind trial of midazolam/placebo and midazolam/fentanyl for sedation and analgesia in lower-extremity angiography. *AJR Am J Roentgenol* 1991;157:173-176
- Ben-Shlomo I, Abd-el-Khalim H, Ezry J, Zohar S, Tverskoy M. Midazolam acts synergistically with fentanyl for induction of anaesthesia. *Br J Anaesth* 1990;64:45-47
- Lind LJ, Mushlin PS. Sedation, analgesia, and anesthesia for radiologic procedures. *Cardiovasc Intervent Radiol* 1987;10:247-253
- Ayre-Smith G. Fentanyl and midazolam: an alternative to diazepam. *Radiology* 1987;164:285
- Sacchetti A, Schafermeyer R, Geradi M, Graneto J, Fuerst RS, Cantor R, et al. Pediatric analgesia and sedation. *Ann Emerg Med* 1994;23:237-250
- Murphy MF. Sedation. *Ann Emerg Med* 1996;27:461-463
- Green SM, Krauss B. Procedural sedation terminology: moving beyond “conscious sedation”. *Ann Emerg Med* 2002;39:433-435
- Cote CJ. “Conscious sedation”: time for this oxymoron to go away! *J Pediatr* 2001;139:15-17
- Miller DL, Wall RT. Fentanyl and diazepam for analgesia and sedation during radiologic special procedures. *Radiology* 1987;162:195-198
- Lundgren S, Rosenquist JB. Amnesia, pain experience, and patient satisfaction after sedation with intravenous diazepam. *J Oral Maxillofac Surg* 1983;41:99-102