

CASE REPORT

## Schistosomal appendicitis: Incidence in Japan and a case report

Tadashi Terada

Tadashi Terada, Department of Pathology, Shizuoka City Shimizu Hospital, Shizuoka 424-8636, Japan

Author contributions: Terada T contributed all to this paper.

Correspondence to: Tadashi Terada, MD, PhD, Department of Pathology, Shizuoka City Shimizu Hospital, Miyakami 1231 Shimizu-Ku, Shizuoka 424-8636,

Japan. [piyo0111jp@yahoo.co.jp](mailto:piyo0111jp@yahoo.co.jp)

Telephone: +81-54-3361111 Fax: +81-54-3361315

Received: December 30, 2008 Revised: February 23, 2009

Accepted: March 2, 2009

Published online: April 7, 2009

[com/1007-9327/15/1648.asp](http://www.wjgnet.com/1007-9327/15/1648.asp) DOI: <http://dx.doi.org/10.3748/wjg.15.1648>

### Abstract

Schistosomal appendicitis is very rare in developed countries like the USA, Europe, and Japan. The author reviewed 311 pathologic archival specimens of vermiform appendix over the past 10 years. One case of schistosomal appendicitis was recognized. Therefore, the incidence of this disease was 0.32% in all appendices surgically resected in our hospital. The patient was a 41-year-old woman presenting with lower abdominal pain. She was a sailor traveling to many countries including endemic areas. Physical examination, laboratory data, and imaging modalities suggested an acute appendicitis, and appendectomy was performed under the diagnosis of ordinary appendicitis. Histologically, numerous schistosomal eggs were present in the vasculatures throughout the appendiceal walls. Some of the eggs were calcified. Stromal foreign body reaction was also recognized. The appendicitis was phlegmonous consisting of severe infiltrations of neutrophils and eosinophils. Acute serositis was also noted. Examination of feces revealed numerous eggs of *Schistosoma mansoni*. Clinicians should be aware of schistosomal appendicitis.

© 2009 The WJG Press and Baishideng. All rights reserved.

**Key words:** Appendix; Histopathology; Pathologic archival specimens; Schistosomiasis; Acute appendicitis

**Peer reviewer:** Maurice A Cerulli, MD, FACP, FACG, Division of Gastroenterology and Hepatology, New York Methodist Hospital, Brooklyn, New York 11215, United States

Terada T. Schistosomal appendicitis: Incidence in Japan and a case report. *World J Gastroenterol* 2009; 15(13): 1648-1649 Available from: URL: <http://www.wjgnet.com>

### INTRODUCTION

Schistosomiasis is caused by *Schistosoma mansoni* or *Schistosoma japonica*, and is a disease of waterborne trematode infestation. Schistosomal appendicitis is very rare in developed countries like the USA, Europe, and Japan<sup>[1-5]</sup>. However, it is prevalent in endemic areas such as Africa and South Asia<sup>[1-5]</sup>. In Japan, Yamanashi and Fukuoka prefectures are endemic areas. However, the incidence and pathological features of schistosomal appendicitis are not known. Therefore, the author herein reports the incidence and pathological features of this disease in Japan.

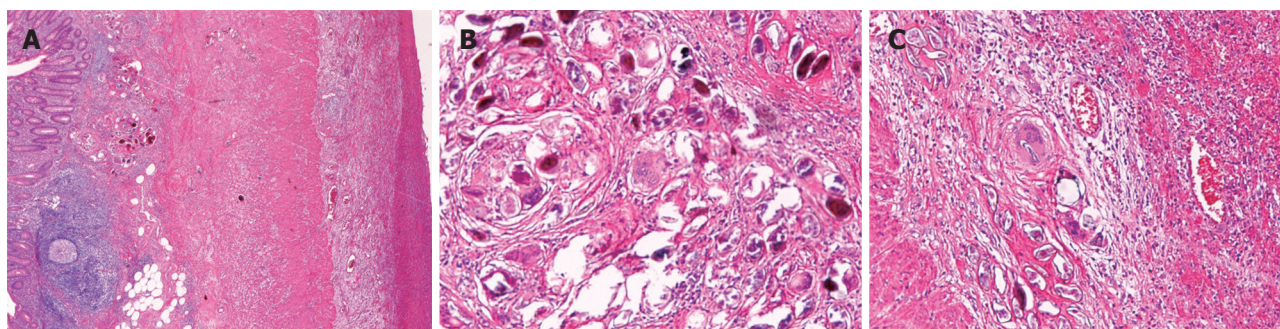
### CASE REPORT

The author re-examined 311 pathologic archival specimens of vermiform appendix over the past 10 years. Of these specimens, one case of schistosomal appendicitis was recognized. Therefore, the incidence of this disease was 0.32% of all appendices surgically resected in our hospital. The specimen was from a 41-year-old woman, who was a sailor traveling to many countries including endemic areas, who had complained of lower abdominal pain. Physical examination was suggestive of acute appendicitis. Blood laboratory data showed leukocytosis. Imaging modalities including CT indicated an appendiceal swelling. An appendectomy was performed under the clinical diagnosis of ordinary appendicitis.

Histologically, numerous schistosomal eggs were present in the vasculatures throughout the appendiceal walls (Figure 1A). This finding was unexpected. Some of the eggs were calcified (Figure 1B). Stromal foreign body reaction was also recognized (Figure 1B). Severe infiltrations of neutrophils and eosinophils were recognized (Figure 1C). Acute serositis was also noted (Figure 1A). Examination of feces revealed numerous eggs of *Schistosoma mansoni*. The involvement of other organs was unclear.

### DISCUSSION

Schistosomiasis is a waterborne parasitic disease caused by *Schistosoma mansoni* and *Schistosoma japonica*. This



**Figure 1** Histologic findings of schistosomal appendicitis. A: Low power view of the appendiceal walls in schistosomal appendicitis. Acute inflammation is recognized throughout the walls. Schistosomal eggs are seen in the mucosa and muscular layer. The serosa shows acute serositis (right). HE,  $\times 40$ ; B: Schistosomal eggs in the mucosa. Foreign body granulomatous reaction is recognized. Some eggs show calcification. HE,  $\times 200$ ; C: Schistosomal eggs in the subserosa. The eggs were located within vasculatures. Severe infiltrations of neutrophils and hemorrhage are recognized. HE,  $\times 200$ .

disease is endemic and particularly prevalent in Africa and South Asia<sup>[1-5]</sup>. Our hospital is located in a non-endemic area. Schistosomiasis is a disease of intestine and liver, where the parasite resides and produces eggs in the vasculatures.

The incidence of schistosomal appendicitis is unclear in Japan. The present study revealed that the incidence was 0.32% of all vermiform appendices resected.

The present case is pathologically typical of schistosomal appendicitis, and feces examination strongly supported the diagnosis. Clinically, schistosomal appendicitis was not considered, and clinicians were first informed after pathologic examination. The present patient was a sailor traveling to many countries including endemic areas. Thus, clinicians should be aware of schistosomal appendicitis.

It is uncertain whether schistosomiasis of the vermiform appendix induces acute appendicitis<sup>[1]</sup>. However, it is now thought that appendiceal schistosomiasis may cause acute appendicitis. This may be due to ischemic changes caused by egg emboli. This situation may diminish mucosal immunity, thus leading to bacterial infection.

In endemic areas like Nigeria, Badmos *et al*<sup>[4]</sup> reported that appendices with schistosomiasis were present in 35/843 (4.2%) of surgically resected cases. Of these 35 positive cases, 23 (65.7%) were associated with acute appendicitis, while the remaining 12 cases (34.3%) were not associated with inflammation. Thus,

the presence of the parasite does not always give rise to acute appendicitis. In developed countries like the USA, Nandipati *et al*<sup>[5]</sup> reported that schistosomal appendicitis was found in 3/1690 (0.2%) of surgically resected cases. All three cases were African Americans<sup>[5]</sup>. Thus, in developed countries, schistosomal appendicitis is preferentially found in travelers or in an endemic area population.

In summary, the incidence of schistosomal appendicitis is 0.34% in Japan. The present patient with this disease was a sailor traveling to many countries. Thus, clinicians should be aware of schistosomal appendicitis.

## REFERENCES

- 1 Satti MB, Tamimi DM, Al Sohaibani MO, Al Quorain A. Appendicular schistosomiasis: a cause of clinical acute appendicitis? *J Clin Pathol* 1987; **40**: 424-428
- 2 Weber G, Borer A, Zirkin HJ, Riesenber K, Alkan M. Schistosomiasis presenting as acute appendicitis in a traveler. *J Travel Med* 1998; **5**: 147-148
- 3 Adehossi E, Parola P. Schistosomal appendicitis. *Lancet Infect Dis* 2004; **4**: 498
- 4 Badmos KB, Komolafe AO, Rotimi O. Schistosomiasis presenting as acute appendicitis. *East Afr Med J* 2006; **83**: 528-532
- 5 Nandipati K, Parithivel V, Niazi M. Schistosomiasis: a rare cause of acute appendicitis in the African American population in the United States. *Am Surg* 2008; **74**: 221-223

S- Editor Cheng JX L- Editor Webster JR E- Editor Ma WH