

Eikenella corrodens Cellulitis and Arthritis of the Knee

SETH A. FLESHER AND EDWARD J. BOTTONE*

Clinical Microbiology Laboratories, The Mount Sinai Hospital, New York, New York 10029-6574

Received 8 May 1989/Accepted 26 July 1989

Severe cellulitis and septic arthritis due to *Eikenella corrodens* and a viridans group streptococcus developed following dental manipulation in a patient with a history of hemarthrosis. Correct diagnosis was achieved by recognition of *E. corrodens* on a culture of a knee aspirate. Antimicrobial (ampicillin) therapy resulted in a therapeutic response.

Eikenella corrodens, a small, *Haemophilus* spp.-like gram-negative microorganism, is a human pathogen which produces, alone or in association with other bacterial species, a variety of systemic, local, and cutaneous infections. Among the reported sites of involvement are skin (1-3, 12), bone (4, 19, 21), brain (9, 13), lung (17, 24, 26), orbital sinuses (2, 3, 23), various abscesses (2, 3, 5, 8, 17, 25), blood (2, 10, 18; J. G. Sinkovics, C. Plager, and K. Mills, Letter, Ann. Intern. Med. 90:991, 1979), and root canal system (15).

In most instances, the pathogenesis of *E. corrodens* infection is thought to originate from the human oral cavity, either directly, e.g., through trauma (7, 12, 23), or indirectly as a consequence of hematogenous spread from an infected focus, e.g., sinus, middle ear, or the oral cavity itself following dental manipulation (6, 7, 11; C. O. Burdick, D. Erasmus, A. Jayaram, P. Schield, and W. Kosch, Letter, J. Am. Med. Assoc. 248:1972-1973, 1973). In the present report, we document a case of severe cellulitis and septic arthritis of the knee caused by *E. corrodens* and an alpha-hemolytic streptococcus which developed following dental manipulation in a patient with a history of hemarthrosis.

Case report. A 22-year-old patient with a history of a bleeding tendency and previous injury to his left medial meniscus was admitted with a 1-day complaint of severe burning pain in his left knee and an overlying erythematous region.

The patient's bleeding tendency had been documented 15 years earlier and was subsequently determined to be a storage-release disorder of platelets, resulting in an aspirin-like clotting defect. Two years previously, an arthrogram showed fraying of the left meniscus concomitant with osteoarthritic changes. The patient had experienced hemarthroses into his left knee about twice yearly for 8 years, documented by aspiration.

Four weeks prior to admission, the patient began to experience discomfort and swelling in his left knee similar to that noted on previous occasions. Two weeks later, while the knee was still painful, the patient underwent dental cleaning without antibiotic prophylaxis. Seven days later, a severe pain developed in his left knee, with accompanying left inguinal node tenderness and adenopathy. Fever (37.4°C) was present at that time, and several episodes of shaking chills occurred. The following day, the patient was admitted.

On physical examination, the knee was hot, red, swollen, and exquisitely tender. The erythema extended several inches below the patella on the anterior aspect of the tibia.

The superior half of the patella was unaffected, as was the popliteal fossa. The patella floated. The range of motion was limited secondarily to the pain and swelling. The initial clinical impression was septic arthritis or cellulitis with a sympathetic effusion.

The knee was aspirated; crystals were absent, but Gram staining revealed gram-positive cocci in pairs and short chains and polymorphonuclear leukocytes. The aspirate was inoculated into 5% sheep blood (BBL Microbiology Systems, Cockeysville, Md.) and chocolate and MacConkey agars and incubated at 35°C under reduced oxygen tension (5% CO₂) and under anaerobic conditions (Gaspak; BBL Microbiology Systems). The patient was started on intravenous penicillin (12,000,000 U daily) and oxacillin (8 g daily). After 2 days of therapy, the erythema extended down to the ankle and the area around the patella was still extremely painful. There was pitting tibial edema without tenderness. A lymphangitic streak extended from the patella to the inguinal nodes, which were coalescing. Penicillin and oxacillin were discontinued when *E. corrodens* was identified on culture, and ampicillin (2 g every 4 h) was begun. The following day, the cellulitis coalesced, forming a bleb (3 by 5 cm) below the patella (Fig. 1). The patient improved rapidly and was discharged 6 days later. To date, 4 years later, the patient has remained asymptomatic.

Bacteriology. After 48 h of incubation, aerobic and anaerobic cultures on blood and chocolate agars showed pinpoint colonies surrounded by a zone of greenish discoloration and flat, radially spreading colonies with a characteristic odor suggestive of hypochlorite bleach. Smears of the former colonies revealed gram-positive cocci in pairs, while the latter showed slender gram-negative stick-like rods. The first isolate was identified as an alpha-hemolytic streptococcus but was not identified to species level, and the second was identified as *E. corrodens* on the basis of both its inability to utilize carbohydrates oxidatively or fermentatively and its ability to produce oxidase and nitrate reductase but not catalase. Retrospectively, because the recovery of *E. corrodens* was achieved culturally, the original Gram-stained smears of the aspirated material were reevaluated, and small gram-negative coccobacilli were observed within polymorphonuclear cells.

Discussion. The case of *E. corrodens* cellulitis and septic arthritis reported here illustrates several of the microbiologic and pathogenetic factors that underscore infections with this microbial species.

Microbiologically, the recognition of *E. corrodens* in an infection process is often delayed because this organism has small coccobacillary morphology in purulent exudates, slow growth in bacteriologic media (often requiring 48 h of incu-

* Corresponding author.

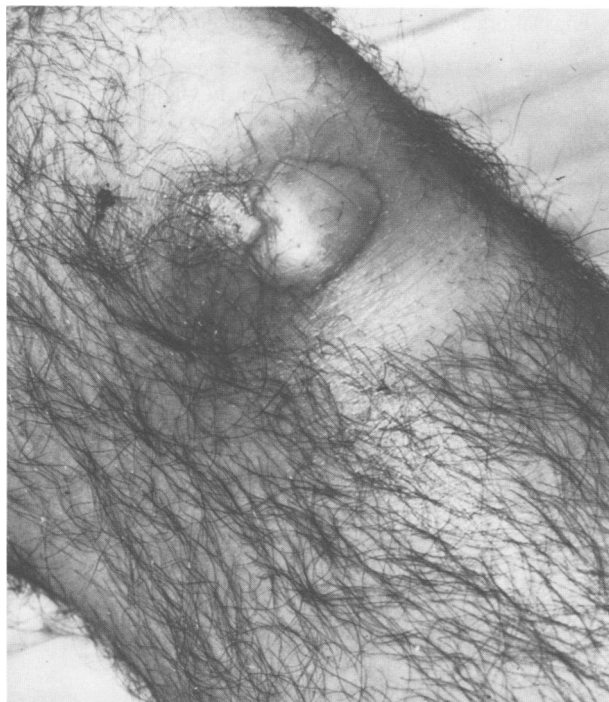


FIG. 1. Resolving *E. corrodens* cellulitis above the left knee following administration of ampicillin.

bation), and usual flat colonial morphology, which may preclude easy visualization. In several reported instances in which a Gram-stained smear of an exudate was examined prior to cultivation, either *E. corrodens* was not observed (8, 9, 21) or a few gram-negative rods were noted (24). Subsequently, however, *E. corrodens* was isolated from the clinical specimens. In the present case, retrospective evaluation of the Gram stain of the knee aspirate revealed small gram-negative coccobacilli morphologically compatible with *E. corrodens*.

The second parameter associated with delayed recognition of *E. corrodens* in clinical material is its slow growth in the absence of CO₂ supplementation; in addition, its flat, discoid colonial morphology, although distinct when recognized, is easily overlooked among the raised colonies of other microbial species which are often present (2). In the case under discussion, *E. corrodens* was initially suspected on the basis of the characteristic hypochlorite odor accompanying its growth on blood and chocolate agars despite the clear visualization of colonies. Inclining the petri plate to allow incident light to impinge on the agar surface subsequently revealed the early appearance of the characteristic flat colonies (2).

Pathogenetically, most *E. corrodens* infections are associated with acquisition of the organism from the oral cavity (6, 7, 11, 14; Burdick et al., Letter). Because infections which originate from this source are suspected to contain anaerobes and staphylococci, empiric therapy while culture results are awaited often comprises clindamycin or metronidazole, oxacillin, and gentamicin, agents to which *E. corrodens* is resistant (13). Persistence of the infection process through this antibiotic regimen often necessitates repeat culture prior to the successful isolation of *E. corrodens* (7, 9, 16). As *E. corrodens* infections are frequently polymicrobial (2, 3, 8, 9, 12, 13, 15, 20, 22–24, 26; Burdick et al., Letter),

antibiotic therapy directed primarily against the concomitant flora, while often not curative, enhances the subsequent recovery of *E. corrodens* (25).

Given all the considerations presented above, *E. corrodens* should be regarded as a potential incitant in an infection process originating from interactions with the oral microflora either directly, e.g., through penetrating injury, or indirectly, e.g., through dental manipulation. Careful examination of Gram-stained smears of purulent material, awareness of the necessity of increased CO₂ tension for growth, and inclination of inoculated petri dishes to enhance colony visualization should all facilitate the recovery of *E. corrodens*. As described for our patient, early detection of *E. corrodens* and administration of specific antimicrobial therapy will decrease the morbidity associated with delay in recognition of this important human pathogen.

We acknowledge the expert professional care rendered the patient by Shalom Z. Hirschman and Michael L. Greenberg.

LITERATURE CITED

1. Barton, L. L., and L. E. Anderson. 1976. Paronychia caused by HB-1 organisms. *Pediatrics* 54:372–373.
2. Bottone, E. J., J. Kittick, Jr., and S. S. Schneierson. 1973. Isolation of bacillus HB-1 from human clinical sources. *Am. J. Clin. Pathol.* 59:560–566.
3. Brooks, G. F., J. M. O'Donoghue, J. P. Rissing, K. Soades, and J. W. Smith. 1974. *Eikenella corrodens*, a recently recognized pathogen: infections in medical-surgical patients and in association with methylphenidate abuse. *Medicine (Baltimore)* 53:325–342.
4. Carruthers, M. M., and H. M. Sommers. 1973. *Eikenella corrodens* osteomyelitis. *Ann. Intern. Med.* 79:900.
5. Cheng, A. F., D. W. K. Man, and G. L. French. 1988. Thyroid abscess caused by *Eikenella corrodens*. *J. Infect.* 16:181–185.
6. Decker, M. D., B. S. Graham, E. B. Hunter, and S. M. Liebowitz. 1986. Endocarditis and infections of intravascular devices due to *Eikenella corrodens*. *Am. J. Med. Sci.* 292:209–212.
7. De Mello, F. J., and M. S. Leonard. 1979. *Eikenella corrodens*: a new pathogen. *Oral Surg. Oral Med. Oral Pathol.* 47:401–404.
8. Dorff, G. J., L. J. Jackson, and M. W. Rytel. 1974. Infections with *Eikenella corrodens*, a newly recognized human pathogen. *Ann. Intern. Med.* 80:305–309.
9. Emerson, A. M., and F. Mills. 1976. Recurrent meningitis and brain abscess caused by *Eikenella corrodens*. *Postgrad. Med. J.* 54:343–348.
10. Geraci, J. E., P. E. Hermans, and J. A. Washington II. 1974. *Eikenella corrodens* endocarditis. Report of cure in two cases. *Mayo Clin. Proc.* 49:950–953.
11. Glassman, A. B., and J. S. Simpson. 1975. *Eikenella corrodens*: a clinical problem. *J. Am. Dent. Assoc.* 91:1237–1241.
12. Goldstein, E. J. C., D. M. Citron, B. Wield, U. Blachman, V. L. Sutter, T. A. Miller, and S. M. Finegold. 1978. Bacteriology of human and animal bite wounds. *J. Clin. Microbiol.* 8:667–672.
13. Goldstein, E. J. C., and M. S. Gombert. 1983. *Eikenella corrodens*: a new perspective, p. 1–43. In E. J. Bottone (ed.), *Unusual microorganisms. Gram negative fastidious species*. Marcel Dekker, Inc., New York.
14. Goldstein, E. J. C., T. A. Miller, D. M. Citron, and S. M. Finegold. 1978. Infections following clenched-fist injury: a new perspective. *J. Hand Surg.* 3:455–457.
15. Goodman, A. D. 1977. *Eikenella corrodens* isolated in oral infections of dental origin. *Oral Surg.* 44:128–134.
16. Johnson, S. M., and G. A. Pankey. 1976. *Eikenella corrodens* osteomyelitis, arthritis, and cellulitis of the hand. *South. Med. J.* 69:535–539.
17. Kaplan, J. M., G. H. McCracken, and J. D. Nelson. 1973. Infections in children caused by the HB group of bacteria. *J. Pediatr.* 82:398–403.
18. Khairat, O. 1967. *Bacteroides corrodens* isolated from bacter-

- aemias. J. Pathol. Bacteriol. **92**:29-40.
19. **Litwack, K., and K. Borchardt.** 1973. Osteomyelitis caused by a *Bacteroides corrodens*-like organism (HB-1). Clin. Med. **80**: 21-40.
 20. **Marsder, H. B., and W. A. Ayde.** 1971. Isolation of *Bacteroides corrodens* from infection in children. J. Clin. Pathol. **24**:117-119.
 21. **Polin, K., and S. T. Shulman.** 1981. *Eikenella corrodens* osteomyelitis. Pediatrics **70**:462-463.
 22. **Rubenstein, J. E., M. F. Lieberman, and N. Gadoth.** 1976. Central nervous system infection with *Eikenella corrodens*: report of two cases. Pediatrics **57**:264-265.
 23. **Schwartz, H., M. A. Baskin, A. Ilkiw, and L. Le Beau.** 1979. An unusual organism causing orbital cellulitis. Br. J. Ophthalmol. **63**:710-712.
 24. **St. John, M. A., A. A. Belda, A. Matlow, and C. G. Prober.** 1981. *Eikenella corrodens* empyema in children. Am. J. Dis. Child. **135**:415-417.
 25. **Stoloff, A. L., and M. L. Gillies.** 1986. Infections with *Eikenella corrodens* in a general hospital: a report of 33 cases. Rev. Infect. Dis. **8**:50-53.
 26. **Suwanagool, S., M. M. Rothkop, S. M. Smith, D. Le Blanc, and R. Eng.** 1983. Pathogenicity of *Eikenella corrodens* in humans. Arch. Intern. Med. **143**:2265-2268.