

Burn Wound Zygomycosis Caused by *Apophysomyces elegans*

RODNEY D. COOTER,^{1*} IRENE S. LIM,² DAVID H. ELLIS,³ AND IAN O. W. LEITCH¹

Department of Plastic and Reconstructive Surgery, Royal Adelaide Hospital,¹ and Division of Clinical Microbiology, Institute of Medical and Veterinary Science,² Adelaide, South Australia 5000, and Mycology Unit, Adelaide Children's Hospital, North Adelaide, South Australia 5006,³ Australia

Received 11 October 1989/Accepted 15 June 1990

A case of zygomycosis caused by *Apophysomyces elegans* in a patient having 25% full-thickness burns is described. Amputation of the leg was necessary to control rapid tissue invasion. The fungus was isolated from soil in the burn environment.

Fungi of the class *Zygomycetes*, order *Mucorales*, are saprophytic molds that subsist on decaying vegetable matter in soil (8). Within the order *Mucorales*, the family *Mucoraceae* is the most important medically, since it has four major genera known to contain species capable of causing zygomycosis; these genera are *Absidia*, *Mucor*, *Rhizomucor*, and *Rhizopus*. In 1979, Misra et al. described a new genus they classified in the *Mucoraceae* that was isolated from soil samples collected from a mango orchard in northern India (7). Because of its impressive funnel-shaped apophysis, the authors were prompted to describe the fungus as *Apophysomyces elegans* (7). Because reports of *A. elegans* as a human pathogen are rare (6, 10; R. E. Winn, P. D. Ramsey, and E. D. Adams, Clin. Res. 30:382A, 1982; R. E. Winn, M. G. Rinaldi, P. Ramsey, and E. D. Adams, Abstr. Annu. Meet. Am. Soc. Microbiol. 1984, F29, p. 297), we present a case of zygomycosis due to *A. elegans* in a patient with full-thickness burns that were contaminated with soil.

A 45-year-old man was admitted to the Royal Darwin Hospital, Darwin, Northern Territory, Australia, 12 h after sustaining 25% full-thickness burns to his face, chest, arms, and feet. After resuscitation and cleaning of the heavily soiled wounds, he was transferred to the Royal Adelaide Hospital, Adelaide, South Australia, Australia, 4 days later with respiratory distress and high fever. He improved sufficiently for split skin grafting to be performed on both hands and feet 2 weeks later. The grafts took well, and his respiratory distress and fever soon settled. Two weeks later he became febrile again and developed subcutaneous swelling on the medial aspect of the right ankle. This swelling was aspirated, but no organisms were seen or cultured. Despite flucloxacillin therapy, he became systemically toxic. Blisters and, later, sinuses discharging thick pus developed (Fig. 1). A Gram stain of the pus showed no bacteria, but fungal hyphae were detected by wet mount. Twenty-four hours later, a zygomycete was isolated on blood agar (MEDVET Science Co. Ltd., Adelaide, South Australia, Australia) and Sabouraud dextrose agar. Amphotericin B therapy was commenced, and the necrotic tissue was debrided (Fig. 2). Below-knee amputation was performed a week later because repeated aggressive surgical debridements failed to contain the rapidly progressive infection, resulting in tissue necrosis. The patient made a rapid postoperative recovery, and amphotericin B therapy was continued for a further 2 weeks.

Macroscopic examination of the below-knee amputation specimen showed extensive inflammation with ligament ne-

crolosis and periosteal inflammation but without bony involvement. Multiple draining sinuses around the ankle contained necrotic tissue resembling anchovy paste. The ankle joint contained pus, and the posterior tibial vessels were surrounded by an inflammatory mass.

Microscopic examination revealed a necrotizing inflammatory process involving fat, fibrous tissue, and muscle with multiple confluent abscesses. In some areas of necrosis there were broad, infrequently septate, hyaline, thin-walled hyphae having focal bulbous vesicles and irregular, nondichotomous branching characteristic of the zygomycetes in tissue. Although there was no obvious angioinvasion, many blood vessels contained recent thrombi. Inflamed and necrotic

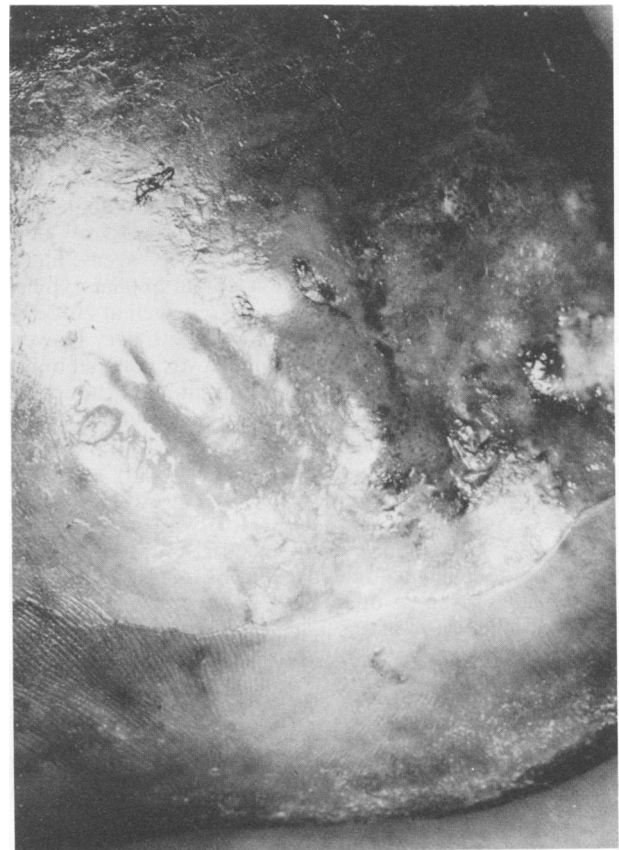


FIG. 1. Blistering on medial aspect of right foot was the first cutaneous sign of infection.

* Corresponding author.

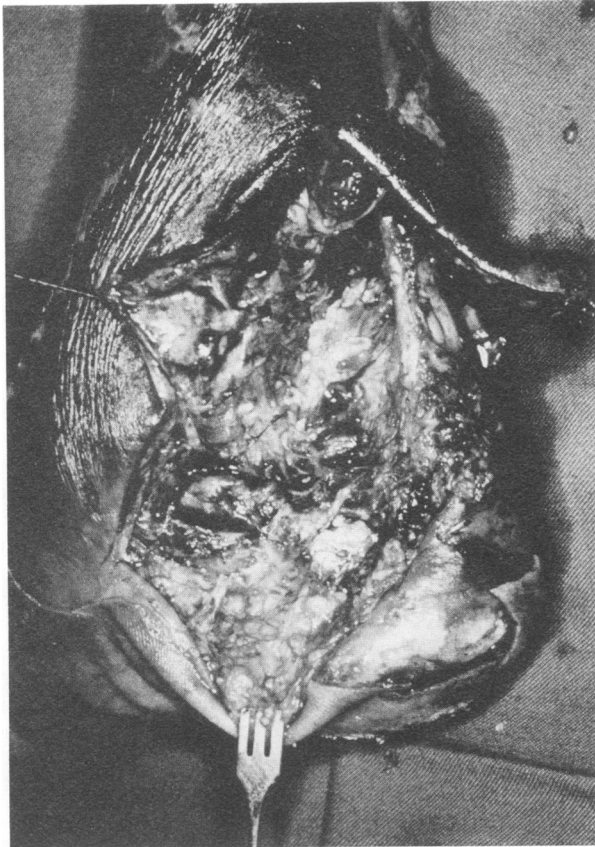

FIG. 2. Necrotic tissue around the posterior tibial vessels at surgical debridement.

nerves were noted. The ankle joint synovium was inflamed and necrotic with surface pus and fibrin containing hyphae.

Fungal cultures of tissue inoculated onto Sabouraud dextrose agar (Oxoid Ltd., London, England) containing chloramphenicol (0.25 mg/ml) and gentamicin (26 µg/ml) yielded fast-growing, white downy colonies with no reverse pigment that were composed of broad, nonseptate hyphae typical of a zygomycetous fungus. The fungus grew well at 26, 37, and 42°C and became creamy white with buff with age. However, laboratory identification of this fungus was delayed because of the failure of the mold to sporulate on the primary isolation medium or upon subsequent subculture onto potato dextrose agar (Oxoid). The cultural characteristics described above and the failure to sporulate on routinely used media were reminiscent of the characteristics observed in clinical isolates of *Saksenaea vasiformis* (1). However, when sporulation was stimulated by the use of a nutrient-deficient medium like cornmeal-glucose-sucrose-yeast extract agar (3), typical sporangia of *A. elegans* were observed after 2 weeks of incubation at 26°C.

This rare thermotolerant zygomycete was readily recognizable by its rapid growth at 42°C and by its characteristic sporangial morphology. Sporangioophores were unbranched, straight or curved, slightly tapering towards the apex, up to 200 µm long, 3 to 5 µm in width near the apophysis, and hyaline when young but developing a sepia to brown pigmentation and a conspicuous subapical thickening 10 to 16 µm below the apophysis with age (see Fig. 4). Sporangioophores arose at right angles from the aerial hyphae and often had a septate basal segment resembling the "foot cell"

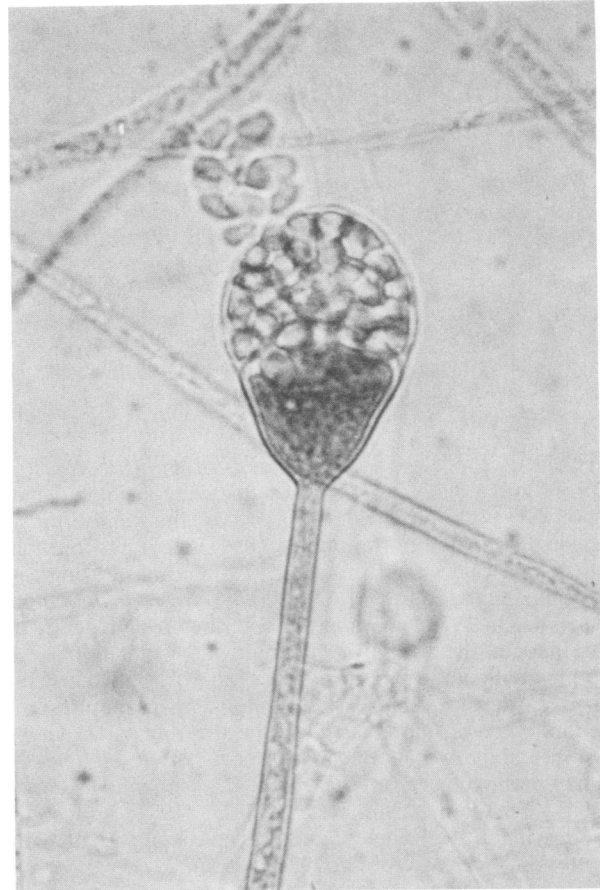


FIG. 3. Young, multisporous, pyriform sporangium of *A. elegans* showing a typical funnel-shaped apophysis but without the subapical thickening of a more mature sporangiophore. Magnification, $\times 750$.

commonly seen in *Aspergillus* spp. Rhizoids were thin walled, subhyaline, and predominantly unbranched. Sporangia were multisporous, small (20 to 50 µm in diameter), typically pyriform, hyaline at first and sepia colored when mature, columellate, and strongly apophysate (Fig. 3 and 4). Columellae were hemispherical, and the apophyses were distinctively funnel or bell shaped. Sporangiospores were smooth walled, mostly oblong, and occasionally subglobose, measured mostly 3.4 by 5.6 µm, and were subhyaline to sepia. Zygospores were not observed.

A. elegans is readily distinguishable from other zygomycetes of medical importance, especially the morphologically similar, strongly apophysate pathogen *Absidia corymbifera*, by having sporangiophores with distinctive funnel- or bell-shaped apophyses and hemispherical columellae, a conspicuous pigmented subapical thickening that constricts the lumen of the sporangiophore below the apophysis, and distinct foot cells.

Isolations selective for thermotolerant fungi (2) were made from eight soil samples collected from the ground on which the patient rolled in his attempts to extinguish the fire. Sabouraud dextrose agar in plates was inoculated with aqueous soil suspensions and by direct inoculation of soil, whereby portions of soil were mixed with molten agar just before it was allowed to solidify. All isolation plates were incubated overnight at 42°C. Soil isolation plates yielded a rich zygomycetous flora, including species of the genera

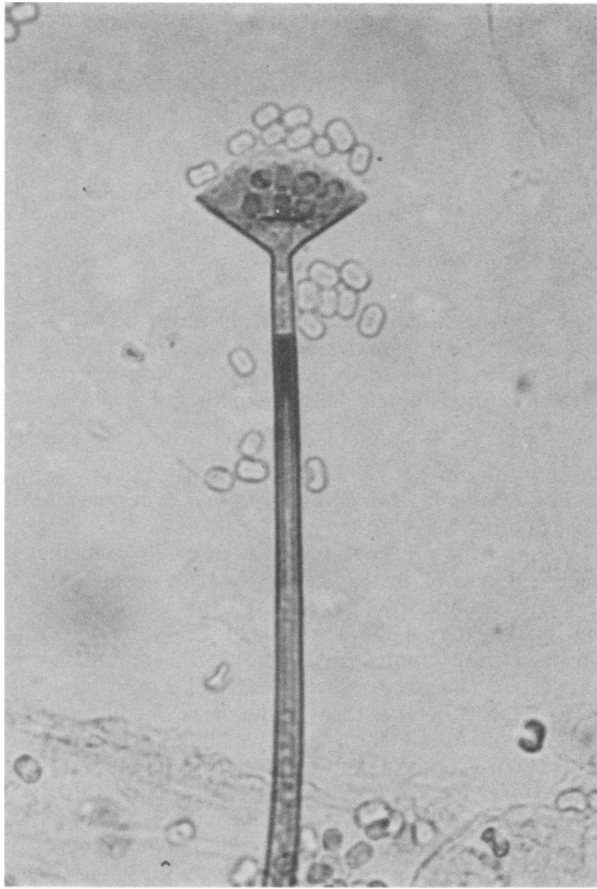


FIG. 4. Mature sporangium of *A. elegans* showing the distinctive funnel-shaped apophysis, hemispherical columella, and conspicuous dematiaceous subapical thickening of the sporangiophore below the apophysis. Magnification, $\times 825$.

Rhizopus, *Choanephora*, *Mucor*, and *Apophysomyces*. Five of the eight soil samples yielded colonies of *A. elegans* which were indistinguishable from the clinical isolate. Living subcultures of both the patient isolate and a soil isolate have been deposited in the culture collection of the CAB International Mycological Institute, Kew, London, England (IMI 338332 and IMI 338333, respectively).

This patient had the fifth reported case of *A. elegans*

infection; it was the first case recorded outside the United States and the first case seen in a burn patient. An extensive burn is recognized as one of the important predisposing conditions for zygomycosis (9). The patient received extensive full-thickness burns that were covered by moist soil during his attempts to extinguish the flames. At that time, the fungus was probably introduced into the wounds from the soil.

Typically, zygomycosis is an aggressive infection that relentlessly invades blood vessels to cause thrombosis and subsequent tissue infarction. Radical operative measures are usually necessary to control infection, and these may include aggressive debridement of large areas (4) or even amputation of limbs (5, 10). Although every endeavor was made to save the leg of the patient, the rapid progression of infection left a below-knee amputation as the only reasonable option. His postoperative systemic improvement was dramatic.

LITERATURE CITED

1. Ellis, D. H., and G. W. Kaminski. 1985. Laboratory identification of *Saksenaea vasiformis*: a rare cause of zygomycosis in Australia. *Sabouraudia* 23:137-140.
2. Ellis, D. H., and P. J. Keane. 1981. Thermophilic fungi isolated from some Australian soils. *Aust. J. Bot.* 29:689-704.
3. Ellis, J. J., and L. Ajello. 1982. An unusual source of *Apophysomyces elegans* and a method of stimulating sporulation of *Saksenaea vasiformis*. *Mycologia* 74:144-145.
4. Gordon, G., M. Indeck, J. Bross, D. A. Kapoor, and S. Brotman. 1988. Injury from silage wagon accident complicated by mucormycosis. *J. Trauma* 28:866-867.
5. Kerr, P. G., H. Turner, A. Davidson, C. Bennett, and M. Maslen. 1988. Zygomycosis requiring amputation of the hand: an isolated case in a patient receiving haemodialysis. *Med. J. Aust.* 148:258-259.
6. Lawrence, R. M., W. T. Snodgrass, G. W. Reichel, A. A. Padhye, L. Ajello, and F. W. Chandler. 1986. Systemic zygomycosis caused by *Apophysomyces elegans*. *J. Med. Mycol.* 24:57-65.
7. Misra, P. C., K. J. Srivastava, and K. Lata. 1979. *Apophysomyces*, a new genus of the Mucorales. *Mycotaxon* 8:377-382.
8. Rippon, J. W. 1988. *Medical mycology: the pathogenic fungi and pathogenic actinomycetes*, 3rd ed., p. 681-713. The W. B. Saunders Co., Philadelphia.
9. Vainrub, B., A. Macareno, S. Mandel, and D. M. Musher. 1988. Wound zygomycosis (mucormycosis) in otherwise healthy adults. *Am. J. Med.* 84:546-548.
10. Wieden, M. A., K. K. Steinbronn, A. A. Padhye, L. Ajello, and F. W. Chandler. 1985. Zygomycosis caused by *Apophysomyces elegans*. *J. Clin. Microbiol.* 22:522-526.