

Early diagnosis of temporomandibular joint involvement in juvenile idiopathic arthritis: a pilot study comparing clinical examination and ultrasound to magnetic resonance imaging

Lukas Müller¹, Christian J. Kellenberger², Elvira Cannizzaro³, Dominik Ettl⁴, Thomas Schraner², Isabel B. Bolt³, Timo Peltomäki¹ and Rotraud K. Saurenmann³

Objectives. To study the validity of both rheumatological and orthodontic examinations and ultrasound (US) as screening methods for early diagnosis of TMJ arthritis against the gold standard MRI.

Methods. Thirty consecutive juvenile idiopathic arthritis (JIA) patients were included in this pilot study. Rheumatological and orthodontic examinations as well as US were performed within 1 month of the MRI in a blinded fashion. Joint effusion and/or increased contrast enhancement of synovium or bone were considered signs of active arthritis on MRI.

Results. A total of 19/30 (63%) patients and 33/60 (55%) joints had signs of TMJ involvement on MRI. This was associated with condylar deformity in 9/19 (47%) patients and 15/33 (45%) joints. Rheumatological, orthodontic and US examinations correctly diagnosed 11 (58%), 9 (47%) and 6 (33%) patients, respectively, with active TMJ arthritis, but misdiagnosed 8 (42%), 10 (53%) and 12 (67%) patients, respectively, as having no signs of inflammation. The best predictor for active arthritis on MRI was a reduced maximum mouth opening.

Conclusion. None of the methods tested was able to reliably predict the presence or absence of MRI-proven inflammation in the TMJ in our cohort of JIA patients. US was the least useful of all methods tested to exclude active TMJ arthritis.

KEY WORDS: Juvenile idiopathic arthritis, Temporomandibular joint arthritis, Diagnosis, Ultrasound, Magnetic resonance imaging.

Introduction

Juvenile idiopathic arthritis (JIA) is the most common rheumatic disease in childhood [1]. It affects synovial joints and can involve the TMJ [2–4].

Depending on the examination methods used and the population studied, the rate of TMJ involvement in patients with JIA varies from 17 to 87% [3, 5, 6]. In 30–40% of the cases, unilateral TMJ involvement has been reported. A higher rate of TMJ involvement [2, 4, 7] was found in JIA subgroups with increased numbers of joints affected by the disease. Importantly, the TMJ may also be the initial or even the only joint affected [8, 9]. Due to the special ontogenesis and anatomy of the TMJ and its cartilage, the risk for growth disturbances is especially high in cases of TMJ arthritis [8, 10, 11]. It may result in considerable mandibular dysfunction and dysmorphic facial features, and therefore is of special concern in the paediatric age group [7, 12–14]. Complicating the problem is that involvement of the TMJ often occurs without clinically detectable signs and symptoms, therefore delaying diagnosis [15, 16]. At the time when lower jaw asymmetry or progressed retrognathism becomes obvious, irreversible condylar damage is already established [4, 17, 18]. For the prevention of this JIA complication, it would be important to have criteria that facilitate early diagnosis of TMJ arthritis [4, 19]. One group found promising results using ultrasound (US) to diagnose TMJ arthritis in adult patients [20], whereas others did not [21].

The primary aim of this pilot study was to evaluate the validity of different TMJ screening methods, namely clinical rheumatological and orthodontic examinations, as well as US against the current gold standard MRI. A secondary aim was to define clinical signs and risk factors associated with active TMJ arthritis in order to improve and facilitate early diagnosis.

Patients and methods

Patients

Between March and September 2006, 33 consecutive patients with a diagnosis of JIA according to the ILAR 2003 criteria [22] were included in this pilot study after informed consent was obtained. Exclusion criteria were a previous diagnosis of TMJ arthritis, performance of MRI of the TMJs within the last 6 months and orthodontic treatment within the past 12 months. Date of birth, sex, type of JIA, disease onset date, date of diagnosis and medications up to the study entry were extracted from the patient's hospital chart. The study was approved by the Institutional and Governmental Ethics Review Board.

Methods

The patients underwent four different examinations performed by different medical and dental specialists:

- (i) rheumatological examination (including TMJ) by a staff paediatric rheumatologist;
- (ii) orthodontic examination performed jointly by two staff orthodontists;
- (iii) US of the TMJs performed by paediatric radiologists experienced in musculoskeletal imaging; and
- (iv) MRI of the TMJs performed by paediatric radiologists.

In addition, the parents completed the Swiss–German version of the child HAQ (CHAQ) [23]. The history taking of TMJ pain was facilitated and structured by a questionnaire distributed to the parents before the consultation. In each patient, all four examinations were scheduled within a time frame of ± 1 month from the MRI.

All examiners were blinded to the results of the other examinations on the same patient.

Rheumatological examination

The rheumatological evaluation included examination of all joints for signs of inflammation such as swelling, tenderness and limitation of range of motion. The TMJ was palpated with and without

¹Clinic for Orthodontics and Pediatric Dentistry, University of Zürich, ²Diagnostic Imaging, ³Department of Rheumatology, University Children's Hospital and ⁴Clinic for Masticatory Disorders, University of Zürich, Zürich, Switzerland.

Submitted 28 November 2008; revised version accepted 5 March 2009.

Correspondence to: Rotraud K. Saurenmann, University Children's Hospital, PO Box 8032 Zürich, Switzerland. E-mail: traudel.saurenmann@kispi.uzh.ch

movement of the jaw, the jaw line visually assessed for mandibular asymmetry or retrognathism and the maximum interdental distance on mouth opening was measured without correction for overbite. The physician gave an assessment of the overall disease activity on a visual analogue scale (VAS) ranging from 0 (no active disease) to 10 cm (worst activity imaginable).

Symptoms considered as signs of active TMJ arthritis were:

- maximum interdental distance <40 mm and
- pain/tenderness at the joint space or mandibular condylar head on palpation or with jaw movement.

Findings considered as signs of TMJ deformity were:

- mandibular asymmetry or retrognathism and
- asymmetric movement of the jaw and/or asymmetric mouth opening.

Orthodontic examination

A detailed questionnaire about TMJ function, pain and symptoms was used to facilitate and structure history taking at the orthodontic examination. Morphology of the lower jaw was visually and manually assessed, with regards to mandibular retrognathism, asymmetry and palpable antegonial notching. Maximum mouth opening (corrected for overbite), protrusion and laterotrusion (corrected for overjet and midline deviation, respectively) were measured and symmetry of motion was assessed. TMJ palpation, compression and distraction tests were performed and TMJ noise was recorded. TMJ pain and tenderness of masticatory muscles (masseter and temporalis) were recorded on the Oucher scale, validated for children between 3 and 12 years of age [24], or on a VAS for children >12 years of age.

Clinical diagnosis of TMJ involvement was based on clinical scores for active arthritis and/or condylar deformity using the following criteria:

Active arthritis. It was diagnosed when at least two of the following six criteria were met:

- (i) a history of TMJ pain;
- (ii) maximum mouth opening (with correction for overbite) <40 mm;
- (iii) deviation in opening/closure of the mandible;
- (iv) crepitation on either TMJ;
- (v) pain on maximum mouth opening or on compression/distraction test or on TMJ palpation; and
- (vi) pain on palpation of the masticatory muscles.

Condylar deformity. It was diagnosed when at least two of the following four criteria were met:

- (i) severe mandibular asymmetry (asymmetry was clinically judged by an agreement of two experienced orthodontists as being beyond any healthy anatomical variation);
- (ii) severe mandibular retrognathism (retrognathism was clinically judged by an agreement between two experienced orthodontists as being beyond any healthy anatomical variation);
- (iii) accentually palpable antegonial notching on either side; and
- (iv) crepitation on either TMJ.

The mouth opening capacity appears to differ much more inter-individually than between children of different ages [4]. A maximal interdental distance of 40 mm was chosen as the cut-off for both the orthodontic and the rheumatological examinations, because it is below the mean maximal mouth opening for all age categories [25] and has been proposed as a cut-off before [5].

US

All US studies were performed on the same day as the MRI with a 12-MHz linear-array transducer (iU22, Philips Medical Systems, Bothell, WA, USA). Both TMJs were investigated dynamically during mouth opening with documentation of static transverse and coronal images at the level of the mandibular condyles in maximum mouth opening and closed mouth positions. All US studies were interpreted by the sonographer and the static images were reviewed independently by a second paediatric radiologist. The TMJs were assessed for anechoic joint effusion, thickening of the joint capsule (>2 mm) and deformities of the mandibular condyle including surface irregularity, erosion (absence of cortical lining), flattening and acute angulation at the transition point from the lateral to the superior condylar surface. Presence of joint effusion or thickening of the joint capsule was considered a sign of active inflammation.

MRI

Both TMJs were imaged on a 1.5 tesla system (Signa MR/i Twinspeed scanner, GE Medical Systems, Milwaukee, WI, USA) with a dedicated TMJ coil in closed mouth position. Axial and coronal T₂-weighted fast spin echo localizers were acquired for adjusting the subsequent sagittal oblique sequences perpendicular to each mandibular condyle and parallel to each mandibular ramus. Sagittal oblique images were acquired with a 2 mm slice thickness, without gap, 12 cm field of view and 256 × 224 matrix. First T₁-weighted spoiled gradient echo images [flip angle 80°, repetition time (TR) 325 ms, echo time (TE) 4.2 ms], proton density fast spin echo images [TR 2660 ms, TE 25 ms, echo train length (ETL) 8] and fat-saturated T₂-weighted fast spin echo images (TR 2840 ms, TE 86 ms, ETL 16) were performed, followed by contrast-enhanced fat-saturated T₁-weighted fast spin echo images (TR 600 ms, TE 11 ms, ETL 3) acquired within 5 min after intravenous administration of a single dose (0.1 mmol/kg bodyweight) of gadolinium-based contrast medium (dimeglumine gadopentate, Magnevist, Bayer, Switzerland; or gadodiamide, Omniscan, GE Healthcare, Switzerland).

Children who were not able to lie sufficiently still for the duration of the MRI had the examination performed under propofol sedation ($n=8/33$) applied by anaesthesiologists according to hospital routine.

All MRI studies were reviewed by two paediatric radiologists and decision was made by consensus. Each TMJ was assessed for the presence of an effusion, increased contrast enhancement and deformity of the mandibular condyle. On T₂-weighted images, small dots or lines of high signal in a joint recess without distension were considered a normal amount of joint fluid. On fat-saturated T₁-weighted images, high signal confined to IA fluid as delineated on the T₂-weighted images was considered normal joint enhancement. Increased joint enhancement was graded as mild, when the signal of the SM was hyperintense to muscle and as severe when the SM was thickened with signal isointense to vessels. Deformity of the mandibular condyle was graded as mild when only the anterior or posterior circumference was flattened, and as severe when the condyle was squared with loss of height. Presence of a joint effusion and/or increased enhancement was considered indicative of active inflammation.

Evaluation and statistical analysis

The result of the MRI examination was considered the gold standard or 'true' value against which the results of the rheumatological, orthodontic and US examinations were compared [5, 26]. The presence of either signs of active TMJ arthritis or signs of TMJ deformity was considered a TMJ pathology or TMJ involvement. The abilities of the different examination methods to correctly predict presence or absence of active arthritis, TMJ deformity and TMJ pathology were tested.

In addition, single components of the examinations were tested for their ability to predict the MRI results.

Statistical analyses were performed using the JMP IN 5.1 software from the SAS Institute, Cary, NC, USA and chi-square (VassarStats web site for Statistical Computation, <http://faculty.vassar.edu/lowry/VassarStats.html>).

Results

Thirty-three patients were enrolled in the study. Three patients were excluded: two patients were not able to lie sufficiently still towards the end of the MRI examination resulting in non-diagnostic contrast-enhanced images. In another patient who had the MRI performed under anaesthesia, the inflamed TMJ was injected with corticosteroids on the same occasion and before the orthodontic examination had taken place, resulting in 30 patients available for evaluation. US was not performed in one patient due to organizational problems.

For the characteristics of the 30 patients regarding JIA subtype, disease duration, disease activity and treatment, see Table 1.

MRI

TMJ pathology was present on MR image in 19/30 (63%) patients and 33/60 (55%) joints. Signs of active TMJ arthritis were present in 19/30 patients (63%) and 32/60 joints (53%). Arthritis was unilateral in six (32%) patients. Enhancement was mild in 22 and severe in 8 joints. An increased amount of joint fluid was found in five TMJs of four patients. In two TMJs of the same patient an increased amount of joint fluid was the only sign of inflammation. Condylar deformity was present in 9/30 (30%) patients and 15/60 (25%) joints and was mild in 5 and severe in 10 joints. In two TMJs with severe condylar deformity, a joint effusion was the only sign of inflammation and in one TMJ with mild condylar deformity there was no sign of active inflammation on MRI. All eight TMJs with severe enhancement had condylar deformities which were severe in seven. Four of 22 (18.4%) TMJs with mild contrast enhancement had condylar deformities which were mild in three. The correlation between the amount of enhancement and the amount of condylar deformity was statistically significant (chi-square $P < 0.0001$ for the difference between the groups).

Rheumatological examination

Rheumatological examination revealed a TMJ pathology in 22/30 (73.3%) patients and 33/60 (55%) joints. The pathology was bilateral in 11/22 patients (50%). Thirteen (61.9%) patients with TMJ pathology met the criteria for active TMJ arthritis, seven had

limited maximum interdental distance and seven had pain on motion or palpation. Fifteen patients had signs of mandibular growth disturbance with mandibular asymmetry in 14/15 (93.3%) and retrognathism in 3/15 (20%) patients. The mean maximum interdental distance was 43.8 mm (range 32–55 mm).

Orthodontic examination

Signs of TMJ involvement were found in 21/30 (70%) patients and 37/60 (61.7%) joints. TMJ involvement was diagnosed bilaterally in 16/21 (76%) patients. Definitions for active TMJ arthritis were fulfilled in 16 (53.3%) patients, 13 bilaterally and 3 unilaterally. Definitions for condylar deformity were met in 14 (46.7%) patients and 18 (30%) joints. Condylar deformity without active TMJ arthritis was diagnosed in three patients bilaterally and in two patients unilaterally. The mean maximum mouth opening in our cohort was 47.1 mm (range 35–56.5 mm) and the mean overbite was 2.3 mm (range –2.5–8.5 mm).

US

Twelve of 29 patients (41%) and 18/58 joints (31%) had a pathologic TMJ ultrasound examination, in 6 cases bilaterally. Active arthritis was diagnosed in 8/29 (28%) patients and 10/58 (17%) joints. Deformity of the condylar head was found in 7/29 (24%) patients and in 10/58 (17%) joints.

Comparison of the different methods of examination

MRI was considered the gold standard. The distribution of the results of the different methods of examination as compared to the MRI result is displayed in Table 2. The results of the different examination methods for each single patient are shown in Fig. 1. For sensitivity, specificity, positive and negative predictive values of each examination technique, refer to Table 3.

TABLE 2. Results of the different examination methods

Examination method	No. of patients examined	Number of patients with		
		Signs of active TMJ inflammation, n (%)	Signs of condylar or TMJ deformity, n (%)	Any TMJ pathology, n (%)
MRI	30	19 (63)	9 (30)	19 (60)
Rheumatology	30	13 (43)	15 (50)	22 (73)
Orthodontist	30	16 (53)	14 (47)	21 (70)
US	29	8 (28)	7 (24)	12 (41)

TABLE 1. Patient characteristics

Patient characteristics	All patients	Patients with TMJ involvement on MRI	Patients without TMJ involvement on MRI	<i>P</i>
Total no. of patients, n (%)	30	19 (63)	11 (37)	
Female, n (%)	16 (53)	10 (55)	6 (53)	0.65
Oligoarticular, n (%)	10 (33)	6 (32)	4 (36)	
Oligoarticular extended, n (%)	2 (7)	2 (11)	1 (9)	
Polyarticular RF negative, n (%)	13 (43)	8 (42)	4 (36)	0.74
Enthesitis-related arthritis, n (%)	4 (13)	3 (16)	1 (9)	
PsA, n (%)	1 (3)	0 (0)	1 (9)	
Age at diagnosis, median (range), years	5.5 (1.1–14.9)	4.3 (1.1–14.9)	6.9 (1.1–14.1)	0.29
Age at examination, median (range), years	9.8 (2.8–16.9)	8.5 (2.8–15.7)	10.5 (4.8–16.9)	0.46
Disease duration, median (range), years	2.4 (0.1–12.3)	2.3 (0.1–12.3)	2.6 (0.1–8.7)	0.91
Global disease activity, median (mean, range), mm (n=25)	7 (12, 0–53)	10 (12, 0–40)	3 (12, 0–53)	0.99
HLA-B27 positive/tested, n (%) (n=27)	1 (4)	1/17 (6)	0/10 (0)	0.39
ANA positive, n (%)	20 (67)	13 (68)	7 (64)	1.0
Uveitis, n (%)	4 (13)	3 (16)	1 (9)	0.51
Median CHAQ score, (mean, range) (n=23)	0.0 (0.2, 0.0–1.0)	0.0 (0.22, 0.0–1.0)	0.0 (0.18, 0.0–0.75)	0.77
Treatment with systemic disease-modifying drugs, %	60	45	68	0.21

Rheumatological examination vs MRI

With the rheumatological examination, 15 patients were diagnosed true positive, 4 true negative, 7 false positive and 4 false negative for TMJ involvement. On assessing every single TMJ, the rheumatological findings were true positive for 20 joints, true negative for 14 joints, false positive for 13 joints and false negative for 13 joints. A total of 12/15 (80%) affected TMJs with deformity seen on MRI, but only 8/18 (44%) affected TMJs without deformity were correctly diagnosed as pathological. Compared to the MRI findings, the rheumatological diagnosis was confirmed in 19/30 (63%) patients and 34/60 (57%) joints. Active TMJ inflammation was correctly diagnosed in 11/19 (58%) patients and 15/32 (47%) joints.

Orthodontic examination vs MRI

With the orthodontic examination, 13 patients were diagnosed true positive, 3 patients true negative, 8 patients false positive and 6 false negative for TMJ involvement. On assessing every single TMJ, the orthodontic diagnosis was confirmed to be true positive in 22 joints, true negative in 12 joints, false positive in 15 joints and false negative in 11 joints. The orthodontic and MRI diagnoses were in agreement in 16/30 (53%) patients and 34/60 (57%) joints. All 15 TMJs with condylar deformity

on MRI but only 7/18 (39%) without deformity were correctly diagnosed as pathological by the orthodontic examination.

US examination vs MRI

By means of US, 10 patients were found true positive and 9 patients true negative, 2 patients were judged false positive and 8 false negative regarding TMJ involvement. Assessing every single TMJ by US resulted in a true positive diagnosis in 15 joints and true negative in 24 joints, false positive in 3 joints and false negative in 16 joints. Eight of 15 (53%) pathological TMJs with deformity on MRI but only 7/16 (44%) without deformity were correctly diagnosed as pathological by US.

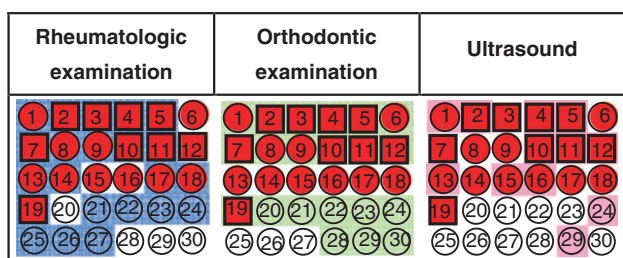
A pathological US was statistically significantly correlated with TMJ pathology on MRI (chi-square $P=0.002$) and active TMJ arthritis on MRI (chi-square $P=0.008$ for all joints and $P=0.047$ for patients). US correctly diagnosed 7/8 (88%) TMJs with severe enhancement as pathological but only 7/20 (35%) with mild enhancement (chi-square $P=0.003$ for the difference between the groups).

Clinical parameters predicting active TMJ arthritis

Factors significantly associated with active TMJ arthritis on MRI were: pathological US ($P=0.008$), age at diagnosis of JIA <6 years (chi-square $P=0.03$), a rheumatological maximum interdental distance <40mm (Fisher's exact $P=0.034$) and a shorter orthodontic mean maximum mouth opening (one-way analysis of variance (ANOVA) $P=0.002$ for the difference between the groups). The rheumatological mean interdental distance in the group with active MRI was 41.8mm as compared to 45mm in the group with normal MRI (one-way ANOVA $P=0.04$ for the difference between the groups).

There was a statistically significant difference in the rheumatological mean maximum interdental distance between patients with normal, mild and severe contrast enhancement on MRI examination (one-way ANOVA $P=0.02$ for the difference between the groups,) as well as for the orthodontic maximum mouth opening ($P=0.01$) (Fig. 2). However, the cut-off value of ≤ 40 mm for a pathological orthodontic maximum mouth opening was obviously chosen too low. A second analysis was performed using a cut-off value of <45mm and revealed better results (chi-square $P=0.016$ for the difference between the groups) (Table 3).

We did not find a statistically significant correlation of any record of pain with active TMJ arthritis. The following parameters were not correlated to a finding of active TMJ arthritis on MRI: the rheumatologist's VAS for global disease activity, CHAQ, parents VAS for overall wellbeing and parents VAS for pain.



○ MRI normal
 ● MRI pathologic (TMJ involvement)
 ■ MRI pathologic (TMJ involvement) with destruction (condylar deformity)
 ■ Rheumatologic examination pathologic (TMJ involvement)
 ■ Orthodontic examination pathologic (TMJ involvement)
 ■ Ultrasound examination pathologic (TMJ involvement)

FIG. 1. The results of the different examination methods for each patient: each patient is represented by an individual number in a square (patients with condylar deformity on MRI) or a circle (patients without condylar deformities on MRI). The red colour stands for pathological findings on MRI. The blue, green and pink colours depict pathological findings in the rheumatological, orthodontic and US examinations, respectively.

TABLE 3. Performance of the different examination methods in predicting active TMJ arthritis on MRI

Test	Sensitivity (95% CI)	Specificity (95% CI)	Positive predictive value (95% CI)	Negative predictive value (95% CI)
Rheumatological examination				
Patients	0.58 (0.34, 0.79)	0.82 (0.48, 0.97)	0.85 (0.54, 0.97)	0.53 (0.29, 0.76)
Joints	0.47 (0.29, 0.65)	0.75 (0.55, 0.89)	0.68 (0.45, 0.85)	0.55 (0.38, 0.71)
Orthodontic examination				
Patients	0.47 (0.25, 0.71)	0.36 (0.12, 0.68)	0.56 (0.31, 0.79)	0.29 (0.1, 0.58)
Joints	0.66 (0.47, 0.81)	0.46 (0.28, 0.66)	0.58 (0.41, 0.74)	0.54 (0.33, 0.74)
US				
Patients	0.33 (0.14, 0.59)	0.82 (0.48, 0.97)	0.75 (0.36, 0.96)	0.43 (0.23, 0.66)
Joints	0.23 (0.11, 0.43)	0.89 (0.71, 0.97)	0.7 (0.35, 0.92)	0.52 (0.37, 0.66)
Maximum interdental distance < 40mm				
Patients	0.37 (0.17, 0.61)	1.0 (0.68, 1.00)	1.0 (0.56, 1.0)	0.48 (0.27, 0.69)
Maximum mouth opening ≤ 40 mm (corrected for overbite)				
Patients	0.11 (0.02, 0.35)	0.91 (0.57, 0.995)	0.67 (0.13, 0.98)	0.37 (0.20, 0.58)
Maximum mouth opening ≤ 45 mm (corrected for overbite)				
Patients	0.47 (0.25, 0.71)	0.91 (0.57, 0.995)	0.9 (0.54, 0.995)	0.5 (0.28, 0.72)

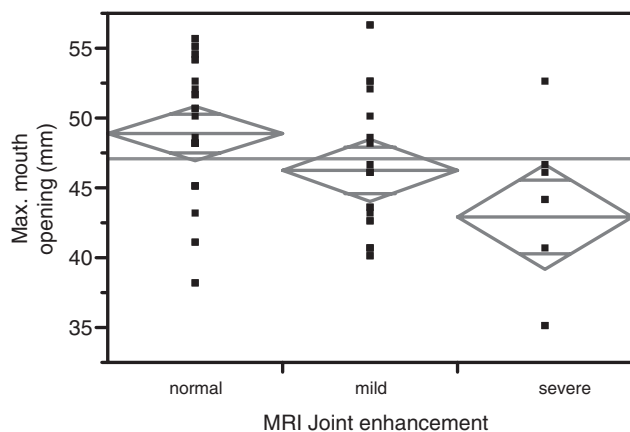


FIG. 2. The orthodontic maximum mouth opening (y -axis) is shown for the three different categories of MRI contrast enhancement of the synovium (x -axis). Each dot represents the measurement result for one patient. The diamond depicts the mean value and the quartiles. The grey horizontal line depicts the mean maximum mouth opening of the total cohort. The difference between the three groups is statistically significant with $P=0.01$ (one-way ANOVA).

Discussion

In this pilot study, we compared three different examination methods—two different clinical assessments and US—against the assumed gold standard contrast-enhanced MRI for the diagnosis of TMJ arthritis [5, 26, 27]. To our knowledge, this is the first study to directly compare these different TMJ examination methods in patients with JIA. All three methods tested were able to detect advanced destructive TMJ pathology with a good reliability. However, none of the methods tested was able to reliably detect early inflammatory changes of the TMJ before changes in mandibular growth had developed.

Contrast-enhanced MRI. It was used as the gold standard for the diagnosis of TMJ involvement in our study. We found a rate of 63% of TMJ involvement in our JIA patients. Our results are in line with results of prior studies which reported unexpectedly high rates of TMJ involvement in patients with JIA [4, 15, 28], especially when contrast-enhanced MRI was used [5, 26, 29]. Weiss *et al.* [29] found acute MRI changes of the TMJ in 75% of their JIA patients. In contrast to our interpretation of MRI, acute TMJ arthritis in their study was defined as effusions or synovial thickening on MRI only, without evaluation of contrast enhancement.

Rheumatological and orthodontic examinations. These were equally effective to detect TMJ pathology in our setting. Rheumatological examination had a slight advantage in detecting inflammatory signs, whereas orthodontic examination was superior in detecting structural changes of the mandible. But even a combination of both examinations would not have been able to find all patients with TMJ involvement or to reliably exclude early stages of inflammation where deformation of the condylar head had not yet occurred (Fig. 1). This again is in keeping with the results of previous studies [4, 5, 15, 29].

US. This would be an easy, quick and inexpensive method to assess the TMJs. Melchiorre *et al.* [20] have found it useful for the diagnosis of TMJ pathology in adult patients with RA. In a study with JIA patients, Jank *et al.* [30] found that high-resolution US was able to detect TMJ pathology before clinical symptoms appeared. However, only destruction and disc dislocation—both known to be late changes of TMJ arthritis—were screened for in this study, whereas effusion, synovial swelling or pannus were not. Furthermore, the US findings were not compared with MRI but

to a clinical examination. In our cohort, US was the most specific of all methods tested. However, US was also the least sensitive of all methods tested and only able to detect the most severely affected TMJs. These findings are in line with results of Weiss *et al.* [29], who compared US and MRI in children with newly diagnosed JIA. For the acute inflammatory TMJ changes the agreement between these two techniques was only 23%. For the chronic deforming TMJ changes the agreement was 50%.

We therefore conclude that US at this time cannot be recommended as a screening method for early TMJ involvement in patients with JIA.

Clinical parameters predicting TMJ involvement. Stabrun *et al.* [31] found the following clinical indicators of TMJ arthritis: reduced maximum mouth opening capacity, vertical differences between the two mandibular angular regions and deviation of the mandible at maximum protrusion. A combination of these variables discriminated correctly between the presence and absence of observed TMJ abnormality in 52/56 (93%) patients. Twilt *et al.* [4] found that pain during jaw excursion, absence of condylar translation, asymmetry during maximum opening and protrusion as well as crepitation during movement were predictors for TMJ involvement with a good specificity but a low sensitivity. Both studies compared their clinical findings to conventional radiographs, a method only able to detect the relatively late occurring bony changes but not early inflammation.

In our study, the only clinical parameter statistically significantly associated with TMJ involvement on MRI was the maximum mouth opening capacity. The extent of the maximum mouth opening was even associated with the severity of enhancement found on MRI. A restricted mouth opening and deviation in opening/closure can be found as a result of active inflammation of the TMJ with improvement following treatment. However, it has to be pointed out that a limited range of motion can also be due to irreversible damage. The focus of our study was to find methods for detecting early inflammation. Therefore, we chose to use a limited motion as a sign of inflammation rather than destruction. This may have limited the ability of the two clinical examinations to predict TMJ destruction.

Pain. Twilt *et al.* [4] found that of all symptoms noted by JIA patients, 'only pain during jaw excursion was a weak predictor of TMJ involvement' ($P < 0.05$). Also in the case of severe condylar destruction due to JIA, TMJ pain did not constitute a reliable symptom [14]. Olson *et al.* [32] suggested that especially in younger children (<7 years of age) subjective symptoms were almost absent, whereas older children reported them more often [15, 32, 33].

In our cohort, pain by whatever method tested was not a reliable predictor for inflammation or for deformity of the TMJ. The fact that the orthodontic score for active arthritis used three pain-related items and a cut-off level of 40 mm for pathological maximum mouth opening, which was probably chosen too low, may be the reason why the orthodontic examination was less effective than the rheumatological examination to predict active TMJ arthritis in our study. The validity of the orthodontic assessment may be improved with correction of these limitations.

Our study is limited by the small number of patients included in this pilot trial. In a larger group of patients, more factors may reach significance for the prediction of early TMJ arthritis. Another limitation is the fact that little is known about the prognostic validity of inflammatory TMJ changes on MRI of growing children to predict future impairment of mandibular growth and development.

In conclusion, we recommend regularly measuring the maximum mouth opening in patients with JIA. Restricted or decreasing mouth opening should be considered a sign of TMJ involvement even in the absence of pain, tenderness or mandibular asymmetry. We cannot recommend the use of US for the

screening for early TMJ arthritis in patients with JIA at this point in time as its sensitivity is too low to detect TMJ arthritis before structural damage has occurred. Currently MRI appears to be the only method able to diagnose early TMJ arthritis, but its validity needs to be studied further. Prospective studies need to be initiated to find risk factors for TMJ involvement in patients with JIA and to develop a feasible screening method for the early diagnosis of TMJ arthritis.

Rheumatology key messages

- Neither clinical examination nor US is able to reliably exclude active TMJ arthritis.
- MRI of the TMJs should be performed in children with JIA whenever the result may change the decision on further treatment.

Acknowledgements

Funding: This study was supported by the Swiss Arthritis Society (Rheumaliga Schweiz) and a dedicated research grant from Essex Switzerland. Funding to pay the Open Access publication charges for this article was provided by the authors.

Disclosure statement: The authors have declared no conflicts of interest.

References

- 1 Gare BA. Epidemiology of rheumatic disease in children. *Curr Opin Rheumatol* 1996;8:449–54.
- 2 Pedersen TK, Jensen JJ, Melsen B, Herlin T. Resorption of the temporomandibular condylar bone according to subtypes of juvenile chronic arthritis. *J Rheumatol* 2001;28:2109–15.
- 3 Ronning O, Valiaho ML, Laaksonen AL. The involvement of the temporomandibular joint in juvenile rheumatoid arthritis. *Scand J Rheumatol* 1974;3:89–96.
- 4 Twilt M, Moberg SM, Arends LR, ten Cate R, van Suijlekom-Smit L. Temporomandibular involvement in juvenile idiopathic arthritis. *J Rheumatol* 2004;31:1418–22.
- 5 Kuseler A, Pedersen TK, Herlin T, Gelineck J. Contrast enhanced magnetic resonance imaging as a method to diagnose early inflammatory changes in the temporomandibular joint in children with juvenile chronic arthritis. *J Rheumatol* 1998;25:1406–12.
- 6 Mayne JG, Hatch GS. Arthritis of the temporomandibular joint. *J Am Dent Assoc* 1969;79:125–30.
- 7 Karhulahti T, Ylijoki H, Ronning O. Mandibular condyle lesions related to age at onset and subtypes of juvenile rheumatoid arthritis in 15-year-old children. *Scand J Dent Res* 1993;101:332–8.
- 8 Martini G, Baccillero U, Tregnaghi A, Montesco MC, Zulian F. Isolated temporomandibular synovitis as unique presentation of juvenile idiopathic arthritis. *J Rheumatol* 2001;28:1689–92.
- 9 Scolozzi P, Bosson G, Jaques B. Severe isolated temporomandibular joint involvement in juvenile idiopathic arthritis. *J Oral Maxillofac Surg* 2005;63:1368–71.
- 10 Ronchezel MV, Hilario MO, Goldenberg J *et al.* Temporomandibular joint and mandibular growth alterations in patients with juvenile rheumatoid arthritis. *J Rheumatol* 1995;22:1956–61.
- 11 Bache C. Mandibular growth and dental occlusion in juvenile rheumatoid arthritis. *Acta Rheumatol Scand* 1964;10:142–53.
- 12 Larheim TA, Haanaes HR. Micrognathia, temporomandibular joint changes and dental occlusion in juvenile rheumatoid arthritis of adolescents and adults. *Scand J Dent Res* 1981;89:329–38.
- 13 Ronning O, Valiaho ML. Progress of mandibular condyle lesions in juvenile rheumatoid arthritis. *Proc Finn Dent Soc* 1981;77:151–7.
- 14 Svensson B, Larsson A, Adell R. The mandibular condyle in juvenile chronic arthritis patients with mandibular hypoplasia: a clinical and histological study. *Int J Oral Maxillofac Surg* 2001;30:300–5.
- 15 Hu YS, Schneiderman ED, Harper RP. The temporomandibular joint in juvenile rheumatoid arthritis: Part II. Relationship between computed tomographic and clinical findings. *Pediatr Dent* 1996;18:312–19.
- 16 Svensson B, Adell R, Kopp S. Temporomandibular disorders in juvenile chronic arthritis patients. A clinical study. *Swed Dent J* 2000;24:83–92.
- 17 Twilt M, van der Giesen E, Moberg SM, ten Cate R, van Suijlekom-Smit LW. Abrupt condylar destruction of the mandibula in juvenile idiopathic arthritis. *Ann Rheum Dis* 2003;62:366–7.
- 18 Karhulahti T, Ronning O, Jamsa T. Mandibular condyle lesions, jaw movements, and occlusal status in 15-year-old children with juvenile rheumatoid arthritis. *Scand J Dent Res* 1990;98:17–26.
- 19 Pedersen TK. Clinical aspects of orthodontic treatment for children with juvenile chronic arthritis. *Acta Odontol Scand* 1998;56:366–8.
- 20 Melchiorre D, Calderazzi A, Maddali Bongi S *et al.* A comparison of ultrasonography and magnetic resonance imaging in the evaluation of temporomandibular joint involvement in rheumatoid arthritis and psoriatic arthritis. *Rheumatology* 2003;42:673–6.
- 21 Emshoff R, Brandlmaier I, Bodner G, Rudisch A. Condylar erosion and disc displacement: detection with high-resolution ultrasonography. *J Oral Maxillofac Surg* 2003;61:877–81.
- 22 Petty RE, Southwood TR, Manners P *et al.* International League of Associations for Rheumatology classification of juvenile idiopathic arthritis: second revision, Edmonton, 2001. *J Rheumatol* 2004;31:390–2.
- 23 Hofer M, Ruperto N, Saurenmann R *et al.* The Swiss German and Swiss French versions of the Childhood Health Assessment Questionnaire (CHAQ) and the Child Health Questionnaire (CHQ). *Clin Exp Rheumatol* 2001;19(4 Suppl. 23):S151–7.
- 24 Beyer JE, Aradine CR. Content validity of an instrument to measure young children's perceptions of the intensity of their pain. *J Pediatr Nurs* 1986;1:386–95.
- 25 Sheppard IM, Sheppard SM. Maximal incisal opening—a diagnostic index? *J Dent Med* 1965;20:13–15.
- 26 Taylor DB, Babyn P, Blaser S *et al.* MR evaluation of the temporomandibular joint in juvenile rheumatoid arthritis. *J Comput Assist Tomogr* 1993;17:449–54.
- 27 Larheim TA, Smith HJ, Aspestrand F. Rheumatic disease of the temporomandibular joint: MR imaging and tomographic manifestations. *Radiology* 1990;175:527–31.
- 28 Sidiropoulou-Chatzigianni S, Papadopoulos MA, Kolokithas G. Mandibular condyle lesions in children with juvenile idiopathic arthritis. *Cleft Palate Craniofac J* 2008;45:57–62.
- 29 Weiss PF, Arabshahi B, Johnson A *et al.* High prevalence of temporomandibular joint arthritis at disease onset in children with juvenile idiopathic arthritis, as detected by magnetic resonance imaging but not by ultrasound. *Arthritis Rheum* 2008;58:1189–96.
- 30 Jank S, Haase S, Strobl H *et al.* Sonographic investigation of the temporomandibular joint in patients with juvenile idiopathic arthritis: a pilot study. *Arthritis Rheum* 2007;57:213–18.
- 31 Stabrun AE, Larheim TA, Hoyeraal HM. Temporomandibular joint involvement in juvenile rheumatoid arthritis. Clinical diagnostic criteria. *Scand J Rheumatol* 1989;18:197–204.
- 32 Olson L, Eckerdal O, Hallonsten AL, Helkimo M, Koch G, Gare BA. Craniomandibular function in juvenile chronic arthritis. A clinical and radiographic study. *Swed Dent J* 1991;15:71–83.
- 33 Forsberg M, Agerberg G, Persson M. Mandibular dysfunction in patients with juvenile rheumatoid arthritis. *J Craniomandib Disord* 1988;2:201–8.