

Fatal Encephalitis Caused by *Dactylaria constricta* var. *gallopava* in a Snowy Owl Chick (*Nyctea scandiaca*)

I. F. SALKIN,^{1*} D. M. DIXON,¹ M. E. KEMNA,¹ P. J. DANNEMAN,² AND J. W. GRIFFITH²

Wadsworth Center for Laboratories and Research, New York State Department of Health, Albany, New York 12201,¹ and Department of Comparative Medicine, Milton S. Hershey Medical Center, Hershey, Pennsylvania 17033²

Received 30 July 1990/Accepted 25 September 1990

Dactylaria constricta var. *gallopava* (Cooke) Salkin et Dixon was found to cause fatal encephalitis in a 28-day-old, captivity-bred snowy owl chick (*Nyctea scandiaca*). The previously healthy bird suddenly developed ataxia, severe torticollis, and extensor rigidity of the legs. Since the animal did not improve with antibiotic or vitamin-mineral supplement therapy, the chick was euthanized 5 days after the onset of neurologic signs. At necropsy, all tissues except the brain were grossly normal. Cultures inoculated with blood from the brain and heart yielded a dematiaceous mould that subsequently proved to be *D. constricta* var. *gallopava*. This is the first report of natural central nervous system infection caused by *D. constricta* var. *gallopava* in a snowy owl.

Dematiaceous moulds are increasingly being recognized as agents of primary and opportunistic infections in humans and animals (1, 2, 4-6, 10, 11). Although commonly associated with such subcutaneous diseases as eumycetoma and chromoblastomycosis, many of these fungi may initiate infections of the central nervous system. For example, *Xylohypha bantiana* (Saccardo) McGinnis, Padhye, Borelli, et Ajello; *Bipolaris hawaiiensis* (Bugnicourt ex M. B. Ellis) Uchida et Aragaki; *B. spicifera* (Bainier) Subramanian; and *Wangiella dermatitidis* (Kano) McGinnis have all been reported as being neurotropic in natural and experimental infections (4).

Dactylaria constricta var. *gallopava* (Cooke) Salkin et Dixon was recently described (8) as one of two varieties within the new combination *D. constricta* (Abbott) Dixon et Salkin (3). It may be distinguished from the second variety, *D. constricta* var. *constricta*, by its delayed (>21 days) positive gelatin reaction, inability to grow on cycloheximide-containing media (e.g., Mycosel), and growth at 37 and 42°C (8). More important, while *D. constricta* var. *constricta* could not initiate infections in experimental animals, *D. constricta* var. *gallopava* was found to cause central nervous system infections in animal models (4, 11) and has been reported as being the agent of natural central nervous system diseases in commercial turkey and chicken flocks (1, 5, 10).

We report here the first natural central nervous system infection caused by *D. constricta* var. *gallopava* in a snowy owl (*Nyctea scandiaca*).

Case report. On 26 June 1989, a previously healthy, 28-day-old, captivity-bred snowy owl chick showed an acute onset of unusual neurologic signs. The animal was ataxic and repeatedly rocked backward to the point of falling over. Although the chick was initially able to right herself, by the following morning (27 June 1989) she was unable to regain an upright position. In addition, the chick was showing clinical signs of intermittent torticollis and extensor rigidity of the legs.

Since the results of radiographic, hematologic, serum chemistry, and fecal studies were within normal limits, nutritional deficiency of thiamine, vitamin E, vitamin D₃, or calcium was considered as the possible cause of the neuro-

logic signs. Consequently, the bird was started on intravenous treatment with a multivitamin-mineral supplement and calcium gluconate in lactate-containing Ringer solution with 5% glucose.

Temporary clinical improvement was noted; however, by 28 June 1989, the owl was once again unable to right herself and showed almost constant torticollis and extensor rigidity of the legs. Therefore, oral administration of a multivitamin-mineral supplement was initiated. When the chick showed no clinical improvement, listeriosis was added to the list of differential diagnoses and the bird was started on oral tetracycline syrup.

On the morning of 30 June 1989, 5 days after onset, the owl was extremely weak, was unable to right herself, and showed continuous and severe torticollis and extensor rigidity of the legs. Therefore, euthanasia was administered.

Laboratory studies. At necropsy, the bird was moderately emaciated, but otherwise, all tissues except that of the brain were grossly normal. The brain showed extensive malacia, particularly on the left side, with hemorrhage of the meninges. Portions of the brain were fixed in 10% Formalin, embedded in paraffin, sectioned, and stained with hematoxylin and eosin and Grocott methenamine-silver stain.

Blood from the brain and heart taken at necropsy was streaked for isolation onto 100-mm-diameter petri plates containing 25 ml of Sabouraud glucose agar with penicillin and streptomycin (Difco Laboratories, Detroit, Mich.) and blood agar plates. All cultures were incubated at 27°C and observed daily for growth.

The isolate recovered from both blood specimens was subcultured to Sabouraud glucose agar slants and incubated at 30, 37, 42, and 45°C and to Mycosel (BBL/Becton Dickinson Microbiological Systems, Cockeysville, Md.) slants incubated at 30°C. Conidial morphology and ontogeny were investigated with 7- to 10-day-old potato dextrose agar (Difco) and cornmeal agar (Difco) slide cultures. Gelatin liquefaction was evaluated with culture tubes containing 5 ml of 14% nutrient gelatin (BBL) which were examined after 7, 14, and 21 days of incubation at 30°C. The ability of the isolate to utilize potassium nitrate as the sole nitrogen source was studied with a previously described nitrate test medium (7).

Microscopic studies. Microscopic examination of sections of the brain stained with hematoxylin and eosin revealed

* Corresponding author.

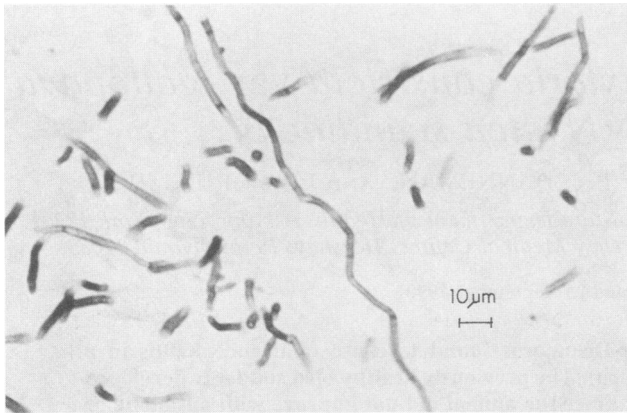


FIG. 1. Septate, dematiaceous hyphal fragments in a methenamine-silver-stained section of brain tissue from a snowy owl chick. Bar, 10 μ m.

widespread invasion with septate, dematiaceous hyphae. Although the fungal elements were generally unbranched, occasional dichotomously branched filaments were noted. Sections stained with Grocott methenamine-silver stain (Fig. 1) showed similar septate fungal hyphae with dichotomous branching.

Mycologic studies. A black-gray, woolly mould was received for identification by the Laboratories for Mycology. Initial microscopic examination of a portion of the mould colony revealed oval, two-celled blastoconidia formed sympodially at the apices of the conidiophores (Fig. 2). The overall appearance of the colony and the microscopic morphology were consistent with *D. constricta*. This initial identification was confirmed through more detailed studies of the potato dextrose agar and cornmeal agar slide cultures. Conidia in these cultures were similar in size and shape to those noted on initial examination. They were released from the conidiophore by a rhexolytic mode of dehiscence. Threadlike denticles were usually found between the conidia and conidiogenous cells.

Subcultures on Sabouraud glucose agar grew at all temperatures and formed a dark red, diffusible pigment. No growth occurred on Mycosel, even after 14 days of incubation. The isolate assimilated potassium nitrate as the sole nitrogen source and liquefied gelatin, but only after 21 days

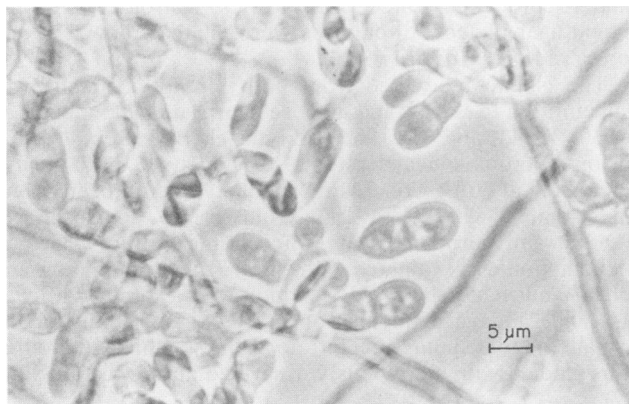


FIG. 2. Characteristic two-celled blastoconidia of *D. constricta* var. *gallopava*. Bar, 5 μ m.

of incubation at 30°C. These physiological characteristics are indicative of *D. constricta* var. *gallopava*.

Observation of dematiaceous hyphal fragments in the stained tissue sections and isolation of a dematiaceous mould morphologically and physiologically consistent with *D. constricta* var. *gallopava* indicate that this fungus was the etiologic agent of the central nervous system infection in the snowy owl chick.

D. constricta var. *gallopava* has been recognized as the etiologic agent of epizootic encephalitis in young turkeys and chickens (1, 5, 10), a neurotropic pathogen in experimentally infected mice (4, 11), and a human pathogen (2). Recently, it was identified as the cause of fatal encephalitis in two grey-winged trumpeters (*Psophia crepitans*; 6). The first of the two birds had been hand raised and died 1 day after onset of neurologic signs, including head tilting, circling, and ptosis of one eyelid. The second, raised by its parents, was euthanized 1 day after onset of similar signs of infection. In both cases, histologic examination revealed severe necrotizing meningoencephalitis with extensive areas of necrosis, diffuse infiltration of large numbers of heterophils, mononuclear cells, and giant cells, along with congestion and thrombosis of the blood vessels. Numerous septate, branching hyphae were observed in stained tissue.

For trumpeters, as well as other avian species, a correlation between disease development and environmental conditions favorable to growth of the etiologic agent has been suggested (10). In the present case, the chick was raised on fir bark bedding in a warm, humid environment conducive to growth of *D. constricta* var. *gallopava*. It is possible that the bedding was the source of infection and the bird's age and weakened nutritional status predisposed it to development of the fatal meningoencephalitis.

D. gallopava (Cooke) Bhatt et Kendrick and *Scolecobasidium constrictum* Abbott are anamorphic-form taxa for which no teleomorphs are known. As members of the class Deuteromycetes, they are defined primarily on the basis of morphologic characteristics, e.g., method of conidiogenesis and size, shape, and pigment of conidia, etc. In this regard, the two dematiaceous moulds are indistinguishable. Consequently, Dixon and Salkin (3) proposed the new combination *D. constricta* Dixon et Salkin. However, since the two species did differ with respect to several physiologic features and pathogenicity in a mouse model, the same researchers subsequently established two varieties of *D. constricta*, i.e., *D. constricta* var. *constricta* and *D. constricta* var. *gallopava* (8). Recently, Sekhon et al. (9) showed that the two varieties can be serologically differentiated by use of an exoantigen test. In view of the previously reported physiologic differences and their studies of the varieties with respect to their exoantigen properties, they suggested that the taxa be retained as separate species, "irrespective of whether one prefers to classify them under the genus *Dactylaria* sensu Bhatt and Kendrick, or *Ochroconis* de Hoog and von Arx." This indicates that these researchers feel that the species should be placed under the same genus, although no formal taxonomic transfer was proposed, and they referred to the species as *D. gallopava* and *S. constrictum*. The basic question is whether these taxa constitute separate species within one genus or separate varieties of one species. We used a strict interpretation of the International Code of Botanical Nomenclature in classifying the entities as separate varieties, since moulds are classified principally on the basis of morphology and only secondarily on the basis of physiology. There are no formal guidelines on when physiological differences become sufficient to warrant separate-

species status. To avoid further confusion on this subject, we will adhere to our original taxonomic proposal, which is justified, and await further data, such as those derived by molecular genetic methods, and possibly formulation of improved guidelines for nomenclatural criteria for moulds.

LITERATURE CITED

1. Blalock, H. G., L. K. Georg, and W. T. Kerieux. 1973. Encephalitis in turkey poult due to *Dactylaria (Diplorhinotrichum) gallopava*—case report and its experimental reproduction. *Avian Dis.* **17**:197–204.
2. Dixon, D. M., A. Polak, and P. J. Szaniszló. 1987. Pathogenicity and virulence of wild-type and melanin-deficient *Wangiella dermatitidis*. *J. Med. Vet. Mycol.* **25**:97–106.
3. Dixon, D. M., and I. F. Salkin. 1986. Morphologic and physiologic studies of three dematiaceous pathogens. *J. Clin. Microbiol.* **24**:12–15.
4. Dixon, D. M., T. J. Walsh, I. F. Salkin, and A. Polak. 1987. *Dactylaria constricta*: another dematiaceous fungus with neurotropic potential in mammals. *J. Med. Vet. Mycol.* **25**:55–58.
5. Georg, L. K., B. W. Bierer, and W. B. Cooke. 1964. Encephalitis in turkey poult due to a new fungus species. *Sabouraudia* **3**:239–244.
6. Karesh, W. B., R. Russel, and D. Gribble. 1987. *Dactylaria gallopava* encephalitis in two grey-winged trumpeters (*Psophia crepitans*). *Avian Dis.* **31**:685–688.
7. Pincus, D. H., I. F. Salkin, N. J. Hurd, I. L. Levy, and M. E. Kemna. 1988. Modification of potassium nitrate assimilation test for identification of clinically important yeasts. *J. Clin. Microbiol.* **26**:366–368.
8. Salkin, I. F., and D. M. Dixon. 1987. *Dactylaria constricta*: description of two varieties. *Mycotaxon* **29**:377–381.
9. Sekhon, A. S., A. A. Padhye, P. G. Standard, L. Kaufman, L. Ajello, and A. K. Garg. 1990. Antigenic relationship of *Dactylaria gallopava* to *Scolecobasidium constrictum*. *J. Med. Vet. Mycol.* **28**:59–66.
10. Waldrip, D. W., A. A. Padhye, L. Ajello, and M. Ajello. 1974. Isolation of *Dactylaria gallopava* from broiler-house litter. *Avian Dis.* **18**:445–451.
11. Walsh, T. J., D. M. Dixon, A. Polak, and I. F. Salkin. 1986. Comparative histopathology of *Dactylaria constricta*, *Fonsecaea pedrosoi*, *Wangiella dermatitidis*, and *Xylohypha bantiana* in experimental phaeohyphomycosis of the central nervous system. *Mykosen* **30**:215–255.