

# Fatigue Stress Fractures of the Pubic Ramus in the Army: Imaging Features with Radiographic, Scintigraphic and MR Imaging Findings

Sang Woo Lee, MD<sup>1</sup>  
Chang Hyun Lee, MD<sup>2</sup>

Although fatigue fractures are not unusual in athletes and military personnel those of the pubic ramus are rare. We report three cases of fatigue fractures of the inferior pubic rami in two male recruits and one female military cadet. On the initial radiograph, most of the lesions were subtle and easy to overlook. However, bone scintigraphy provided more distinct images that allowed easy and early detection of lesions, and MR imaging presented more diagnostic information, which allowed a precise diagnosis.

**F**atigue fractures are caused by the continuous and repetitive muscular pulling on the normal bone, and not unusual in athletes and military personnel (1, 2). The most common locations of fatigue fractures are the tibia, fibula and metatarsal bone, while fatigue fractures of the pubic ramus are rare (1). There are a few reports in which the MR imaging findings of fatigue fractures of the pubic ramus are available (3, 4). However, to our knowledge, there is no case report describing its radiographic, scintigraphic, and MR imaging findings in the same patient. We report the radiographic, scintigraphic, and MR imaging findings of fatigue fractures of the inferior pubic rami in two male recruits and one female military cadet undergoing basic military training. The follow-up scintigraphic and MR imaging findings are also available in one of these cases.

## Index terms:

Bones, radionuclide studies  
Bones, MR  
Fractures, stress  
Pubic bones

## Korean J Radiol 2005; 6: 47-51

Received April 24, 2004; accepted after revision December 27, 2004.

Departments of <sup>1</sup>Nuclear Medicine and <sup>2</sup>Radiology, the Armed Forces Capital Hospital, Korea

## Address reprint requests to:

Sang Woo Lee MD, Department of Nuclear Medicine, the Armed Forces Capital Hospital, San 13-4 Yul-dong, Bundang-gu, Seongnam, Kyunggi-do 463-040, Korea.  
Tel. (8231) 725-6485  
Fax. (8231) 706-0987  
e-mail: swlee-nm@hanmail.net

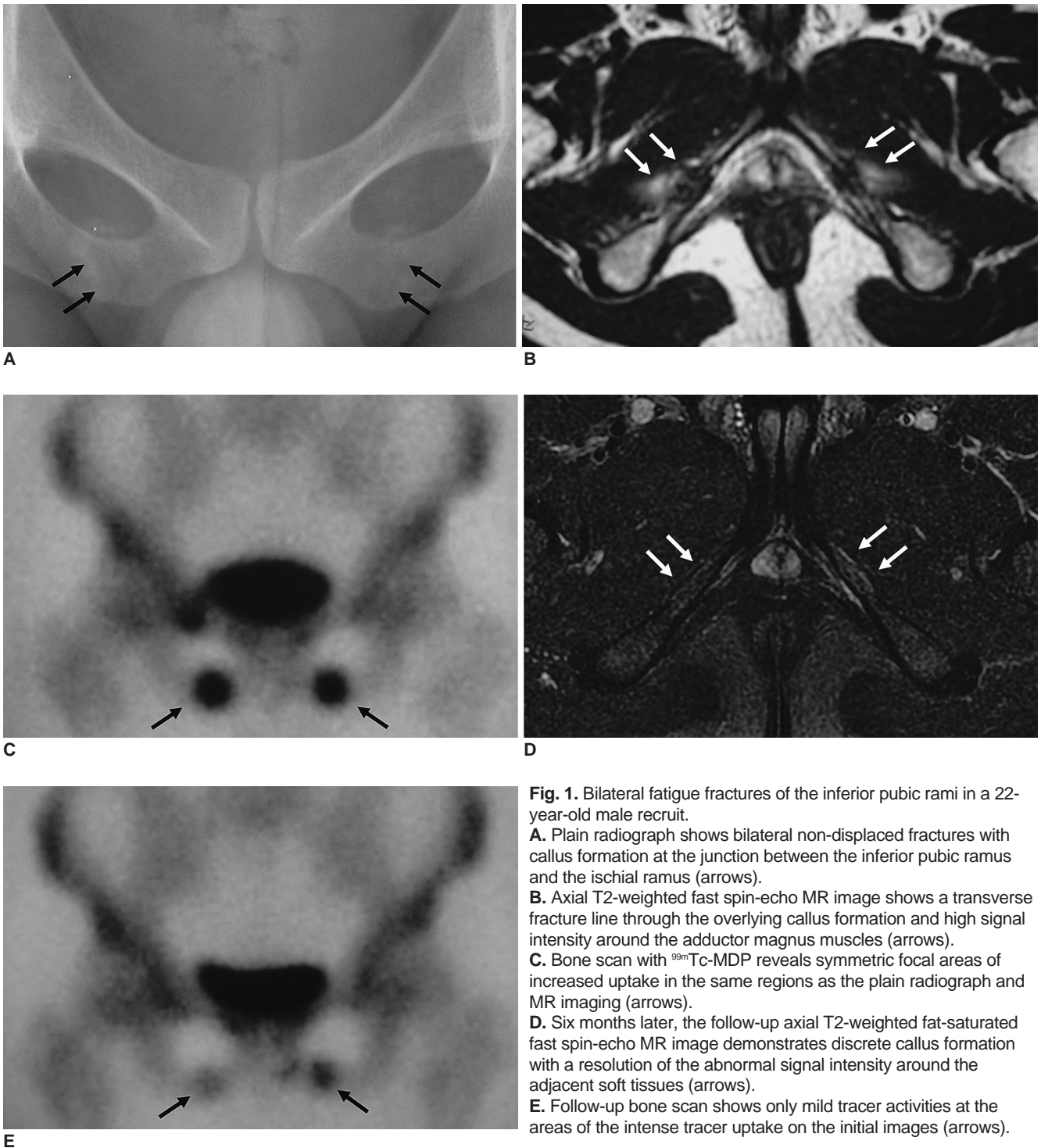
## CASE REPORT

### Case 1

A 22-year-old male recruit complained of pain in the both hips for several weeks without a history of direct trauma in his hip and pelvis. He also complained of right chest wall pain and a painful swelling in his left foot. His symptoms appeared during his basic military training such as repetitive running and marching in an army recruit training center. Approximately four years before the occurrence of the recent painful episodes, he underwent surgery for a fracture of the right femoral neck caused by a fall in a bathroom. With the exception of this surgical history, he had no remarkable history of disease or treatment with medication. The plain radiograph showed no evidence of complications from the previous surgery for a fracture of the right femoral neck, but revealed bilateral non-displaced fractures with callus formation at the junction between the inferior pubic ramus and the ischial ramus (Fig. 1A), which were overlooked by an orthopedic surgeon. In order to exclude any surgery-related complications such as osteonecrosis, MR imaging (Signa Excite, GE Medical Systems, Milwaukee, Wis.) of the pelvis was performed, which showed transverse fracture lines through the overlying callus formation and high signal intensity around the adductor

magnus muscles bilaterally (Fig. 1B). A bone scan (E.CAM, Siemens, Erlangen, Germany) with <sup>99m</sup>Tc-MDP revealed symmetric focal areas of increased uptake at the same regions as the plain radiograph and MR imaging (Fig. 1C). In addition, scintigraphy demonstrated rib fractures of the right 5th and 6th ribs, and a fatigue fracture of the left 4th metatarsal bone. His symptoms gradually improved with

rest and some analgesics. Six months later, follow-up MR imaging and bone scan were performed. The follow-up MR images demonstrated discrete callus formation with a resolution of the abnormal signal intensity around adjacent soft tissues (Fig. 1D). In the follow-up bone scan, the focal tracer activities still remained but were much improved (Fig. 1E) compared with the initial images, and there were



**Fig. 1.** Bilateral fatigue fractures of the inferior pubic rami in a 22-year-old male recruit.  
**A.** Plain radiograph shows bilateral non-displaced fractures with callus formation at the junction between the inferior pubic ramus and the ischial ramus (arrows).  
**B.** Axial T2-weighted fast spin-echo MR image shows a transverse fracture line through the overlying callus formation and high signal intensity around the adductor magnus muscles (arrows).  
**C.** Bone scan with <sup>99m</sup>Tc-MDP reveals symmetric focal areas of increased uptake in the same regions as the plain radiograph and MR imaging (arrows).  
**D.** Six months later, the follow-up axial T2-weighted fat-saturated fast spin-echo MR image demonstrates discrete callus formation with a resolution of the abnormal signal intensity around the adjacent soft tissues (arrows).  
**E.** Follow-up bone scan shows only mild tracer activities at the areas of the intense tracer uptake on the initial images (arrows).

## Imaging Findings of Fatigue Stress Fractures of Pubic Ramus in Army

no clinical symptoms.

### Case 2

A 20-year-old male recruit presented with a history of the right buttock pain for a month after a long distance military march in the Marine Corps. He had no history of direct trauma to the pelvis and his past medical history was unremarkable. The plain radiograph showed bilateral non-displaced fractures with callus formation at the junction between the inferior pubic ramus and the ischial ramus (Fig. 2A), which were similar to those observed in case 1. A bone scan with  $^{99m}\text{Tc}$ -MDP also demonstrated symmetric bilateral focal areas of intensely increased tracer accumulation at the same regions as the plain radiograph (Fig. 2B), suggesting bilateral fatigue fractures. In addition, scintigraphy revealed rib fractures of the left 6th and 7th ribs. His symptoms gradually disappeared with reduced training activity over a period of several weeks. MR imaging was not done.

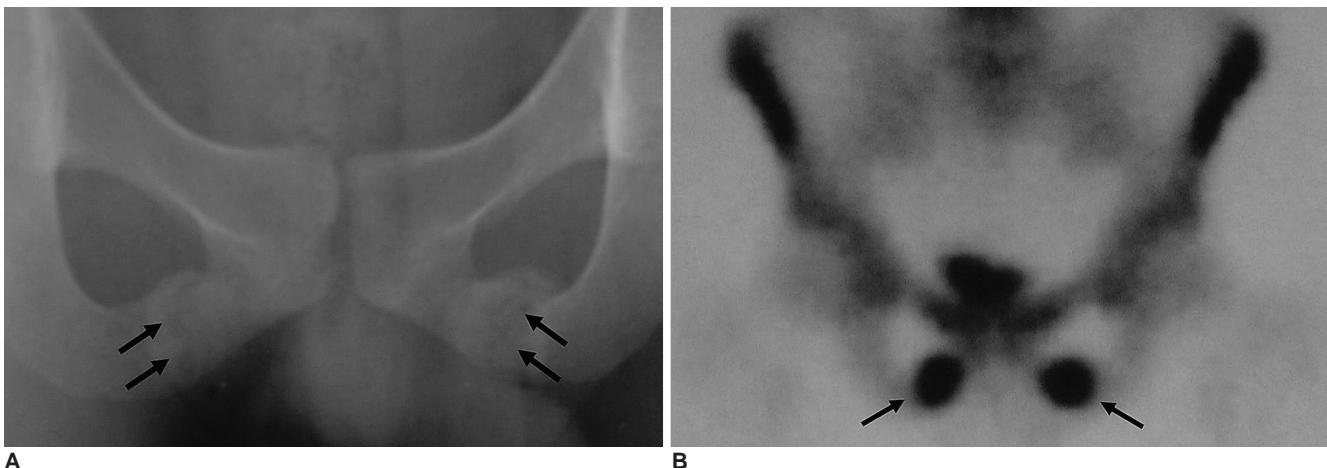
### Case 3

A 19-year-old female military cadet complained of pain in her left buttock and posterior upper thigh for approximately three weeks. She also complained of pain in her left leg. She had no history of direct trauma in the left hip. There was no remarkable history of disease or treatment with medication. Her symptoms were aggravated through the continuing basic military training such as running and marching in full kit. Clinically, a fatigue fracture was suspected, but the initial radiograph only showed a subtle fracture line in the left inferior pubic ramus (Fig. 3A). A bone scan with  $^{99m}\text{Tc}$ -MDP revealed a focal area of

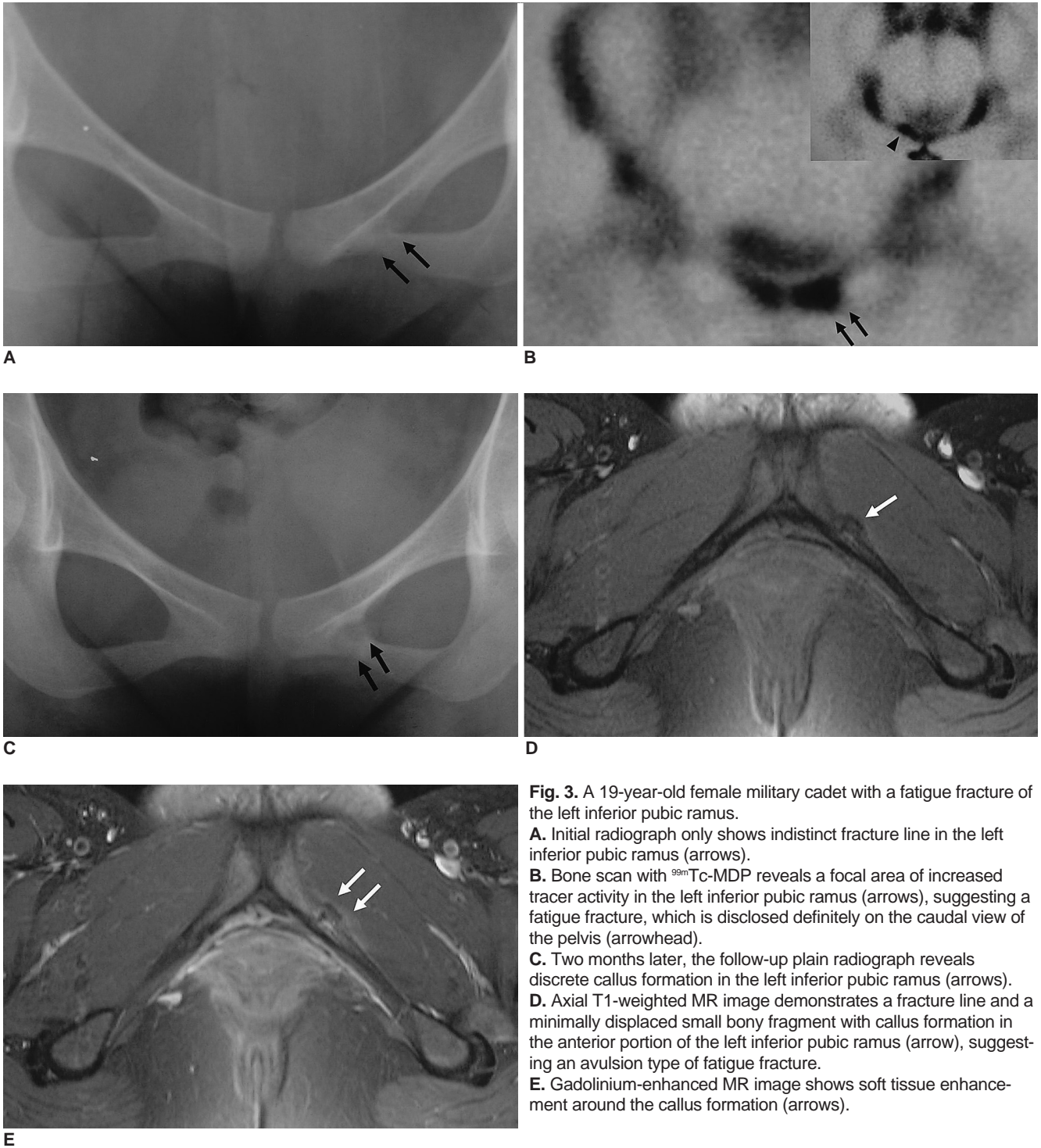
increased tracer activity in the left inferior pubic ramus (Fig. 3B), suggesting a fatigue fracture, which was disclosed definitely on the caudal view of the pelvis by separating it from the urinary bladder activity. Scintigraphy also showed a fusiform area of increased uptake in the left fibular shaft, suggesting fatigue fracture. Two months later, a follow-up radiographic examination and MR imaging were performed. The follow-up plain radiograph revealed discrete callus formation in the left inferior pubic ramus (Fig. 3C). The axial T1-weighted MR image demonstrated a fracture line and a minimally displaced small bony fragment with callus formation in the anterior portion of the left inferior pubic ramus (Fig. 3D), suggesting an avulsion type of fatigue fracture, and the Gd-DTPA (Gadolinium-diethyltriaminepentaacetic acid) enhanced MR image showed soft tissue enhancement around the callus formation (Fig. 3E).

## DISCUSSION

Fatigue fractures of the pubic ramus are infrequent, although fatigue fractures are not unusual in athletes and military personnel (1, 2). Usually, fatigue fractures of the pelvic bone occur in the medial portion of the pubic ramus, and at the junction between the inferior pubic ramus and the ischial ramus (5). Continuous and repetitive muscular pulling of the bony insertion site will cause local bony absorption and osteoporosis, leading to a fatigue fracture (6). Fatigue fractures of the pubic ramus are attributed to the pulling of the adductor magnus muscle, which originates in the junction between the inferior pubic ramus and the ischial ramus (1). Strong tensile forces produced by



**Fig. 2.** Bilateral fatigue fractures of the inferior pubic rami in a 20-year-old male recruit. **A.** Plain radiograph shows bilateral non-displaced fractures with callus formation at the junction between the inferior pubic ramus and the ischial ramus (arrows). **B.** Bone scan with  $^{99m}\text{Tc}$ -MDP demonstrates symmetric bilateral focal areas of intensely increased tracer uptake at the same regions as the plain radiograph (arrows), suggesting bilateral fatigue fractures.



**Fig. 3.** A 19-year-old female military cadet with a fatigue fracture of the left inferior pubic ramus.  
**A.** Initial radiograph only shows indistinct fracture line in the left inferior pubic ramus (arrows).  
**B.** Bone scan with <sup>99m</sup>Tc-MDP reveals a focal area of increased tracer activity in the left inferior pubic ramus (arrows), suggesting a fatigue fracture, which is disclosed definitely on the caudal view of the pelvis (arrowhead).  
**C.** Two months later, the follow-up plain radiograph reveals discrete callus formation in the left inferior pubic ramus (arrows).  
**D.** Axial T1-weighted MR image demonstrates a fracture line and a minimally displaced small bony fragment with callus formation in the anterior portion of the left inferior pubic ramus (arrow), suggesting an avulsion type of fatigue fracture.  
**E.** Gadolinium-enhanced MR image shows soft tissue enhancement around the callus formation (arrows).

the muscle pulls on the lateral aspect of the pubic ramus and ischium as the hip is extended are believed to underlie the development of these fatigue fractures (2). Indeed, MR imaging of the left inferior pubic ramus in the case 3 demonstrated an anterolaterally displaced small bony fragment with callus formation, suggesting an avulsion type of fatigue fracture. It is speculated that the same

mechanism applied to our cases.

The early detection of a fatigue fracture is important for the treatment and prevention of its complication. However, a diagnosis of a fatigue fracture of the pubic ramus has been often delayed (5, 7, 8). It is possible that anatomical circumstances make the local pain and swelling upon palpation more difficult to feel than that in the more

## Imaging Findings of Fatigue Stress Fractures of Pubic Ramus in Army

common sites. Moreover, the nonspecific nature of the symptoms together with a lack of knowledge of this fracture might be the reason why fatigue fractures of the pubic ramus are often misdiagnosed (8). Furthermore, in the early stage of a fatigue fracture the radiographs are often negative and most fractures are non-displaced and are easy overlooked on the initial radiographic examination (5). In this study, all three cases were misdiagnosed based only on a clinical examination and plain radiography. Bone scintigraphy has been an important imaging tool since the 1970s because it is a more sensitive indicator of an early fatigue fracture than a radiographic examination (6). Besides, scintigraphy can provide unexpected additional information such as fatigue fractures in other sites or rib fractures by the acquisition of whole body images. Recent studies reported that MR imaging provided more diagnostic information such as the fracture line and the periosteal edema compared with scintigraphy (9), and MR imaging was even more sensitive in revealing the stress injuries of the bone than a bone scan (10). MR imaging might be an excellent alternative imaging tool for diagnosing fatigue fractures of the pubic ramus, even though the high cost and limited imaging field compared with scintigraphy need to be considered.

Ishibashi et al. reported that the grade of scintigraphy and the MR imaging were closely correlated, and these findings also correlated with the degree of the clinical symptoms (9). Although, all the imaging studies could not be performed in each patient within a fixed period or at regular intervals, a follow-up bone scan and MR imaging could be obtained in one case, which correlated well with the clinical symptoms.

In summary, fatigue fractures of the pubic ramus are a rare condition and are difficult to diagnose based only on an either clinical examination or plain radiography. A strong level of suspicion is required and advanced imaging studies such as bone scintigraphy and MR imaging will be needed to ensure an early and precise diagnosis when the plain radiograph is not diagnostic.

### References

1. Kim SM, Park CH, Gartland JJ. Stress fracture of the pubic ramus in a swimmer. *Clin Nucl Med* 1987;12:118-119
2. Thorne DA, Datz FL. Pelvic stress fracture in female runners. *Clin Nucl Med* 1986;11:828-829
3. Kiuru MJ, Pihlajamaki HK, Ahovuo JA. Fatigue stress injuries of the pelvic bones and proximal femur: evaluation with MR imaging. *Eur Radiol* 2003;13:605-611
4. Miller C, Major N, Toth A. Pelvic stress injuries in the athlete: management and prevention. *Sports Med* 2003;33:1003-1012
5. Pavlov H, Nelson TL, Warren RF, Torg JS, Burstein AH. Stress fractures of the pubic ramus. A report of twelve cases. *J Bone Joint Surg Am* 1982;64:1020-1025
6. Wilcox JR Jr, Moniot AL, Green JP. Bone scanning in the evaluation of exercise-related stress injuries. *Radiology* 1977;123:699-703
7. Hill PF, Chatterji S, Chambers D, Keeling JD. Stress fracture of the pubic ramus in female recruits. *J Bone Joint Surg Br* 1996;78:383-386
8. Meurman KO. Stress fracture of the pubic arch in military recruits. *Br J Radiol* 1980;53:521-524
9. Ishibashi Y, Okamura Y, Otsuka H, Nishizawa K, Sasaki T, Toh S. Comparison of scintigraphy and magnetic resonance imaging for stress injuries of bone. *Clin J Sport Med* 2002;12:79-84
10. Kiuru MJ, Pihlajamaki HK, Hietanen HJ, Ahovuo JA. MR imaging, bone scintigraphy, and radiography in bone stress injuries of the pelvis and the lower extremity. *Acta Radiol* 2002;43:207-212