

Maxillary Sinus Infection Caused by the Homobasidiomycetous Fungus *Schizophyllum commune*

MARTHA E. KERN^{1*} AND F. A. UECKER²

Department of Pathology, Southern Maryland Hospital Center, Clinton, Maryland 20735,¹ and Systematic Botany, Mycology, and Nematology Laboratory, Biosystematics and Beneficial Insects Institute, U.S. Department of Agriculture, Beltsville, Maryland 20705²

Received 3 December 1985/Accepted 25 February 1986

We investigated a case of maxillary sinus infection caused by the medusoid mutant of the basidiomycetous fungus *Schizophyllum commune*. Morphologies of both typical and medusoid forms of *S. commune* were determined. Prior reports of pathogenic homobasidiomycetes are discussed.

Homobasidiomycetous fungi such as mushrooms, shelf fungi, and their relatives are widely recognized by their fruiting bodies. Some are plant pathogens, some are mycorrhizal fungi, and others are saprobic. Some are harmful to humans upon ingestion because of the toxic or hallucinogenic compounds they contain. Only rarely have any of these fungi been associated with human infections. In 1950 Kligman (8) reported that *Schizophyllum commune* was the first homobasidiomycete discovered to be a possible etiologic agent of human infection. The sporophore of the fungus grew and matured in culture directly from nail fragments. Unfortunately, the fungus could not be reisolated. Batista et al. (1) recovered *S. commune* from cerebrospinal fluid of a patient who had atypical meningitis. The fungus was recovered again in cerebrospinal fluid from the same patient 4 months later. McGinnis (9) included this organism in his list of fungal meningitis agents. Ciferri et al. (2) isolated *S. commune* on three different occasions in sputum from a man with a lung disorder. Restrepo et al. (12) repeatedly isolated *S. commune* from a large lesion that had perforated the hard palate of a four-month-old girl admitted for vomiting, diarrhea, and dehydration. Biopsies of the lesion showed invasion of the epithelium and submucosa without involvement of the small blood vessels.

The only other homobasidiomycetes reported to cause human infection belong to the genus *Coprinus*. In 1954 Emmons (5) noted that he had repeatedly isolated *Coprinus micaceus* from sputum of a patient with chronic respiratory disease. Speller and MacIver (14) and DeVries et al. (4) confirmed that *Coprinus cinereus* (identified as *Coprinus delicatulus* [4]) was involved in an infection following open heart surgery. The aortic valves were completely destroyed, only a tangled mass of septate hyphae remained, and no other organisms were isolated.

CASE REPORTS

Case 1. A 30-year-old female was referred to an ear, nose, and throat clinic in April 1983 for lifelong nasal congestion. The patient vaguely recalled intranasal surgery 10 years previously and also recalled several treatments with irrigation. Otherwise her past history was unremarkable. After an X ray in February 1983 revealed a cloudy maxillary sinus, the patient received several courses of antibiotics, without relief. A negative aspiration was also obtained. A left Caldwell-Luc maxillary sinus procedure (described be-

low) and nasal antral window were surgically performed in September 1983. The surgical contents were cultured in the mycology laboratory, where *S. commune* was identified in pure culture. (This case was first presented at an annual regional meeting of the Am. Soc. Microbiol. at Wagner College, Staten Island, N.Y., in February 1985. It was generously shared by personal communication from E. Altire-Werber.)

Case 2. The second patient, a 75-year-old, obese female, was admitted in December 1984, suffering from pain of the right side of the head and face due to chronic maxillary sinusitis. Also present were hypertension, managed without drugs; a hiatus hernia and diverticulitis, treated with metoclopramide hydrochloride (Reglan), cimetidine (Tagamet), and antacids; upper epigastric pain; a possible lump in her left breast; and cataracts. Past history revealed that the patient was a type II diabetic, managed on diet without medication, and had lost 40 lb in the previous year (going from 210 to ca. 170 lb [ca. 95 to 77 kg]).

A Caldwell-Luc procedure was performed on the right maxillary sinus. The patient was sedated intravenously, after which the sinus area was numbed with a solution containing 1% lidocaine with 0.001% epinephrine. A 2-cm window of the right maxillary sinus was created surgically. Within the sinus there was an accumulation of black necrotic debris and some purulent material filling the entire sinus. The specimen was sent to the department of pathology for bacterial and fungal culture and microdiagnosis. The maxillary antrum mucosa was markedly edematous and reddish; the entire mucosa was removed and sent for histopathology. Another window was cut into the nasoantral area, and iodoform gauze was packed in the maxillary sinus, brought out through the nasoantral window, and secured at the level of the nasal dorsum. The window of the maxillary sinus was closed, with the nasoantral window remaining open for drainage. The patient recovered without event, though she still complains of sinus pain nearly 1 year after surgery.

MATERIALS AND METHODS

Sinus contents and maxillary sinus mucosa were fixed in 10% Formalin, embedded in paraffin, sectioned at 10 μ m, and stained with Gomori methenamine silver with eosin counterstain or in hematoxylin and eosin.

Contents of the sinus were streaked on various bacteriological media: two Trypticase soy agar plates with 5% sheep blood (BAP; BBL Microbiology Systems, Cockeysville, Md.), a chocolate agar plate, a MacConkey agar plate, a

* Corresponding author.

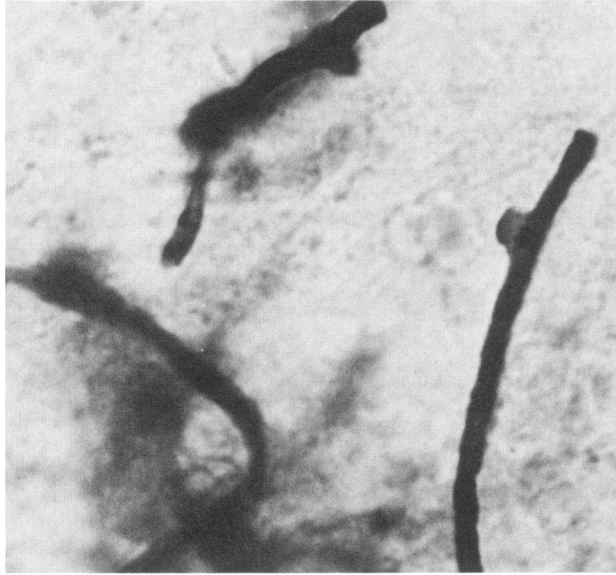


FIG. 1. Hyphae with short lateral projections, or tubercles, in sinus contents. Sample stained with Gomori methenamine silver with eosin counterstain. Magnification, $\times 1,000$.

mannitol salt agar plate, two Columbia colistin nalidixic acid agar plates with 5% sheep blood (CNA), and a thioglycolate broth enriched with hemin and vitamin K. One BAP, one chocolate agar, and one CNA plate were incubated at 37°C in 10% CO₂; one BAP and one CNA plate were incubated at 37°C anaerobically (10% CO₂, 15% H₂, 75% N₂); and the remaining media were incubated at 37°C aerobically.

Sinus contents were also streaked on Sabouraud dextrose agar (SDA) tubes at 30 and 37°C and on Mycosel (BBL) at 30°C. Mycelium developing from the streaks was grown on SDA plates and on potato flakes agar plates (13) at room temperature.

The cover glass sandwich technique (7) was used for temporary mounts in some cases. A flamed cover glass was inserted at an angle into an inoculated streak and through the agar below. The fungus grew up on both sides of the cover glass. For observation 1 drop of lactophenol cotton blue (7) was placed on a slide, and the cover glass was removed from the agar and placed on the drop. Then another 3 drops of stain were placed on top of the cover glass, with a larger cover glass added. Sometimes the fungus grew better on one side of the cover glass than on the other. With this technique, both sides were preserved for use.

Further morphological evaluation and identification were carried out on the complete medium of Raper and Krongelb (11). This medium consists of 20 g of dextrose, 2 g of peptone, 0.5 g of MgSO₄, 0.46 g of KH₂PO₄, 1 g of K₂HPO₄, 120 μg of thiamine hydrochloride, and 20 g of agar per liter of water. Chambers of the type described by Cole and Kendrick (3) were used for observing the mycelium for extended periods of time. The chamber consisted of a glass slide (50 by 75 by 1 mm) with an 18-mm hole bored 15 to 20 mm from one end. A 2-mm-wide slit extended from the hole to the edge of the slide and was about 40 mm long. A cover glass (24 by 60 mm) was attached with petrolatum to the bottom of the chamber to cover the hole and slit. The hole was then filled with the agar medium. When the medium solidified, excess was removed with a sharp razor blade to make the agar surface even with the glass surface. The agar

in the half of the chamber nearest the slit was then removed, and the inoculum was placed against the cut edge of remaining agar. Then another cover glass (24 by 60 mm) was attached with petrolatum to the upper side of the chamber to cover the hole and slit. The end of the slit at the edge of the slide was left open for gas exchange. Fungal growth occurred primarily on the cover glasses. The entire chamber could be placed under the microscope for prolonged observation of the various stages of maturation, even under an oil immersion objective.

RESULTS

Pathology. Sinus contents consisted of necrotic debris. Staining with hematoxylin and eosin and with Gomori methenamine silver with eosin counterstain revealed cellular material admixed with large amounts of bacteria and thick-walled hyphae. The latter contained rare clamp connections and occasional short, aborted hyphal outgrowths (Fig. 1). Mucosal sections showed severe acute and subacute inflammation with no actual invasion of hyphae.

Bacteriology. Isolated on the BAPs, chocolate agar, CNAs, and thioglycolate broth were moderate growths of nonhemolytic streptococci, not group D, and light growths of mold, which were sent to the hospital mycology laboratory for identification. The mold was later identified as the same fungus that had been isolated from mycological cultures of the surgical material. No other organisms were found.

Mycology. Cultures of surgically obtained sinus contents supported good growth of white woolly mold on SDA at 30 and 37°C in 10 days. The colony reverse became light brown on aging. The mold was inhibited on Mycosel. Basidiocarps did not develop on tubed SDA, although clamp connections were observed in lactophenol cotton blue mounts. After incubation for 3 weeks on SDA plates and on potato flakes agar plates the mold formed macroscopic white, tube-shaped, leathery basidiocarps at the colony periphery (Fig. 2).

We identified our patient isolate as the medusoid variant of *S. commune*, a mutant first described by Raper and Krongelb (11). Usually, isolates of *S. commune* form characteristic fan-shaped basidiocarps with split gills (Fig. 3). In our isolate, the original sporophore gave rise to branches in

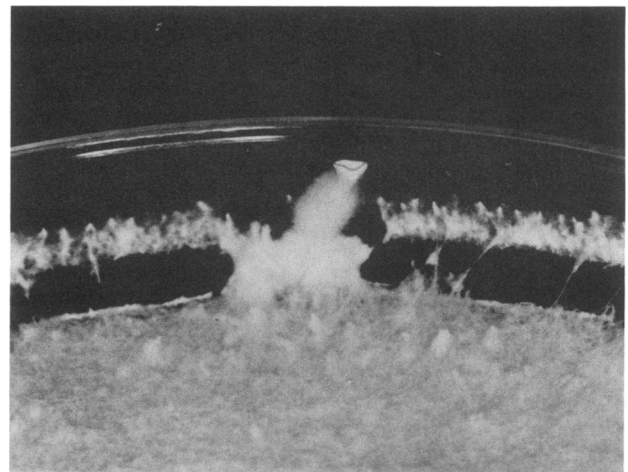


FIG. 2. *S. commune* from maxillary sinus at 3 weeks on SDA, 25°C.

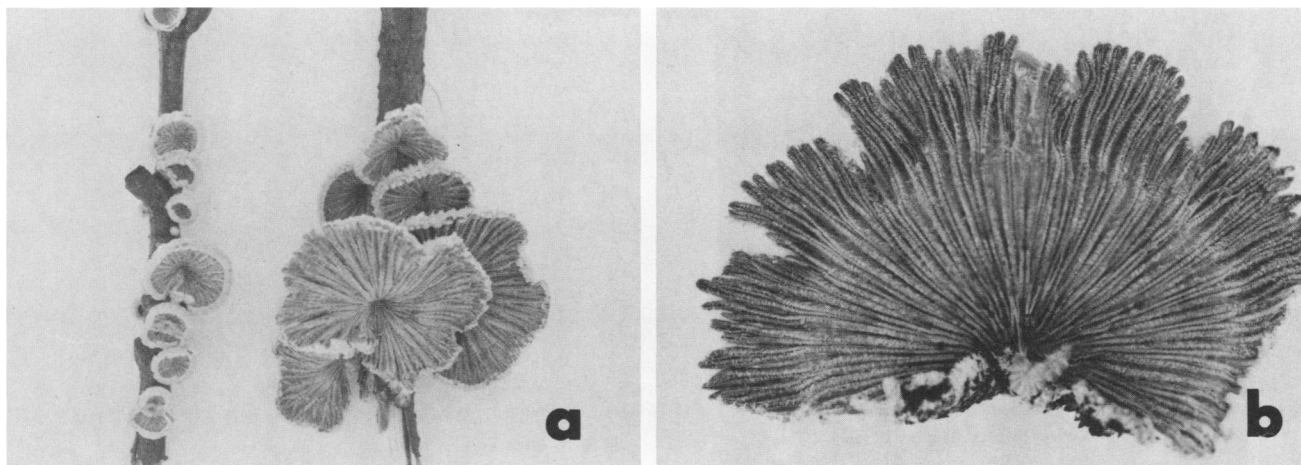


FIG. 3. Typical forms of *S. commune*. (a) With basidiocarps in nature, growing on twigs. (b) With basidiocarp showing split gills.

various directions (Fig. 4a and b), and the tips of some of these branches contained small cavities (Fig. 4c) in which typical basidia and basidiospores were formed. Sometimes the edges of a cavity developed to a limited degree, producing small gills with surfaces oriented in random directions (Fig. 4d).

Mycelia from our isolate did not produce numerous tubercles (small, lateral hyphal projections) until several days elapsed. Tubercles were sparse and were discovered microscopically on only a small percentage of hyphae after 3 days, but after 7 days they were much more numerous (Fig. 5). There was a continuum of hyphal diameters from 1.5 to 6 μm or more, rather than two distinct sizes of hyphae, 1 to 3 μm and 5 to 8 μm , as previously reported (10, 15). A clamp connection developed at essentially every septum.

DISCUSSION

S. commune is a well-known fungus, having been reported as a plant pathogen from 150 countries and every continent except Antarctica (15). It attacks a wide range of host trees, both angiosperms and gymnosperms. On wood the basidiocarps are 2 to 30 mm or more in diameter, more or less

villose or tomentose when young, but later they may become smooth. They are white when young but become grayish at maturity. The split gills (Fig. 3) are the most distinctive and unique feature of this fungus. Previous workers (10, 15) found that *S. commune* can be identified with reasonable certainty in culture by observing two kinds of hyphae: narrow filaments to 3 μm in diameter and wider ones that are 5 to 8 μm in diameter. In our isolate a continuum of hyphal diameters occurred rather than two distinct classes. Many of the wider hyphae have small lateral projections, or tubercles, which Nobles (10) considered diagnostic for the species. She stated that these structures are always present but are easily overlooked (Fig. 5). A typical hypha has a clamp connection at every septum. The few branches that do arise do so near septa. Another factor useful in identifying this fungus is the possession of extracellular oxidases. These are the enzymes that digest lignin from wood and produce a white rot. Presence of the enzymes can be detected in culture by placing 1 drop of alcoholic gum guaiac (0.5 g in 30 ml of 95% ethanol solution) on the mycelium. A blue spot forms immediately if the enzymes are present.

Development of a normal basidiocarp (15) begins with the

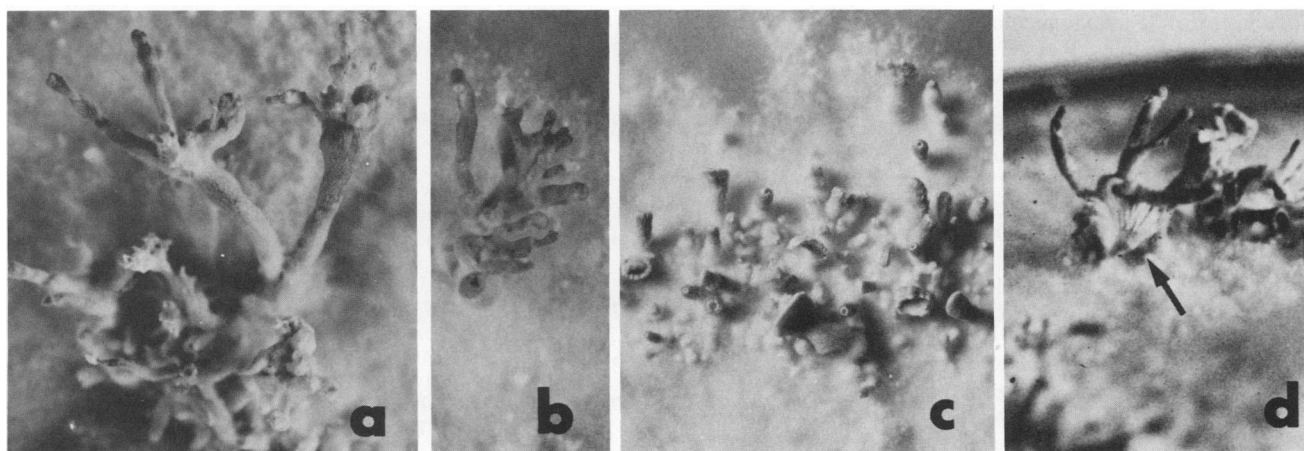


FIG. 4. Various forms of the medusoid variant from maxillary sinus, grown on Raper-Krongelb agar. (a and b) Coralloid branching. (c) Younger stages with inverted cup-like apices on some branches. (d) Coralloid form. Arrow indicates small basidiocarp, which can be identified by its split gills.

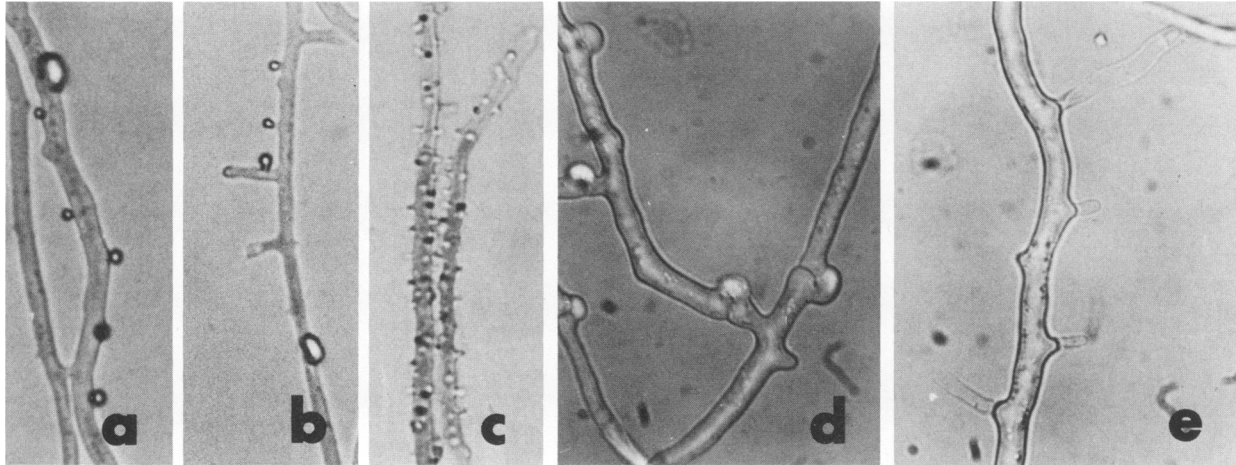


FIG. 5. Hyphae of *S. commune*. (a and b) Tubercles with spherical excretions. (c) Short, thin, truncate tubercles, which are diagnostic for *S. commune*. (d) Hyphae with clamp connections. (e) Broad, truncate tubercles with hyphae emerging from the ends. Magnification, $\times 1,000$.

formation of a column that grows toward the light. A small cavity, in which basidia develop, forms in the apex of the column. The tip of the column turns downward so that the cavity has the form of an inverted cup. The outer rim of the cup continues to grow, and new gill tissue is added from the rim. The basidiocarp becomes fan shaped as it enlarges, while the original column remains part of the more or less eccentric stalk. The medusoid variant is formed when the tip of the column fails to turn downward and produce new gill tissue from the rim. Instead, the column elongates and branches (Fig. 4a and b) or thickens (Fig. 4c). According to Raper and Krongelb (11), the medusoid character occurs frequently in nature and is genetically complex. Offspring of some medusoid \times wild-type crosses are normal, whereas in other such crosses the offspring are a mixture of medusoid and normal. Full expression of the medusoid character requires that both strains carry medusoid components.

Greer and Bolanos (6) studied the pathogenic potential of *S. commune* in white Swiss mice. Their inoculum was the same isolate described by Restrepo et al. (12). Three age groups of mice were treated: suckling (0 to 15 days), weanling (16 to 30 days), and adult (older than 30 days). When injected intraperitoneally with 10^2 viable particles of inoculum, 1 of 21 sucklings died in 8 to 10 days. At a dosage of 10^3 viable particles, 9 of 21 sucklings died in 8 to 10 days. None of the weanlings died after 4 weeks with intraperitoneal inoculation of 10^4 viable particles, and none of the adults died after similar inoculations with 10^3 viable particles. When weanlings and adults were treated with cortisone before injection with fungus, 15 of 20 weanlings died in week 1, whereas cortisone had no effect on susceptibility to infection in adults. Disease was produced in all age groups, with or without cortisone, and the mold affected the lymph nodes, liver, and spleen. It was concluded that induced infection follows a course characteristic of most opportunistic fungi, e.g., a progressive infection of low virulence aided by immunosuppressive agents, with death occurring in some very young animals.

In light of past research and our two case reports, it appears that *S. commune* can be expected to afflict the oral-nasal areas of the body. It is reasonable but unsubstantiated to conjecture that inhalation of basidiospores is the usual mode of exposure. This basidiomycete is certainly

prevalent in nature. The rare human cases may reflect a compromised immune status due to antibiotic or steroid therapy, or previous underlying disorders such as diabetes or malignancy. In the future it is clear that clinical laboratories must not overlook basidiomycetes as potential opportunistic pathogens.

ACKNOWLEDGMENTS

We thank D. F. Farr, Biosystematics and Beneficial Insects Institute, U.S. Department of Agriculture, Beltsville, Md., H. H. Burdsall, Jr., Forest Diseases Laboratory, U.S. Forest Service, Madison, Wis., and A. A. Padhye, Centers for Disease Control, Atlanta, Ga., for assisting and confirming the identity of our isolate. We appreciate the photographic assistance of Michael Dolan, Pathology Department, and Grant McClure, Radiology Department, Southern Maryland Hospital Center, Clinton, Md. We also thank A. Garro, Southern Maryland Hospital Center.

LITERATURE CITED

- Batista, A. D., J. A. Maia, and R. Singer. 1955. Basidiomycosis on man. *An. Soc. Biol. Pernambuco* 13:52-60.
- Ciferri, R., A. C. Batista, and S. Campos. 1956. Isolation of *Schizophyllum commune* from a sputum. *Atti Ist. Bot. Lab. Crittogam. Univ. Pavia* 14:3-5.
- Cole, G. T., and W. B. Kendrick. 1968. A thin culture chamber for time-lapse photomicrography of fungi at high magnifications. *Mycologia* 60:340-344.
- DeVries, G. A., R. F. O. Kemp, and D. C. E. Speller. 1971. Endocarditis caused by *Coprinus delicatulus*. *C. R. Commun. Congr. ISHAM* 5:185-186.
- Emmons, C. W. 1954. Isolation of *Myxotrichum* and *Gymnoascus* from lungs of animals. *Mycologia* 46:334-338.
- Greer, D. L., and B. Bolanos. 1974. Pathogenic potential of *Schizophyllum commune* isolated from a human case. *Sabouraudia* 12:233-244.
- Kern, M. E. 1985. *Medical mycology: a self-instructional text*, p. 61-63. F. A. Davis Co., Philadelphia.
- Kligman, A. 1950. A basidiomycete probably causing onychomycosis. *J. Invest. Dermatol.* 14:67-70.
- McGinnis, M. R. 1983. Detection of fungi in cerebrospinal fluid. *Am. J. Med.* 75(1B):129-138.
- Nobles, M. K. 1965. Identification of cultures of wood-inhabiting hymenomycetes. *Can. J. Bot.* 43:1097-1139.
- Raper, J. R., and G. S. Krongelb. 1958. Genetic and environmental aspects of fruiting in *Schizophyllum commune* Fr.

- Mycologia **50**:707-740.
12. **Restrepo, A., D. L. Greer, M. Robledo, O. Osorio, and H. Mondragon.** 1973. Ulceration of the palate caused by a basidiomycete *Schizophyllum commune*. Sabouraudia **11**:201-204.
 13. **Rinaldi, M. G.** 1982. Use of potato flakes agar in clinical mycology. J. Clin. Microbiol. **15**:1159-1160.
 14. **Speller, D. C. E., and G. MacIver.** 1971. Endocarditis caused by a *Coprinus* species: a fungus of the toadstool group. J. Med. Microbiol. **4**:370-374.
 15. **Watling, R., and J. Sweeney.** 1974. Observations on *Schizophyllum commune* Fries. Sabouraudia **12**:214-226.