

# Native Valve Endocarditis Caused by an Organism Resembling *Corynebacterium striatum*

SHELDON M. MARKOWITZ<sup>1\*</sup> AND PHILIP E. COUDRON<sup>2</sup>

Departments of Medicine<sup>1</sup> and Pathology,<sup>2</sup> Hunter Holmes McGuire Veterans Administration Medical Center and  
Medical College of Virginia, Richmond, Virginia 23249

Received 13 July 1989/Accepted 18 September 1989

**An organism resembling *Corynebacterium striatum* was isolated from the blood of a patient with acute aortic valvular insufficiency and no history of valvular heart disease. At autopsy, histopathologic examination of the aortic valve revealed pleomorphic gram-positive bacilli and destruction of valvular tissue. Our isolate differed from other nondiphtherial corynebacteria, including the type strain of *C. striatum* (ATCC 6940), in its ability to reduce nitrite. Nitrite reduction may be useful for distinguishing strains of corynebacteria.**

*Corynebacterium* species are widely distributed in the environment and are prominent members of the normal skin and mucous membrane flora. These organisms are often regarded as contaminants, with little or no capacity to cause human infections. However, recent evidence suggests that the nondiphtherial corynebacteria cause a spectrum of clinical illnesses including skin infections, lymphadenitis, pneumonia, endocarditis, pharyngitis with and without a scarlatiniform rash, and even diphtheria (1, 10, 12, 14, 18). Failure to identify "diphtheroid" organisms definitively in many infectious processes has hampered our understanding of the true pathogenic role of these organisms. Endocarditis due to corynebacteria has been reported in patients with prosthetic heart valves and underlying congenital or rheumatic heart disease (8, 11, 13, 15). Endocarditis of normal native valves is rare (7, 17). In this report, we present the clinical and laboratory results of a fatal case of infective endocarditis of a normal native heart valve due to an organism resembling *Corynebacterium striatum*.

## CASE REPORT

A 76-year-old male with no history of heart disease was transferred to the McGuire Veterans Administration Medical Center for acute aortic valvular insufficiency and insipient congestive heart failure. He had presented 6 days earlier to another hospital with a 2-day history of back pain, fever, vomiting, and malaise. At that time, his temperature was 38.9°C, his blood pressure was 130/60, and his pulse rate was 104. An aortic valvular insufficiency murmur was heard for the first time. Six blood cultures were obtained, and all were positive with a single gram-positive bacillus resembling a diphtheroid. The patient was placed on parenteral ampicillin and gentamicin and transferred to our institution for emergency aortic valve replacement. On arrival, the patient was obtunded with a temperature of 39.2°C, blood pressure of 110/40, and pulse rate of 112. He was in gross pulmonary edema with loud murmurs of aortic and tricuspid insufficiency, which were confirmed by two-dimensional echocardiography. The patient became hemodynamically unstable, suffered a cardiopulmonary arrest, and expired 6 h after arrival. Postmortem findings included a ruptured right coronary aortic cusp and large vegetations on both the right coronary and noncoronary cusps. Tissue from the vegetation was sent for stain and culture.

\* Corresponding author.

## MATERIALS AND METHODS

Media were obtained from Difco Laboratories, Detroit, Mich., and biochemical tests were performed by conventional methods (5). Tests for nitrite reduction included some modifications: the medium consisted of heart infusion broth (25 mg/ml), potassium nitrite (10 µg/ml), and horse serum (10%) (pH 7.0). Cells were grown for 48 h on sheep blood agar and suspended in brain heart infusion broth (McFarland standard no. 1); 3 drops of this suspension were added to 4 ml of the nitrite broth medium. The medium was incubated at 37°C and tested for nitrite reduction at 2 and 5 days. Growth was scored on the basis of turbidity. Conventional reagents were used to detect nitrite (5). Gas production from nitrite reduction was determined by placing a Durham vial in the medium. If the broth failed to contain nitrite and no gas was produced, zinc dust was added to ensure that nitrite had not been oxidized to nitrate. The following strains were tested for nitrite reduction: *C. striatum* ATCC 6940, *C. aquaticum* ATCC 14665, *C. bovis* ATCC 7715, *C. pseudodiphthericum* ATCC 10700, *C. xerosis* ATCC 373, *Corynebacterium* group JK (ATCC 43734), *Arcanobacterium haemolyticum* ATCC 9345, *Actinomyces pyogenes* ATCC 19411, and *Corynebacterium* group A-4 (CDC F-4277). *Alcaligenes faecalis* ATCC 8750 and uninoculated medium served as the positive and negative controls, respectively. Elastase activity was measured by the elastin-Congo red substrate (Sigma Chemical Co., St. Louis, Mo.) method (3), proteolytic activity was measured by using Hide powder azure (Sigma) (16), and phospholipase activity was determined by using *p*-nitrophenylphosphorylcholine (Sigma) as substrate (2).

## RESULTS

Postmortem cultures of the aortic valve and vegetation revealed no growth. Histopathologic sections of the aortic valve and cusps showed dense concentrations of gram-positive pleomorphic bacilli (Fig. 1) with destruction of valve tissue. No underlying valvular abnormalities were noted.

On the basis of test results (9), the blood isolate phenotypically most closely resembled *C. striatum* and *C. xerosis*. The isolate was sent to the Centers for Disease Control, Atlanta, Ga., where it was identified as similar to *C. striatum* ATCC 6940 except for the nitrite reaction.

Due to the discrepant nitrite results between our isolate and the type strain of *C. striatum*, ATCC 6940, additional

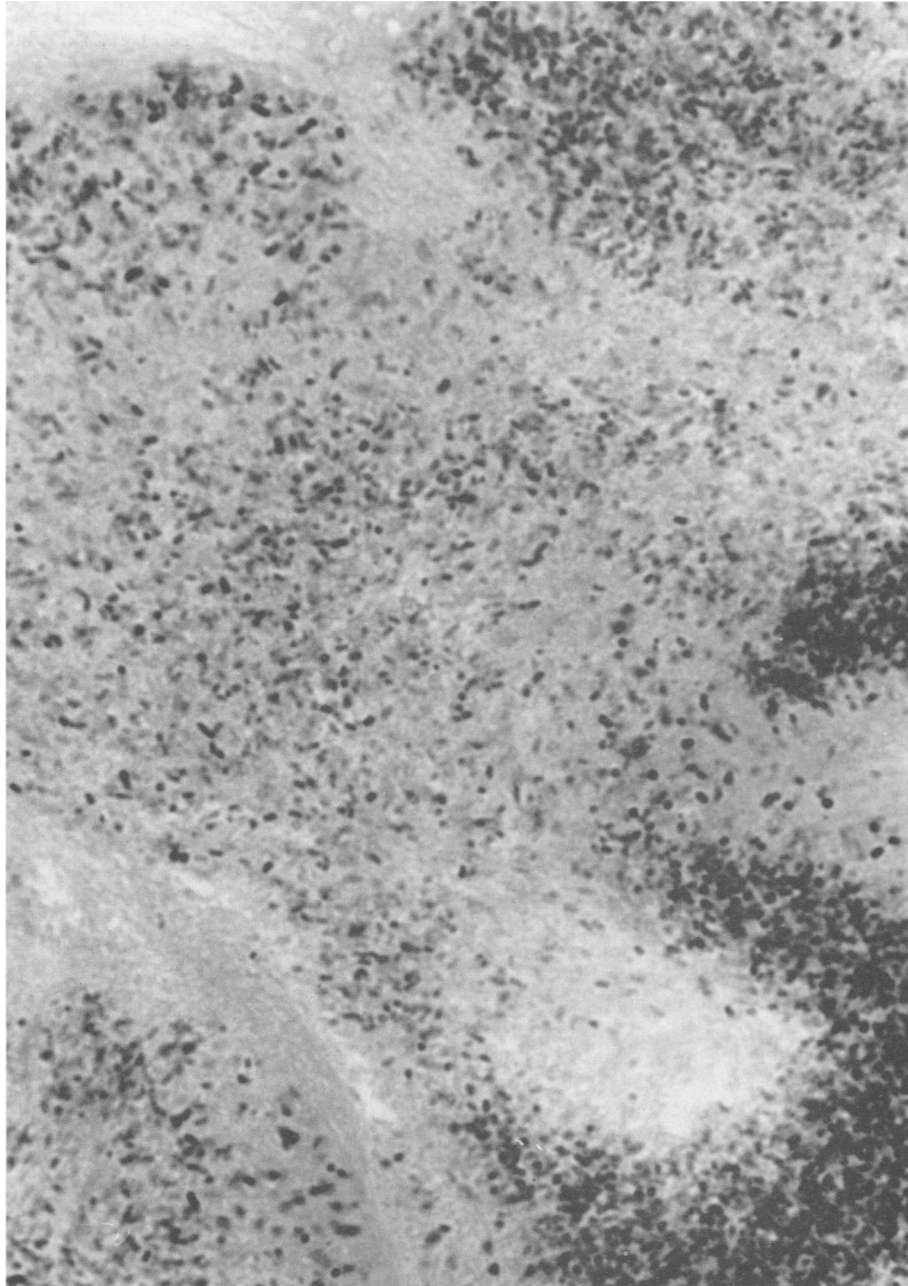


FIG. 1. Gram stain (Brown-Brenn) of a histopathologic section of the aortic valve showing numerous gram-positive pleomorphic bacilli and severe valvular destruction. Magnification,  $\times 1,000$ .

strains of gram-positive bacilli were tested for nitrite reduction. All isolates showed good growth in the broth medium at 2 days. Nitrite results for each strain tested at 2 and 5 days agreed. Of all gram-positive bacilli tested, including the type strain of *C. striatum*, only the VA strain reduced nitrite (Table 1). The positive control strain, *Alcaligenes faecalis* ATCC 8750, reduced nitrite, whereas the uninoculated medium was negative. No extracellular enzyme activity was detected.

#### DISCUSSION

We isolated an organism resembling *C. striatum* from the blood of an elderly male with acute aortic valve endocarditis

and believe this report is unique in several respects. First, this is the only report of endocarditis due to an organism resembling *C. striatum*. Second, the severity of the infection and its occurrence in an immunocompetent host were remarkable. Third, the VA strain described herein is distinctive among the "avirulent" corynebacteria in its capacity to reduce nitrite to gaseous nitrogen or other compounds containing nitrogen.

Only one report of infection due to *C. striatum* has been published, that of an elderly male with chronic lymphocytic leukemia who developed a fatal pleuropulmonary infection (4). The organism was isolated from the blood and identified by the Centers for Disease Control. No information on the

TABLE 1. Nitrite and nitrate reduction reactions for selected gram-positive bacilli

Organism	Reaction	
	Nitrite reduction	Nitrate reduction <sup>a</sup>
VA strain	+	+
<i>C. striatum</i> ATCC 6940	-	+
<i>C. aquaticum</i> ATCC 14665	-	V
<i>C. bovis</i> ATCC 7715	-	-
<i>C. pseudodiphthericum</i> ATCC 10700	-	+
<i>C. xerosis</i> ATCC 373	-	+
<i>Corynebacterium</i> group JK (ATCC 43734)	-	-
<i>Corynebacterium</i> group A-4 (CDC F-4277)	-	V
<i>Arcanobacterium haemolyticum</i> ATCC 9345	-	-
<i>Actinomyces pyogenes</i> ATCC 19411	-	-

<sup>a</sup> Data from reference 7. Number of strains tested varied from 1 to 139. V, Variable.

nitrite reaction was given. *C. striatum* is part of the flora of the nasal mucous membranes (6). Other corynebacteria considered part of the normal human flora (e.g., *C. xerosis* and *Corynebacterium* group JK) have caused infective endocarditis (7, 11).

Other than diphtheria, severe or systemic infections due to corynebacteria usually occur in patients with anatomical alterations or who are immunocompromised. Our patient had severe tissue destruction not commonly seen with avirulent members of the normal human skin. This is especially striking given the presence of an apparently normal aortic valve. Tissue-destructive enzymes, particularly the dermonecrotic toxin of *C. ulcerans* and *C. pseudotuberculosis*, have been shown to have a predilection for vascular endothelium and to have lethal effects in experimental animals (11). Despite the aggressive nature and rapid valvular destruction seen in this patient, the organism did not produce extracellular enzymes such as elastases, proteases, and phospholipases.

With one exception, the biochemical test results of our isolate and the type strain of *C. striatum*, ATCC 6940, were identical. The exception was nitrite reduction; our isolate reduced nitrite, but neither the type strain nor the other species of *Corynebacterium* that were tested did. No strain produced gas, which could have been due to the low concentration of nitrite in the testing medium. Few reports of nondiphtherial corynebacteria include data for nitrite reduction. Although we studied a limited number of strains, the nitrite test may prove to be helpful for distinguishing different species of corynebacteria.

#### ACKNOWLEDGMENT

We thank Jean Ryland for typing the manuscript.

#### LITERATURE CITED

- Banck, G., and M. Nyman. 1986. Tonsillitis and rash associated with *Corynebacterium haemolyticum*. *J. Infect. Dis.* **154**:1037-1040.
- Berka, R. M., G. L. Gray, and M. L. Vasil. 1981. Studies of phospholipase C (heat-labile hemolysin) in *Pseudomonas aeruginosa*. *Infect. Immun.* **34**:1071-1074.
- Bjorn, M. J., P. A. Sokol, and B. H. Iglewski. 1979. Influence of iron on yields of extracellular products in *Pseudomonas aeruginosa* cultures. *J. Bacteriol.* **138**:193-200.
- Bowstead, T. T., and S. M. Santiago. 1980. Pleuropulmonary infection due to *Corynebacterium striatum*. *Br. J. Dis. Chest* **74**:198-200.
- Clark, W. A., D. G. Hollis, R. E. Weaver, and P. Riley. 1984. Identification of unusual pathogenic gram-negative aerobic and facultatively anaerobic bacteria, p. 8-25. Centers for Disease Control, Atlanta.
- Collins, M. D., and C. S. Cummins. 1986. Genus *Corynebacterium*, p. 1266-1276. In P. H. A. Sneath, N. S. Mair, M. E. Sharpe, and J. G. Holt (ed.), *Bergey's manual of systematic bacteriology*, vol. 2. The Williams & Wilkins Co., Baltimore.
- Eliakim, R., P. Silkoff, G. Lugassy, and J. Michel. 1983. *Corynebacterium xerosis* endocarditis. *Arch. Intern. Med.* **143**:1995.
- Gerry, J. L., and W. B. Greenough III. 1976. Diphtheroid endocarditis: reports of nine cases and review of the literature. *Johns Hopkins Med. J.* **139**:61-68.
- Hollis, D. G., and R. E. Weaver. 1986. Gram-positive organisms: a guide to identification, p. 3. Centers for Disease Control, Atlanta.
- House, R. W., M. Schousboe, J. P. Allen, and C. C. Grant. 1986. *Corynebacterium ovis* (pseudo-tuberculosis) lymphadenitis in a sheep farmer: a new occupational disease in New Zealand. *N. Z. Med. J.* **99**:659-662.
- Lipsky, B. A., A. C. Goldberger, L. S. Tompkins, and J. J. Plorde. 1982. Infections caused by nondiphtheria corynebacteria. *Rev. Infect. Dis.* **4**:1220-1235.
- McNaughton, R. D., R. R. Villanueva, R. Donnelly, J. Freedman, and R. Nawrot. 1988. Cavitating pneumonia caused by *Corynebacterium* group JK. *J. Clin. Microbiol.* **26**:2216-2217.
- Murray, B. E., A. W. Karchmer, and R. C. Moellering, Jr. 1980. Diphtheroid prosthetic valve endocarditis: a study of clinical features and infecting organisms. *Am. J. Med.* **69**:838-848.
- Van Etta, L. L., G. A. Filice, R. M. Ferguson, and D. N. Gerding. 1983. *Corynebacterium equi*: a review of 12 cases of human infection. *Rev. Infect. Dis.* **5**:12-18.
- Van Scoy, R. E., S. N. Cohen, J. E. Geraci, and J. A. Washington II. 1977. Coryneform bacterial endocarditis: difficulties in diagnosis and treatment, presentation of three cases, and review of literature. *Mayo Clin. Proc.* **52**:216-219.
- Woods, D. E., M. S. Schaffer, H. R. Rabin, G. D. Campbell, and P. A. Sokol. 1986. Phenotypic comparison of *Pseudomonas aeruginosa* strains isolated from a variety of clinical sites. *J. Clin. Microbiol.* **24**:260-264.
- Worthington, M. G., B. D. T. Daly, and F. E. Smith. 1985. *Corynebacterium hemolyticum* endocarditis on a native valve. *South. Med. J.* **78**:1261-1262.
- Young, V. M., W. F. Meyers, M. R. Moody, and S. C. Schimpff. 1981. The emergence of coryneform bacteria as a cause of nosocomial infections in compromised hosts. *Am. J. Med.* **70**:646-650.