

## CONTINUING MEDICAL EDUCATION

# Basic Knowledge of Refractive Surgery

Correction of Refractive Errors Using Modern Surgical Procedures

Thomas Kohnen, Anja Strenger, Oliver K. Klaproth

## SUMMARY

**Introduction:** Refractive ophthalmic surgery allows refractive errors to be corrected permanently in a safe, effective, and reliable way with few complications.

**Methods:** Selective literature review with special reference to the guidelines of the German Commission for Refractive Surgery.

**Results:** With a total of almost 18 million treatments performed to date, laser in-situ keratomileusis (LASIK) is the most commonly used refractive surgical procedure worldwide. Alternatives to LASIK include surface ablation procedures (PRK, LASEK, Epi-LASIK) and phakic intraocular lens implantation. If ocular accommodation is lost, removal of the crystalline lens and implantation of modern multifocal intraocular lenses (refractive lens exchange) provide an alternative means of correcting myopia, hyperopia and presbyopia.

**Discussion:** The treatment effect is maximized and complications kept to a minimum if strict inclusion criteria are applied and a high technical standard maintained during the procedure.

Dtsch Arztebl Int 2008; 105(9): 163–72  
DOI: 10.3238/arztebl.2008.0163

**Key words:** excimer, refractive surgery, surface ablation, LASIK, phakic intraocular lenses, refractive lens exchange

Klinik für Augenheilkunde der Johann-Wolfgang-Goethe-Universität, Frankfurt am Main: Prof. Dr. med. Kohnen, Dipl.-Ing. (FH) Strenger, Dipl.-Ing. (FH) Klaproth

**R**efractive surgery, a subfield of ophthalmology, is defined as the surgical correction of refractive errors of the human eye. It has become a highly specialized area in the last few years. Ophthalmic surgeons now have a multiplicity of refractive surgical methods at their disposal for the individualized correction of refractive errors. Techniques of refractive surgery on the cornea and lens are now available that reliably fulfill the standard criteria of safety, efficacy, cost-effectiveness, and predictability of the refractive outcome (1, e1).

The learning objectives of this article are that the reader

- should become familiar with the different techniques of refractive surgery now available for the correction of refractive errors of the human eye,
- should know the indications for each technique according to the guidelines of the German Commission for Refractive Surgery,
- and should be able to inform patients about the contraindications and possible complications of each technique.

This CME article is based on a selective review of the literature and on the authors' personal experience of more than 6000 refractive surgical procedures.

## Refractive errors in the human eye

Refractive errors are measured in diopters (D) and are classified as axially symmetrical, astigmatic, or (most commonly) mixed. The axially symmetrical types of refractive error are nearsightedness (myopia) and farsightedness (hyperopia). Myopia is present when the eye is too long in relation to its refractive apparatus (e2). In the myopic eye, parallel incident light rays are focused onto a point in front of the retina, and the image on the retina itself is blurred (*figure 1, I*). Hyperopia (or hypermetropia) is the medical term for farsightedness. This type of refractive error arises when the eye is too short for its refractive apparatus. In this case, parallel incident light rays are focused – theoretically, that is – onto a point behind the retina, and the image on the retina itself

## Refractive errors

are classified as axially symmetrical refractive errors (myopia, hyperopia), astigmatic refractive errors (astigmatism), and presbyopia. Refractive errors of these types represent lower-order aberrations.

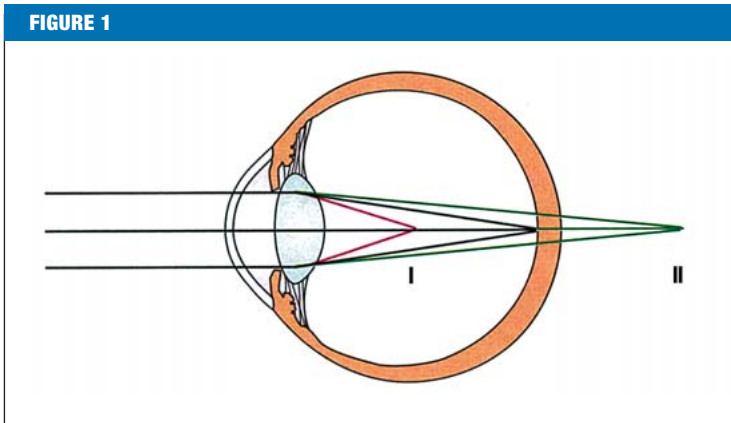


Image formation in myopia and hyperopia. In myopia, the image of a point at infinity is projected in front of the retina (I); in hyperopia, the image of a point at infinity is projected behind the retina (II).

is likewise blurred (*figure 1, II*). Myopia and hyperopia are often found in combination with astigmatism, though astigmatism can also occur alone.

The refractive apparatus of the eye essentially consists of the cornea, the anterior chamber, the lens, and the vitreous. These elements constitute two functional groups, the corneal system and the lens system. The refractive power of the corneal system is about 40 to 50 diopters, while that of the lens system is much less, about 15 to 25 diopters, as measured at accommodative rest with the eyes focused on a point in the distance. Astigmatism arises when one or both of the two refractive media – the cornea and the lens – has a different curvature, and therefore a different refractive power, in two meridians. When this is the case, the uneven refraction of a light ray that is incident upon the eye results in the projection of a displaced or distorted image onto the retina, rather than a point image. A further type of refractive error is the presbyopia that occurs in normal aging, which is caused by a gradual loss of flexibility of the lens rendering it unable to increase its refractive power for near vision, i.e., to accommodate. Most people lose the ability to accommodate during the fifth decade of life.

Finally, in addition to the types of refractive error just described (lower-order aberrations), there can also be aberrations of higher order, which are deviations from the ideal wavefront that impair the quality of the retinal image and cannot be corrected with eyeglasses or contact lenses. The wave nature of light lies at the basis

of the scientific description of ocular wavefronts (2). Two commonly occurring and long-recognized types of higher-order aberration are coma (asymmetry error) and spherical aberration (aperture error).

### Refractive surgical techniques

Two currently established surgical methods for the correction of refractive error are refractive corneal surgery and refractive lens surgery. Excimer laser techniques and incisional procedures are used in refractive corneal surgery; phakic intraocular lenses (PIOL) and refractive lens exchange (RLE) are used in lens surgery.

#### Refractive corneal surgery

An excimer ("excited dimer") laser is an argon fluoride laser operating with a wavelength of 193 nanometers. The cornea is remodeled with laser ablation so that light rays falling upon the eye join together precisely in the spot on the retina that possesses the sharpest vision (macula). The procedures employing excimer lasers to correct refractive errors are of two types:

- surface treatment techniques and
- lamellar treatment techniques.

The surface treatment techniques include photorefractive keratectomy (PRK), laser-subepithelial keratomileusis (LASEK), and epi-LASIK. In these three types of procedure, corneal tissue is ablated with an excimer laser just below the corneal epithelium, which is the outermost of the five layers of the cornea. Before ablation, the corneal epithelium is removed by a mechanical or chemical method or with a laser (as in PRK), with an alcohol solution (as in LASEK), or else it is separated from the underlying tissue with a microkeratome (as in epi-LASIK). After ablation, the corneal epithelium is put back in place.


The combination of a lamellating stromal corneal incision with excimer-laser ablation is known as laser in situ keratomileusis (LASIK). In this technique, a microkeratome or a femtosecond laser is used to cut a flap which is folded back to have access to stromal tissue (*figure 2*). Unlike the surface treatment techniques, laser ablation is performed in a deeper layer of the cornea, i.e., the anterior stroma. After ablation, the flap is put back into its original position, where it sticks to the cornea without any further intervention because of adhesive forces and the pumping effect of the endothelium and then becomes definitively fixed in place by tissue growth within a few hours (e3).

### Presbyopia

is a part of normal aging and a further type of refractive error impairing near vision.

### Excimer laser techniques

can be used to correct the spherical and cylindrical components of refractive error. Modern laser profiles can also correct refractive errors due to higher-order aberrations in the eye.



**Figure 2:** A LASIK procedure with a femtosecond laser and an excimer laser: a) The laser beams are focused, under computer guidance, onto a point lying at a precisely calculated depth (femtosecond laser). b) A flap is created by the concentration of many thousands of individual laser pulses in a single plane. c) The flap is lifted, and the refractive error is corrected with the argon fluoride excimer laser. d) Finally, the flap is repositioned.

The femtosecond laser is the newest technology for creating a corneal flap. It is very safe: the risk of a cutting error, as may occur with a mechanical microkeratome, is extremely low. The 40- and 50-kHz lasers that were previously used have now been replaced by 60-kHz lasers, which are currently available on the market. This technology also prevents the occurrence of delayed hypersensitivity syndrome (DHS). The time needed for visual rehabilitation is roughly the same whether the corneal flap is created with femtosecond laser or with a microkeratome. Despite their advantages, femtosecond lasers are used in only a few centers at present.

The ablation profile of an excimer laser counteracts the spherical and cylindrical portions of the refractive error (*box 1*) (3, e4). To correct myopia, an excimer laser is used to remove a round lenticule (piece of tissue) from the center of the cornea. Ablation to correct hyperopia is performed in the corneal periphery, so that the curvature of the central portion of the cornea is increased and the refractive index of the cornea is made higher. Modern aspheric (i.e., deviating from spherical shape) and wavefront-guided ablation profiles are used to prevent the generation of higher-order aberrations (HOA) of the eye, or to reduce HOA that are already present (3, 4, e4–e6), and thus improve the patient's vision. To adjust the ablation profile more precisely, "eye trackers" registering the position of the iris are used to correct for horizontal, vertical, and rotatory eye movements. An eye tracker is a pursuit system that ensures the removal of corneal tissue at the intended location and prevents accidental decentering of the ablation zone. It can compensate for ocular saccades that occur during treatment. If the patient should suddenly make a large-amplitude eye movement, the ablation procedure is interrupted.

**BOX 1**

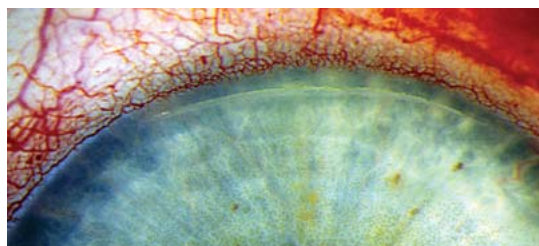
**Ablation profile of the excimer laser\*1**

- based on the overall optical system
  - Conventional profile (calculated with the Munnerlyn formula)
  - Wavefront-guided
  - Wavefront-optimized
- based on corneal topography (the surface contour of the cornea)
  - Topography-guided
  - Aspheric

\*1 modified from 3, e4

**Incisions**

Incisional techniques are used to correct astigmatism. A diamond knife or femtosecond laser is used to make multiple microscopic cuts perpendicular to the steep meridian of the cornea in order to alter the corneal surface curvature in such a way as to cancel out the patient's astigmatism. One or two cuts are made either centrally (astigmatic keratotomy, AK) or near the limbus (limbal relaxation incision, LRI, *figure 3*), as necessary. Incisional techniques have an intermediate degree of reliability and are a highly cost-effective means of correcting astigmatism (e10).



**Figure 3:** Limbal relaxation incision (LRI) at the edge of the cornea to correct astigmatism

**The femtosecond laser**

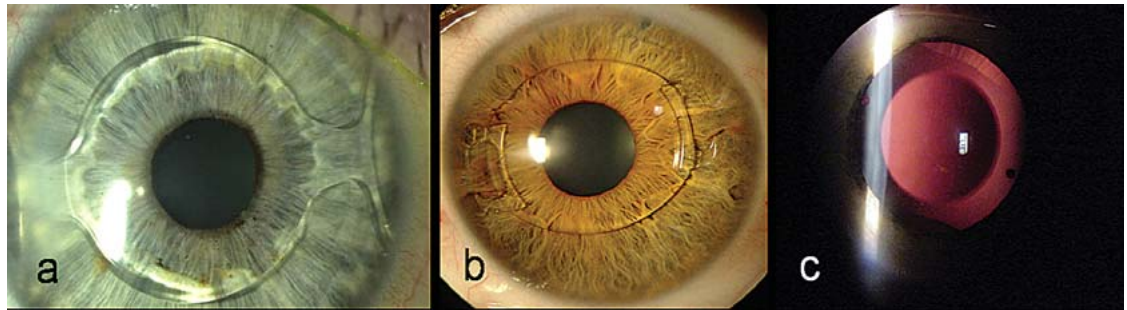
is a technical innovation that is used to create a corneal flap more safely than is possible with a mechanical keratome.

**Incisional techniques**

are used to make one or two cuts in the cornea to correct astigmatism.

**Figure 4:**

Foldable phakic intraocular lenses in situ:  
 a) angle-supported,  
 b) iris-fixated,  
 c) sitting in the posterior chamber.



**Refractive lens surgery**

An artificial lens (intraocular lens) can be implanted into the eye either in addition to, or instead of, the natural lens: phakic intraocular lenses (PIOL) are implanted into the eye without removing the natural lens, while the lens is removed when a refractive lens exchange (RLE) is performed. These methods leave the cornea untouched and are particularly advantageous for patients with high refractive errors and corneal pathology.

**Phakic intraocular lenses**

Phakic intraocular lenses are implanted into the human eye in addition to the natural ocular lens. They can be implanted into either the anterior or the posterior chamber. Anterior chamber lenses come in two kinds – angle-supported and iris-fixated – depending on the site where their position in the eye is secured (figures 4a and 4b).

Posterior chamber lenses are implanted between the iris and the natural lens of the eye (figure 4c). Rigid PIOLs are made of polymethyl methacrylate (PMMA);

there are also flexible ones made of acrylate and silicone that can be implanted through an incision measuring no more than 3 mm. Flexible PIOL are not only relatively easy to implant, they are also nearly astigmatism-neutral.

**Refractive lens exchange**

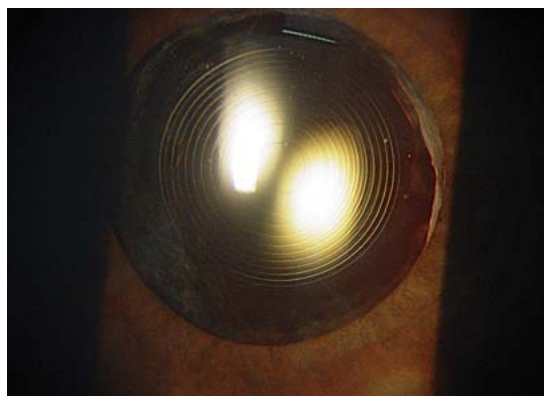
Refractive lens exchange (RLE) is the replacement of the patient's natural ocular lens with an artificial one. The eye is opened at the edge of the cornea and the natural lens is broken down and suctioned away with the aid of an ultrasonic device, as in modern cataract surgery. A new, artificial lens is then inserted into the capsular bag: it may be either monofocal (i.e., suitable for sharp vision either at close range or at a distance) or multifocal. Multifocal IOL have the advantage that the patient can see both near and far objects sharply, without having to wear reading glasses for near vision (figure 5).

**Indications**

The Commission for Refractive Surgery (Kommission Refraktive Chirurgie, KRC), a joint committee of the German Ophthalmological Society (Deutsche Ophthalmologische Gesellschaft, DOG) and the Professional Association of Ophthalmologists in Germany (Berufsverband der Augenärzte Deutschlands, BVA) has issued generally applicable indication criteria for refractive surgical procedures with the aim of preventing severe complications (www.augeninfo.de/krc; box 2, figures 6 and 7; [6]). The "range of applicability" (or "indicated range") is the range of preoperatively measured parameters within which the technique in question is considered to be suitable and has only rare adverse effects. In the area of "borderline applicability," the technique in question can still be used, though perhaps to less good effect and with more common adverse effects. In

**Figure 5:**

Refractive lens exchange: a multifocal intraocular lens with apodized diffractive structure of the anterior lens surface, in situ, for both near and far vision



**The implantation of phakic intraocular lenses**

is a reversible procedure in which an artificial lens is implanted into the anterior or posterior chamber of the eye in addition to the natural lens in order to correct very severe refractive errors.

**Refractive lens exchange**

is performed to correct presbyopia, high myopia, and hyperopia. The intraocular lens is implanted into the capsular sac of the eye after the natural lens is removed.

general, all refractive surgical techniques are held to be contraindicated for patients under age 18, or when a refractive error (other than presbyopia) is currently progressing in severity.

The excimer-laser techniques (LASEK, PRK, LASIK, epi-LASIK) are used for the correction of myopia up to -8 dpt (LASIK for myopia up to -10 dpt), hyperopia up to +4 dpt, and astigmatism up to 5 dpt.

These techniques are contraindicated in the presence of a symptomatic cataract, glaucoma with marked visual field damage, or exudative macular degeneration.

A preoperative corneal thickness of less than 500 microns is a further contraindication for the lamellar surgical procedures. In such cases, superficial procedures are preferred for the correction of refractive errors. Astigmatic keratotomy (AK) is used only in cases of very severe astigmatism (>3 dpt), while limbal relaxation incisions (LRI) are used to treat astigmatism of less than 2.5 dpt or an astigmatism that has developed in the aftermath of refractive (e.g., excimer) or cataract surgery (figure 7).

A PIOL can be implanted as long as the anterior chamber is at least 3.0 mm deep and the endothelial cell count is at least 2000 cells per square millimeter. If astigmatism (< 2 dpt) is present, this can also be treated at the time of PIOL implantation by suitably incising the steep meridian. When astigmatism of 2 dpt or more is present, a toric PIOL can be implanted to correct both the refractive error and the astigmatism. Now that more experience has been gained with the implantation of intraocular lenses, PIOL are beginning to be used for the correction of intermediately severe refractive errors (i.e., myopia of about -5 dpt or more) as an alternative to refractive corneal surgery.

Refractive lens exchange (RLE) is performed mainly in patients over 50 years of age with advanced presbyopia, and for the correction of marked myopia or hyperopia. Astigmatism, if present, can be corrected at the time of RLE (just as in PIOL) either by suitably incising the steep meridian or by the insertion of a toric implant.


## Results

### Refractive corneal surgery

Refractive surgery with excimer lasers has now been performed in man for more than 20 years. With modern lasers, the reliability of LASIK and superficial treatments within the indicated range is  $\pm 0.5$  dpt in 85% of cases and  $\pm 1.0$  dpt in 99%. The correction of larger refractive errors is less reliable than that of smaller ones,

### Contraindications for excimer laser techniques

- Symptomatic cataract
- Glaucoma
- Exudative macular degeneration
- Preoperative corneal pathology



Indications for refractive surgical techniques depending on the axially symmetrical refractive error (dark shading = ideal indication, lighter shading = possible indication); RLE, refractive lens exchange, IOL, intraocular lens, PRK, photorefractive keratotomy; modified from (6).

because of the greater degree of wound healing that takes place afterwards. This is true for both myopia and hyperopia, and especially for astigmatism.

The incisional techniques are among the older methods in refractive surgery. Astigmatic keratotomy is particularly suitable for the correction of high astigmatism after corneal transplantation; in this setting, however, just as in the primary correction of primary astigmatism, it is relatively imprecise in comparison to the other available techniques (excimer surgery, toric intraocular lenses). Its reliability can be increased with the use of the new femtosecond lasers. Limbal relaxation incisions are very effective at reducing astigmatism of up to 2.5 dpt, with a much better reliability than astigmatic keratotomy.

### Refractive lens surgery

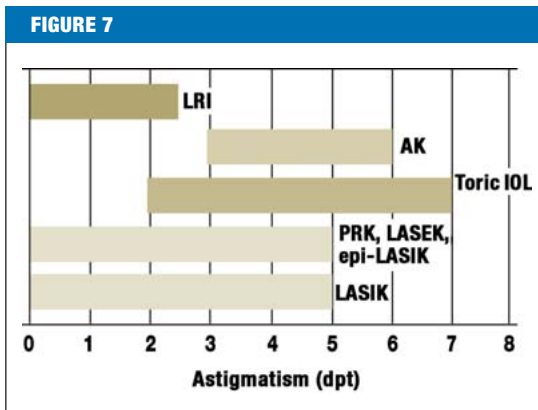
Phakic intraocular lenses have proven to be an effective, safe, reliable, and stable means of correcting higher refractive errors, especially myopia. The reliability of this procedure within the indicated range is  $\pm 0.5$  dpt in more than 70% of cases and  $\pm 1.0$  dpt in more than 90%. This procedure is often used to treat myopia of more than 15 dpt and its reliability here is not as good, both because of the difficulty of preoperative diagnosis and for other reasons. Nonetheless, even in such cases, the patient's vision generally improves, because there is no longer a need to wear high-myopic eyeglasses that reduce the size of the visual image.

The exchange of a normal human lens for an artificial lens is also an effective, safe, reliable, and stable means of correcting higher ametropias, and it can be used to treat presbyopia in addition if a multifocal artificial lens

### Refractive lens surgery

Phakic intraocular lenses have proven to be an effective, safe, reliable, and stable method of correcting high refractive errors, especially myopia.

Indications for refractive surgical techniques depending on the severity of astigmatism; LRI, limbal relaxation incision, AK, astigmatic keratotomy, IOL, intraocular lens, PRK, photorefractive keratotomy; modified from (6).



**BOX 2**

**Indications for refractive surgical techniques\*1**

**Superficial procedures (PRK, LASEK, epi-LASIK)**

Range of applicability

- Myopia up to -6 dpt
- Astigmatism up to 5 dpt

Borderline applicability

- Myopia up to -8 dpt
- Astigmatism up to 6 dpt
- Hyperopia up to +4 dpt

**LASIK**

Range of applicability

- Myopia up to -8dpt
- Astigmatism up to 5 dpt
- Hyperopia up to +3 dpt

Borderline applicability

- Myopia up to -10 dpt
- Astigmatism up to 6 dpt
- Hyperopia up to +4 dpt

**Phakic IOL**

Range of applicability

- Myopia of -8 dpt or more
- Hyperopia of +4 dpt or more

Borderline applicability

- Myopia of -5 dpt or more
- Hyperopia of +3 dpt or more

\*1 according to the guidelines of the German Commission for Refractive Surgery (Kommission Refraktive Chirurgie, KRC) (6).

is used. Its reliability within the indicated range is  $\pm 0.5$  dpt in more than 80% of cases.

**Further corrections**

In 5% to 10% of eyes that are operated upon, some degree of refractive error remains after refractive surgery, and this can be treated with another procedure. Because these residual refractive errors are small, they are usually treated with excimer surgery.

**Complications**

Although modern refractive surgery is remarkably successful, every refractive surgical procedure still carries a risk of complications. These can be held to a minimum by adherence to proper indication criteria and by the maintenance of high technical standards, including strictly sterile operative technique, in every procedure. Increasing experience of the operating surgeon also helps to prevent complications. Their overall frequency is less than 0.5%.

**Refractive corneal surgery**

The potential adverse effects of the surface treatments (PRK, LASEK, epi-LASEK) include superficial corneal scarring ("haze") in addition to longer-lasting refractive fluctuations and more difficult secondary procedures in comparison to LASIK (7). These complications have become very rare with the introduction of newer techniques; their frequency is now 0.5%.

A transiently dry eye is the most common complication after LASIK, arising after 15% to 20% of all treatments. Its cause is the transection of corneal nerves by the flap incision, which results in diminished secretion of the tear film and thus produces a neuroparalytic keratoconjunctivitis sicca (8, e7). In nearly 100% of cases, the eye becomes as moist as it was before surgery within six months after the procedure. Aside from dry eye, there have been very rare cases – about 0.05% – of keratectasia (protrusion of the cornea [9, 10]) or infection [8, 11]).

Keratectasia hardly ever occurs any more as a complication, for the following reasons:

- strict adherence to indication criteria,
- technical improvements in the incision apparatus,
- and increasing experience in the assessment and interpretation of the preoperative surface data (corneal topography) and higher-order corneal aberrations (aberrometry) (12).

The development of irregular astigmatism after

**Further corrections**

After 5% to 10% of procedures for refractive correction, there remains a residual refractive error that can be corrected with a further intervention.

**Complications**

A temporarily dry eye is a common complication of LASIK, with a frequency of 15% to 20%.

astigmatic keratotomy can nearly always be prevented by the use of a new technology, the femtosecond laser. In very rare cases (<0.05%), epithelial ingrowth into the incision may occur.

### Lens surgery

A recognized complication of phakic anterior chamber lenses is the loss of corneal endothelial cells because of the direct or indirect contact of the artificial lens with the corneal endothelium (innermost layer of the cornea). In practice, however, this complication arises only very rarely, as long as the indication criteria for phakic intraocular lens implantation are strictly respected, intraocular lenses of modern, improved design are used, and the patient is regularly followed up after surgery.

When an artificial lens is implanted into the posterior chamber, transient or permanent contact of the artificial lens with the natural lens of the eye in addition to the diminished supply of nutrients to the natural lens can lead to the development of an anterior subcapsular cataract in about 5% to 10% of patients in the first five years after the procedure (13).

Refractive lens exchange (RLE) may be followed, in the first few weeks after the procedure, by cystoid macular edema (swelling of the retina at the site of sharpest vision), causing a loss of visual acuity. The risk of retinal detachment after an RLE procedure is greatest when it is performed to correct high myopia; thus, RLE is recommended in highly myopic eyes only after vitreous detachment, which reduces the risk of retinal detachment. A few months or years after an RLE procedure, a regenerative or fibrotic "secondary cataract" (opacification behind the new artificial lens) may develop. This can be treated with YAG-laser capsulotomy without the need for surgically reopening the eye. Another recognized complication of RLE is worsened twilight vision, with halo perception and glare, after the implantation of multifocal intraocular lenses. Fortunately, the newly developed types of aspheric bifocal and multifocal lenses optimize image quality particularly well in poorly lit situations, e.g., automobile driving in twilight or in the dark, because they compensate for the spherical aberration of the cornea (14).

### Overview

Refractive errors can be corrected safely, effectively, reliably, and with only rare complications by the methods of refractive surgery (15–20, e8–e9). The optimal type of treatment is chosen individually for each patient

after an extensive presurgical work-up. Above all, LASIK with a femtosecond laser is currently the most advanced technique and is used in combination with modern aspheric and wavefront-guided ablation profiles to correct mild or moderately severe refractive errors (21). If the preoperative corneal thickness is less than 500 microns, superficial techniques (PRK, LASEK, or epi-LASIK) are preferred for the correction of refractive errors. With modern lasers, the reliability of LASIK and these superficial techniques when used within the indicated range is  $\pm 0.5$  dpt in 85% of cases and  $\pm 1.0$  dpt in 99%. When LASIK is contraindicated, and if the eye is still able to accommodate, moderately severe ametropias of  $-5$  dpt or more can be alternatively treated with phakic intraocular lenses. This form of treatment has been found to yield a long-lasting good refractive result in studies with up to 10 years of follow-up (22–24); its reliability within the indicated range is  $\pm 0.5$  dpt in over 70% of cases and  $\pm 1.0$  dpt in over 90%. For eyes that are no longer able to accommodate, refractive lens exchange with a newly developed type of multifocal lens is a promising method of treating both ametropias and presbyopia. Mild residual refractive errors that persist after a lens procedure can be corrected with excimer surgery.

### Conflict of interest statement

Professor Kohnen has received study support from Alcon Pharma GmbH, AMO Germany GmbH, Bausch & Lomb Surgical, Rayner Surgical GmbH, Schwind Eye-Tech-Solutions GmbH Co KG, and Carl Zeiss Meditech AG. Ms. Strenger and Mr. Klaproth state that they have no conflict of interest as defined by the guidelines of the International Committee of Medical Journal Editors.

Manuscript received on 13 June 2007; revised version accepted on 19 October 2007.

Translated from the original German by Ethan Taub, M.D.

### REFERENCES

1. Kohnen T: Kriterien zur Evaluierung und Publikation von refraktiv-chirurgischen Eingriffen (Editorial). *Klin Monatsbl Augenheilkd* 1999; 326–8.
2. Mrochen M, Seiler T: Grundlagen der wellenfrontgeführten refraktiven Hornhautchirurgie. *Ophthalmologie* 2001; 98: 703–14.
3. Mrochen M, Hafezi F, Jankov M, Seiler T: Ablationsprofile in der kornealen refraktiven Laserchirurgie. Gegenwärtige und zukünftige Konzepte. *Ophthalmologie* 2006; 103: 175–83.
4. Kohnen T, Bühren J, Kühne C, Mirshahi A: Wavefront-guided LASIK with the Zyoptix 3.1 system for the correction of myopia and compound myopic astigmatism with 1-year follow-up: clinical outcome and change in higher order aberrations. *Ophthalmology* 2004; 111: 2175–85.

### Complications of lens surgery

A cataract may develop within 5 years in about 5% of cases.

### Overview

Refractive errors can be corrected safely and with a low rate of complications with the methods of refractive surgery.

5. Kohnen T, Kühne C, Cichocki M, Strenger A: Zyklorotation des Auges bei wellenfrontgeführter LASIK mit statischem Iriskennungs-tracker. *Ophthalmologie* 2007; 104: 60–5.
6. Kohnen T, Knorz MC, Neuhann T: Bewertung und Qualitätssicherung refraktiv-chirurgischer Eingriffe durch die DOG und den BVA. *Ophthalmologie* 2007; 104: 719–26.
7. Kohnen T: Retreating residual refractive errors after excimer surgery of the cornea: PRK versus LASIK. *J Cataract Refract Surg* 2000; 26: 625–6.
8. Knorz MC: Komplikationen der Excimerlaser-Chirurgie zur Behandlung von Refraktionsfehlern. *Ophthalmologie* 2006; 103: 192–8.
9. Pallikaris IG, Kymionis GD, Astyrakakis NI: Corneal ectasia induced by laser in situ keratomileusis. *J Cataract Refract Surg* 2001; 27: 1796–802.
10. Randleman JB, Russell B, Ward MA, Thompson KP, Stulting RD: Risk factors and prognosis for corneal ectasia after LASIK. *Ophthalmology* 2003; 110: 267–75.
11. Moshirfar M, Welling JD, Feiz V, Holz H, Clinch TE: Infectious and noninfectious keratitis after laser in situ keratomileusis Occurrence, management, and visual outcomes. *J Cataract Refract Surg* 2007; 33: 474–83.
12. Bühren J, Kühne C, Kohnen T: Defining subclinical keratoconus using corneal first-surface higher-order aberrations. *Am J Ophthalmol* 2007; 143: 381–9.
13. Kohnen T: Cataract formation after implantation of myopic phakic posterior chamber IOLs. *J Cataract Refract Surg* 2004; 30: 2245–6.
14. Kasper T, Bühren J, Kohnen T: Intraindividual comparison of higher-order aberrations after implantation of aspherical and spherical intraocular lenses as a function of pupil diameter. *J Cataract Refract Surg* 2006; 32: 78–84.
15. Sekundo W, Bonicke K, Mattausch P, Wiegand W: Six-year follow-up of laser in situ keratomileusis for moderate and extreme myopia using a first-generation excimer laser and microkeratome. *J Cataract Refract Surg* 2003; 29: 1152–8.
16. Kohnen T, Meltendorf C, Cichocki M: Laser-in-situ-Keratomileusis mittels Scanning-Spot-Excimerablation zur Korrektur von Myopie und myopem Astigmatismus 3-Jahresergebnisse. *Ophthalmologie* 2005; 102: 363–8.
17. Jaycock PD, O'Brart DP, Rajan MS, Marshall J: 5-year follow-up of LASIK for hyperopia. *Ophthalmology* 2005; 112: 191–9.
18. Kohnen T, Kasper T, Terzi E: Intraokularlinsen zur Korrektur von Refraktionsfehlern. Teil II: Phake Hinterkammerlinsen und refraktiver Linsenaustausch mit Hinterkammerlinsenimplantation. *Ophthalmologie* 2005; 102: 1105–17.
19. Kohnen T, Baumeister M, Cichocki M: Intraokularlinsen zur Korrektur von Refraktionsfehlern. Teil I: Phake Vorderkammerlinsen. *Ophthalmologie* 2005; 102: 1003–7.
20. Kohnen T: Evaluation of new phakic intraocular lenses and materials. *J Cataract Refract Surg* 2007; 33: 1347.
21. Mrochen M, Donges A, Korn G: Femtosekundenlaser für die refraktive Hornhautchirurgie: Grundlagen, Wirkungsweise und klinische Anwendungen. *Ophthalmologie* 2006; 103: 1005–13.
22. Landesz MWJ, van Rij G: Long-term results of correction of high myopia with an iris claw phakic intraocular lens. *J Refract Surg* 2000; 16: 310–6.
23. Saxena R, Landesz M, Noordzij B, Luyten GP: Three-year follow-up of the Artisan phakic intraocular lens for hypermetropia. *Ophthalmology* 2003; 110: 1391–5.
24. Moshirfar M, Holz HA, Davis DK: Two-year follow-up of the Artisan/Verisyse iris-supported phakic intraocular lens for the correction of high myopia. *J Cataract Refract Surg* 2007; 33: 1392–7.

**Corresponding author**

Prof. Dr. med. Thomas Kohnen  
 Klinik für Augenheilkunde  
 Johann Wolfgang Goethe-Universität  
 Theodor-Stern-Kai 7  
 60590 Frankfurt am Main, Germany  
 Kohnen@em.uni-frankfurt.de



For a detailed description of the procedure please refer to:  
[www.aerzteblatt-international.de/cme/0803](http://www.aerzteblatt-international.de/cme/0803)

For e-references please see:  
[www.aerzteblatt-international.de/cme/ref0908](http://www.aerzteblatt-international.de/cme/ref0908)

**Further Information**

This article has been certified by the North Rhine Academy for Postgraduate and Continuing Medical Education.

Deutsches Ärzteblatt provides certified continuing medical education (CME) in accordance with the requirements of the Chambers of Physicians of the German federal states (Länder). CME points of the Chambers of Physicians can be acquired only through the Internet by the use of the German version of the CME questionnaire within 6 weeks of publication of the article. See the following website: [www.aerzteblatt.de/cme](http://www.aerzteblatt.de/cme)

Participants in the CME program can manage their CME points with their 15-digit "uniform CME number" (einheitliche Fortbildungsnummer, EFN). The EFN must be entered in the appropriate field in the [www.aerzteblatt.de](http://www.aerzteblatt.de) website under "meine Daten" ("my data"), or upon registration. The EFN appears on each participant's CME certificate.

The solutions to the following questions will be published in Volume 17/2008. The CME unit "Diagnosis and Management of Upper Gastrointestinal Bleeding" (Volume 5/2008) can be accessed until the 14th March. For volume 12/2008 we plan to offer the topic "Wounds – From Physiology to Wound Dressing".

**Solutions to the CME questionnaire in volume 1–2/2008:**

Hach-Wunderle V et al.: The Treatment of Deep Vein Thrombosis in the Pelvis and Leg: 1/a, 2/e, 3/b 4/b, 5/d, 6/d, 7/c, 8/b, 9/c, 10/d



Please answer the following questions to participate in our certified Continuing Medical Education program. Only one answer is possible per question. Please select the answer that is most appropriate.

**Question 1**

**Which refractive errors of the human eye are classified as lower-order aberrations?**

- a) Axially symmetric myopia and astigmatism
- b) Axially symmetric types, astigmatic types, and presbyopia
- c) Myopia and hyperopia
- d) Presbyopia and astigmatism
- e) Spherical aberrations and astigmatic refractive errors

**Question 2**

**The refractive apparatus of the eye consists of which of the following?**

- a) The iris, cornea, retina, and vitreous body
- b) The cornea, anterior chamber, lens, and vitreous body
- c) The ciliary muscle, cornea, iris, and posterior chamber
- d) The chamber angle, iris, vitreous body, and retina
- e) The retina, fundus of the eye, vitreous body, and cornea

**Question 3**

**In excimer laser surgery for the correction of refractive errors, what is the difference between superficial techniques (PRK, epi-LASIK, LASEK) and LASIK?**

- a) The superficial techniques, unlike LASIK, are used in deeper layers of the cornea after the surface is removed as a flap.
- b) The excimer laser techniques differ from one another in the type of excimer laser that is used.
- c) In the superficial techniques, corneal tissue is removed at a more superficial level, immediately under the corneal epithelium.
- d) The superficial techniques, unlike LASIK, are used exclusively to correct hyperopia.
- e) LASIK, in contrast to the superficial techniques, is also used if the preoperative thickness of the cornea is less than 500 microns.

**Question 4**

**Five patients with the following measured values (a–e) present for LASIK surgery. For which patient is LASIK contraindicated?**

- a) Preoperative corneal thickness >500 microns, astigmatism 2.0 dpt, myopia –4 dpt.
- b) Preoperative corneal thickness >500 microns, astigmatism 3.0 dpt, hyperopia +2 dpt.
- c) Preoperative corneal thickness >500 microns, myopia –8 dpt, astigmatism 0 dpt.
- d) Preoperative corneal thickness <500 microns, myopia –5 dpt, astigmatism 1.0 dpt.
- e) Preoperative corneal thickness >500 microns, myopia 0.0 dpt, astigmatism 4.0 dpt.

**Question 5**

**What is the most common complication of LASIK about which the patient must be informed before the procedure?**

- a) Corneal erosion
- b) Posterior synechia
- c) Keratectasia
- d) Photoelectric keratitis
- e) Dry eye

**Question 6**

**Where in the eye can phakic intraocular lenses be implanted?**

- a) Cornea, vitreous body, iris
- b) Cornea, iris, posterior chamber
- c) Chamber angle, iris, posterior chamber
- d) Chamber angle, iris, vitreous body
- e) Anterior chamber, vitreous body, posterior chamber

**Question 7**

**A patient with myopia of –10 diopters and presbyopia of 3 diopters would like to have a phakic intraocular lens implanted. What are the minimal anatomical and histological prerequisites for this to be done?**

- a) Anterior chamber depth >2.0mm, more than 1000 endothelial cells/mm<sup>2</sup>.
- b) Anterior chamber depth >3.0mm, more than 2000 endothelial cells/mm<sup>2</sup>.
- c) Anterior chamber depth >4.0mm, more than 3000 endothelial cells/mm<sup>2</sup>.
- d) Anterior chamber depth >5.0mm, more than 5000 endothelial cells/mm<sup>2</sup>.
- e) Anterior chamber depth >6.0mm, more than 7000 endothelial cells/mm<sup>2</sup>.

**Question 8**

**Your patient has read that multifocal intraocular lenses are better than monofocal intraocular ones and would like to know why. What do you say in response?**

- a) Multifocal intraocular lenses have a smaller diameter and can be implanted more easily than monofocal intraocular lenses.
- b) Fewer preoperative tests are needed before a multifocal intraocular lens can be implanted.
- c) When a multifocal intraocular lens is implanted, the patient can see sharply both near and far, without having to wear reading spectacles in addition.
- d) Monofocal intraocular lenses can remain in the eye longer than multifocal ones, which must be exchanged every five years.
- e) Multifocal intraocular lenses can also be implanted in older patients (from age 50 onward), but monofocal intraocular lenses cannot.

**Question 9**

**Which of the following is a correct statement about the difference between the use of phakic intraocular lens implantation and that of refractive lens exchange?**

- a) Phakic intraocular lenses are implanted in addition to the natural lens of the eye, while in refractive lens exchange the natural lens is replaced with an artificial one.
- b) Phakic lenses are implanted to correct low myopia or hyperopia, while refractive lens exchange is performed to correct high myopia or hyperopia.
- c) Phakic intraocular lens implantation and refractive lens exchange differ in the severity of the refractive error that is to be corrected.
- d) These two techniques differ in the material that the artificial intraocular lens is made of.
- e) The difference has to do with the correction of astigmatism: phakic intraocular lenses can be used to correct astigmatism, while refractive lens exchange cannot.

**Question 10**

**A patient with an astigmatism of 6.5 diopters would like to have her refractive error corrected. Which of the following techniques would be appropriate for her?**

- a) No refractive methods are available to correct her astigmatism.
- b) With this magnitude of astigmatism (6.5 dpt), astigmatic keratotomy and the implantation of toric intraocular lenses are the methods of choice.
- c) To correct this degree of astigmatism, a refractive lens exchange must be performed and the patient must then wear glasses for far vision.
- d) This degree of astigmatism can be corrected with eyeglasses, contact lenses, or a limbal relaxation incision.
- e) This degree of astigmatism can be corrected with photorefractive keratotomy and LASEK.

## CONTINUING MEDICAL EDUCATION

# Basic Knowledge of Refractive Surgery

Correction of Refractive Errors Using Modern Surgical Procedures

Thomas Kohnen, Anja Strenger, Oliver K. Klaproth

**E-REFERENCES**

- e1. Koch DD, Kohnen T, Obstbaum SA, Rosen ES: Format for reporting refractive surgical data. *J Cataract Refract Surg* 1998; 24: 285–7.
- e2. Seiler T, Genth U: Zum gegenwärtigen Stand der chirurgischen Myopiekorrektur. *Dtsch Arztebl* 1994; 91(48): A 3344–50.
- e3. Giessler S, Duncker GI: Short-term visual rehabilitation after LASIK. *Graefes Arch Clin Exp Ophthalmol* 2001; 239: 603–8.
- e4. Kohnen T: Classification of excimer laser profiles. *J Cataract Refract Surg* 2006; 32: 543–4.
- e5. Kohnen T, Bühen J: Derzeitiger Stand der wellenfrontgeführten Hornhautchirurgie zur Korrektur von Refraktionsfehlern. *Ophthalmologie* 2004; 101: 631–45.
- e6. Kohnen T: Optimierung der refraktiven Hornhautchirurgie. *Ophthalmologie* 2006; 103: 173–4.
- e7. Lee SJ, Kim JK, Seo KY, Kim EK, Lee HK: Comparison of corneal nerve regeneration and sensitivity between LASIK and laser epithelial keratomileusis (LASEK). *Am J Ophthalmol* 2006; 141: 1009–15.
- e8. O'Brart DP, Patsoura E, Jaycock P, Rajan M, Marshall J: Excimer laser photorefractive keratectomy for hyperopia: 7.5-year follow-up. *J Cataract Refract Surg* 2005; 31: 1104–13.
- e9. Tahzib NG, Nuijts RM, Wu WY, Budo CJ: Long-term study of Artisan phakic intraocular lens implantation for the correction of moderate to high myopia: ten-year follow-up results. *Ophthalmology* 2007; 114: 1133–42.
- e10. Wang L, Swami A, Koch DD: Peripheral corneal relaxing incisions after excimer laser refractive surgery. *J Cataract Refract Surg* 2004; 30: 1038–44.