

REVIEW ARTICLE

Posterior Tarsal Tunnel Syndrome

Diagnosis and Treatment

Gregor Antoniadis, Konrad Scheglmann

SUMMARY

Background: Posterior tarsal tunnel syndrome is an uncommon clinical entity which is sometimes misdiagnosed in patients with pain of the retromalleolar region and the plantar aspect of the foot. Surgical intervention is recommended for correctly diagnosed posterior tarsal tunnel syndrome.

Methods: Selective literature review.

Results: Surgical treatment is indicated in the presence of dysesthesias refractory to conservative treatment or of neurological deficits. If a neural tumor or tarsal tunnel ganglion is suspected, diagnostic imaging (MRI, neurosonography) should precede surgery. Division of the flexor retinaculum (ligamentum laciniatum) in the tarsal tunnel must always include distal decompression of the end branches of the tibial nerve posterior to the fascia of the abductor hallucis muscle. Only extensive exposure of the nerve guarantees adequate release.

Conclusion: Accurate diagnosis requires the evaluation of relevant clinical, neurological, and neurophysiological findings along with the careful consideration of other possible diagnoses. High success rates of 44% to 91% are reported after operative treatment. The results are better in idiopathic than in posttraumatic cases. If surgery fails, re-operation is indicated only in patients with inadequate release.

Dtsch Arztebl Int 2008; 105(45): 776–81

DOI: 10.3238/arztebl.2008.0776

Key words: compression syndrome, tibial nerve, diagnosis, treatment concept, nerve lesion

Carpal and cubital tunnel syndromes are among the more common peripheral nerve compression syndromes. Posterior tarsal tunnel syndrome is relatively uncommon, though the literature contains no precise estimate of its prevalence. In our experience, it is diagnosed too often. Posterior tarsal tunnel syndrome involves damage to the tibial nerve where it lies under the flexor retinaculum (lacinate ligament) on the medial side of the ankle. It is to be distinguished from anterior tarsal syndrome, in which the deep peroneal nerve is compressed under the extensor retinaculum on the dorsum of the foot. Pollock and Davis described posttraumatic compression of the tibial nerve as early as 1933 (1). In 1960, Kopell and Thompson described the clinical manifestations of tarsal tunnel syndrome (2). Keck coined the expression "tarsal tunnel syndrome" in his case report of 1962 (3). Keck thought that the condition was underdiagnosed and frequently misdiagnosed as plantar fasciitis.

Keck and Lam independently recommended considering this type of compression syndrome in the differential diagnosis whenever a patient complains of pain and paresthesia in the sole of the foot (3, 4).

In this article, we will present the current state of the diagnostic assessment of posterior tarsal tunnel syndrome and its treatment on the basis of a selective review of the literature and our own extensive experience.

Anatomy

At the level of the thigh, the tibial nerve is the medial component of the sciatic nerve. The tibial nerve comes to the surface at the level of the medial side of the ankle. Together with the posterior tibial artery and vein, it enters the tarsal tunnel between the medial malleolus and the Achilles tendon.

This tunnel is an osteofibrous canal covered by the flexor retinaculum, which extends like a fan from the medial malleolus to the transverse septa of the crural fascia. The distal portion of this ligament is stronger than its proximal portion.

Usually, the tibial nerve divides within the tarsal tunnel into its terminal branches, the medial and lateral plantar nerves. These run below the fascia of the abductor hallucis muscle into two further tunnels that are located on the medial side of the foot.

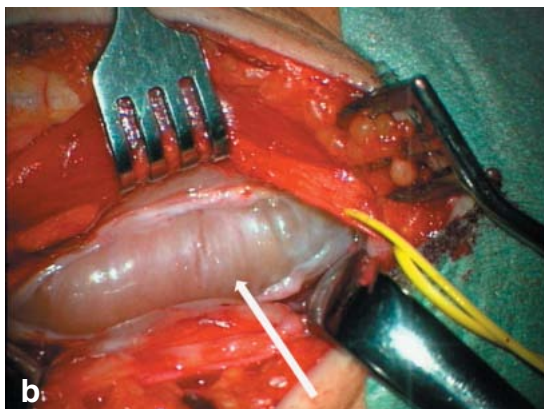
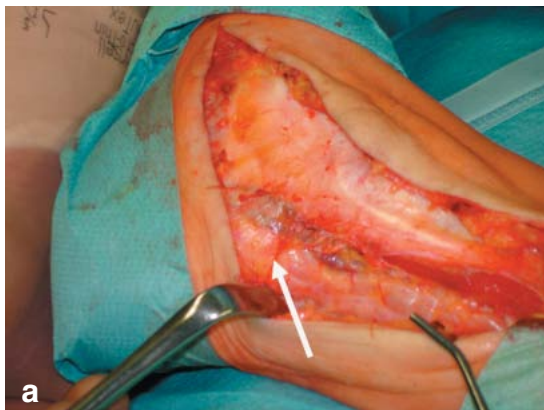
These branches supply sensory innervation to the plantar forefoot as far as the toes and motor innervation to the muscles of the sole of the foot, particularly the toe flexors.

Neurochirurgische Klinik der Universität Ulm, Bezirkskrankenhaus Günzburg: Prof. Dr. med. Antoniadis

Neurologische Klinik mit Klinischer Neurophysiologie Klinikum Augsburg: Dr. med. Scheglmann

Figure 1:

(a) A woman with type 2 neurofibromatosis and a plexiform neurofibroma of the tibial nerve in the posterior tarsal tunnel. Partial division of the flexor ligament (arrow)
 (b) Tibial nerve release by complete splitting of the flexor retinaculum (arrow) prior to tumor resection.



Clinical features

The initial and most characteristic manifestation of tarsal tunnel syndrome (TTS) is irritation of the peripheral nerve, i.e., paresthesia or burning sensation in the territory of the distal branches of the tibial nerve. These medial and lateral plantar nerves, and also the calcaneal branch, which supplies sensory innervation to the heel, may be affected in isolation. If only one plantar nerve is affected, the problem is a so-called distal tarsal tunnel syndrome.

Protracted walking or standing often exacerbates the symptoms. Dysesthesia arising during the night can also disturb the patient's sleep. Pressure over the course of the nerve on the medial side of the ankle is said to be painful in 60% to 100% of the affected patients and to intensify the paresthesia. A Hoffmann-Tinel sign (electrical paresthesia on percussion of the nerve) can be elicited in more than half of the affected patients. The symptoms can also be exacerbated by forced eversion and dorsiflexion of the foot. Rarely, the pain radiates into the thigh as well. If the clinical picture is dominated by the pain of nerve irritation without any consistently detectable neurological deficit, one may speak of the "algetic form" of tarsal tunnel syndrome.

With increasing degrees of damage to the nerve, consistently detectable neurological deficits are produced beyond the subjective irritative phenomena. The demonstrable sensory loss must be restricted to the territory of the affected nerves. Weakness is a late phenomenon, appearing first in the toe abductors and afterward

BOX

Differential diagnosis

- Polyneuropathy
- L5 and S1 nerve root syndromes
- Morton's metatarsalgia
- Compartment syndrome of the deep flexor compartment
- Calcaneal spur, arthrosis, inflammatory changes of the fasciae and ligaments
- Ischemia

also in the short toe flexors; muscle atrophy is seen last. Trophic disturbances such as diminished sweating are also a late manifestation (5, 6).

Pecina and coauthors have described a compression syndrome of the medial plantar nerve ("jogger's foot") that arises in middle-aged joggers and is characterized by stabbing pain in the medial sole on walking (7).

Pathogenesis

The cause of TTS is nerve compression in the tarsal tunnel. This can arise on an idiopathic or posttraumatic basis; it can also be produced by a mass lesion.

Patients often (17% to 43%) have a prior history of trauma, e.g., fractures near the ankle or ankle sprains with medial ligamentous injuries. Arthrosis, tenosynovitis, and rheumatoid arthritis are also said to cause as many as 10% of all cases. Tumors such as tibial nerve schwannoma at the level of the tarsal tunnel (*figures 1a and 1b*) are rare, as are ganglia (up to 8%); convoluted vessels have been described somewhat more frequently (up to 17%) (8).

Hypertrophic or accessory muscles (e.g., the abductor hallucis) and tendons (e.g., the flexor digitorum longus tendon) may impinge on the tarsal tunnel and compress the nerve.

Diabetes mellitus, hypothyroidism, gout, mucopolysaccharidoses, and (very rarely) hyperlipidemia have also been described as precipitating causes (5, 6, 8).

Acute tarsal tunnel syndrome is often encountered after marathon races as an acute effect of unusual mechanical stress.

In recent years, we have observed an increasing number of cases of nerve compression arising after surgical procedures because of local swelling, as well as iatrogenic injuries of the tibial nerve and its branches.

Differential diagnosis

Paresthesia of the forefoot is a very common symptom that usually appears bilaterally as the result of polyneuropathy. The possibility of ischemia must also be considered. Proximally located nerve lesions, such as radiculopathy or plexopathy, should also be included in the differential diagnosis, though they are usually easy to distinguish from peripheral nerve lesions on the basis of

the reflex findings and the distribution of sensory and motor deficits.

It is also possible to overlook a compartment syndrome of the deep flexor compartment, in which the tibial nerve runs next to the toe flexors. This can produce the clinical manifestations of a distal tibial nerve lesion.

The pain that arises after walking a certain distance in lumbar spinal stenosis ("neurogenic intermittent claudication") is usually bilateral, unlike the pain of tarsal tunnel syndrome.

The typical lancinating, shock-like pain of Morton's metatarsalgia between the third and fourth toes arises on mechanical stress and compression of the vault of the foot and is thus distinct from the continual burning dysesthesia of the sole that is found in tarsal tunnel syndrome.

Further elements of the differential diagnosis of pain in the foot are calcaneal spurs, arthrosis of the joints of the foot, and inflammatory conditions of the ligaments and fasciae, but these problems do not produce pain of a characteristically neuropathic type.

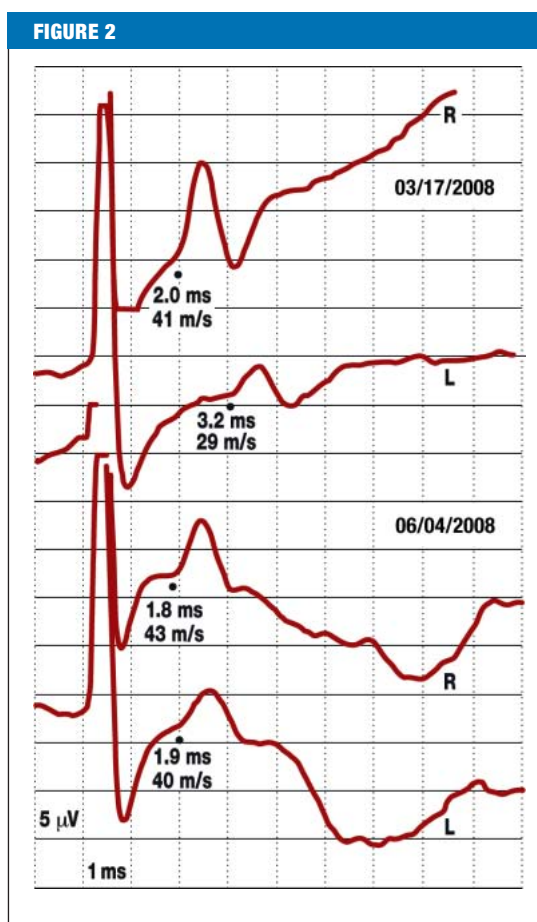
Plain films and, sometimes, magnetic resonance imaging or neurosonography may be of further assistance if a tumor in the tarsal tunnel is suspected and are sometimes crucial for further treatment planning (box).

Neurophysiological testing

The presence of an isolated tibial nerve lesion in the tarsal tunnel is confirmed by measurement of the sensory and motor nerve conduction velocity (NCV).

The most sensitive method, which is also the most technically demanding, is measurement of the sensory conduction velocity of the medial and lateral plantar nerves. This is best done by recording from the tibial nerve just above the flexor retinaculum and stimulating the nerves at the vault of the foot. When surface electrodes are used, the responses to stimulation are of low amplitude and not always measurable in the presence of ankle edema, sometimes not even on the healthy side. If necessary, recordings can be performed through needle electrodes. A number of authors advocate stimulating the first and fifth toes with ring electrodes. Although this is, theoretically, a very attractive method, it is difficult to apply successfully in practice because the responses to stimulation are of even lower amplitude. Polyneuropathies are not uncommon in advanced age, and the progressively smaller nerve action potentials of old age are difficult to assess with the use of inter-individual normed values; thus, recordings should, as a rule, be performed bilaterally so that the two sides can be compared (9, 10). The determinative findings are: significant differences between the NCVs in the affected segment on the two sides of the body, and significant differences in amplitude (i.e., a more than 50% difference between the two sides) in measurements made with surface electrodes. Additional measurements on unaffected nerves should also be obtained and compared.

Measurement of the motor NCV through recording of the distal motor latency at the abductor hallucis brevis muscle is a much easier, but less sensitive method. The



A 42-year-old woman with an electrographically confirmed diagnosis of left tarsal tunnel syndrome. Sensory neurography of the medial plantar nerve bilaterally reveals a decreased nerve conduction velocity on the left that renormalized after surgical treatment in parallel with clinical improvement

positive findings to be sought are prolonged distal motor latencies and low-amplitude summed motor potentials. Sometimes a conduction block can be demonstrated with stimulation proximal and distal to the flexor retinaculum. Significant differences between the two sides should be sought in motor neurography, just as in sensory neurography (figure 2).

The important finding on electromyography (EMG) is the demonstration of axonal injury when the EMG is recorded from the distal muscles supplied by the tibial nerve. Even in healthy individuals, however, fibrillations and positive waves are not uncommonly found in these muscles, as has been reported in the literature. It follows that this finding, too, can only be considered positive when there is a significant difference between the two sides.

Conservative treatment

Conservative measures consist of putting the distal part of the lower limb at rest. Local anesthetic or corticosteroid infiltrations are recommended mainly to treat the "algetic form" of tarsal tunnel syndrome. Injections of corticosteroids into the tarsal tunnel should be performed with utmost caution, however, and the authors advise against multiple injections because of their increased risk and no more than moderate chances of success.

Figure 3:
Long incision behind the lateral medial malleolus of the right foot

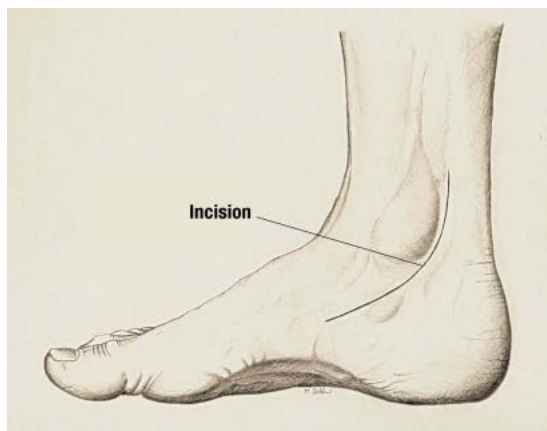


Illustration: Markus Schöni (with kind permission)

Figure 4:
After splitting of the tunnel proximally and distally, the tibial nerve and its plantar branches are decompressed

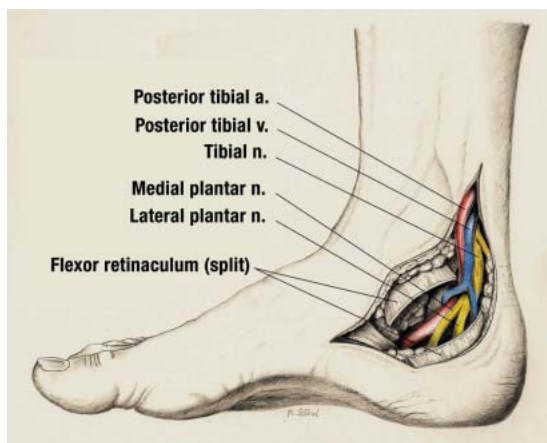


Illustration: Markus Schöni (with kind permission)

When there is an underlying condition, such as rheumatoid arthritis or hypothyroidism, treating this condition is, of course, an important component of therapy.

No evidence-based data on conservative treatment are yet available in the literature.

Shoe inserts are often recommended, but these are said to worsen the symptoms in many cases. If there is any deformity of the foot, orthopedic treatment is necessary.

Surgical techniques

Tarsal tunnel syndrome, in our opinion, is diagnosed too frequently, and thus the indications for operative treatment should always be assessed critically. If conservative treatment fails in a patient with well-documented tarsal tunnel syndrome and severe pain, surgery will be indicated sooner than in a patient with only moderate pain. In such cases, conservative treatment can be attempted for up to six months.

Electrophysiological testing may be of great help in establishing the diagnosis and in deciding whether to decompress the tibial nerve surgically.

The operation consists of decompression of the tibial nerve and its branches over a long segment of their course,

from the lower third of the calf down to deep within the distal medial portion of the foot (figure 3). The skin incision is gently curved. The flexor retinaculum may be very broad and must be split in its entire breadth (figure 4). The calcaneal branches must be preserved; their sites of origin are highly variable.

The medial and lateral plantar nerves must also be decompressed over a long segment of their course. They run in two separate tunnels beneath the abductor hallucis muscle and its fascia. Isolated compressions may be present at this location as well. Therefore, in the surgical treatment of tarsal tunnel syndrome, the fascia of the abductor hallucis muscle must be split and the two terminal branches must be spared in the distal tunnels (5).

The operation can be performed under local, epidural, spinal, or general anesthesia with a tourniquet applied to the lower limb. An operative microscope is generally not necessary except in reoperations or when the lesion to be operated on is of traumatic or iatrogenic origin.

Endoscopic techniques for the decompression of the tibial nerve and its branches can be used with just as good results as open decompression (11).

Postoperatively, the leg should be kept raised. Mobilization should ensue in the first two weeks with the aid of crutches to take the weight off the foot that has been operated on. The sutures must remain in place for 10 to 12 days.

Complications

New neurological deficits can arise as a complication in patients with any type of neuropathy, which makes the nerves particularly vulnerable. Complex regional pain syndrome (CRPS) is a rare sequela of surgery; lesions of the calcaneal branches can produce causalgia in the heel.

Postoperative complications include impaired wound healing, infection, and keloid formation (12).

If the patient's symptoms persist and the neurological deficits remain unchanged, then the diagnosis may need to be re-evaluated neurologically, or else the possibility that the tibial nerve and its branches have not been decompressed over a segment of sufficient length may need to be considered. Multiple operations can produce severe iatrogenic complications.

Discussion

Owing to the lack of controlled clinical studies of this rare condition, the most informative statements that can be made about its treatment are of an intermediate evidence level, based on numerous case series involving as many as 122 patients (13).

After many years of experience in our respective hospitals, and in the light of discussions with many professional colleagues, we are convinced that tarsal tunnel syndrome is too commonly diagnosed. Insufficient attention is often paid to the differential diagnosis of pain in the foot, and the electrophysiological diagnostic assessment is often imprecise. Misdiagnoses can be avoided only through detailed clinical and electro-

physiological examination and through an adequate knowledge of the relevant anatomy. If these preconditions are fulfilled, then the required treatment—usually surgical—is likely to meet with success.

According to published data, TTS is idiopathic in 20% of cases, symptomatic in the remaining 80% (13, 14). In 81% of cases, it can be diagnosed on the basis of the history and the clinical and electrophysiological findings (15).

Any proposed treatment of TTS should be judged in the light of its etiology and pathogenesis in the individual case.

Conservative measures have not had any significant degree of success in the management of TTS due to mass lesions (13, 16, 17). In the report of Cimino, only 16% of patients were treated conservatively. Foot-supporting accessories (shoe inserts) were a successful treatment only 34% of the time, and only in patients with flexible deformities (13).

In most articles on the subject, surgical treatment is recommended (15). Multiple retrospective clinical studies of surgical nerve decompression have been published to date, with reported success rates ranging from 75% to 91% (13, 15, 16, 18, 19).

Sammarco and Chang found that patients with symptoms of less than 1 year's duration had significantly better outcomes after surgery than patients with a longer history (20).

Turan and coauthors reported the achievement of complete relief of symptoms in 11 (61%) of their 18 patients, improvement in 4 (22%), and no improvement in 3 (17%) (19). Only 12 (50%) of the 24 patients treated by Linscheid and coauthors had any improvement (21).

Pfeiffer and Gracchiolo cast doubt on the long-term effectiveness of the operation (16). They reported good or excellent results in only 44% of their 30 patients. The discrepancy between this figure and the higher figures reported in other series can be explained by the fact that these authors followed their patients up for at least 24 months (mean, 31 months), much longer than many of the other authors. In consequence, Pfeiffer and Gracchiolo no longer offer surgical treatment to patients in whom a lesion in the tarsal tunnel has not been clinically demonstrated.

Herbsthofer and coauthors reported that they observed progressive improvement of symptoms up to the sixth month after surgery, which they attributed to reparative remodeling and to the resolution of the inflammation and edema accompanying tarsal tunnel syndrome (22).

Factors associated with poor results include advanced age, chronic symptoms with motor deficits, epineural scarring of the tibial nerve, idiopathic cases, and inadequate splitting of the tarsal tunnel (23). Patients performing intense manual labor and those with recurrent tarsal tunnel syndrome have worse outcomes (15).

Skalley and coauthors reported that the indication for reoperation in patients with TTS should always be viewed highly critically (18). Zeiss and coauthors recommend magnetic resonance imaging (MRI) of the affected region before any reoperation is performed, as this may enable

Key messages

- Posterior tarsal tunnel syndrome is a rare compression syndrome of the distal portion of the tibial nerve.
- The diagnostic criteria for posterior tarsal tunnel syndrome are:
 - Paresthesia and burning dysesthesia in the territory of the tibial nerve
 - Exacerbation of symptoms on walking and standing
 - Sensory loss and weakness of the toe abductors and short toe flexors
 - Neurophysiological confirmation of a distal tibial nerve lesion
- Surgical treatment is indicated if the symptoms are intractable and the diagnosis is well established.

detection of the underlying cause (24). Reoperation can succeed only if the nerves were not completely decompressed in the initial operation (15).

Goldring and coauthors studied 60 patients who underwent a total of 68 operations. Data were collected on these patients' subjective and objective manifestations of tarsal tunnel syndrome. Although the objective manifestations improved in 85% of patients, only 51% stated that they were free of symptoms (25).

In our experience, the results of surgery are very good in cases where the syndrome is due to the presence of a mass lesion in the tarsal tunnel. If a mass lesion or local compression cannot be demonstrated, the option of surgical treatment should be considered with great care. If the first operation does not go well, the diagnosis should be reassessed before a reoperation is contemplated. Any reoperation that is then done should be performed, if possible, by an experienced peripheral nerve surgeon.

This article is dedicated to Professor Dr. med. Hans-Peter Richter in celebration of his 65th birthday.

Conflict of interest statement

The authors declare that they have no conflict of interest as defined by the guidelines of the International Committee of Medical Journal Editors.

Manuscript submitted on 11 January 2008, revised version accepted on 10 July 2008.

Translated from the original German by Ethan Taub, M.D.

REFERENCES

1. Pollock L, Davis L: Peripheral nerve injuries. *Am J Surg* 1932; 18: 361.
2. Koppel HP, Thompson WA: Peripheral entrapment neuropathies of the lower extremity. *N Engl J Med* 1960; 262: 56–60.
3. Keck C: The tarsal-tunnel syndrome. *J. Bone Joint Surg* 1962, 44A: 180–2.
4. Lam SJS: A tarsal-tunnel syndrome. *Lancet* 1962; 2: 1354–5.
5. Mumenthaler M, Stöhr M, Müller-Vahl (eds.): *Läsion peripherer Nerven und radikuläre Syndrome*. Stuttgart: Thieme Verlag 2003.
6. Tackmann W, Richter HP, Stöhr M (eds.): *Kompressions Syndrome peripherer Nerven*. Heidelberg: Springer Verlag 1989.

7. Pecina MM, Krmpotic-Nemanic J, Markiewitz AD: Tunnel Syndromes – Peripheral Nerve Compression Syndromes. CRC Press Boca Raton, Florida 2001; 267–74.
8. Oh S, Meyer R: Entrapment neuropathies of the tibial nerve. *Neurologic Clinic* 1999; Volume 17, 593–615.
9. Oh SJ, Sarala PK, Kuba T et al.: Tarsal tunnel syndrome: Electrophysiological study. *Ann Neurol* 5: 327–30.
10. Stöhr M (ed.): *Klinische Elektromyographie und Neurographie – Lehrbuch und Atlas*. Stuttgart: Kohlhammer Verlag, Stuttgart 2005.
11. Krishnan KG, Pinzer T, Schackert G: A novel endoscopic technique in treating single nerve entrapment syndromes with special attention to ulnar nerve transposition and tarsal tunnel release: Clinical application. *Neurosurgery* 2006; 59: 89–100.
12. Reade BM, Longo DC, Keller NC: Tarsal Tunnel Syndrome. *Clinics in podiatric medicine and surgery*, Volume 18 2001; 395–408.
13. Cimino WR: Tarsal tunnel syndrome: a review of the literature. *Foot Ankle Int* 1990; 11: 47–52.
14. Frey C, Kerr R: Magnetic resonance imaging and the evaluation of tarsal tunnel syndrome. *Foot Ankle Int* 1993; 14: 159–64.
15. Ballie DS, Kelinkian AS: Tarsal tunnel syndrome: Diagnosis, surgical technique, and functional outcome. *Foot Ankle Int* 1998; 19: 65–72.
16. Pfeiffer WH, Gracchiolo A: Clinical results after tarsal tunnel decompression. *J Bone Joint Surg* 1994; 76A: 1222–30.
17. Takakura Y, Kitada C, Sugimoto K, Tanaka Y, Tamal S: Tarsal tunnel syndrome. *J Bone Joint Surg* 1991; 73B: 125–8.
18. Skalley TC, Schon LC, Hinton RY, Myerson MS: Clinical results following revision tibial nerve release. *Foot Ankle Int* 1994; 15: 360–7.
19. Turan I, Rivero-Melina C, Guntner P, Rolf C: Tarsal tunnel syndrome – Outcome of surgery in longstanding cases. *Clin Orthopaedics and related research* 1997; 343: 151–8.
20. Sammarco GJ, Chang L J: Outcome of surgical treatment of tarsal tunnel syndrome. *Foot Ankle Int* 2003; 24: 125–31.
21. Linscheid RL, Burton RC, Fredericks EJ: Tarsal tunnel syndrome. *South Med J* 1970; 63: 1313–23.
22. Herbsthofer B, Vogt T, Karbowski A, Krishek O: Diagnostik und Langzeitergebnisse nach operativer Therapie des Tarsaltunnelsyndroms. *Z Orthop* 1998; 136: 77–82.
23. Lau J, Daniels T: The effects of tarsal tunnel release and stabilization procedures on tibial nerve tension in a surgically created pes planus foot. *Foot Ankle Int* 1998; 19: 770–7.
24. Zeiss J, Fenton P, Ebraheim N, Coombs RJ: Magnetic resonance imaging for ineffectual tarsal tunnel surgical treatment. *Clin Orthop* 1991; 264: 264–6.
25. Goldring WH, Shields B, Wenger S: An outcome analysis of surgical treatment of tarsal tunnel syndrome. *Foot Ankle Int* 2003; 24: 545–50.

Corresponding author
 Prof. Dr. med. Gregor Antoniadis
 Neurochirurgische Klinik der Universität Ulm
 Bezirkskrankenhaus Günzburg
 Ludwig-Heilmeyer-Str. 2
 89312 Günzburg, Germany
 gregor.antoniadis@uni-ulm.de