

Serratia marcescens Meningitis

GIGI THECCANAT, LARRY HIRSCHFIELD,* AND HENRY ISENBERG

Long Island Jewish Medical Center, New Hyde Park Campus,
Albert Einstein College of Medicine, New Hyde Park,
New York 11042

Received 24 September 1990/Accepted 14 January 1991

A case of *Serratia marcescens* meningitis in a 66-year-old man is reported. The infection occurred 4 weeks after apparently successful otic surgery, and a nidus of infection in the middle ear was established at autopsy. This is the second case of *S. marcescens* meningitis following ear surgery reported in the English-language literature.

A 66-year-old male was admitted to Long Island Jewish Medical Center in August 1988 with complaints of severe headache, backache, and loss of orientation of 24-h duration. One month before this admission, he had surgery performed on his right ear and was well and ambulatory thereafter. After admission, a lumbar puncture was performed, and the cerebrospinal fluid showed a leukocyte count of 5,184/ml with 98% neutrophils. The initial Gram stain of the cerebrospinal fluid read in the emergency room was interpreted as positive for gram-positive diplococci. The patient's hemoglobin level was 11 g/dl, his erythrocyte count was $4.35 \times 10^6/\text{mm}^3$, and his leukocyte count was $6.8 \times 10^3/\text{mm}^3$. The differential count showed 84% neutrophils, 13% lymphocytes, and 3% monocytes. A computerized tomography scan of the patient's head was negative for a space-occupying lesion or hematoma. On the following day, the microbiology laboratory performed a cerebrospinal fluid smear that revealed numerous polymorphonuclear leukocytes and gram-negative rods. Cerebrospinal fluid and blood cultures were positive for *Serratia marcescens*.

The patient had a temperature of 100°F (ca. 37.8°C) with neck stiffness and was agitated and unresponsive. The tympanic membranes were clear bilaterally. Ampicillin and penicillin were administered initially and were subsequently replaced by nafcillin and ceftazidime after reports on cultures were received. One day after admission, the patient became increasingly agitated and unresponsive to verbal stimuli. He later developed cardiac arrest and died 30 h following admission. At autopsy, the leptomeninges were covered with a purulent exudate. Similar material was present over the convexities of both cerebral hemispheres, the interpeduncular fossa, and the base of the brain. The ventricular system, including the lateral, fourth, and third ventricles, likewise contained the purulent exudate. Microscopic examination revealed the exudate to have a varied appearance ranging from purely polymorphonuclear to a mixed infiltrate containing, in addition, lymphocytes and monocytes (Fig. 1). No penetration into the cerebral substance or along Virchow-Robin spaces over the convexities was noted. The dura was completely stripped off, and cultures were taken from the middle ear by aseptic techniques. This was approached via the

tegmen tympani of the petrous bone, which forms the roof of the middle ear. Postmortem cultures taken from the middle ear and meninges were positive for *S. marcescens*.

In the laboratory, *S. marcescens* was identified by its production of catalase and glucose fermentation with production of gas. Nitratase was present, and oxidase was absent. The isolates produced extracellular DNase, gelatinase at 22°C, and lipase and were resistant to colistin and cephalothin. The most common *Serratia* sp. isolated in the hospital setting is *S. marcescens*. This species and all isolates from this patient can be and were distinguished from other members of the genus by their inability to ferment L-arabinose and their production of prodigiosin, a water-insoluble red compound.

S. marcescens infection occurs as an opportunistic infection, typically in granulocytopenic patients and those who are immunosuppressed by disease or therapy. It may also colonize or complicate surgical and traumatic wounds. Most of the reported cases of meningitis due to *S. marcescens* have been in neonates and infants. Christensen et al. (1) reported an outbreak of sepsis, meningitis, and pneumonia due to *S. marcescens* in 15 neonates in a neonatal intensive care unit. Epidemiologic investigation failed to reveal a common source for the infection, with *S. marcescens* having been isolated from an employee's hand, a suction tube, and a resuscitation bag. Another article (6) described the development of cutaneous abscesses at sites of previous infusion in 42 infants, 6 of whom developed *Serratia* bacteremia. Two of the infants died of *Serratia* meningitis, while 34 patients were colonized with the organism but remained unaffected. Further reported cases of *S. marcescens* meningitis occurred after neurosurgical procedures (3-5) while a single case following ear surgery has been reported (2). The patient in that case developed signs and symptoms of meningeal infection 8 days postoperatively, 1 day after discharge from the hospital. In our case, however, the patient developed meningitis 1 month after apparent full recovery from otic surgery. A nidus of infection in the middle ear was found upon autopsy and was the source of the meningeal infection. The patient had no history of being immunocompromised, and it is likely that he acquired the infection during the initial surgical procedure.

* Corresponding author.

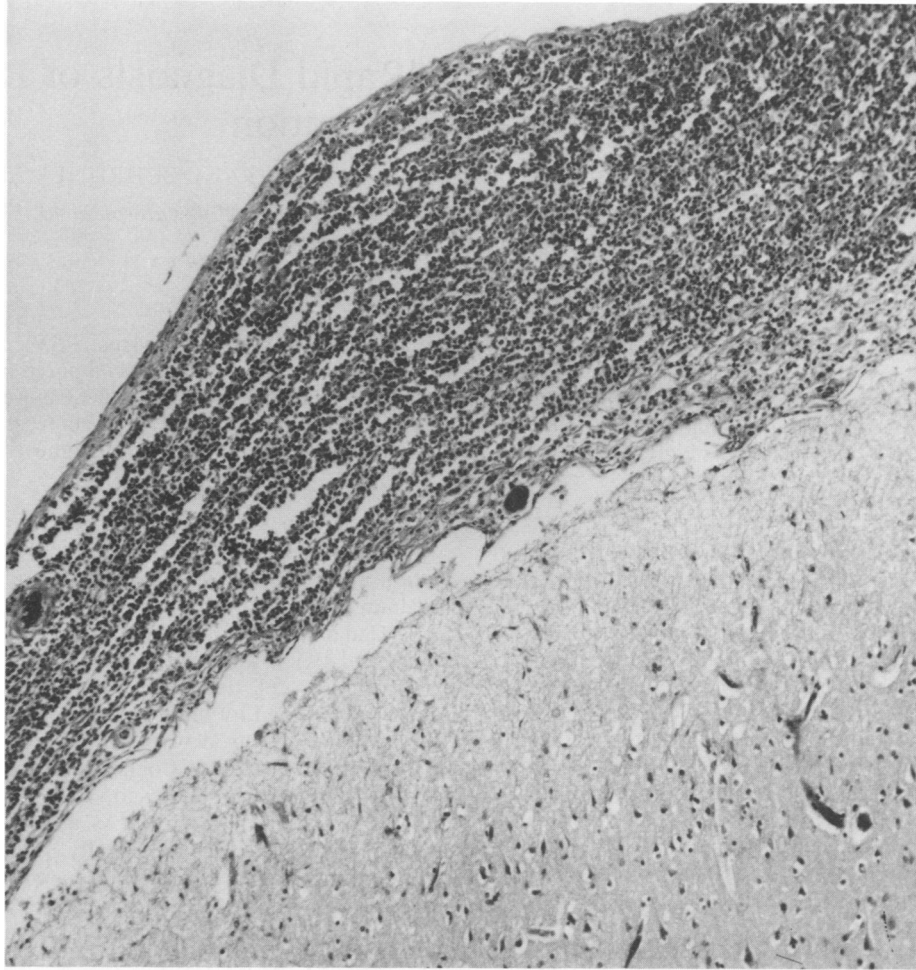


FIG. 1. Section of brain and meninges. Note the acute inflammatory cell infiltrate in the meninges. The section was stained with hematoxylin and eosin. Magnification, $\times 113$.

REFERENCES

1. Christensen, G. D., S. B. Korones, L. Reed, R. Bulley, B. McLaughlin, and A. L. Bisno. 1982. Epidemic *Serratia marcescens* in a neonatal intensive care unit. *Infect. Control* 3:127-133.
2. Jablokow, V. R., and S. Kathuria. 1982. Fatal meningitis due to *Serratia marcescens* after stapedectomy. *Arch. Otolaryngol.* 108:34-35.
3. Kourtopoulos, H., and S. E. Holm. 1976. Intraventricular treatment of *Serratia marcescens* meningitis with gentamicin. Pharmacokinetic studies of gentamicin concentration in one case. *J. Infect. Dis.* 8:57-60.
4. LeFrock, J. L., A. Molvi, B. Smith, P. Black, M. Rosenberg, K. Rolston, R. Brodner, P. Chandrasekar, L. Henao, and D. W. Kannangara. 1984. Effectiveness of cefatoxime in gram negative meningitis. *Neurosurgery* 15:679-682.
5. McConville, J. H., and J. P. Manzella. 1984. Parenteral trimethoprim/sulfamethoxazole for gram negative bacillary meningitis. *Am. J. Med. Sci.* 287:43-45.
6. Stamm, W. E., C. A. Kolff, E. M. Dones, R. Javariz, R. L. Anderson, J. J. Farmer, and H. R. De-Quinones. 1976. A nursery outbreak caused by *Serratia marcescens*—scalp-vein needles as a portal of entry. *J. Pediatr.* 98:96-99.