

Fatal Disseminated Infection Caused by *Myceliophthora thermophila*, a New Agent of Mycosis: Case History and Laboratory Characteristics

PAUL BOURBEAU,^{1*} DEANNA A. MCGOUGH,² HUGH FRASER,¹ NARAYAN SHAH,³
AND MICHAEL G. RINALDI^{2,4}

Departments of Laboratory Medicine¹ and Pediatric Hematology/Oncology,³ Geisinger Medical Center, Danville, Pennsylvania 17822, and Fungus Testing Laboratory, Department of Pathology, University of Texas Health Science Center at San Antonio² and Department of Veterans Affairs Mycology Reference Laboratory, Audie L. Murphy Memorial Veterans Hospital,⁴ San Antonio, Texas 78284

Received 9 April 1992/Accepted 18 August 1992

We report a case of human infection caused by the hyphomycete *Myceliophthora thermophila*. A 7-year-old male with neurofibromatosis (type 1) was diagnosed in 1987 with acute myeloblastic leukemia associated with the chromosomal abnormality monosomy 7. The patient experienced multiple serious infections over a three-year period before expiring in 1990 while in the end stage of leukemia. Autopsy findings included fungal vegetations of the left atrium, ascending aorta, and pulmonary arteries and fungal invasion of both lungs. Cultures yielded *M. thermophila*. We believe that this is the first reported fatality caused by *M. thermophila*.

Case report. A 7-year-old boy was diagnosed in 1987 at Geisinger Medical Center with biphenotypic acute myeloblastic leukemia associated with the chromosomal abnormality monosomy 7. His medical history was remarkable in that it included familial neurofibromatosis. His mother died at the age of 38 from complications associated with the disease.

During the three-year period between the time that he was diagnosed with leukemia until his death in 1990, he was beset by a multitude of infections. At different times, he was treated for culture-positive sepsis caused by *Capnocytophaga* spp., viridans group streptococci, *Enterobacter cloacae* (two episodes), *Micrococcus* spp., *Staphylococcus aureus*, *Escherichia coli*, and *Fusobacterium* spp. On two separate occasions he had antibiotic-associated enterocolitis with positive *Clostridium difficile* tissue culture toxin assays. He was also treated for various lengths of time for *Candida* esophagitis, herpes simplex stomatitis, hepatosplenic fungal (yeast) abscesses, and chronic Epstein-Barr virus infection marked by steadily rising Epstein-Barr virus immunoglobulin G titers.

The patient received several courses of chemotherapy during multiple hospital visits. Except for one period of remission, he was profoundly neutropenic for extended periods of time. In the month prior to his death, he remained febrile despite being treated with broad-spectrum antibiotics. The repeatedly negative bacterial cultures obtained while he was receiving multiple broad-spectrum antibiotics heightened a clinical suspicion of disseminated fungal infection. However, all fungal cultures during this month were negative. Fungal cultures included Isolator blood cultures (incubated for 4 weeks at 30°C) for each of the last 23 days of his life, a 200-ml pericardial infusion collected 1 week before his death, and two tracheal aspirate cultures.

Amphotericin B was administered for 14 days during the patient's last month of life. The dosage was 0.5 mg/kg for 2 days, 0.75 mg/kg for 2 days, and 1.0 mg/kg for 10 days.

Frequent chest X rays revealed no pulmonary abnormalities until three days prior to his death, at which time a bilateral pleural effusion was noted. Several echocardiograms during the same period showed no evidence of cardiac vegetations.

At autopsy, vegetations were noted in the left atrium, ascending aorta, main pulmonary artery, and both right and left pulmonary arteries. The right pulmonary artery was 80 to 90% obstructed by a fungal lesion. There was fungal invasion of both lungs, with infarction of the right middle lobe and left lower lobe secondary to obstruction of the arterial supply to these areas by fungi and accompanying fibrin thrombi. There was also a fibrinous, fungal exudate covering both the pericardium and the pleura of both lungs.

Laboratory studies. Samples of lung tissue obtained at autopsy were cultured in the microbiology laboratory of Geisinger Medical Center. A direct calcofluor white stain revealed many septate hyphal elements. After four days of incubation at 30°C, growth of a mold was detected on both inhibitory mold agar and brain heart infusion agar with cyclohexamide and chloramphenicol (REMEL, Lenexa, Kans.). Attempts to identify the fungus were unsuccessful. The isolate as well as unstained tissue slides were sent to the Fungus Testing Laboratory, Department of Pathology, University of Texas Health Science Center at San Antonio (UTHSC) for identification. There, the isolate (UTHSC no. 90-1045) was subcultured to potato flake agar (PFA) (7) as well as PFA slide cultures, all prepared in house. Gross morphology was ascertained from PFA at 25°C. Temperature growth studies were performed at 25, 35, and 50°C on Sabouraud dextrose agar slants (Becton Dickinson Microbiology Systems, Cockeysville, Md.).

Susceptibility testing was accomplished via a previously published broth macrodilution method (5, 8). A final concentration of 10⁴ blastoconidia per ml (as determined by hemacytometer count) was used as the starting inoculum, with incubation at 25°C.

Antimycotic agents investigated included amphotericin B (Fungizone I.V., E.R. Squibb & Sons, Princeton, N.J.),

* Corresponding author.

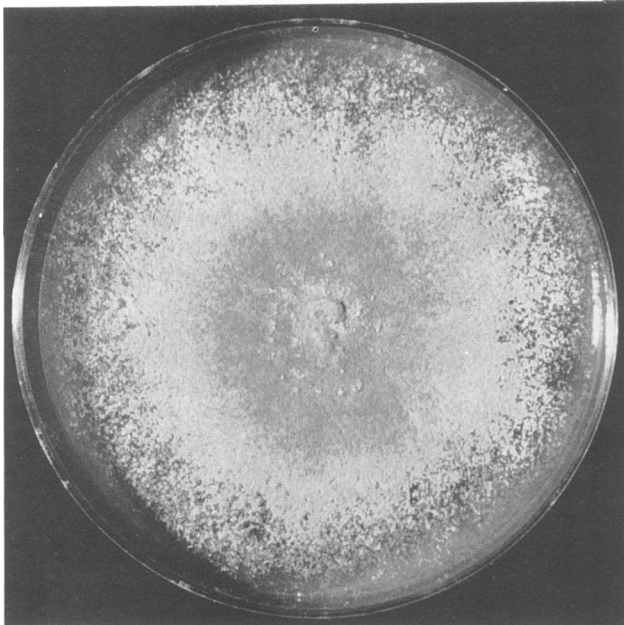


FIG. 1. Colonial morphology of *M. thermophila* after 7 days at 25°C on PFA. Note ill-defined margins, tan to brown coloration, and powdery texture.

5-fluorocytosine (Roche Laboratories, Nutley, N.J.), fluconazole (Pfizer Central Research, Groton, Ct.), itraconazole, ketoconazole, miconazole (Monistat I.V.), saperconazole (Janssen Pharmaceutica, Piscataway, N.J.), and Schering 39304 (Schering-Plough, Bloomfield, N.J.).

Amphotericin B was evaluated in antibiotic medium 3 (Difco Laboratories, Detroit, MI), while the other agents

were tested in Synthetic Amino Acid Medium-Fungal (American Biorganics, Niagara Falls, N.Y.).

A quality control strain of a *Paecilomyces* sp., UTHSC 90-459, was tested in concert with the clinical isolate to ensure that the test system was performing properly.

The isolate was grown for five days on a PFA plate, and three agar blocks (5 by 5 mm) were cut from the plate and placed in 10% formalin. These blocks, containing hyphae and conidia, were then stained in the UTHSC histopathology laboratory by the Masson-Fontana method. A melanin-positive control was stained in concert with the isolate. Histological slides prepared from both cardiac and lung tissue were stained in the same manner.

Results and discussion. Colonies on PFA were initially white and cottony and later pale brown (6) and powdery, without a well-defined margin (Fig. 1). The isolate produced colonies of approximately 40 mm in diameter in a 50-mm-diameter petri dish after two weeks (25°C). Growth occurred at all temperatures tested, with more luxuriant colonies growing at the elevated temperatures. Submerged hyphae (up to 6.0 μm in width) were wider than aerial hyphae (0.8 to 3.0 μm). Blastoconidia were borne terminally or laterally on the hyphae, sometimes with short or long pedicels and occasionally with a secondary blastoconidium being produced from the distal end of the first (Fig. 2). One to four blastoconidia were borne on one hyphal cell or ampulliform swelling. Conidia were obovoid to pyriform, 4.5 to 11.0 by 3.0 to 4.5 μm in size, hyaline, smooth, and thick walled, and became rough-walled at maturity (Fig. 3). The isolate was presumptively identified as *Myceliophthora thermophila*. This identification was confirmed by Lynne Sigler, University of Alberta, Edmonton, Alberta, Canada (UAMH no. 6713).

Figure 4 is a Masson-Fontana stain of a section of lung tissue. This picture is representative of other sections of lung and heart tissue stained by the Masson-Fontana method.

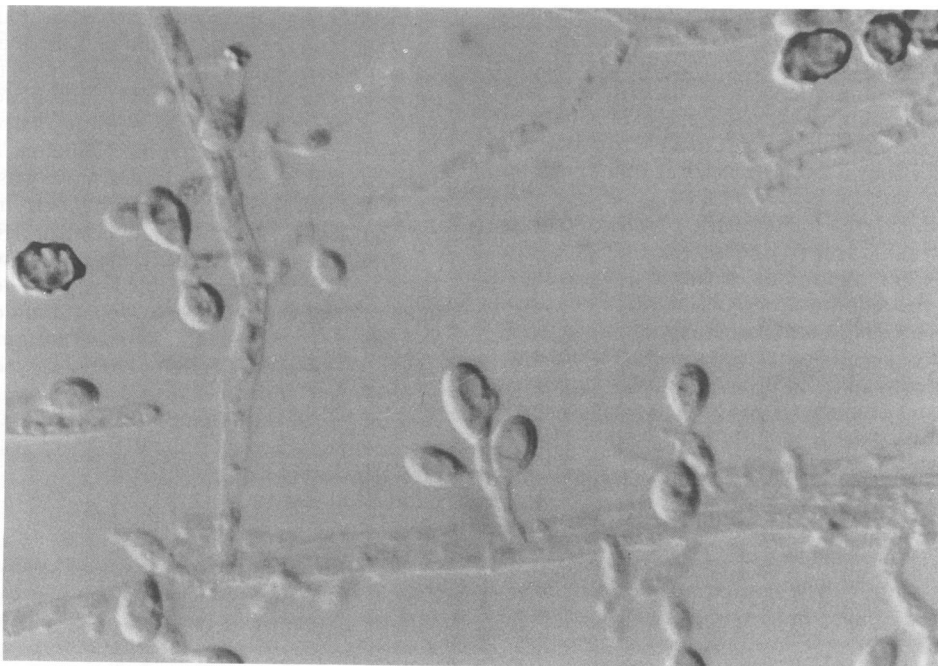


FIG. 2. Immature blastoconidia borne terminally and laterally on ampulliform swellings. Note mature conidium in the upper right corner. Magnification, $\times 1025$; Nomarski optics and a lactophenol cotton blue mount were used.

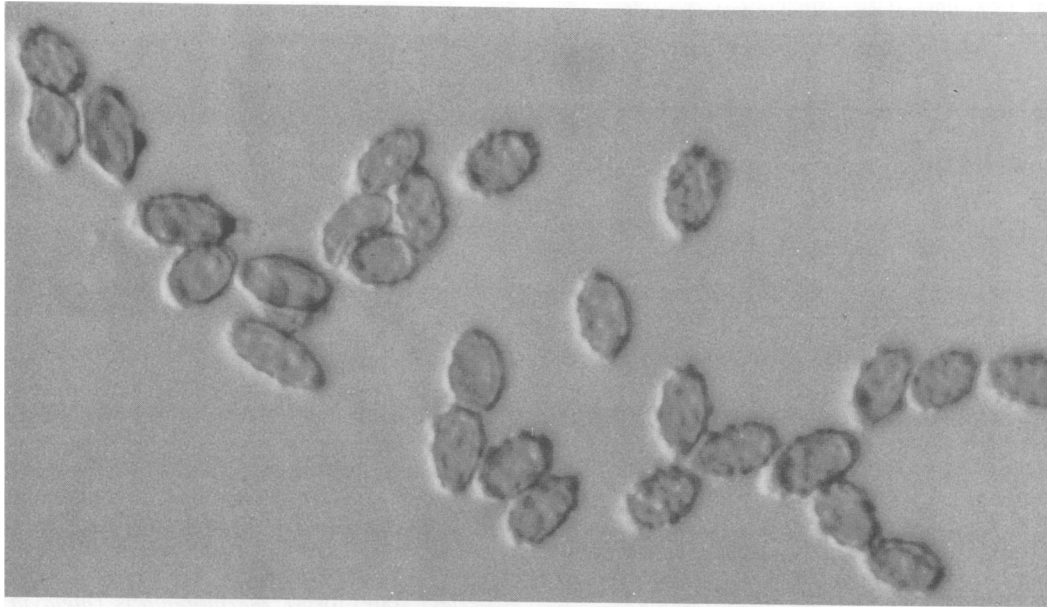

FIG. 3. Mature conidia of *M. thermophila*, showing dematiaceous and roughened nature. Magnification, $\times 1250$; Nomarski optics and a lactophenol cotton blue mount were used.

This stain may be utilized to detect melanin in the cell walls of fungi, as demonstrated by the brown to black staining of the fungal elements. Microscopic examination of all lesions examined showed fungal hyphae. In some areas, the fungi invaded through the thickness of the pulmonary arteries.

In vitro antifungal susceptibility testing data are displayed in Table 1. While the isolate appeared to be resistant to 5-fluorocytosine (a common finding at UTHSC for filamentous molds), data for the other agents would suggest in vitro susceptibility. Particularly noteworthy are the low minimum

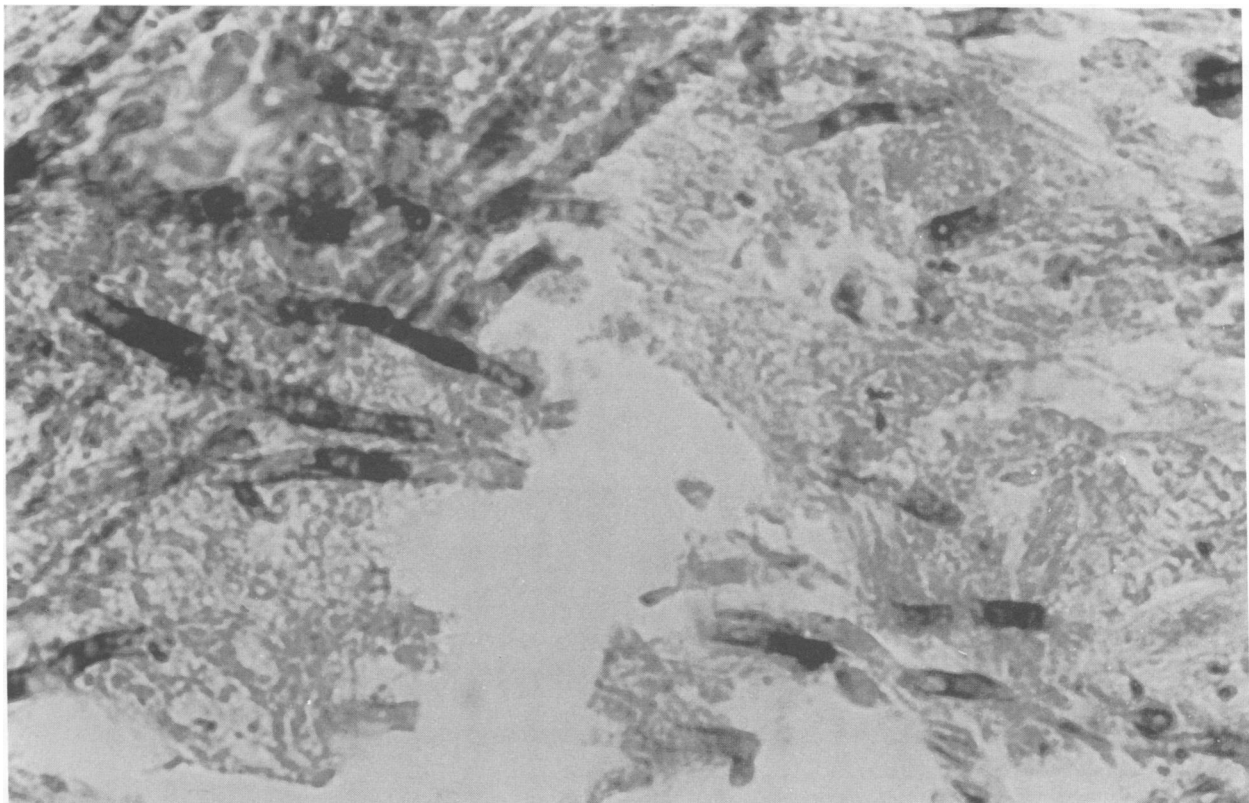


FIG. 4. Hyphae in the lung mass stained by the Masson-Fontana technique. Magnification, $\times 1200$.

TABLE 1. Antifungal susceptibility testing results

Antimycotic agent ^a	MIC ($\mu\text{g/ml}$) at:		MLC ^b ($\mu\text{g/ml}$) at:	
	72 h	96 h	72 h	96 h
AMB	0.29	0.58	0.58	1.16
5-FC	>322.75			
FLU	5	10	10	20
ITRA ^c	≤ 0.018	≤ 0.018	0.035	2.5
KETO	0.2	0.2	0.2	0.8
MON	≤ 0.6	≤ 0.6	≤ 0.6	≤ 0.6
SCH	5	5	5	40
SAP	≤ 0.018	≤ 0.018	≤ 0.018	2.5

^a AMB, amphotericin B; 5-FC, 5-fluorocytosine; FLU, fluconazole; ITRA, itraconazole; KETO, ketoconazole; MON, miconazole; SCH, Schering 39304; SAP, saperconazole.

^b MIC, minimum lethal concentration.

^c ITRA MICs and MLCs were read after 96 and 120 and after 120 and 144 h, respectively, because of the slower growth in the polyethylene glycol used to solubilize the drug.

lethal concentration readings for the azoles. These agents, which are fungistatic rather than fungicidal, frequently have low MICs but high minimum lethal concentrations.

This case is representative of the diagnostic dilemma faced by clinicians treating patients with prolonged neutropenia. Although a fungal infection was suspected in the weeks preceding the patient's death, there were no positive laboratory test results to support this diagnosis. Fungal cultures of blood drawn on each of 23 days prior to the patient's death were negative. Neither radiological chest films nor echocardiography results were suggestive of fungal infection. Increasingly, postmortem examination of individuals with se-

vere immunodeficiencies reveals the presence of invasive mycotic disease caused by fungi that are rarely, if ever, encountered as agents of mycosis.

M. thermophila, as the species epithet implies, is a thermophilic fungus responsible for a disease of cultivated mushrooms and is encountered in silage, fresh alfalfa grass forage, hay, wheat straw compost, and wood pulp (14). It has also been recovered from nonthermal areas such as dry pasture soil and birch chips (2). We believe that this is the first published report associating this fungus with a fatal, disseminated infection. This further reinforces the pathogenic potential of infrequently seen saprobic fungi in patients with severe immune system abrogation.

The taxonomy and nomenclature for this organism have, over the years, been subject to several revisions. Because the hyphae lacked clamp connections (seen with fungi having basiomycetous affinities), the fungus was transferred from the genus *Sporotrichum* to *Chrysosporium* (12). However, since *Chrysosporium* species have a maximum temperature for growth of 45°C rather than 48°C (9, 10) and produce arthroconidia, the organism was further transferred to the genus *Myceliophthora*. The ascomycetous teleomorph (or perfect state) for *M. thermophila* is *Thielavia heterothallica* Klopotek. It is described as a heterothallic, thermophilic fungus with spherical, black, nonostiolate cleistothecia containing ellipsoidal, evanescent asci. Asci contain eight one-celled ellipsoidal ascospores, deep brown to black, with one germ pore (11, 13). Mating studies were not performed with our strain of *M. thermophila*.

While the literature refers to *M. thermophila* as having hyaline hyphae, and hyaline to brown blastoconidia (3, 4, 9, 14), we were unable to document any prior attempts to

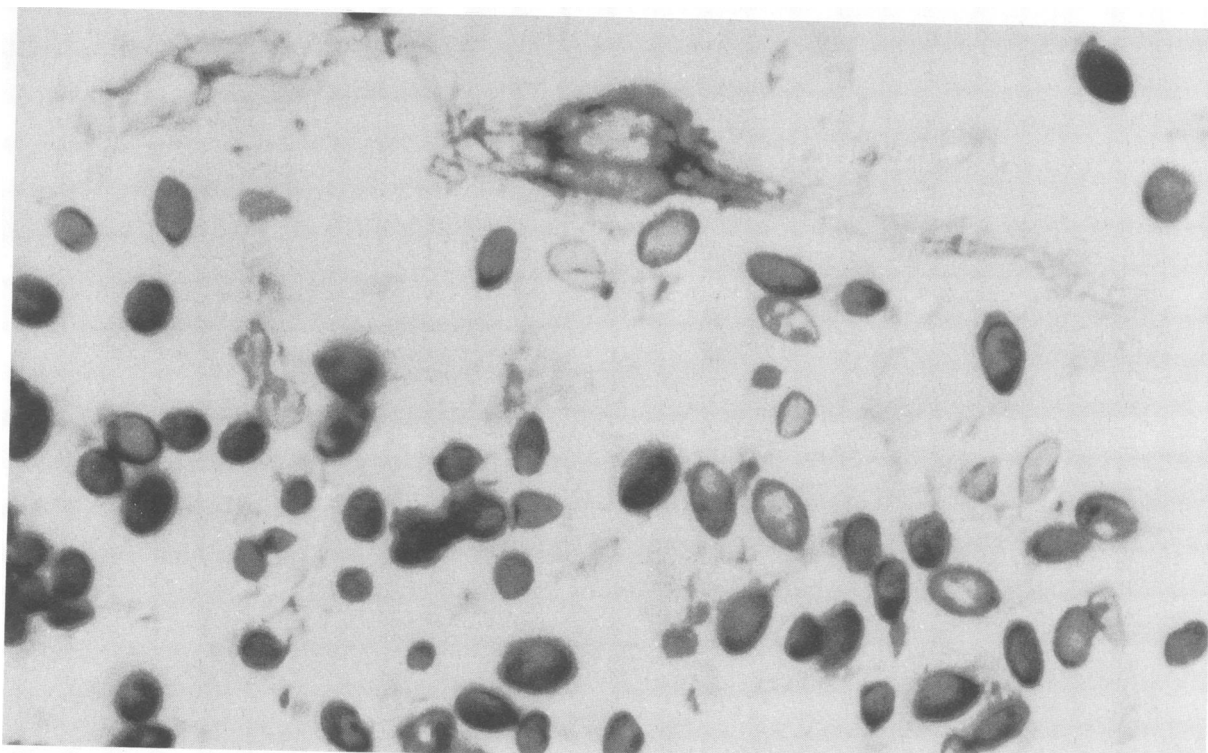


FIG. 5. Blastoconidia and hyphae of *M. thermophila* after 7 days of growth on PFA and stained by the Masson-Fontana technique. Magnification, $\times 1250$; Nomarski optics.

determine whether the fungus contained melanin. As the fungus in tissue obtained from the lung mass was Masson-Fontana positive, indicating melanin in the cell walls, this finding appeared to be contradictory with the original descriptions. Thus, to resolve this discrepancy, we stained the laboratory isolate. As shown in Figure 5, the *M. thermophila* isolate was also positive. Although we did not definitely identify the pigment produced by *M. thermophila*, we assume (pending further study) that it is some form of melanin. Whether one equates melanin with dematiaceous or adheres to the broader definition meaning "pigmented more or less darkly—of mycelium, spores, etc." (4), this isolate would certainly meet the criteria for inclusion in this category and could thus be considered an agent of phaeohyphomycosis (1).

The susceptibility testing data presented here would indicate in vitro susceptibility to all antifungal agents except 5-fluorocytosine. In the case of new, rarely isolated (frequently plant associated) agents of human disease, in vitro data correlation with in vivo clinical efficacy awaits standardization of such testing and prospective correlative studies. It is noteworthy that the patient received 286 mg of amphotericin B over a 12-day period which ended approximately one week prior to his death. Clearly, the success of any antifungal agent is enhanced by neutrophil activity. The development of more effective granulocyte colony-stimulating factors may improve the prognosis of individuals such as this patient.

M. thermophila represents yet another agent of the myriad of saprobic, frequently opportunistic, members of the class Hyphomycetes causing mycotic disease in severely immunocompromised hosts. The thermophilic nature of this organism, combined with its propensity for the vascular system, underscores the virulent and aggressive potential of this newly recognized human pathogen.

REFERENCES

1. Ajello, L. 1986. Hyalohyphomycosis and phaeohyphomycosis: two global disease entities of public health importance. *Eur. J. Epidemiol.* 2:243-251.
2. Apinis, A. E. 1963. Occurrence of thermophilous microfungi in certain alluvial soils near Nottingham. *Nova Hedwigia* 5:57-78.
3. Carmichael, J. W., W. B. Kendrick, I. L. Connors, and L. Sigler. 1980. *Genera of Hyphomycetes*. The University of Alberta Press, Edmonton, Alberta, Canada.
4. Hawksworth, D. L., B. C. Sutton, and G. C. Ainsworth. 1983. Ainsworth & Bisby's dictionary of the fungi, 7th ed. Commonwealth Mycological Institute, Kew, Surrey, United Kingdom.
5. McGinnis, M. R., and M. G. Rinaldi. 1985. Antifungal drugs: mechanisms of action, drug resistance, susceptibility testing, and assays of activity in biological fluids, p. 223-281. In V. Lorian (ed.), *Antibiotics in laboratory medicine*, 2nd ed. The Williams & Wilkins Co., Baltimore.
6. Rayner, R. W. 1970. A mycological colour chart. *Comm. Mycol. Inst. Kew, Surrey, United Kingdom*.
7. Rinaldi, M. G. 1982. Use of potato flakes agar in clinical mycology. *J. Clin. Microbiol.* 15:1159-1160.
8. Rinaldi, M. G., and A. W. Howell. 1988. Antifungal antimicrobics: laboratory evaluation, p. 325-355. In S. Bartlett, B. E. Robinson, and I. F. Salkin (ed.), *Diagnostic procedures for mycotic and parasitic infections*, 7th ed. American Public Health Association, Washington, D.C.
9. Semeniuk, G., and J. W. Carmichael. 1966. *Sporotrichum thermophile* in North America. *Can. J. Bot.* 44:105-108.
10. Sigler, L., and J. W. Carmichael. 1976. Taxonomy of *Malbranchea* and some other Hyphomycetes with arthroconidia. *Mycotaxon* 4:349-488.
11. von Arx, J. A. 1975. On *Thielavia* and some similar genera of Ascomycetes. *Stud. Mycol.* 8:1-29.
12. von Klopotek, A. 1974. Revision der thermophilen *Sporotrichum*-Arten: *Chrysosporium thermophilum* (Apinis) comb. nov. und *Chrysosporium fergusii* spec. nov. = status conidialis von *Corynascus thermophilus* (Fergus und Sinden) comb. nov. *Arch. Mikrobiol.* 98:365-369.
13. von Klopotek, A. 1976. *Thielavia heterothallica* spec. nov. die perfekte Form von *Chrysosporium thermophilum*. *Arch. Mikrobiol.* 107:223-224.
14. von Oorschot, C. A. N. 1977. The genus *Myceliophthora*. *Persoonia* 9:401-408.