

## Techniques for the Recovery and Identification of *Cryptosporidium* Oocysts from Stool Specimens

LYNNE S. GARCIA,\* DAVID A. BRUCKNER, THOMAS C. BREWER, AND ROBYN Y. SHIMIZU

Department of Pathology, Clinical Microbiology, University of California, Los Angeles, Medical Center, Los Angeles, California 90024

Received 23 March 1983/Accepted 31 March 1983

Due to increasing numbers of patients with documented infections with *Cryptosporidium* and other coccidia, it is important for the physician and clinical laboratory to be aware of the appropriate diagnostic techniques necessary for organism recovery and identification. Although *Cryptosporidium* is found in the gastrointestinal tract, tissue biopsies may be insufficient for organism recovery; the examination of stool specimens is a noninvasive procedure and will provide better overall opportunities for organism recovery. Human clinical specimens were examined from 45 patients with confirmed cryptosporidiosis or suspected of having the infection. Tissue biopsy sections, fecal wet preparations, and permanent stained smears were examined. Stool specimens were submitted in 10% Formalin, 2.5% potassium dichromate, and polyvinyl alcohol and were examined for oocysts by using 15 different methods: phase-contrast and light microscopy; Sheather's sugar flotation; Formalin concentration techniques; 10% potassium hydroxide; Giemsa; trichrome; periodic acid-Schiff; modified periodic acid-Schiff; silver methenamine; acridine orange; auramine-rhodamine; Kinyoun acid-fast; Ziehl-Neelsen carbolfuchsin; and a modified acid-fast procedure. Each technique or combination of techniques was assessed by organism quantitation, organism morphology, and ease of visual recognition. Based on these comparative studies, the modified Ziehl-Neelsen carbolfuchsin stain on 10% Formalin-preserved stool is recommended for the recovery and identification of *Cryptosporidium*.

In 1981, the Centers for Disease Control began reporting the occurrence of Kaposi's sarcoma and other severe opportunistic infections in previously healthy, young homosexual men (5-9, 17, 18, 20, 21, 27, 28, 31, 36, 42, 53). Numerous reports have appeared concerning a number of opportunistic infections and neoplasms, not only in homosexual and bisexual men, but also in other groups such as Haitians living in the United States, hemophiliacs, transfusion recipients, intravenous drug users, and contacts and children of high-risk patients (10-12, 14, 15, 26, 29, 33, 34, 44).

This syndrome has been called the acquired immunodeficiency syndrome (AIDS), and over 1,000 cases have been reported in this country and abroad (25, 40, 50). The AIDS syndrome has been associated with high mortality rates, ranging from approximately 20% for those with Kaposi's sarcoma alone to over 70% for those individuals with concurrent neoplasms and other opportunistic infections.

Among the opportunistic agents is *Cryptosporidium*, a coccidian parasite that has been implicated in intestinal disease, primarily in immunosuppressed patients (3, 4, 32, 43, 45, 46,

51, 52). Clinical symptoms include nausea, low-grade fever, abdominal cramps, anorexia, and 5 to 10 watery, frothy bowel movements a day, which may be followed by constipation (35, 38, 39, 47). Recent information also supports previous suggestions that cryptosporidiosis is a zoonosis and that *Cryptosporidium* is not host specific and is probably transmitted by the fecal-oral route; data also support the contention that cryptosporidiosis occurs not only in immunosuppressed or -compromised patients, but also among immunocompetent individuals (1, 19, 37).

Previously, the majority of cases had been diagnosed after examination of small or large bowel biopsy material. However, recent cases have been diagnosed by recovering oocysts (4 to 6  $\mu\text{m}$ ) from fecal material by flotation techniques, many of which use unpreserved specimens. Due to the risk of infection not only with *Cryptosporidium*, but more importantly, with the potentially infectious agent of AIDS, our laboratory was interested in developing and perfecting techniques which use preserved material. A number of different techniques and modifications were tried; for the recovery and identification of *Cryptosporidium*, the most sat-

isfactory method appears to be the modified Ziehl-Neelsen carbolofuchsin stain, using stool material preserved in 10% Formalin.

#### MATERIALS AND METHODS

Multiple specimens were examined from 45 patients; 8 patients were positive for *Cryptosporidium* (7 with AIDS, 1 with congenital immunoglobulin deficiencies). Fecal specimens were submitted to the laboratory in three separate vials, each containing one of the following: 2.5% potassium dichromate, 10% Formalin, or polyvinyl alcohol (PVA) (22, 39). The 10% Formalin and PVA fixatives were supplied by Meridian Diagnostics (Cincinnati, Ohio), and the 2.5% potassium dichromate was prepared in our laboratory. Patients and hospital staff were instructed to place 1 g (or 1 teaspoon) of fecal material into each vial and mix well.

Due to the possible presence of *Mycobacterium* in the stool specimens, all smears prepared from 10% Formalin and potassium dichromate were heat fixed for 10 min at 70°C before staining. All centrifugation procedures were performed by using 15-ml screw-capped centrifuge tubes (Corning Glass Works, Corning, N.Y.) to prevent aerosols. Safety precautions recommended by the Centers for Disease Control were followed (13).

Direct wet mounts and concentrated material (flotation and sedimentation) were examined from the 10% Formalin and 2.5% potassium dichromate preparations by using both phase-contrast and light microscopy. Sediments from Formalin and dichromate samples were processed and examined by the following stains: periodic acid-Schiff (PAS), modified PAS, silver methenamine, acridine orange, auramine-rhodamine, Kinyoun acid-fast, Ziehl-Neelsen acid-fast, and modified acid-fast (2, 16, 22, 30, 41, 48, 49; W. P. Horen, J. Parasitol., in press). Formalin-sedimented material was also treated with 10% KOH or subjected to Formalin rinses before staining (or both). Specimens submitted in PVA were processed by using the following stains: Giemsa, Gomori's Trichrome, Kinyoun acid-fast, Ziehl-Neelsen acid-fast, and modified acid-

fast (2, 22, 49). The addition of D'Antoni's iodine to PVA-preserved specimens facilitates the removal of mercuric chloride, thus allowing the smear to be stained with Giemsa or acid-fast stains (23).

The modified acid-fast procedure with 10% KOH is performed as follows. Sedimented material (upper layer of sediment after centrifugation for 2 min at 300 × g) is placed on a slide (thin layer) and is heat fixed at 70°C for 10 min before staining. If the specimen appears to be mucoid, 10 drops of 10% KOH are added to the sediment and vortexed until homogeneous before smear preparation. This is rinsed with 10% Formalin and centrifuged. Without decanting the supernatant fluid, 1 drop of sediment is placed on the slide as described above. After heat fixation, the smear is placed on a staining rack and flooded with carbolofuchsin. The slide is heated to steaming and allowed to stain for 5 min. If the slide begins to dry, more stain is added without additional heating. The smear is rinsed with tap or distilled water and decolorized with 5% sulfuric acid solution for 30 s (thicker smears may require a longer time). The smear is rinsed again with tap or distilled water and drained, and the slide is flooded with methylene blue counterstain for 1 min, rinsed with tap or distilled water, drained, and air dried.

Protocols and organism recovery assessment were performed by three technologists. Quantitation of organisms was based on numbers used in the quantitation of intestinal protozoa (24).

#### RESULTS

The most effective methods for specimens containing few organisms were Giemsa- and permanent acid-fast-stained smears with the hot staining method (Table 1). As the quantity of organisms per specimen increased, the number of effective techniques for recovery and identification also increased; these included sugar flotation, Formalin sedimentation, and Kinyoun acid-fast.

Phase-contrast microscopic examination of di-

TABLE 1. Ease of visual recognition of *Cryptosporidium* for different techniques

Technique	Ease of visual recognition for various overall quantities of organisms in specimen <sup>a</sup>				
	Rare	Rare-Few	Few-Moderate	Moderate-Many	Packed
Sugar flotation <sup>b</sup>	1+	1+	2+	3+	4+
Formalin sedimentation <sup>b</sup>	1+	1+	1+	2+	3+
Iodine	0	0	1+	1+	2+
Giemsa	1+	2+	3+	4+	4+
Trichrome	0	0	0	0	1+
PAS	0	0	1+	2+	2+
Modified PAS	0	0	0	1+	1+
Silver methenamine	0	0	0	1+	1+
Acridine orange	0	0	0	0	0
Auramine-rhodamine	0	1+	1+	1+	2+
Kinyoun acid-fast (cold)	1+	1+	2+	2+	2+
Ziehl-Neelsen acid-fast (hot)	1+	2+	3+	4+	4+
Modified acid-fast (hot)	3+	4+	4+	4+	4+

<sup>a</sup> The rating of 0 to 4+ indicates that techniques with the higher figure are considered more effective in allowing visual recognition of the *Cryptosporidium* organisms.

<sup>b</sup> Examined by phase-contrast and light microscopy.

TABLE 2. Quality of *Cryptosporidium* oocyst morphology for different techniques

Technique	Organism morphology <sup>a</sup>
Sugar flotation .....	Good-excellent <sup>b</sup>
Formalin sedimentation .....	Fair-good <sup>b</sup>
Iodine .....	Poor
Giemsa .....	Good-excellent
Trichrome .....	Poor-fair
PAS .....	Fair
Modified PAS .....	Poor-fair <sup>b</sup>
Silver methenamine .....	Poor-fair
Acridine orange .....	Poor <sup>c</sup>
Auramine-rhodamine .....	Fair-good <sup>c</sup>
Kinyoun acid-fast .....	Good
Ziehl-Neelsen acid-fast .....	Good-excellent
Modified acid-fast .....	Excellent

<sup>a</sup> Morphology was based on size, color, consistency of shape, and ability to distinguish *Cryptosporidium* from other artifacts.

<sup>b</sup> These specimens were examined under  $\times 400$ ; all other techniques included oil immersion examination at  $\times 1,000$ .

<sup>c</sup> Fluorescent specimens were screened at  $\times 250$ .

rect wet mounts and those prepared from concentrated material (flotation and sedimentation) was more effective in demonstrating *Cryptosporidium* than light microscopy. However, this

approach was not as effective as some of the permanent staining methods.

The morphology was found to be quite variable (Table 2), with the overall best results being obtained with Sheather's sugar flotation concentration, Giemsa, Kinyoun acid-fast, Ziehl-Neelsen acid-fast, and modified acid-fast techniques. The fluorescent techniques also provided a rapid screening approach, although definitive morphology was sometimes difficult to see and there was nonspecific fluorescence which could not always be confirmed as *Cryptosporidium* on permanent stained smears. Recognition of *Cryptosporidium* becomes very important in those patients where the numbers of organisms seen in the stool are rare or few. Even in those patients having typical watery diarrhea, the numbers of organisms eliminated were quite variable.

Among the staining techniques used, those that actually stained the organisms were much better than techniques with a negative staining approach where the organism was clear and the background was stained (iodine, modified PAS, and silver methenamine). The addition of 10% KOH to the 10% Formalin concentrate sediment provided better results with both the Giemsa and the acid-fast techniques. Optimal staining of the organisms was achieved after preliminary diges-

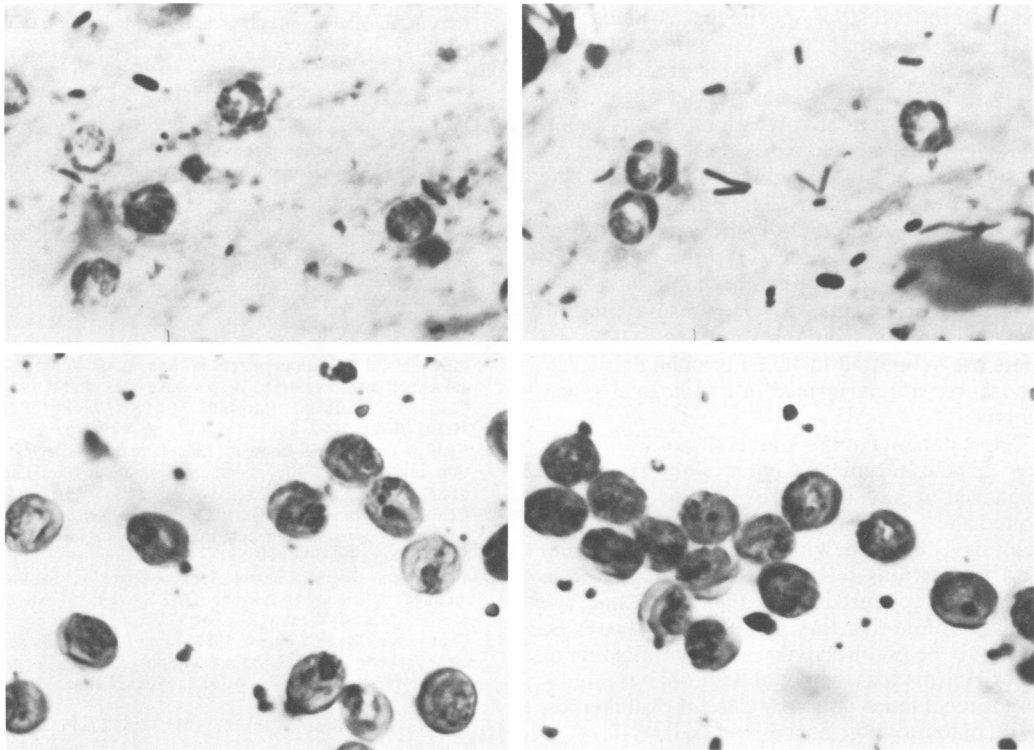


FIG. 1. *Cryptosporidium* oocysts recovered from stool material and stained by the modified acid-fast technique ( $\times 2,700$ ).

tion of the mucus with 10% KOH. The modified acid-fast technique provided less chance for over-decolorization, and the color was intense enough to allow the smear to be scanned at  $\times 400$  as well as  $\times 1,000$ . Based on the data from this study, the most effective technique is the modified acid-fast stain on concentrated 10% Formalin-preserved stool material after treatment with 10% KOH (Fig. 1).

This conclusion is supported by the fact that six of eight patients found to have *Cryptosporidium* infections in the intestinal tract were diagnosed from biopsy specimens; however, eight of eight patients were positive by using the recommended techniques for stool material. No patients have been diagnosed as positive by biopsy where the stool examination was negative.

### DISCUSSION

Because over 1,000 patients have now been identified as having the AIDS syndrome, the recovery and accurate identification of *Cryptosporidium* as one of the possible opportunistic agents will become more important to both clinicians and laboratorians. Many techniques have been tried to best demonstrate these small organisms. Biopsy material may provide a diagnosis; however, if the particular site biopsied is not infected, then the diagnosis will be missed. Examination of stool specimens assumes that there will be sampling of the entire intestinal tract and provides a noninvasive procedure.

The etiology of AIDS has not yet been established. Since it may involve an infectious agent, safe handling of specimens is most important for the hospital staff and the clinical laboratory. The use of Formalin-preserved material helps reduce this risk. Potassium dichromate is not a preservative; consequently, any *Cryptosporidium* oocysts present would remain viable and thus infective for humans. At the present time all fecal specimens from presumptive AIDS patients are submitted in 10% Formalin and PVA; procedures are performed in a biological safety cabinet.

Those patients at the University of California, Los Angeles Medical Center who have been diagnosed as having cryptosporidiosis have exhibited the typical watery diarrhea, and five of eight have expired with the AIDS syndrome. With the various numbers of *Cryptosporidium* organisms recovered from these patients, we cannot assume that the infection will always be extremely heavy. Recovery and identification of the organisms may be dependent on a combination of techniques and very careful examination of the material after processing.

The recommended techniques described here will ensure that the clinician and laboratory will

maximize their ability to make the diagnosis, thus assisting the clinician in patient care. The use of Giemsa and modified acid-fast stains on formalinized sediment provide the most effective opportunity for organism identification; the Sheather's sugar flotation method and the Kin-youn acid-fast technique also provide excellent diagnostic methods if the numbers of organisms in fecal material are fairly numerous.

These same staining techniques can also be used on duodenal aspirates which have first been fixed in an equal volume of 10% Formalin and then sedimented as described above.

### ACKNOWLEDGMENTS

We thank Mary Clancy, Marla Kort, Loraine Kobayashi, and George Berlin for technical assistance, William Current for technical guidance and consultation, Marietta Voge for manuscript review, Zane Price for photography, and Joan Duckgeischel for manuscript preparation.

### LITERATURE CITED

- Anderson, B. C., T. Donnelinger, R. M. Wilkins, and J. Smith. 1982. Cryptosporidiosis in a veterinary student. *J. Am. Vet. Med. Assoc.* **30**:408-409.
- Bailey, W. R., and E. G. Scott. 1966. *Diagnostic microbiology*, 2nd ed. The C. V. Mosby Co., St. Louis.
- Bird, R. G., and M. D. Smith. 1980. Cryptosporidiosis in man: parasite life cycle and fine structural pathology. *J. Pathol.* **132**:217-233.
- Booth, C. C. 1980. Immunodeficiency and cryptosporidiosis. Clinicopathological conference. *Br. Med. J.* **281**:1123-1127.
- Centers for Disease Control. 1981. *Pneumocystis pneumonia*—Los Angeles. *Morbidity and Mortality Weekly Report*. **30**:250-252.
- Centers for Disease Control. 1981. Kaposi's sarcoma and *Pneumocystis pneumonia* among homosexual men—New York and California. *Morbidity and Mortality Weekly Report*. **30**:305-308.
- Centers for Disease Control. 1982. Persistent, generalized lymphadenopathy among homosexual males. *Morbidity and Mortality Weekly Report*. **31**:249-251.
- Centers for Disease Control. 1982. Diffuse, undifferentiated non-Hodgkin's lymphoma among homosexual males—United States. *Morbidity and Mortality Weekly Report*. **31**:277-279.
- Centers for Disease Control. 1982. A cluster of Kaposi's sarcoma and *Pneumocystis carinii pneumonia* among homosexual male residents of Los Angeles and Orange Counties, California. *Morbidity and Mortality Weekly Report*. **31**:305-307.
- Centers for Disease Control. 1982. Opportunistic infections and Kaposi's sarcoma among Haitians in the United States. *Morbidity and Mortality Weekly Report*. **31**:353-361.
- Centers for Disease Control. 1982. *Pneumocystis pneumonia* among persons with hemophilia A. *Morbidity and Mortality Weekly Report*. **31**:365-367.
- Centers for Disease Control. 1982. Update on acquired immune deficiency syndrome (AIDS)—United States. *Morbidity and Mortality Weekly Report*. **31**:507-514.
- Centers for Disease Control. 1982. Acquired immune deficiency syndrome (AIDS): precautions for clinical and laboratory staffs. *Morbidity and Mortality Weekly Report*. **31**:577-580.
- Centers for Disease Control. 1983. Immunodeficiency among female sexual partners of males with acquired immune deficiency syndrome (AIDS)—New York. *Morbidity and Mortality Weekly Report*. **31**:697-698.

15. Centers for Disease Control. 1983. Acquired immune deficiency syndrome (AIDS) in prison inmates—New York, New Jersey. *Morbidity and Mortality Weekly Report* 31:700-701.
16. Churkian, C. T., and E. A. Schenk. 1977. Rapid Grocott's methenamine-silver nitrate method for fungi and *Pneumocystis carinii*. *Am. J. Clin. Pathol.* 68:427-428.
17. Drew, W. L., R. C. Miner, J. L. Ziegler, J. H. Gullett, D. I. Abrams, M. A. Conant, E. S. Huang, J. R. Groundwater, P. Volberding, and L. Mintz. 1982. Cytomegalovirus and Kaposi's sarcoma in young homosexual men. *Lancet* ii:125-127.
18. Drew, W. L., L. Mintz, R. C. Miner, M. Sands, and B. Ketterer. 1981. Prevalence of cytomegalovirus in homosexual men. *J. Infect. Dis.* 143:188-192.
19. Fletcher, A., T. A. Sims, and I. C. Talbot. 1982. Cryptosporidial enteritis without general or selective immune deficiency. *Br. Med. J.* 285:22-23.
20. Follansbee, S. E., D. F. Busch, C. B. Wofsy, D. L. Coleman, J. Gullett, G. P. Aurigemma, T. Ross, W. K. Hadley, and W. L. Drew. 1982. An outbreak of *Pneumocystis carinii* pneumonia in homosexual men. *Ann. Intern. Med.* 96:705-713.
21. Friedman-Kien, A. E., L. J. Laubenstein, P. Rubenstein, E. Buimovici-Kien, M. Marmor, R. Stahl, I. Spigland, K. S. Kim, and S. Zolla-Pazner. 1982. Disseminated Kaposi's sarcoma in homosexual men. *Ann. Intern. Med.* 96:693-700.
22. Garcia, L. S., and L. R. Ash. 1979. *Diagnostic parasitology*, 2nd ed. The C. V. Mosby Co., St. Louis.
23. Garcia, L. S., T. C. Brewer, D. A. Bruckner, and R. Y. Shimizu. 1983. Acid-fast staining of *Cryptosporidium* from human fecal specimens. *Clin. Microbiol. Newslett.* 5:60-62.
24. Garcia, L. S., and R. Shimizu. 1981. Comparison of clinical results for the use of ethyl acetate and diethyl ether in the Formalin-ether sedimentation technique performed on polyvinyl alcohol-preserved specimens. *J. Clin. Microbiol.* 13:709-713.
25. Gerstoft, J., A. Malchow-Moller, I. Bygbjerg, E. Dickmeiss, C. Enk, P. Halberg, S. Haahr, M. Jacobsen, K. Jensen, J. Mejir, J. O. Nielsen, H. K. Thomas, J. Sondergaard, and I. Lorenzen. 1982. Severe acquired immunodeficiency in European homosexual men. *Br. Med. J.* 285:17-19.
26. Gold, K. D., L. Thomas, and T. J. Garrett. 1982. Aggressive Kaposi's sarcoma in a heterosexual drug addict. *N. Engl. J. Med.* 307:98.
27. Gottlieb, M. S., R. Schroff, H. M. Schanker, J. D. Weisman, P. T. Fan, R. A. Wolf, and A. Saxon. 1981. *Pneumocystis carinii* pneumonia and mucosal candidiasis in previously healthy homosexual men. *N. Engl. J. Med.* 305:1425-1431.
28. Greene, J. B., G. Sidhu, S. Lewin, J. Levine, H. Masur, M. Simberkoff, P. Nicholas, R. Good, S. Zolla-Pazner, A. Pollock, M. Tapper, and R. Holzman. 1982. *Mycobacterium avium-intracellulare*: a cause of disseminated life-threatening infection in homosexuals and drug abusers. *Ann. Intern. Med.* 97:539-546.
29. Hauser, W. E., B. J. Luft, F. K. Conley, and J. S. Remington. 1982. Central nervous system toxoplasmosis in homosexual and heterosexual adults. *N. Engl. J. Med.* 307:498-499.
30. Ingram, R. L., L. B. Otken, Jr., and J. R. Jumper. 1961. Staining of malarial parasites by the fluorescent antibody technique. *Proc. Soc. Exp. Biol. Med.* 106:52-54.
31. Johnson, R., S. N. Horwitz, and P. Frost. 1982. Disseminated Kaposi's sarcoma in a homosexual man. *J. Am. Med. Assoc.* 247:1739-1741.
32. Lasser, K. H., K. J. Lewin, and F. W. Rynning. 1979. Cryptosporidial enteritis in a patient with congenital hypogammaglobulinemia. *Hum. Pathol.* 10:234-240.
33. Masur, H., M. A. Michelis, J. B. Greene, I. Onorato, R. A. Vande Stouwe, R. S. Holzman, G. Wormser, L. Brettman, M. Lange, H. W. Murray, and S. Cunningham-Rundles. 1981. An outbreak of community acquired *Pneumocystis carinii* pneumonia. *N. Engl. J. Med.* 305:1431-1438.
34. Masur, H., M. A. Michelis, G. P. Wormser, S. Lewin, J. Gold, M. L. Tapper, J. B. Giron, C. W. Lerner, D. Armstrong, U. Setia, J. A. Sender, R. S. Siebken, P. Nicholas, Z. Arien, S. Maayan, J. Ernst, F. Siegel, and S. Cunningham-Rundles. 1982. Opportunistic infections in previously healthy women. *Ann. Intern. Med.* 97:533-539.
35. Meisel, J. L., D. R. Perera, C. Meligro, and C. E. Rubin. 1976. Overwhelming watery diarrhea associated with *Cryptosporidium* in an immunosuppressed patient. *Gastroenterology* 70:1156-1160.
36. Mildvan, D., U. Mathur, R. W. Enlow, P. L. Romain, R. J. Winchester, C. Colp, H. Singman, and B. R. Adelsberg. 1982. Opportunistic infections and immune deficiency in homosexual men. *Ann. Intern. Med.* 96:700-704.
37. Moon, H. W., and W. J. Bemrick. 1981. Fecal transmission of calf cryptosporidia between calves and pigs. *Vet. Pathol.* 18:248-255.
38. Nime, F. A., J. D. Burek, D. L. Page, M. A. Holscher, and J. H. Yardley. 1976. Acute enterocolitis in a human being infected with protozoan *Cryptosporidium*. *Gastroenterology* 70:592-598.
39. Reese, N. C., W. L. Current, J. V. Ernst, and W. S. Bailey. 1982. Cryptosporidiosis of man and calf: a case report and results of experimental infections in mice and rats. *Am. J. Trop. Med. Hyg.* 31:226-229.
40. Rosenbaum, W., J. P. Couland, A. G. Sarmot, D. Klitzmann, C. H. Mayaud, and M. F. Carette. 1982. Multiple opportunistic infections in a male homosexual in France. *Lancet* i:572-573.
41. Shute, G. T., and T. M. Sodeman. 1973. Identification of malaria parasites by fluorescence microscopy and acridine orange staining. *Bull. W.H.O.* 48:591.
42. Siegel, F. P., C. Lopez, G. S. Hammer, A. E. Brown, S. J. Kornfeld, J. Gold, J. Hassett, S. Z. Hirschman, C. Cunningham-Rundles, B. A. Adelsberg, D. M. Parham, M. Siegel, S. Cunningham-Rundles, and D. Armstrong. 1981. Severe acquired immunodeficiency in male homosexuals, manifested by chronic perianal, ulcerative *Herpes simplex* lesions. *N. Engl. J. Med.* 305:1439-1444.
43. Sloper, K. S., R. R. Dourmaskin, R. B. Bird, C. Slavina, and A. D. B. Wester. 1982. Chronic malabsorption due to cryptosporidiosis in a child with immunoglobulin deficiency. *Gut* 23:80-82.
44. Spangenthal, S., D. G. Beer, D. R. Snyderman, S. R. Findlay, R. E. Rocklin, and B. L. Famburg. 1982. *Pneumocystis carinii* and cytomegalovirus pneumonia in a previously healthy adult. *Am. Rev. Respir. Dis.* 125:601-603.
45. Stemmermann, G. N., T. Hayashi, G. A. Glover, N. Oisahi, and R. I. Frankel. 1980. Cryptosporidiosis: report of a fatal case complicated by disseminated toxoplasmosis. *Am. J. Med.* 69:637-642.
46. Tzipori, S., K. W. Angus, I. Campbell, and E. W. Gray. 1980. *Cryptosporidium*: evidence for a single-species genus. *Infect. Immun.* 30:884-886.
47. Tzipori, S., K. W. Angus, E. W. Gray, and I. Campbell. 1980. Vomiting and diarrhea associated with *Cryptosporidium* infection. *N. Engl. J. Med.* 303:818.
48. United States Department of Health and Human Services. 1979. Laboratory methods in medical mycology. Public Health Service, Washington, D.C.
49. Vestal, A. L. 1975. Procedures for the isolation and identification of mycobacteria. U.S. Department of Health, Education, and Welfare, Centers for Disease Control 77-8230, Atlanta, Ga.
50. Vilaseca, J., J. M. Arnao, R. Bacardi, C. Mieras, A. Serrano, and C. Navarro. 1982. Kaposi's sarcoma and *Toxoplasma gondii* brain abscess in a Spanish homosexual. *Lancet* i:572.
51. Weinstein, L., S. M. Edelstein, J. L. Madera, K. R. Falchuk, B. M. McManus, and J. R. Trier. 1981. Intestinal cryptosporidiosis complicated by disseminated cytomegalovirus infection. *Gastroenterology* 81:584-591.
52. Weisburger, W. R., D. F. Hutcheon, J. H. Yardley, J. C.

- Roche, W. D. Hillis, and P. Charache. 1979. Cryptosporidiosis in an immunosuppressed renal-transplant recipient with IgA deficiency. *Am. J. Clin. Pathol.* 72:473-478.
53. Ziegler, J. L., R. C. Miner, E. Rosenbaum, E. T. Lennette, E. Shillito, C. Casavant, W. L. Drew, L. Mintz, J. Gershow, J. Greenspan, J. Beckstead, and K. Yamamoto. 1982. Outbreak of Burkitt's-like lymphoma in homosexual men. *Lancet* ii:631-633.