

Comparison of central corneal thickness and anterior chamber depth measurements using three imaging technologies in normal eyes and after phakic intraocular lens implantation

Muriël Doors · Lars P. J. Cruysberg · Tos T. J. M. Berendschot · John de Brabander · Frenne Verbakel · Carroll A. B. Webers · Rudy M. M. A. Nuijts

Received: 24 October 2008 / Revised: 23 March 2009 / Accepted: 6 April 2009 / Published online: 30 April 2009
© The Author(s) 2009. This article is published with open access at Springerlink.com

Abstract

Background The repeatability and interchangeability of imaging devices measuring central corneal thickness (CCT) and anterior chamber depth (ACD) are important in the assessment of patients considering refractive surgery. The purpose of this study was to investigate the agreement of CCT and ACD measurements using three imaging technologies in healthy eyes and in eyes after phakic intraocular lens implantation (pIOL).

Methods In this comparative study, CCT and ACD were measured using anterior segment optical coherence tomography (AS-OCT), Orbscan II, and Pentacam in 33 healthy volunteers (66 eyes) and 22 patients (42 eyes) after pIOL implantation. Intraobserver repeatability was evaluated for all three devices in the healthy volunteer group.

Results Pairwise comparison of CCT measurements showed significant differences between all devices ($P < 0.001$), except for the AS-OCT and Orbscan II in the healthy volunteer group ($P = 0.422$) and the Orbscan II and Pentacam in the pIOL group ($P = 0.214$). ACD measurements demonstrated significant differences between all pairwise comparisons in both groups ($P \leq 0.001$). Intraobserver reliability was high

for CCT and ACD measurements in the healthy volunteer group, with coefficients of variation ranging from 0.6% to 1.2% and 0.4% to 0.5% respectively.

Conclusions CCT and ACD measurements using AS-OCT, Orbscan II, and Pentacam demonstrated high intraobserver reliability. However, these devices should not be used interchangeably for measurements of CCT and ACD in healthy subject and patients after pIOL implantation.

Keywords Anterior segment imaging · Corneal thickness · Anterior chamber depth · Phakic intraocular lens · Optical coherence tomography

Introduction

Measurements of central corneal thickness (CCT) are important in the assessment of a variety of corneal diseases, the precision of intraocular pressure readings, and eligibility of patients considering refractive surgery. Doughty and Zaman described that a 10% difference in CCT may result in a 3.4 mmHg change in intraocular pressure (IOP) [1]. Furthermore, changes in corneal thickness can be a warning sign of endothelial cell loss [2], which can be helpful in evaluating the safety of iris-fixated phakic intraocular lenses (pIOLs).

Currently, a variety of non-contact imaging technologies are available to measure CCT. Applications such as the Visante anterior segment optical coherence tomography (AS-OCT; Carl Zeiss Meditec, Dublin, CA, USA), Orbscan II (Bausch & Lomb, Munich, Germany), and Pentacam (Oculus, Wetzlar, Germany), can all assess CCT without being in contact with the eye. Non-contact devices are becoming more popular, as they eliminate the disadvantages of ultrasound biometry, such as the risk of corneal

Financial support

None

The authors have no financial or proprietary interest in any aspect of this study and have full control of all primary data, and agree to allow Graefe's Archive for Clinical and Experimental Ophthalmology to review our data if requested.

M. Doors · L. P. J. Cruysberg · T. T. J. M. Berendschot · J. de Brabander · F. Verbakel · C. A. B. Webers · R. M. M. A. Nuijts (✉)

Department of Ophthalmology, University Hospital Maastricht, P. Debyelaan 25, 6202 AZ Maastricht, The Netherlands
e-mail: rudy.nuijts@mumc.nl

abrasions and infections due to corneal contact, as well as discomfort experienced by the patient.

In addition to CCT measurements, AS-OCT, Orbscan II and Pentacam also calculate anterior chamber depth (ACD). ACD is particularly important when evaluating patients' eligibility for iris-fixated pIOL implantation. Iris-fixated pIOL implantation is a safe method for correcting higher refractive errors when strict inclusion criteria for surgery are applied [3]. Hence, an accurate measurement of the ACD is of immense value to assure the safety of the adjacent corneal endothelium.

Although previously several of these imaging devices were compared in normal eyes, eyes diagnosed with keratoconus and eyes after corneal refractive surgery, no studies are reported in which these methods were compared in patients after pIOL implantation [4–11]. In this study, we evaluated CCT measurements in healthy volunteers and patients after pIOL implantation using AS-OCT, Orbscan II, and Pentacam. Additionally, we compared the ACD measurements using these three devices and evaluated their repeatability.

Materials and methods

Patient population and study design

Thirty-three healthy volunteers (66 eyes) were prospectively recruited from our outpatient clinic at the Academic Hospital Maastricht. This group had a mean age of 22.3 ± 1.6 years (range 20–29), and included 14 men and 19 women.

Furthermore, a group of 22 patients (42 eyes) who had undergone iris-fixated pIOL implantation were evaluated. This group had a mean age of 51.1 ± 9.3 years (range 33–67), and included nine men and 13 women. Before pIOL implantation, the mean spherical equivalent was -11.84 ± 6.13 diopters (D) and mean implanted pIOL power was -11.85 ± 5.91 D.

The study was conducted in accordance with the Declaration of Helsinki, and informed consent was obtained from all included subjects. Patients and volunteers with corneal pathology, previous refractive surgery, or abnormalities in the anterior segment were excluded from this study. All subjects were examined using AS-OCT, Orbscan II and Pentacam. In the healthy volunteer group, three consecutive measurements of each device were obtained by the same investigator to evaluate the intraobserver repeatability. The first measurement was used for the comparative analysis. In the pIOL group, all measurements were done once by the same investigator.

Imaging devices

Visante AS-OCT is a non-contact high-resolution device which can be used to measure CCT and ACD. Multiple A-

scans form a two-dimensional image of the anterior segment, using low-coherence interferometry. In our study, all images were made in the anterior segment single-scan mode, on the horizontal meridian, in an unaccommodated state, and in the same light conditions (50 lux). All subjects were asked to look at the optical target in the system. When the corneal reflex, a vertical white line along the center of the cornea, was visible, the image was captured. ACD was measured using the chamber function as provided by the manufacturer (from corneal endothelium to crystalline lens). Using this chamber function, the CCT was automatically computed by the system, using built-in analysis software which marks the boundaries of the anterior and posterior surface of the cornea. These automated measurements were used for the comparative analysis. In the healthy volunteer group, CCT was also measured manually in the anterior segment single-scan and the high-resolution scan, using the caliper function as provided by the manufacturer. The high-resolution scan is an enhanced image of the central cornea, which was also made on the horizontal meridian.

The Orbscan topography system (Orbscan II; version 3.10.31) uses a computerized slit-scanning method, which creates 40 vertical slit projections sequentially onto the cornea at an angle of 45° . The anterior and posterior corneal surfaces are obtained, and a corneal pachymetric map is created in a non-contact manner. Because initial comparative studies showed an overestimation of CCT using Orbscan II, an acoustic correction factor has to be used [12–15]. The manufacturer recommends an acoustic correction factor of 0.92, which was applied in our study. During the measurements, all patients were instructed to fixate on a fixation target in the center of the device. The corneal thickness in the center of the pupil was used for analysis. Besides CCT measurements, Orbscan II calculated the ACD, measured from corneal endothelium to crystalline lens.

The Pentacam is a non-contact device using a rotating Scheimpflug camera. The software constructs a three-dimensional image of the anterior segment, which gives information about the anterior and posterior surface of the cornea, and ACD (from corneal endothelium to crystalline lens). In our study, the patient was asked to fixate on a blue light target in the center of the camera. The device automatically determined when the image was in focus and the corneal apex correctly aligned. The rotating camera obtained 25 slit images of the anterior segment. The pachymetric measurement at the pupil center was used for analysis.

Statistical analysis

Previous studies have reported a standard deviation (SD) of within-subject CCT measurements ranging from 4.9 to $6.9 \mu\text{m}$ for Orbscan, Pentacam and AS-OCT [16, 17].

Therefore, with a significance level of 0.05, our study with 66 healthy eyes and 42 pIOL eyes has a power of >90% for both groups to detect a 15- μm difference between two measurement methods. For within-subject ACD measurements, a SD ranging from 0.001 to 0.052 mm for Orbscan, Pentacam and AS-OCT has been described [11, 18]. Thus, with a significance level of 0.05, our study with 66 healthy eyes and 42 pIOL eyes has a power of >90% for both groups to detect a 0.10 mm difference between two measurement methods. All data were collected in an Excel database and transferred to SPSS (SPSS for Windows, version 15.0, SPSS Inc, Chicago, IL, USA) for data analysis. Continuous variables were described as mean \pm SD. Paired *t*-tests were applied to compare CCT and ACD measurements between two applications in the healthy volunteer group and the pIOL group. To determine a relationship between the measurements of two devices, the Pearson's correlation coefficient (*r*) was used. The agreement between two devices was studied using the method described by Bland and Altman [19]. This method also computed 95% limits of agreement (LoA=mean difference \pm 1.96 SD). To determine intraobserver reliability between three consecutive measurements in the healthy volunteer group, the mean standard deviation between three consecutive measurements (SD^{within}), the coefficient of variation (CV) (ratio of SD^{within} and mean in percentage), and precision ($1.96 * SD^{\text{within}}$) were calculated. A *P*-value of <0.05 was considered significant.

Results

Agreement of central corneal thickness measurements

The results of the pairwise comparisons of the healthy volunteer group and the pIOL group are shown in Table 1 and Fig. 1. In the healthy volunteer group, CCT was measured using AS-OCT, Orbscan II, and Pentacam, with means of 532.1 ± 25.3 , 536.1 ± 28.1 and 551.3 ± 26.2 μm

respectively. In this group, all pairwise correlations were highly significant. However, all pairwise comparisons showed a significant difference, except for the comparison between automatic measurements in the anterior segment single-scan of the AS-OCT and the Orbscan II measurements ($P=0.422$). Pentacam overestimated CCT measurements compared to the other two devices ($P<0.001$).

In the pIOL group, the mean CCT using AS-OCT was 529.8 ± 40.3 μm , and the mean Orbscan II and Pentacam CCT were 541.4 ± 36.7 and 543.8 ± 38.6 μm respectively. All comparisons were highly correlated, and there was no significant difference between the Orbscan II and Pentacam CCT measurements in the pIOL group ($P=0.214$). AS-OCT measurements significantly underestimated CCT when compared to Orbscan II and Pentacam ($P<0.001$).

The pairwise comparisons of the CCT measurements using three different AS-OCT measurement modes in the healthy volunteer group are also listed in Table 1. Automatic CCT measurement using the anterior segment single-scan demonstrated the smallest values, whereas manual CCT measurements using the same scan showed the highest CCT values. All three AS-OCT modes comparisons were significantly different ($P<0.001$).

Agreement of anterior chamber depth measurements

In the healthy volunteer group, the mean ACD using AS-OCT, Orbscan II, and Pentacam were 3.41 ± 0.25 , 3.25 ± 0.29 and 3.34 ± 0.27 mm respectively. All pairwise comparisons demonstrated a significant difference between ACD measurements (Table 2). ACD measurements using Orbscan II were always smaller than the measurements of the other two imaging devices ($P<0.001$). The AS-OCT demonstrated higher ACD measurements than the Pentacam ($P<0.001$).

In the pIOL group, mean ACD using AS-OCT, Orbscan II and Pentacam were 3.15 ± 0.22 , 2.94 ± 0.31 and 3.06 ± 0.24 mm respectively. All pairwise comparisons showed a

Table 1 Pairwise comparison of central corneal thickness measurements for the healthy volunteers (healthy) and phakic intraocular lens (pIOL) group using anterior segment optical coherence tomography (AS-OCT), orbscan II, and pentacam

Pairwise comparison	Mean difference \pm SD (μm)		Pearson correlation coefficient* (<i>r</i>)		95% limits of agreement	
	Healthy	pIOL	Healthy	pIOL	Healthy	pIOL
Orbscan II/ Pentacam	-16.4 ± 12.4	-2.8 ± 13.3	0.902	0.931	8.0 to -40.7	23.3 to -28.9
Orbscan II/ AS-OCT	1.8 ± 14.2	9.7 ± 12.8	0.867	0.938	29.7 to -26.1	34.8 to -15.5
AS-OCT/ Pentacam	-19.2 ± 8.5	-14.1 ± 11.6	0.947	0.958	-2.6 to -35.8	8.7 to -36.8
Automatic SS/manual SS	-13.9 ± 11.8	NA	0.901	NA	9.1 to -37.0	NA
Automatic SS/manual HR	-6.21 ± 7.6	NA	0.954	NA	8.7 to -21.1	NA
Manual SS/manual HR	7.73 ± 10.5	NA	0.922	NA	28.3 to -12.8	NA

SD=standard deviation; SS=anterior segment single-scan; HR=high-resolution scan

*All with $P<0.001$

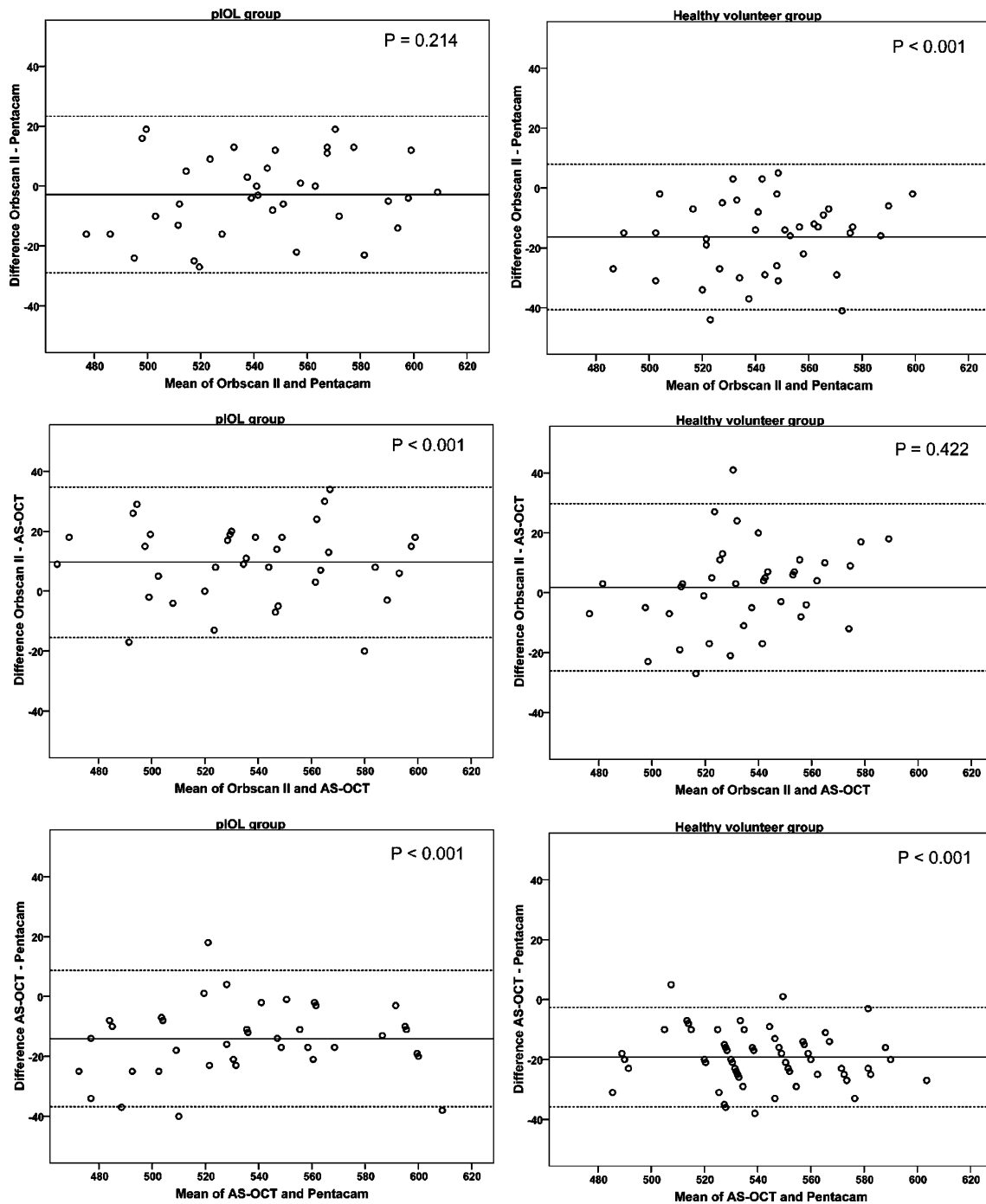


Fig. 1 Bland-Altman plots of the differences between anterior segment optical coherence tomography (AS-OCT), Orbscan II and Pentacam central corneal thickness measurements in the healthy

volunteer group and the phakic intraocular lens (pIOL) group with *P*-value of the paired *t*-test. All scales in μm

significant difference between ACD measurements (Table 2). Similar to the healthy volunteer group, Orbscan II underestimated ACD compared to AS-OCT and Pentacam measurements, and AS-OCT overestimated ACD when compared to Pentacam measurements. In Fig. 2, Bland-Altman plots visualize the ACD differences between the three imaging systems for both groups.

Intraobserver reliability

Table 3 presents the intraobserver reliability for measurements of CCT using three AS-OCT modes, Orbscan II, and Pentacam. In all imaging devices the repeatability was high. Manual measurements of CCT using the high-resolution scan showed the smallest SD^{within} and CV, and manual

Table 2 Pairwise comparison of anterior chamber depth measurements for the healthy volunteers (healthy) and phakic intraocular lens (piol) group using anterior segment optical coherence tomography (AS-OCT), Orbscan II, and Pentacam

Pairwise comparison	Mean difference±SD (mm)		Pearson correlation coefficient* (<i>r</i>)		95% limits of agreement	
	Healthy	piOL	Healthy	piOL	Healthy	piOL
Orbscan II/ Pentacam	-0.08±0.04	-0.10±0.04	0.990	0.983	0.00 to -0.17	-0.02 to -0.19
Orbscan II/ AS-OCT	-0.15±0.05	-0.21±0.05	0.987	0.981	-0.06 to -0.24	-0.12 to -0.30
AS-OCT/ Pentacam	0.07±0.04	0.10±0.08	0.990	0.946	0.15 to -0.01	0.25 to -0.06

SD=standard deviation

*All with $P<0.001$

measurements in the anterior segment single-scan showed the highest SD^{within} and CV.

The intraobserver reliability of the ACD measurements using AS-OCT, Orbscan II, and Pentacam was high, with a SD^{within} of 0.014 ± 0.009 , 0.015 ± 0.009 and 0.017 ± 0.009 mm respectively. The AS-OCT showed the smallest variation between ACD measurements, with a CV of $0.4\pm 0.3\%$ and a precision of 0.028 ± 0.018 and the Pentacam presented the largest variation, with a CV of $0.5\pm 0.3\%$ and a precision of 0.033 ± 0.019 . The CV and precision of the Orbscan II were $0.5\pm 0.3\%$ and 0.029 ± 0.017 respectively.

Discussion

This study revealed significant differences in ACD measurements using AS-OCT, Orbscan II, and Pentacam, between all pairwise comparisons in the healthy volunteer group and the piOL group. Furthermore, the pairwise comparisons of CCT measurements using AS-OCT, Orbscan II, and Pentacam showed significant differences in both groups, except for the comparison between AS-OCT and Orbscan II in the healthy volunteer group and between Orbscan II and Pentacam in the piOL group. However, these last two comparisons did show large 95% limits of agreement. Overall, this indicates the existence of systematic offsets in CCT and ACD values between the investigated imaging technologies in healthy volunteers and patients after piOL implantation.

The CCT values measured with automatic AS-OCT were significantly smaller than Pentacam measurements in both groups. Furthermore, we found significantly smaller CCT measurements using AS-OCT compared to Orbscan II in the piOL group. In the healthy volunteer group, this difference did not reach significance. The reported differences are in accordance with recent literature [20]. Significantly smaller CCT measurements using AS-OCT were described by Ho et al., comparing AS-OCT values to Pentacam, and Orbscan II measurements [4]. A possible

explanation for these smaller CCT values using AS-OCT was described by Li et al. They reported that the algorithm for the Visante OCT places the anterior corneal surface boundary slightly below the anterior corneal surface [16]. This results in slightly smaller CCT values when using the automatic CCT measurements, which we used for our comparative analysis. During the manual CCT measurements of this study, the calipers were placed on the anterior corneal surface. This resulted in significantly higher manual AS-OCT measurements compared to the automatic CCT measurements.

Orbscan II showed smaller CCT measurements than Pentacam, with a significant difference in the healthy volunteer group. Rosa et al. also reported smaller Orbscan II CCT measurements than Pentacam measurements in normal eyes [21]. Lackner et al. investigated the intensity profiles of the Pentacam and Orbscan II. The Pentacam showed steeper corneal edge depictions than the Orbscan, which resulted in less blurred images using Pentacam [17]. The reliability of the detection of the posterior corneal surface using the Orbscan II is still unknown, and could be the explanation for the reported differences [22].

To our knowledge, no studies have evaluated all three imaging techniques in healthy eyes and compared them to ultrasound pachymetry, which is known to be the gold standard. There are several studies reported in the literature comparing AS-OCT, Pentacam and Orbscan II separately to ultrasound pachymetry. Studies comparing CCT measurements with ultrasound pachymetry to AS-OCT in healthy eyes showed an underestimation of AS-OCT measurements, with mean differences of $26.6\mu\text{m}$ reported by Kim et al. [23] and $31.9\mu\text{m}$ by Wong et al. [24]. Some comparison studies investigating the agreement between Orbscan II and ultrasound pachymetry found no statistical significant difference in CCT measurements when the mentioned acoustic correction factor of 0.92 was applied to the Orbscan II values [5, 20, 25]. However, other studies reported underestimations of CCT measurements using Orbscan II, after the acoustic correction factor was applied

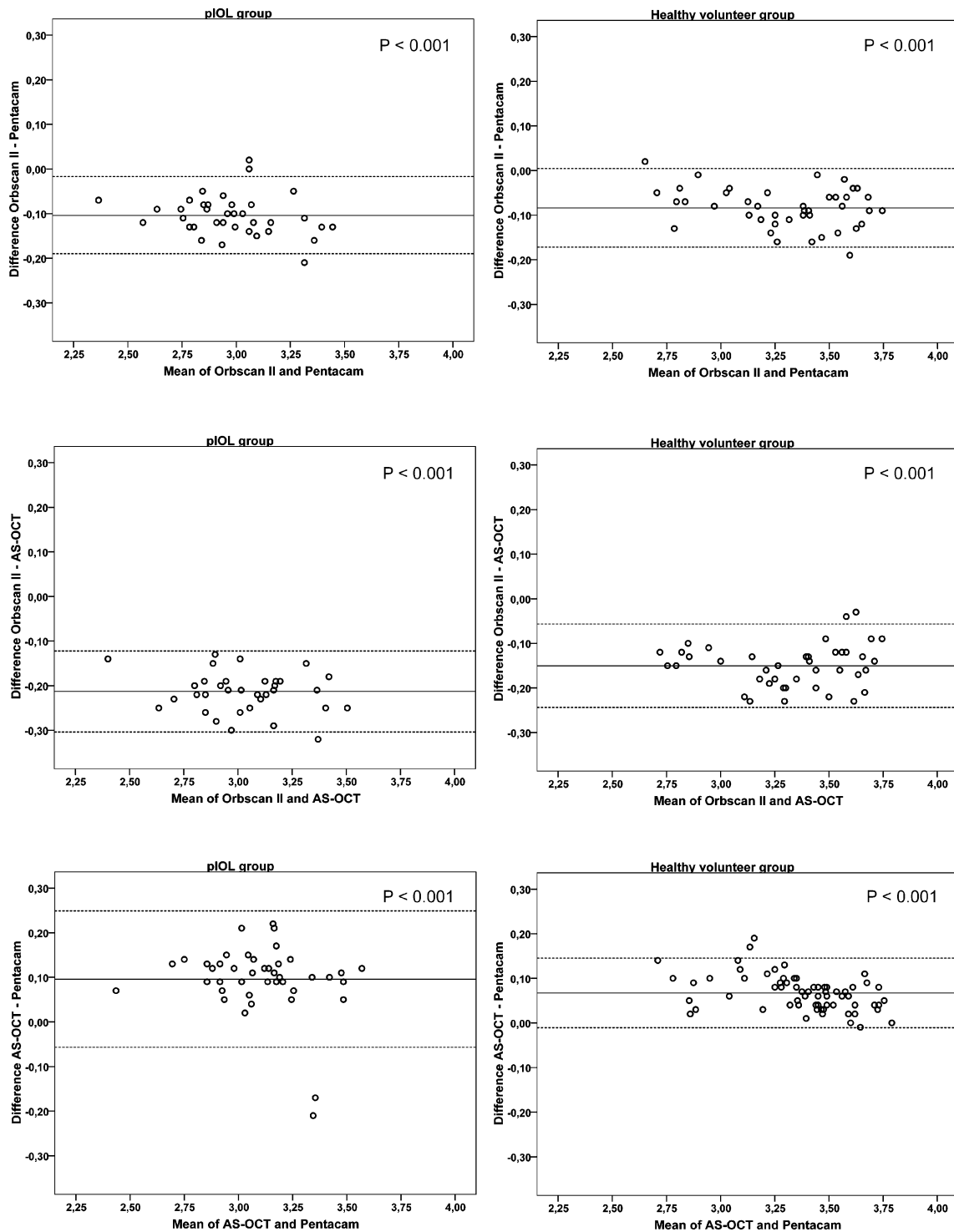


Fig. 2 Bland-Altman plots of the differences between anterior segment optical coherence tomography (AS-OCT), Orbscan II and Pentacam anterior chamber depth measurements in the healthy

volunteer group and the phakic intraocular lens (pIOL) group with *P*-value of the paired *t*-test. All scales in mm

[8, 15, 17, 26]. Amano et al. found no significant difference between Pentacam and ultrasound pachymetry CCT measurements [5]. However, there are studies reporting a significant difference between these two

devices [8, 27]. Since there are a large amount of studies reporting significant differences between the AS-OCT, Pentacam and Orbscan II when compared to ultrasound pachymetry; even with the application of a correction

Table 3 Intraobserver reliability from three consecutive central corneal thickness measurements of the healthy volunteer group

Device	Overall Mean±SD (μm)	SD ^{within} ±SD	CV±SD (%)	Precision±SD
AS-OCT				
Automatic segment single	531.1±25.1	3.8±2.7	0.7±0.5	7.5±5.4
Manual segment single	545.3±25.1	6.8±6.0	1.2±1.1	13.3±11.7
Manual high resolution	538.8±24.4	3.3±4.1	0.6±0.7	6.5±8.0
Orbscan II	530.3±40.8	5.4±3.5	1.0±0.7	10.5±6.8
Pentacam	551.6±25.6	4.0±2.3	0.7±0.4	7.9±4.6

SD=standard deviation; SD^{within}=mean standard deviation between three consecutive measurements; CV=coefficient of variation; AS-OCT=anterior segment optical coherence tomography

factor in the Orbscan II, these devices can not be used interchangeably.

Limits of agreement give an idea about how much the devices can differ in 95% of the patients. In this study, the significant mean differences in CCT measurements were between 10 and 19 μm, with spans of the 95% limits of agreement between 38.4 and 50.3 μm. In the comparison between Orbscan II and Pentacam in the pIOL group and between Orbscan II and AS-OCT in the healthy volunteer group, the mean differences were not statistically significant. However, these two comparisons showed the largest 95% limits of agreement, with spans of 52.2 μm between Orbscan II and Pentacam and 55.8 μm between Orbscan II and AS-OCT. In our opinion, the reported CCT differences with their 95% limits of agreement are clinically significant, especially in patients considering refractive surgery. Furthermore, these large limits of agreement come close or even exceed the mentioned 10% difference in CCT measurements by Doughty et al., which may result in IOP differences of 3.4 mmHg or more depending on the used imaging device [1]. Some investigators recommend categorizing corneal thickness as thin, average, or thick and not using a specific algorithm to correct for corneal thickness, since CCT measurements can differ between devices and there are different algorithms reported in the literature [28, 29].

ACD measurements using AS-OCT were significantly higher than the Pentacam values in both groups. Pentacam ACD measurements are automatically calculated by the device. However, when using AS-OCT the ACD had to be measured manually. The chamber function provides a caliper which has to be placed on the anterior surface of the lens. This caliper has a thickness of approximately 40 μm and was placed with the anterior surface of the caliper on the anterior surface of the lens. Placing the posterior surface of the caliper onto the lens surface might improve the agreement between AS-OCT and Pentacam ACD measurements.

Orbscan II ACD measurements were significantly smaller than AS-OCT and Pentacam measurements. This

could be due to the relatively low-depth resolution of slit scanning compared to Pentacam and AS-OCT [22].

The mean differences in ACD measurements between two devices ranged from 0.07 to 0.21 mm, with a large range in the spans of 95% limits of agreement from 0.16 to 0.31 mm. The mean differences between the three imaging devices seem quite small; however, the 95% limits of agreement are large and clinically relevant, especially in pIOL power calculation and the assessment of pIOL safety. Although the devices were highly correlated, they can not be used interchangeably.

The intraobserver reliability for ACD and CCT was excellent for the AS-OCT, Orbscan II, and Pentacam. The manual CCT measurement using the anterior segment single-scan demonstrated the largest variability. The caliper function in this scan shows large steps for each pixel, i.e. one pixel represents 20 μm, with explains the larger variability. Measurements in the high-resolution scan were more precise. In this scan, one pixel is 10 μm. Li et al. also evaluated the intraobserver reliability of CCT measurements using manual and automatic AS-OCT. They described a SD^{within} of 4.9 and 6.9 for automatic AS-OCT and manual AS-OCT, with a CV of 0.9 and 1.2%, respectively, which are consistent with our results [16]. Furthermore, the AS-OCT showed the best intraobserver reliability for ACD measurements in our study, with the smallest standard deviation and coefficient of variation. In accordance with our results, Pinero et al. reported a CV of 0.38% using AS-OCT for ACD measurements [30].

In conclusion, the intraobserver reliability of AS-OCT, Pentacam and Orbscan II were excellent for CCT and ACD measurements. However, all investigated devices should not be used interchangeably for measurement of ACD and CCT in healthy subjects and patients after pIOL implantation. Pairwise comparison of the imaging technologies showed significant mean differences, with large 95% limits of agreement.

Acknowledgements None.

Open Access This article is distributed under the terms of the Creative Commons Attribution Noncommercial License which permits any noncommercial use, distribution, and reproduction in any medium, provided the original author(s) and source are credited.

References

- Doughty MJ, Zaman ML (2000) Human corneal thickness and its impact on intraocular pressure measures: A review and meta-analysis approach. *Surv Ophthalmol* 44:367–408. doi:10.1016/S0039-6257(00)00110-7
- Cheng H, Bates AK, Wood L, McPherson K (1988) Positive correlation of corneal thickness and endothelial cell loss. Serial measurements after cataract surgery. *Arch Ophthalmol* 106:920–922
- Tahzib NG, Nuijts RM, Wu WY, Budo CJ (2007) Long-term study of artisan phakic intraocular lens implantation for the correction of moderate to high myopia: Ten-year follow-up results. *Ophthalmology* 114:1133–1142. doi:10.1016/j.ophtha.2006.09.029
- Ho T, Cheng AC, Rao SK, Lau S, Leung CK, Lam DS (2007) Central corneal thickness measurements using Orbscan II, Visante, ultrasound, and Pentacam pachymetry after laser in situ keratomileusis for myopia. *J Cataract Refract Surg* 33:1177–1182. doi:10.1016/j.jcrs.2007.03.028
- Amano S, Honda N, Amano Y, Yamagami S, Miyai T, Samejima T, Ogata M, Miyata K (2006) Comparison of central corneal thickness measurements by rotating Scheimpflug camera, ultrasonic pachymetry, and scanning-slit corneal topography. *Ophthalmology* 113:937–941. doi:10.1016/j.ophtha.2006.01.063
- Kim SW, Byun YJ, Kim EK, Kim TI (2007) Central corneal thickness measurements in unoperated eyes and eyes after PRK for myopia using Pentacam, Orbscan II, and ultrasonic pachymetry. *J Refract Surg* 23:888–894
- de Sanctis U, Missolungi A, Mutani B, Richiardi L, Grignolo FM (2007) Reproducibility and repeatability of central corneal thickness measurement in keratoconus using the rotating Scheimpflug camera and ultrasound pachymetry. *Am J Ophthalmol* 144:712–718. doi:10.1016/j.ajo.2007.07.021
- Hashemi H, Mehravaran S (2007) Central corneal thickness measurement with Pentacam, Orbscan II, and ultrasound devices before and after laser refractive surgery for myopia. *J Cataract Refract Surg* 33:1701–1707
- Lavanya R, Teo L, Friedman DS, Aung HT, Baskaran M, Gao H, Alfred T, Seah SK, Kashiwagi K, Foster PJ, Aung T (2007) Comparison of anterior chamber depth measurements using the IOLMaster, scanning peripheral anterior chamber depth analyser, and anterior segment optical coherence tomography. *Br J Ophthalmol* 91:1023–1026. doi:10.1136/bjo.2006.113761
- Haque S, Simpson T, Jones L (2006) Corneal and epithelial thickness in keratoconus: A comparison of ultrasonic pachymetry, Orbscan II, and optical coherence tomography. *J Refract Surg* 22:486–493
- Lackner B, Schmidinger G, Skorpik C (2005) Validity and repeatability of anterior chamber depth measurements with Pentacam and Orbscan. *Optom Vis Sci* 82:858–861. doi:10.1097/01.opx.0000177804.53192.15
- Yaylali V, Kaufman SC, Thompson HW (1997) Corneal thickness measurements with the Orbscan topography system and ultrasonic pachymetry. *J Cataract Refract Surg* 23:1345–1350
- Liu Z, Huang AJ, Pflugfelder SC (1999) Evaluation of corneal thickness and topography in normal eyes using the Orbscan corneal topography system. *Br J Ophthalmol* 83:774–778. doi:10.1136/bjo.83.7.774
- Chakrabarti HS, Craig JP, Brahma A, Malik TY, McGhee CN (2001) Comparison of corneal thickness measurements using ultrasound and Orbscan slit-scanning topography in normal and post-lasik eyes. *J Cataract Refract Surg* 27:1823–1828
- Hashemi H, Roshani M, Mehravaran S, Parsafar H, Yazdani K (2007) Effect of corneal thickness on the agreement between ultrasound and Orbscan II pachymetry. *J Cataract Refract Surg* 33:1694–1700
- Li H, Leung CK, Wong L, Cheung CY, Pang CP, Weinreb RN, Lam DS (2008) Comparative study of central corneal thickness measurement with slit-lamp optical coherence tomography and Visante optical coherence tomography. *Ophthalmology* 115:796–801. doi:10.1016/j.ophtha.2007.07.006
- Lackner B, Schmidinger G, Pieh S, Funovics MA, Skorpik C (2005) Repeatability and reproducibility of central corneal thickness measurement with Pentacam, Orbscan, and ultrasound. *Optom Vis Sci* 82:892–899. doi:10.1097/01.opx.0000180817.46312.0a
- Goldsmith JA, Li Y, Chalita MR, Westphal V, Patil CA, Rollins AM, Izatt JA, Huang D (2005) Anterior chamber width measurement by high-speed optical coherence tomography. *Ophthalmology* 112:238–244. doi:10.1016/j.ophtha.2004.09.019
- Bland JM, Altman DG (1986) Statistical methods for assessing agreement between two methods of clinical measurement. *Lancet* 1:307–310
- Li EY, Mohamed S, Leung CK, Rao SK, Cheng AC, Cheung CY, Lam DS (2007) Agreement among 3 methods to measure corneal thickness: ultrasound pachymetry, Orbscan II, and Visante anterior segment optical coherence tomography. *Ophthalmology* 114:1842–1847
- Rosa N, Lanza M, Borrelli M, Polito B, Filosa ML, De Bernardo M (2007) Comparison of central corneal thickness measured with Orbscan and Pentacam. *J Refract Surg* 23:895–899
- Cairns G, McGhee CN (2005) Orbscan computerized topography: attributes, applications, and limitations. *J Cataract Refract Surg* 31:205–220. doi:10.1016/j.jcrs.2004.09.047
- Kim HY, Budenz DL, Lee PS, Feuer WJ, Barton K (2008) Comparison of central corneal thickness using anterior segment optical coherence tomography vs ultrasound pachymetry. *Am J Ophthalmol* 145:228–232. doi:10.1016/j.ajo.2007.09.030
- Wong AC, Wong CC, Yuen NS, Hui SP (2002) Correlational study of central corneal thickness measurements on Hong Kong Chinese using optical coherence tomography, orbscan and ultrasound pachymetry. *Eye* 16:715–721. doi:10.1038/sj.eye.6700211
- Suzuki S, Oshika T, Oki K, Sakabe I, Iwase A, Amano S, Araie M (2003) Corneal thickness measurements: scanning-slit corneal topography and noncontact specular microscopy versus ultrasonic pachymetry. *J Cataract Refract Surg* 29:1313–1318. doi:10.1016/S0886-3350(03)00123-8
- McLaren JW, Nau CB, Erie JC, Bourne WM (2004) Corneal thickness measurement by confocal microscopy, ultrasound, and scanning slit methods. *Am J Ophthalmol* 137:1011–1020. doi:10.1016/j.ajo.2004.01.049
- Fujioka M, Nakamura M, Tatsumi Y, Kusuhara A, Maeda H, Negi A (2007) Comparison of Pentacam Scheimpflug camera with ultrasound pachymetry and noncontact specular microscopy in measuring central corneal thickness. *Curr Eye Res* 32:89–94. doi:10.1080/02713680601115010
- Brandt JD (2004) Corneal thickness in glaucoma screening, diagnosis, and management. *Curr Opin Ophthalmol* 15:85–89. doi:10.1097/00055735-200404000-00004
- Behki R, Damji KF, Crichton A (2007) Canadian perspectives in glaucoma management: the role of central corneal thickness. *Can J Ophthalmol* 42:66–74. doi:10.3129/canjophthalmol.06-108
- Pinero DP, Plaza AB, Alio JL (2008) Anterior segment biometry with 2 imaging technologies: very-high-frequency ultrasound scanning versus optical coherence tomography. *J Cataract Refract Surg* 34:95–102. doi:10.1016/j.jcrs.2007.08.033