

# Foreign Body Granulomas of the Breast Presenting as Bilateral Spiculated Masses

Boo-Kyung Han, MD<sup>1</sup>  
Yeon Hyeon Choe, MD<sup>1</sup>  
Young-Hyeh Ko, MD<sup>2</sup>  
Seok-Jin Nam, MD<sup>3</sup>  
Jung-Hyun Yang, MD<sup>3</sup>

In Asia, mammography following the injection of foreign materials into the breasts for cosmetic augmentation is frequently seen and diagnosis based on the typical radiologic findings is straightforward.

We report the unusual radiologic findings in two patients with foreign body granulomas caused by injected foreign materials and discovered incidentally during screening work up. The mammographic findings were bilateral, hyperdense, spiculated masses, with occasional microcalcification, and at sonography, markedly hypoechoic, spiculated solid masses, located near the pectoralis muscle and partly extending into it, were observed. These radiologic findings mimicked malignancy.

## Index terms :

Breast, abnormalities  
Breast radiography

## Korean J Radiol 2001 ; 2 : 113-116

Received October 6, 2000; accepted after revision February 9, 2001.

Departments of <sup>1</sup>Radiology, <sup>2</sup>Pathology and <sup>3</sup>General Surgery, Samsung Medical Center, Sungkyunkwan University School of Medicine.

## Address reprint requests to:

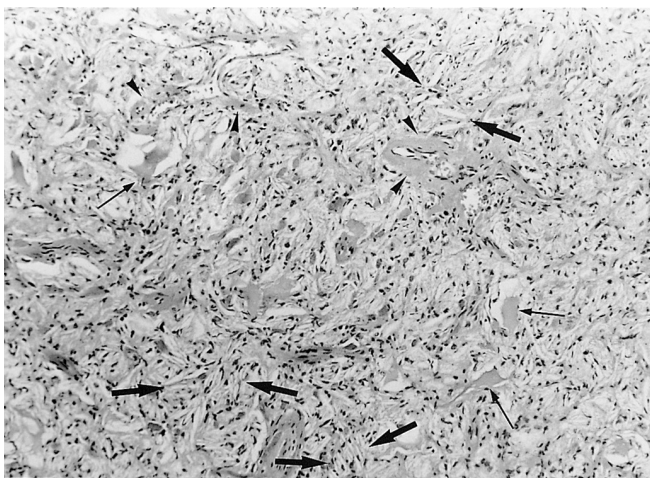
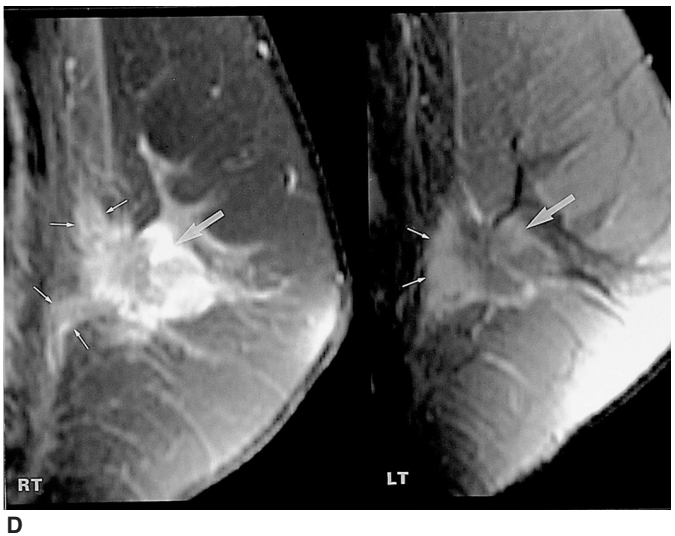
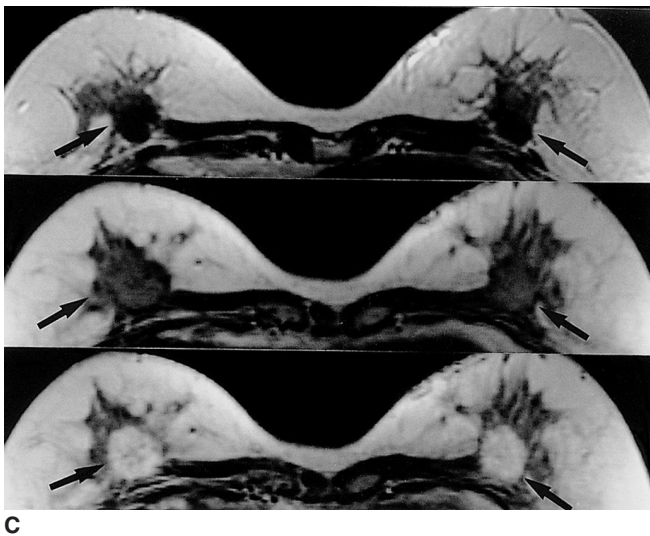
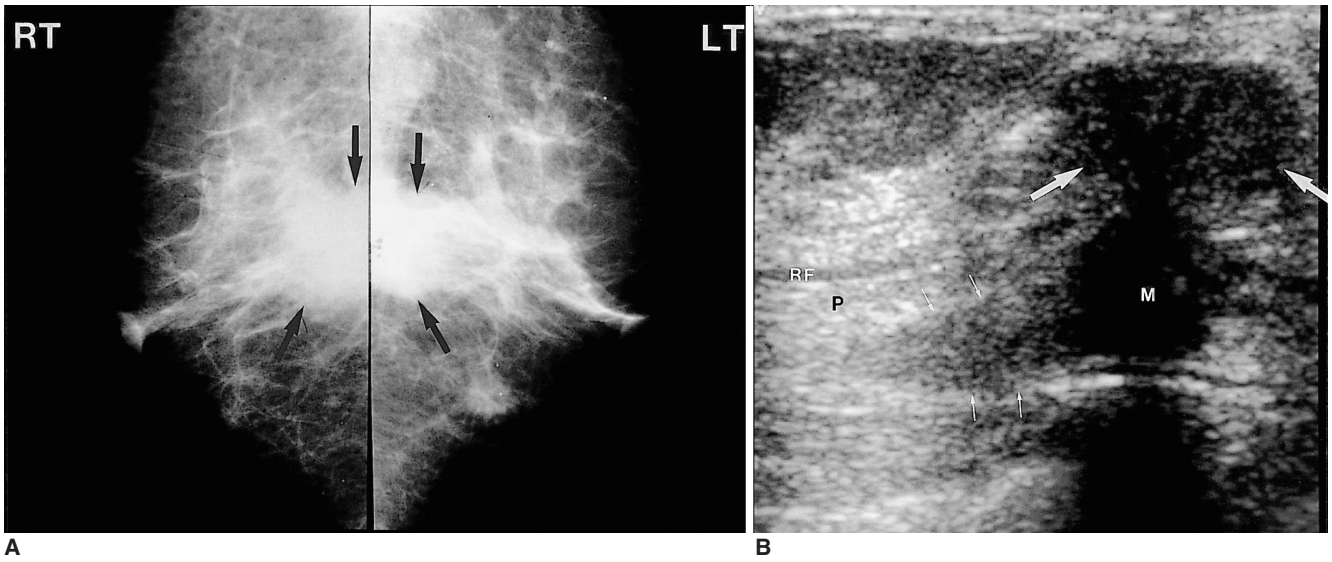
Boo-Kyung Han, MD, Department of Radiology, Samsung Medical Center, Sungkyunkwan University School of Medicine, 50 Ilwon-dong, Kangnam-gu, Seoul 135-710, Korea.  
Telephone: (822) 3410-2518  
Fax: (822) 3410-2559  
e-mail: bkhan@smc.samsung.co.kr

**A** spiculated margin of a mass, as demonstrated by mammography, is recognized as the most significant indicator of breast malignancy. Spiculated margins can, however, also be encountered in benign lesions such as a radial scar, fat necrosis, postoperative scar, sclerosing adenosis, granular cell tumor, and desmoid. Although several morphologic criteria such as long spicules without a central mass suggest the presence of a rare benign spiculated lesion, unequivocal diagnosis nonetheless requires a biopsy (1). We report another rare benign lesion which can present as a spiculated mass.

## CASE REPORTS

### Case 1

Physical examination of a 61-year-old woman who presented for breast screening revealed a poorly defined mass in the central portion of the left breast. The patient had no risk factors for breast cancer and no history of breast disorder. Mammography demonstrated that in the central posterior portion, bilateral ill-defined masses were present (Fig. 1A), and sonography revealed that in both subareolar portions, 2-cm masses, each showing posterior shadowing and heterogeneous echogenicity, extended into the pectoralis muscle (Fig. 1B). The radiologic diagnosis was bilateral breast cancer. MR imaging revealed the presence of centrally located masses in the posterior glandular and retroglandular region of both breasts. Fat-suppressed T2- and T1-weighted spin-echo images demonstrated low signal intensity, and 1 min after the administration of gadolinium-DTPA (0.1 mmol/kg body weight; Schering, Berlin, Germany), diffuse enhancement was noted (Fig. 1C). Eight minutes after contrast enhancement, a peripherally enhanced mass extending into the pectoralis muscle was noted in both breasts (Fig. 1D). Sonographically guided core biopsy using a 14-gauge needle led to a pathologic diagnosis of cholesterol granulomas in both breasts, though



**Fig. 1.** 61-year-old woman with foreign body granuloma of the breast.

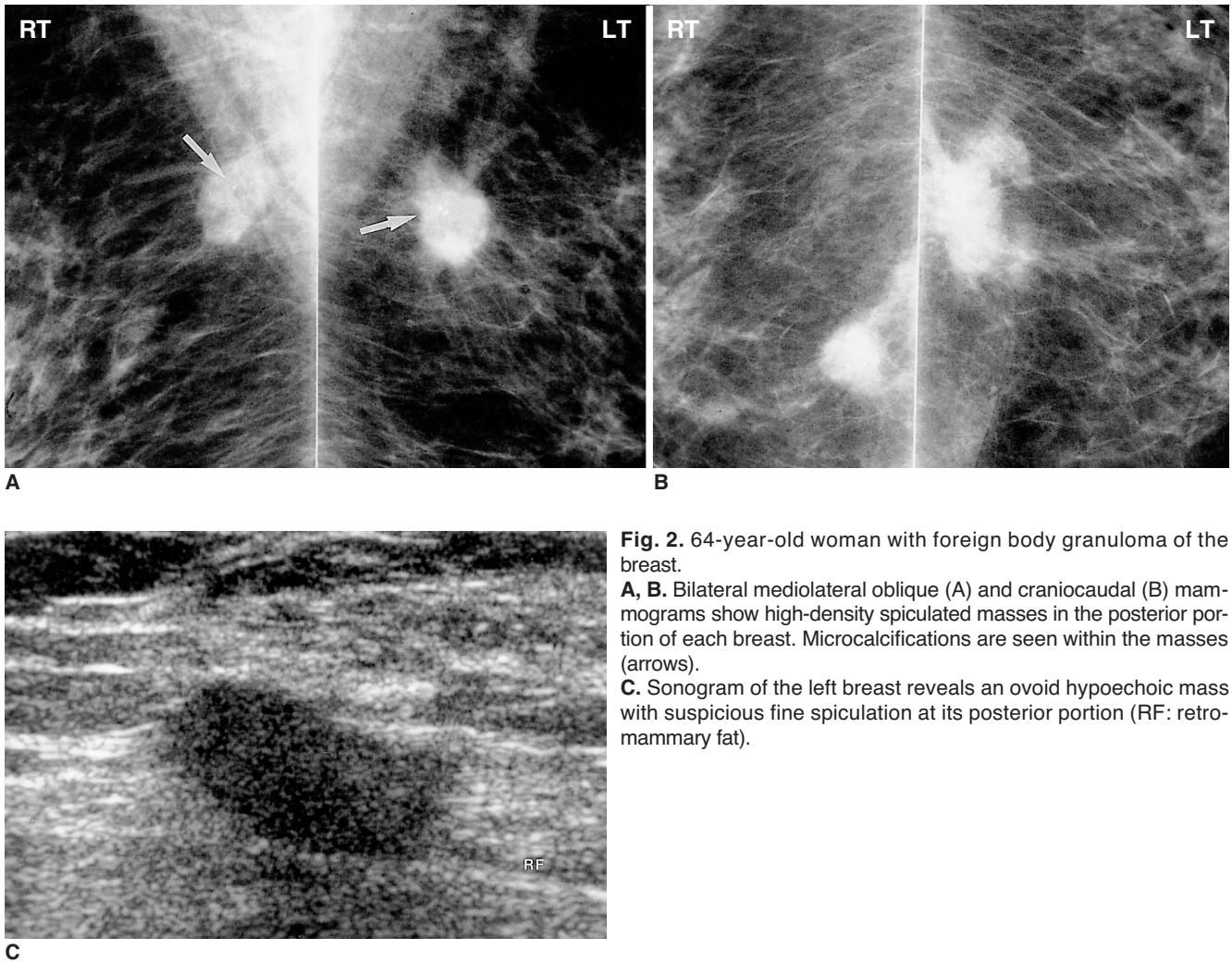
**A.** Bilateral mediolateral oblique mammograms show ill-defined masses with some spiculation in the central posterior portion of both breasts (arrows).

**B.** Sonogram of the right breast shows a markedly lobulated, heterogeneously hypoechoic mass in the subareolar portion (large arrows) and extending into the pectoralis muscle (small arrows). A sonogram of the left breast revealed similar features (not shown) (M: retroglanular portion of the mass; P: pectoralis muscle; RF: retromammary fat).

**C.** Axial, fat-saturated, T2-weighted fast spin-echo images (TR/TE, 4383/102, upper), two-dimensional spoiled gradient-echo images before (76/3.3, middle) and 1 min after gadolinium enhancement (lower) show bilateral, spiculated, low-signal intensity masses with early enhancement (arrows) in the posterior central portion of the breasts (arrows).

**D.** Sagittal T1-weighted images with fat saturation 8 mins after gadolinium enhancement (550/10) show spiculated masses in both breasts (large arrows) extending into the pectoralis muscle (small arrows). Note the delayed peripheral enhancement of the masses.

**E.** Photomicrograph of histologic specimen shows cholesterol clefts, seen as needle-like empty spaces (large arrows), secretory materials in luminal structures (small arrows) and perivascular fibrosis (arrowheads) (H and E,  $\times 100$ ).



**Fig. 2.** 64-year-old woman with foreign body granuloma of the breast.

**A, B.** Bilateral mediolateral oblique (A) and craniocaudal (B) mammograms show high-density spiculated masses in the posterior portion of each breast. Microcalcifications are seen within the masses (arrows).

**C.** Sonogram of the left breast reveals an ovoid hypoechoic mass with suspicious fine spiculation at its posterior portion (RF: retro-mammary fat).

the patient denied that any breast injection procedure had occurred. Because of strong radiological suspicion, however, open biopsy of the right breast was performed. Pathologically, the mass was found to consist primarily of granulomatous tissue containing cholesterol clefts and collagen (Fig. 1E), and the final pathologic diagnosis was foreign body granuloma. She then admitted that foreign materials had been injected directly into her breasts about twenty years earlier.

### Case 2

A 64-year-old woman presented for breast screening, and palpation revealed no abnormality. Mammography, however, demonstrated the bilateral presence of spiculated masses with microcalcifications at the left upper central and right upper inner quadrant (Figs. 2A, B). The masses were located in the posterior portion of the breasts near the pectoralis muscle, and sonography revealed that both were hypoechoic and posterior shadowing (Fig. 2C). By means of core needle showed biopsy, the presence of cho-

lesterol granulomas was pathologically confirmed. Sonography-guided needle localization and excisional biopsy were performed for both lesions, and in both, the pathologic result was foreign body granuloma. Many years earlier, paraffin had been injected directly into her breasts for augmentation.

### DISCUSSION

We have described the unusual mammographic and sonographic findings of foreign body granuloma of the breasts arising after the injection of unknown foreign materials and presenting at screening mammography as bilateral spiculated masses. It has been reported that at mammography, foreign body reactions can appear as calcifications or a mass which simulates malignancy due to its partially circumscribed or ill-defined margin (2–4). Reported foreign matter has included suture materials, carbon particles used for the localization of a nonpalpable breast lesion, and gunpowder. In both our cases, bilateral spiculated masses were

observed at presentation; in one case there were associated microcalcifications within the mass, and malignancy was thus strongly suspected. Both patients had undergone direct injection of foreign materials into the breast for cosmetic purposes.

Several published reports have described the mammographic findings associated with the injection of foreign materials into the breasts. Silicone granulomas have been depicted as multiple rounded opaque masses (5), and paraffinomas as dense, streaky opacities causing bizarre architectural distortion and, often, amorphous ring calcifications (6). Both types of granuloma often involve the whole breast diffusely. At mammography, silicone granulomas or paraffinomas can be diagnosed easily, without the need for histologic diagnosis. Our cases are unique in that the granuloma appeared as a single spiculated mass, present in both breasts. One patient (case 2) told us that the injected material had been paraffin, but the other (case 1) did not remember the kind of injected material. Although the direct injection of silicone or paraffin is illegal, the technique has been used for breast augmentation for several decades. The peculiar finding in our cases may be interpreted as the result of various illegal injection methods. This is the first published case report in which mammography revealed a foreign body granuloma as a single spiculated bilateral mass. In case 1, the patient initially denied having injected her breasts with foreign material, and at first, correct diagnosis was thus not possible. Because such injection is illegal, patients often conceal the fact that it has occurred.

Histological examination revealed groups of cholesterol crystals encased by histiocytes and giant cells, with surrounding granulomatous zones of histiocytes, lymphocytes and plasma cells, and a fibroblastic reaction, similar to that seen in cholesterol granuloma. Cholesterol granulomas occur most commonly in the middle ear and mastoid process, resulting from a foreign body response to cholesterol crystals which involved local tissue breakdown or blood (7). In the breast, cholesterol granuloma can develop as the late sequela of mammary duct ectasia (8, 9).

Sonography revealed that in our cases, deeply located hypoechoic masses were present, and one had invaded the pectoralis muscle, which is unusual even in malignancy. MR imaging of the mass in case 1 demonstrated low signal intensity on T1- and T2-weighted spin-echo images and rapid enhancement, as would be expected with cancers. Delayed images, however, showed peripheral enhancement and central washout, a centrifugal enhancement pattern, in other words, and one not observed in cancers (Fig. 1D). Generally, breast cancers enhance from the periphery to the center, and there is peripheral washout (10). Our cases, in which the histopathologic findings indicated the

presence of a fibrotic mass, were also different from those in which fibrosis occurs in an irradiated breast, in which enhancement is not observed (11). A large number of vessels surrounded by fibrosis might explain the enhancement observed after gadolinium administration (Fig. 1E).

The signal intensity of the paraffin-containing round component has been reported as characteristically low on both T1- and T2-weighted images and is markedly suppressed on fat-suppression images (6). The signal intensity of silicone is reported to be low on T1-weighted images but high on STIR images (5). In our cases, however, because histopathologic examination showed that the mass consisted primarily of fibrosis and cholesterol clefts, with no identifiable oily materials, the low signal intensity observed on all spin-echo images seems to be due to fibrosis.

We have described this unusual manifestation of a benign lesion developed in reaction to a foreign body. Mammography and sonography both indicated that the bilateral spiculated masses were located in the posterior portion of the breast. Although the imaging findings strongly suggested malignancy, preoperative histologic confirmation by means of large core-needle biopsy helped prevent unnecessary radical mastectomy and led to appropriate treatment.

## References

1. Kopans DB. *Breast Imaging*, 2nd ed. Philadelphia : Lippincott-Raven, 1997:302-305
2. Rosenberg RF, Siegelman SS. Foreign-body granuloma simulating carcinoma on mammography. *N Y State J Med* 1976;76:445-446
3. Wakabayashi M, Reid JD, Bhattacharjee M. Foreign body granuloma caused by prior gunshot wound mimicking malignant breast mass. *AJR* 1999;173:321-322
4. Patrikeos A, Wylie EJ, Bourke A, Frost F. Imaging of carbon granulomas of the breast following carbon track localization. *Clin Radiol* 1998;53:845-848
5. Helbkch TH, Wunderbaldinger P, Plenk H, et al. The value of MRI in silicone granuloma of the breast. *European J Radiol* 1997; 24:155-158
6. Khong PL, Ho LWC, Chan JHM, Leong LLY. MR imaging of breast paraffinomas. *AJR* 1999; 173:929-932
7. Som PM, Curtin HD, eds. *Head and Neck Imaging*, 3rd ed. St. Louis: Mosby-Year Book, 1996: 1396-1398
8. Wilhelmus JL, Schrodt GR, Mahaffey LM. Cholesterol granulomas of the breast : a lesion which clinically mimics carcinoma. *Am J Clin Pathol* 1982; 77:592-597
9. Reynolds HE, Crame HM. Cholesterol granuloma of the breast: a mimic of carcinoma. *Radiology* 1994; 191: 249-250
10. Newstead GM, Weinreb JC. Critical pathways for the future: MR imaging and digital mammography. *RadioGraphics* 1995; 15(4):951-962
11. Dao TH, Rahmouni A, Campana F, et al. Tumor recurrence versus fibrosis in the irradiated breast: differentiation with dynamic gadolinium-enhanced MR imaging. *Radiology* 1993; 187(3):751-755