

Anatomical Abnormalities of the Anterior Cingulate Cortex in Schizophrenia: Bridging the Gap Between Neuroimaging and Neuropathology

Alex Fornito^{1,2}, Murat Yücel^{2,3}, Brian Dean^{4–6}, Stephen J. Wood², and Christos Pantelis^{2,7}

²Melbourne Neuropsychiatry Centre, Department of Psychiatry, The University of Melbourne, Victoria, Australia; ³ORYGEN Research Centre, Department of Psychiatry, The University of Melbourne, Victoria, Australia; ⁴The Rebecca L Cooper Research Laboratories, The Mental Health Research Institute, Parkville, Victoria, Australia; ⁵Departments of Pathology and Psychiatry, The University of Melbourne, Victoria, Australia; ⁶Department of Psychological Medicine, Monash University, Victoria, Australia; ⁷Howard Florey Institute, The University of Melbourne, Victoria, Australia

The anterior cingulate cortex (ACC) is a functionally heterogeneous region involved in diverse cognitive and emotional processes that support goal-directed behaviour. Structural magnetic resonance imaging (MRI) and neuropathological findings over the past two decades have converged to suggest abnormalities in the region may represent a neurobiological basis for many of the clinical manifestations of schizophrenia. However, while each approach offers complimentary information that can provide clues regarding underlying pathophysiological processes, the findings from these 2 fields are seldom integrated. In this article, we review structural neuroimaging and neuropathological studies of the ACC, focusing on the unique information they provide. The available imaging data suggest grey matter reductions in the ACC precede psychosis onset in some categories of high-risk individuals, show sub-regional specificity, and may progress with illness duration. The available post-mortem findings indicate these imaging-related changes are accompanied by reductions in neuronal, synaptic, and dendritic density, as well as increased afferent input, suggesting the grey matter differences observed with MRI arise from alterations in both neuronal and non-neuronal tissue compartments. We discuss the potential mechanisms that might facilitate integration of these findings and consider strategies for future research.

Key words: psychosis/neuron/VBM/glia/limbic/prefrontal

¹To whom correspondence should be addressed; Melbourne Neuropsychiatry Centre, Levels 2 and 3, National Neuroscience Facility, 161 Barry St, Carlton South, Vic 3053, Australia; tel: + 61-3-8344-1861, fax: + 61-3-9348-0469, email: fornitoa@unimelb.edu.au.

Neurobiological research has been critical in identifying the brain regions involved in the pathogenesis of schizophrenia, implicating several structures extending across limbic, frontal, temporal, and subcortical areas.^{1–5} One brain region commonly reported to show abnormal structure and function in patients with the disorder is the anterior cingulate cortex (ACC), an area crucial for integrating cognitive and emotional processes in support of goal-directed behaviour.^{6–10} The functional diversity of the ACC, which encompasses executive, social cognitive, affective, and skeleto- and visceromotor functions,^{6,11–17} suggests that abnormalities in the region may partly explain the difficulties in cognitive and emotional integration that characterize the clinical manifestations of schizophrenia.^{15,18}

Both neuropathological and neuroimaging findings support a role for ACC dysfunction in schizophrenia. Neuropathological research has revealed alterations in the cellular and synaptic architecture of the region,^{19,20} while imaging work has identified ACC abnormalities that correlate with the disorder's characteristic symptoms and cognitive deficits,^{21,22} and which ameliorate with treatment response.^{23,24} However, the precise ACC sub-region affected, and the nature of the underlying changes, has varied across these reports, making it difficult to discern their pathophysiological significance. Moreover, while both neuroimaging and neuropathological approaches offer complimentary information, their findings are seldom integrated systematically, making it unclear how changes in cell density or synaptic morphology relate to volumetric differences identified with imaging.

In this article, we review magnetic resonance imaging (MRI) and neuropathological studies of the ACC in schizophrenia in an attempt to understand the pathological processes underlying the changes observed with in vivo imaging. Our discussion is organized around key questions that speak to the particular strengths of the 2 approaches. For neuroimaging research, we ask whether there is evidence of (1) regionally specific abnormalities, (2) abnormalities predating illness onset, and (3) variation in the abnormalities across different illness stages. For neuropathological work, we ask whether the evidence (1) supports the existence of volumetric changes in the ACC, (2) supports the occurrence of

cell loss in the ACC of schizophrenia patients, and (3) identifies changes in the intercellular neuropil. We then discuss the influence of psychotropic treatment on the findings, before providing a synthesis and consideration of their implications for uncovering underlying pathophysiological mechanisms. We primarily discuss structural MRI research and neuropathological studies of cell counts and cortical, axonal, dendritic, and cellular morphology, as these data are the most comparable, although we draw on other relevant literature where necessary. Rather than propose a definitive unitary pathophysiological process, we use the available data to stimulate discussion regarding which mechanisms might be most useful in integrating findings from these diverse fields. We begin with a brief overview of ACC anatomy and function.

Structure and function of the anterior cingulate cortex

Located bilaterally in the medial frontal lobes, the ACC comprises the cytoarchitectonic areas 24/24' and 32/32', with area 25, commonly called the subgenual cingulate,²⁵ located posterior to the subcallosal extension of area 24, ventral to the genu. Areas 24'/32' are located dorsal to the corpus callosum, while areas 24/32 occupy a pregenual position.²⁶ Areas 32 and 32' have been termed transition cortex because they possess cytoarchitectonic features common to areas 24/24' and adjacent frontal regions.²⁶ Other authors have labeled areas 32/32' as paralimbic, or paracingulate, cortex and areas 24/24' as limbic ACC due to the latter's denser connections with emotional centres.⁶ The relative location and size of these regions change in accordance with variability in sulcal and gyral anatomy. In particular, the paracingulate sulcus (PCS), which is present in 30%–60% of cases and runs dorsal and parallel to the cingulate sulcus (CS),^{27,28} is associated with a relative expansion of area 32, such that it extends from the depths of the CS across the crown of the paracingulate gyrus that forms between the CS and PCS, contrasting its location on the dorsal bank of the CS when a PCS is absent.²⁶ This variability has functional consequences^{29–34} and is an important consideration when interpreting morphometric studies of the region, as discussed below. Figure 1 presents a simplified illustration of how the major cytoarchitectonic fields vary as a function of PCS variability.

Several meta-analyses of functional MRI (fMRI) and positron emission tomography (PET) studies have demonstrated that cognitive paradigms tend to elicit activation in dorsal areas 24'/32', whereas affective tasks produce increased activation in rostral areas 24/32, a distinction that parallels the greater connectivity between these rostral areas and limbic structures.^{12,14,17,35} Within the rostral ACC, activation during negative emotional conditions tends to localize within the subcallosal extension of area 24 and the adjacent area 25, while positive emotions

elicit activations in the pregenual portion of area 24, supporting a further functional distinction.¹⁷ Evidence of functional dissociations between areas 24 and 32, and 24' and 32', are also being uncovered,^{7,36} consistent with differences in their functional connectivity with other brain regions.^{37,38} Some evidence suggests certain paralimbic areas mediate self-reflective and social cognitive processes,^{14,39,40} although the precise nature of functional specialization in this region remains unclear. Broadly however, such findings suggest the ACC may be grossly partitioned into limbic (ACC_L) and paralimbic (ACC_P) regions, each containing dorsal, rostral, and subcallosal divisions (see figure 1). There is also evidence for a caudal division involved in motor control,¹⁶ but it will not be considered further in this discussion. (For further details regarding ACC functional specialization, see ^{6–9,11,12,14,17,41,42}.)

Structural magnetic resonance imaging research

Are changes in the ACC regionally specific?

Structural MRI studies have used 2 approaches to investigating neuroanatomical changes in patients with schizophrenia. One, the region-of-interest (ROI) method, involves manual delineation of the ACC on each scan, with morphometric parameters such as gray matter volume calculated secondarily. The second, commonly termed voxel-based morphometry (VBM), is an automated technique that involves spatial normalization of each participant's scan to a common stereotactic space, followed by voxelwise statistical comparison of group differences in gray matter measures. This has provided an attractive alternative to the ROI methodology because it affords a relatively unbiased assessment of gray matter changes across the entire brain, although errors in spatial normalization, particularly in morphologically variable regions such as the ACC, can complicate interpretation of findings.^{43–45} We collectively refer to reports using one of the several variants of this technique^{46–50} as whole-brain mapping (WBM) studies from hereon.

The findings of cross-sectional WBM studies investigating anatomical changes in the ACC of patients with schizophrenia are summarized in table 1, and stereotactic foci representing regions of maximal gray matter change reported in these studies are plotted in figure 2. The results suggest ACC gray matter reductions in schizophrenia are dispersed across dorsal and rostral divisions of the limbic and paralimbic regions, with few differences being noted in the subcallosal area. One-third (13/39) of WBM studies failed to identify any significant differences in ACC grey matter.

Results obtained using the ROI approach are summarized in table 2. Studies examining the entire anterior cingulate gyrus (ie, the ACC_L) have been variable, reporting right-sided,^{51,52} bilateral,^{53–59} or no group

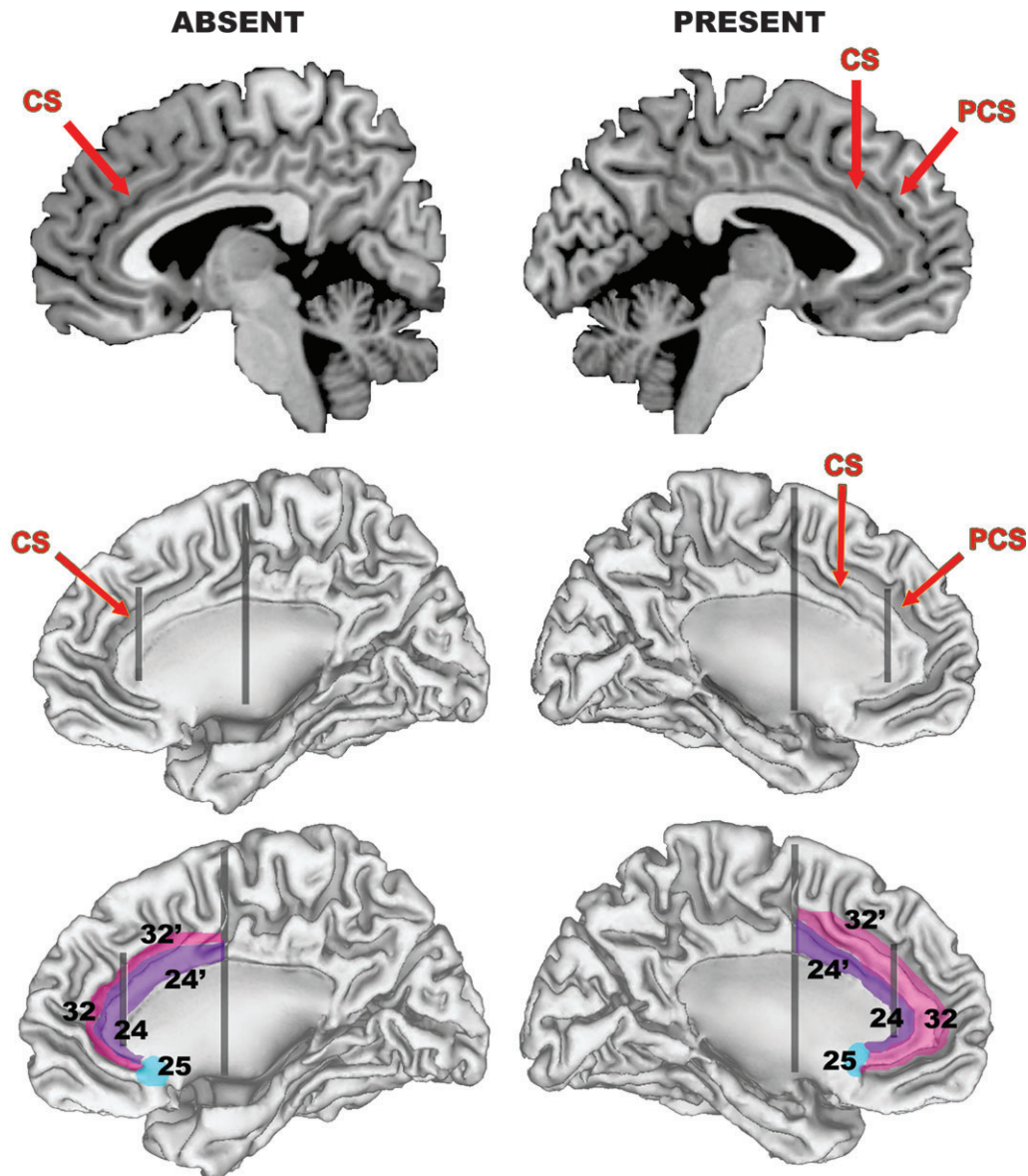


Fig. 1. Simplified Illustration of How Anterior Cingulate Cortex (ACC) Cytoarchitecture is Altered by Variations in Morphology of the Paracingulate Sulcus (PCS). Top row presents a sagittal slice through the left (right column) and right (left column) hemisphere of the N27 template,¹⁷⁹ which provides a good example of a “present” and “absent” PCS. Middle row illustrates the locations of the PCS and cingulate sulcus (CS) on cortical surface reconstructions generated from the N27 template using freely available software (<http://brainmap.wustl.edu/caret>). The surfaces run midway through the thickness of the cortical ribbon, facilitating visualization inside the sulcal walls. Bottom row illustrates how major cytoarchitectonic fields in the area are altered by PCS variability. The posterior vertical black line approximates the caudal border of what is termed the dorsal division of the ACC, and the anterior vertical black line approximates the border between areas 24/32 and 24'/32'. Note how areas 32/32' extend across the crown of the paracingulate gyrus when a PCS is present, in contrast to being buried in the depths of the CS when the PCS is absent. The purple area corresponds to what is termed the limbic ACC, the pink area to the paralimbic ACC. The borders are only intended as a rough approximation of their actual location.

differences.^{21,60–62} Similarly, those focusing on the dorsal ACC_L have found either left-sided⁶³ or right-sided^{64,65} reductions or no group differences.^{66–68} Studies of the rostral ACC have been more consistent, with most finding no gray matter differences,^{63,65,67–69} although one found a left lateralized thickness increase that was positively correlated with years of antipsychotic treatment.⁷⁰ Relatively few (4/28) ROI studies have examined the

subcallosal ACC, with no significant differences reported.^{52,68,71,72}

Only 3 ROI studies have separately parcellated the ACC_P. The first⁵³ found bilateral volumetric reductions in the region to be among the largest seen across 48 ROIs in patients with established schizophrenia. The second⁷³ found a right-sided reduction in a first-episode (FE) sample but not patients with established schizophrenia. In the

Table 1. Details of Voxel-Based, Whole-Brain Mapping Studies in Schizophrenia

Study	Sample (No. of males)	Method (Measure)	Stereotactic Coordinates (x, y, z) ^a
Wright <i>et al</i> ¹⁸⁰	15 (15) SZ; 15 (15) CON	SPM96 _T (GMC)	Nil
Sowell <i>et al</i> ¹⁸¹	9 (3) COS; 10 (2) CON	Customized SPM96 (GMC)	Nil
Foong <i>et al</i> ¹⁸²	25 (19) SZ; 30 (22) CON	SPM 96 _T (MTR, PD)	Nil
Hulshoff Pol <i>et al</i> ¹⁸³	159 (112) SZ; 158 (106) CON	MNI (GMC)	Nil
Paillere-Martinot <i>et al</i> ¹⁸⁴	20 (20) SZ; 20 (20) CON	SPM96 _T (GMC)	-8 56 10; -6 39 -12
Sigmundsson <i>et al</i> ¹⁸⁵	27 (26) SZ; 27 (25) CON	BAMM (GMC)	-0.5 46 1
Wilke <i>et al</i> ¹⁸⁶	48 (27) SZ; 48 (27) CON	SPM99 _T (GMC)	Nil
Ananth <i>et al</i> ¹⁸⁷	20 (10) SZ; 20 (10) CON	SPM99 _T (GMV)	Nil
Job <i>et al</i> ^{188 c}	34 (17) FE SZ; 36 (23) CON	SPM99 _O (GMC)	3.96 40.87 1.64
Kubicki <i>et al</i> ¹⁸⁹	16 (14) FE SZ; 18 (16) CON	SPM99 _T (GMC)	-6 2 40; 9 14 33
Shapleske <i>et al</i> ¹⁹⁰	72 (72) SZ; 32 (32) CON	BAMM (GMC)	3 -4 4 ^b
Suzuki <i>et al</i> ¹⁹¹	45 (23) SZ; 42 (22) CON	SPM96 _T (GMC)	4 30 28
Bagary <i>et al</i> ¹⁹²	30 (19) FE SZ; 30 (18) CON	SPM99 _O (MTR, GMC, GMV)	-4 40 12; -3 33 17; -1 25 22; 1 37 17; 2 38 12 (differences observed for MTR but not GMV or GMV)
Kuperberg <i>et al</i> ¹⁹³	33 (26) SZ; 32 (27) CON	SBM (GMT)	Left r-ACC _L /r-ACC; Right d-, r-, & s-ACC _L /ACC _P
Marcelis <i>et al</i> ¹⁹⁴	31 (15) SZ; 27 (12) CON	BAMM (GMC)	0.5 17.2 42.2
Salgado-Pineda <i>et al</i> ¹⁹⁵	13 (13) Neuroleptic-naïve FE SZ; 13 (13) CON	SPM99 _T (GMC)	9 24 33; 10 32 25
Hyon Ha <i>et al</i> ¹⁹⁶	35 (21) SZ; 35 (21) CON	SPM99 _T (GMC)	0 42 14; 4 50 -8 ^b ; 2 9 -12 ^b
Kawasaki <i>et al</i> ⁸⁶	25 (14) SZ; 50 (28) CON	SPM99 _T (GMC)	-2 57 8; -1 54 19; -1 36 26; 4 44 24; 1 54 6; 2 22 41
McIntosh <i>et al</i> ⁷⁷	26 (13) familial SZ; 49 (23) CON	SPM99 _O (GMC)	Nil
Moorhead <i>et al</i> ^{197 d}	25(14) SZ; 29(14) CON	SPM99 _{O&T} (GMC & GMV)	5 9 30 (differences observed for GMV, but not GMC)
Salgado-Pineda <i>et al</i> ¹⁹⁸	14(7) SZ; 14(7) CON	SPM2 _O (GMV)	-08 10 35; 10 -01 40
Antonova <i>et al</i> ¹⁹⁹	45(27) SZ; 43(25) CON	SPM99 _O (GMC)	Nil
Davatzikos <i>et al</i> ²⁰⁰	69(46) SZ; 79(41) CON	RAVENS (GMV)	Bilateral d-ACC _L /ACC _P , s-ACC _L /ACC _P
Farrow <i>et al</i> ⁸⁹	25(18) FE SZ; 22(13) CON	SPM99 _O (GMC)	-8 39 15; -3 55 -12
Jayakumar <i>et al</i> ²⁰¹	18(9) FE SZ; 18(9) CON	SPM2 _O (GMV)	Nil
McDonald <i>et al</i> ²⁰²	25(18) SZ; 52(24) CON	SPM99 _O & BAMM (GMV)	34 44 -8 ^b
Narr <i>et al</i> ²⁰³	72(37) FE SZ; 78(51) CON	CPM (GMT)	L r-ACC _L /ACC _P ; R d-ACC _L /ACC _P
Suzuki <i>et al</i> ⁵⁵	4(3) Simple SZ; 20(10) CON	SPM99 _T (GMC)	Nil
Whitford <i>et al</i> ²⁰⁴	31(20) FE SZ; 30(20) CON	SPM99 _O (GMV)	Nil
Necklemann <i>et al</i> ²⁰⁵	12(n/a) SZ; 12(n/a) CON	SPM99 _O (GMC)	Nil
Ohnishi <i>et al</i> ²⁰⁶	47(24) SZ; 76(30) CON	SPM2 TBM (GMV)	9 33 20; -11 32 20; -12 -16 39
Park <i>et al</i> ²⁰⁷	16 SZ; 16 CON	SBM (GMT)	Left r-ACC
Vidal <i>et al</i> ¹⁴¹	12(6) COS; 12(6) CON	CPM (GMC)	Bilateral d- & r-ACC _P
Whitford <i>et al</i> ⁹⁰	41(26) FE SZ; 47(33) CON	SPM2 _O (GMC)	-11 36 17
Chua <i>et al</i> ²⁰⁸	26(12) med-free FE SZ; 38(18) CON	BAMM (GMC)	2.6 14 1 ^b
Kašpárek <i>et al</i> ²⁰⁹	22(22) FE SZ; 18(18) CON	SPM2 _O (GMV)	2 20 64 ^b
Kawasaki <i>et al</i> ²¹⁰	30(16) SZ; 30(16) CON	SPM2 _O (GMC)	-3 33 21; 7 38 25; 6 50 11

Table 1. Continued

Study	Sample (No. of males)	Method (Measure)	Stereotactic Coordinates (x, y, z) ^a
Pagsberg et al ²¹¹	29(11) COP; 29(25) CON	SPM99 _O (GMV)	Nil
Yamada et al ²¹²	20(10) SZ; 20(10) CON	SPM2 _O (GMC and GMV)	5 56 -3; 2 7 -6 (differences observed for GMC but not GMV)

Note: Studies were published before September 2007 and identified using the online PubMed database using the following search terms: schiz* (or psychosis) and VBM; schiz* (or psychosis) and SPM; schiz* (or psychosis) and voxel; schiz* (or psychosis) and MRI. Listed results are for gray matter comparisons only. SZ = schizophrenia; CON = control; COP = childhood-onset psychosis; COS = childhood-onset schizophrenia; FE = first episode; GMC = gray matter density; GMD = gray matter density; GMT = gray matter thickness; MTR = magnetic transfer ratio; PD = proton density; TBM = tensor-based morphometry; SBM = surface-based morphometry, as implemented in Freesurfer (surfer.nmr.mgh.harvard.edu); MNI = Montreal Neurological Institute (www.bic.mni.mcgill.ca); BAMB = Brain Activation and Morphological Mapping (www-bmu.psychiatry.cam.ac.uk/BAMB); CPM = Cortical Pattern Matching, as described by Thompson et al⁴⁷; RAVENS refers the approach described by Davatzikos et al⁴⁸; SPM96, SPM99, and SPM2, refer to the different versions of the Statistical Parametric Mapping software package (www.fil.ion.ucl.ac.uk/spm) used for data analysis. The subscript _T refers to the traditional method, whereas the subscript _O refers to the optimized approach (see ^{46, 213}). All foci represent areas of relative gray matter decreases in patients. ACC_L = limbic anterior cingulate cortex; ACC_P = paralimbic anterior cingulate cortex; the prefixes d-, r-, and s-, refer to dorsal, rostral, and subcallosal subdivisions, respectively.

^aCoordinates for the studies by Sigmundsson et al, Job et al, Shapleske et al, Marcelis et al, Salgado-Pineda et al,¹⁹⁵ Hyon Ha et al, Ohnishi et al, Whitford et al, and Chua et al, are in Talairach and Tourneoux²¹⁴ space. All other coordinates are in MNI space (see ²¹⁵). Verbal descriptions of regions showing significant differences are provided for studies that did not report stereotactic coordinates (there may be some ambiguity inherent in such descriptions, given that the figures did not always present slices optimum for visualizing medial frontal regions). Studies that did not report coordinates specifying significant differences in the ACC, did not verbally state that significant differences in these regions were identified, or did not display figures demonstrating change in these areas, were considered to show no differences.

^bThese foci were not near the ACC but formed part of a large cluster of significant voxels that extended into these regions. As such, they are not plotted in figure 2.

^cThese authors ran several patient-control comparisons to examine the effects of using different templates and covariates. We only included foci for what these authors termed their “primary” comparison (reported in table 2, p. 883 of their article).

^dThese authors ran several patient-control comparisons to examine the effects of using parametric vs non-parametric statistics, and to compare traditional and optimised VBM processing streams. We only retained parametric results for the traditional and optimised approach. These authors also published a second study using the same sample to investigate methodological effects. We only report on results from the first study here.

third, we found a bilateral reduction in thickness, but not volume or surface area, of the ACC_P extending across dorsal, rostral, and subcallosal subregions in FE patients,⁶⁸ with no differences being identified in limbic subregions.

In summary, most MRI studies suggest schizophrenia patients show reduced ACC gray matter, although the location of these changes has been variable. Generally, the reductions seem to extend across the dorsal and rostral ACC_L and ACC_P, with limited subcallosal involvement. Methodological differences, such as variations in ROI parcellation schemes or image pre-processing steps implemented in WBM research, likely contribute to these inconsistencies, as do variations in sample characteristics. An additional, major and often-neglected influence on the findings is variability in the incidence and extent of the PCS. As previously mentioned, PCS variability can alter the location and extent of paralimbic ACC,²⁶ with MRI studies suggesting its appearance can produce up to an 88% increase in ACC_P volume and 39% decrease in ACC_L volume.^{28,45} People with schizophrenia are less likely to show a PCS in the left hemisphere,^{56,74,75} suggesting that the results of ROI or WBM studies

will be biased unless the comparison groups are well matched for sulcal morphology. Our recent study of FE patients⁶⁸ attempted to control for this variability by matching patients and controls for PCS morphology.^{34,45} While our finding of reduced bilateral ACC_P thickness suggests that gray matter reductions in schizophrenia are not entirely attributable to group differences in sulcal and gyral anatomy, it needs to be replicated in independent samples.

Do anatomical changes in the ACC predate illness onset?

The question of whether neuroanatomical changes precede illness onset has typically been examined by studying individuals at elevated risk for schizophrenia to determine whether they show changes similar to those observed in affected probands. Cross-sectional studies of unaffected relatives of patients have yielded conflicting findings. Goghari et al,⁷⁶ using an ROI approach, found a bilateral reduction in ACC thickness in patients' relatives, in addition to a right-sided decrease in volume and surface area extending across the entire cingulate gyrus, although 2 earlier WBM studies failed to find any association

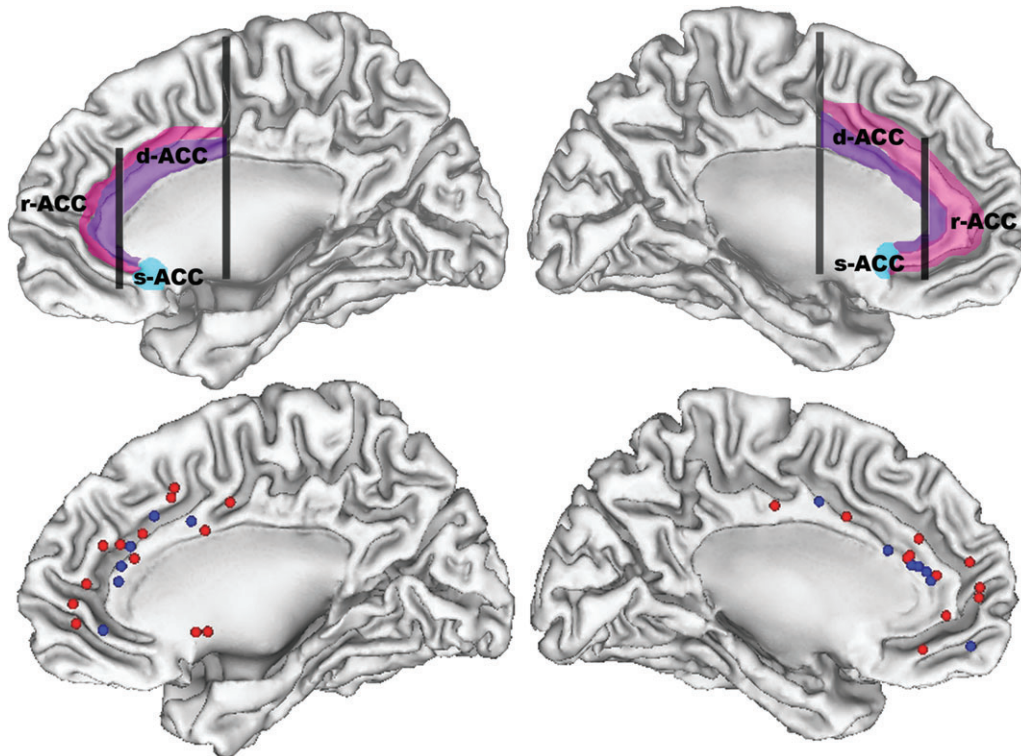


Fig. 2. Stereotactic Foci (Bottom Row) Representing Regions of Maximal Anterior Cingulate Cortex (ACC) Gray Matter Reductions Reported in Whole-Brain Mapping Studies of Schizophrenia. Blue foci correspond to differences between first-episode patients and controls, and red foci correspond to differences between patients with established schizophrenia and controls. Top row presents the same surfaces illustrating the approximate locations of the dorsal (d-ACC), rostral (r-ACC) and subcallosal (s-ACC) divisions of the anterior cingulate cortex. Limbic ACC is shown in purple and paralimbic ACC is in pink. Left hemisphere is presented on the right side.

between changes in ACC gray matter and genetic risk for schizophrenia.^{77–79} This discrepancy may partly reflect differences in the sensitivity of ROI and WBM methods for assessing ACC changes, as a WBM study by Job *et al.*⁸⁰ found reduced ACC gray matter in a sample of individuals at genetic risk for schizophrenia after restricting their analysis to this region (the differences did not emerge in a whole brain analysis). However, the unknown rate of illness transition in these samples makes it difficult to determine whether the findings reflect changes associated with imminent illness onset or a generalized at-risk status.

Studies incorporating a longitudinal component to ascertain the diagnostic outcome of their high-risk samples have yielded more consistent findings. The first such study applied WBM techniques to scans acquired in a group of individuals deemed to be at ultra-high risk (UHR) for psychosis onset⁸¹ based on a combination of state and trait criteria associated with a 30%–40% rate of transition to frank psychosis within 1 year.⁸² Comparing UHR individuals who did develop psychosis (UHR-P) with those who did not (UHR-NP) revealed reduced ACC gray matter in UHR-P individuals prior to psychosis onset, as well as longitudinal reductions in this region during the transition to psychosis that were

not apparent in the UHR-NP group. Independently, Borgwardt *et al.*⁸³ found reduced ACC gray matter in their UHR-P group (defined using similar criteria) when using uncorrected thresholds to account for their limited sample size. However, in a longitudinal study of individuals at genetic high risk, Job *et al.*⁸⁴ found no differences in ACC gray matter between those who did and those who did not subsequently become psychotic, despite there being ACC gray matter reductions in the high-risk sample as a whole at baseline.⁸⁰ Job *et al.*⁸⁴ also found no ACC differences in a small subgroup ($n = 8$) who eventually developed schizophrenia. The discrepancy in these findings suggests that prepsychotic ACC abnormalities may vary depending on whether individuals are at elevated risk for genetic or nongenetic reasons because a positive family history was not necessary for inclusion in the UHR samples.

We have recently examined ACC morphometry in the largest cohort of high-risk people making the transition to psychosis to date (Fornito, Yung, Wood, Phillips, Nelson, Cotton, Velakoulis, McGorry, Pantelis & Yücel, *in revision*), using the same approach implemented in our previous work^{68,85} to account for the confounding effects of PCS variability. Relative to healthy controls, UHR-P ($n = 35$) individuals displayed bilateral thinning of the

Table 2. Details of Region-of-Interest Magnetic Resonance Imaging Studies Examining the Anterior Cingulate Cortex in Schizophrenia

Study	Sample Size (no. of males)	ROI (Measures) ^a	Major Findings
Noga et al ⁶⁶	14(n/a) SZ; 14(n/a) CON	d-ACC _L ^b (V)	No group differences.
Hirayasu et al ⁷¹	17(14) FE SZ; 20(18) CON	s-ACC _L (V)	No group differences.
Szeszko et al ²¹⁶	19(10) FE SZ; 26(16) CON	ACG (V)	No group differences.
Goldstein et al ⁵³	29(17) SZ; 26(12) CON	ACG; PaG ^c (V)	SZ < CON in ACG & PaG bilaterally.
Crespo-Facorro et al ⁶⁷	26(26) med-naïve FE SZ; 34(34) CON	d-ACC _L ; r-ACC _L (V & A) ^d	No group differences.
Convit et al ⁶⁰	9(9) SZ; 9(9) CON	ACG (V)	No group differences.
Yücel et al ⁷⁴	55(55) SZ; 75(75) CON	PCS incidence	SZ less likely to possess a PCS in the left hemisphere.
Takahashi et al ^{e 64}	40(20) SZ; 40(20) CON	d-ACC _L (V)	Female SZ < Female CON in right d-ACC _L . R>L asymmetry observed in Female CON was not seen in Female SZ.
Le Provost et al ⁷⁵	40(40) SZ; 100(100) CON	PCS incidence	SZ less likely to possess a PCS in the left hemisphere, and were more likely to display a right-lateralized PCS asymmetry.
Takahashi et al ^{f 69}	58(31) SZ; 61(30) CON	r-ACC _L (V)	No group differences. SZ did not show the Male>Female difference seen in CON.
Haznedar et al ⁶³	27(20) SZg; 32(25) CON	d-ACC _L ; r-ACC _L ^h (V)	SZ < CON left d-ACC _L .
Yamasue et al ⁵⁴	27(20) SZ; 27(20) CON	ACG (V)	SZ < CON ACG bilaterally.
Choi et al ⁶⁵	22(15) SZ; 22(15) CON	d-ACC _L ; r-ACC _L ^d (V)	SZ < CON right d-ACC _L .
Coryell et al ⁷²	10(6) SZ; 10(6) CON	s-ACC _L ⁱ (V, A, T)	No group differences.
Marquardt et al ²¹⁷	13(7) COS; 18(10) CON	ACG (PaG included if PCS present) (V)	SZ > CON right ACG. SZ did not show Left>Right asymmetry in present in CON.
Mitelman et al ⁵²	37(27) SZ; 37(23) CON	Areas 24 (dorsal & rostral combined) & 25 ^j (V)	SZ < CON area 24 bilaterally.
Kopelman et al ⁷⁰	30(30) SZ; 30(30) CON	r-ACC _L (V, A, T)	SZ > CON left r-ACC _L volume & thickness; Left r-ACC _L thickness positively correlated with years of antipsychotic treatment.
Riffkin et al ⁶¹	18(18) SZ; 18(18) CON	ACG (V)	No group differences.
Suzuki et al ⁵⁵	22(9) SZ; 44(18) CON	ACG (V)	SZ < CON bilaterally.
Zhou et al ⁵¹	59(31) SZ; 58(30) CON	ACG (V)	SZ < CON right ACC.
Lopez-Garcia et al ⁷³	21(13) SZ; 22(16) FE SZ; 24(12) CON	Area 32 (V) ^k	SZ = CON; FE SZ < CON right area 32.
Szendi et al ⁶²	13(13) SZ; 13(13) CON	ACG (V)	No group differences.
Fujiwara et al ⁵⁶	26(13) SZ 20(10) CON	ACG (V)	SZ < CON bilaterally.
Szeszko et al ⁵⁷	20(17) Cannabis using SZ; 31(25) Non-cannabis using SZ; 56(36) CON	ACG (V)	Cannabis using SZ showed reduced volume bilaterally compared to CON and non-cannabis using SZ.
Fornito et al ⁶⁸	40 (31) FE SZ; 40 (31) CON ¹	d-, r-, & s-ACC _L & -ACC _P (V, A, T)	SZ < CON in d-, r-, & s-ACC _P bilaterally in thickness, but not volume or area.
Mitelman et al ⁵²	51(40) good outcome SZ; 53(43) poor outcome SZ; 41(28) CON	Areas 24(dorsal & rostral combined), 25, & 32 ^j (V)	Both good & poor outcome SZ < CON right area 32.No differences between good & poor outcome SZ.

Table 2. Continued

Study	Sample Size (no. of males)	ROI (Measures) ^a	Major Findings
Wang et al ⁵⁸	53(32) SZ; 68(35) CON	ACG (V, A, T)	SZ < CON volume bilaterally; trend for a thickness reduction; no differences in surface area.
Qiu et al ^{m 59}	49 SZ; 64 CON	ACG (T)	SZ < CON bilaterally.

Note: Studies were published before September 2007 and identified using the online PubMed database using the following search terms: schiz* (or psychosis) and cing*; schiz* (or psychosis) and paracing*; schizo* (or psychosis) and MRI. Listed results are for gray matter comparisons only. One study, conducted by Yamasue, et al²¹⁸, was also not listed because the authors used a region-of-interest (ROI) derived from a voxel used to localize spectroscopic measurements, rather than an anatomically-driven protocol. SZ = schizophrenia; CON = control; FE = first episode; COS = childhood-onset schizophrenia; ACC_L=limbic anterior cingulate cortex; ACC_P=paralimbic anterior cingulate cortex; the prefixes d-, r-, and s-, refer to dorsal, rostral, and subcallosal subdivisions, respectively; ACG = anterior cingulate gyrus; PaG = paracingulate gyrus; PCS = paracingulate sulcus; V = gray matter volume; A = surface area; T = cortical thickness. ^aWhere we were confident the ROIs described by the authors were similar to the ACC subregions we illustrated in figure 1, we have used our terminology. In cases where we were uncertain, we retained the ROI nomenclature assigned by the authors.

^bEstimated by taking the coronal slice in which the septum pellucidum was visible, and tracing 6 mm either side.

^cUsed the whole-brain parcellation method described in Caviness²¹⁹. Although the ACC_P was parcellated separately, PCS variability was not explicitly considered.

^dBorder between rostral and dorsal ACC taken from the method of Crespo-Facorro et al²²⁰. Part of the sub-ACC is included in r-ACC with this method. Choi et al⁶⁵ included the ACC_P as part of their ROI if a PCS was apparent.

^eTakahashi et al⁸⁸ used a similar methodology to Takahashi et al⁶⁴ in an extended sample that also looked at patients with schizotypal personality disorder. The results were unchanged in the schizophrenia group, so only the latter is listed.

^fTakahashi et al²²¹ used a similar method in a sample extended from the Takahashi et al. study listed above. Again, the results were unchanged, so only the 2003 study is listed.

^g7 patients were neuroleptic-naïve, 20 had been medication free for ~ 3 weeks prior to scanning.

^hDorsal & rostral ACC delineated using proportions of Brodmann Areas 24 & 25 taken from the atlas of Talairach & Tournoux²¹⁴.

ⁱA region posterior to the s-ACC, approximating Brodmann area 25, was also parcellated separately.

^jRegions were delineated by geometrically dividing consecutive coronal slices into distinct portions and comparing them with a post-mortem cytoarchitectonic map divided in a similar fashion. See Mitelman et al⁵² for more details. Samples partially overlap across all these studies.

^kParcellated by registering the a template onto each individual's image.

^lControls were matched to patients for morphology of the PCS.

^mThis sample partially overlaps with that studied by Wang et al, but the authors applied a different method for comparing group thickness differences.

rostral ACC_P, whereas UHR-NP ($n = 35$) individuals showed increased thickness bilaterally in the dorsal ACC_L. Subdiagnostic analyses suggested that these pre-onset changes were specific to UHR-P individuals that went on to develop a schizophrenia-spectrum psychosis, with none being noted in those who developed affective or other psychoses.

Together, these findings suggest that ACC gray matter reductions precede psychosis onset and that these pre-onset changes may be specific to schizophrenia-spectrum disorders. However, they may be more prevalent in individuals at clinical, rather than genetic, high risk. Studies of people with schizotypal personality disorder have generally failed to find any ACC differences,^{63,86–88} further underscoring the need to examine how different risk factors relate to pre-onset neuroanatomical changes in schizophrenia.

Do the changes vary across illness stages?

The most straightforward method for examining whether ACC changes vary across illness stages is to compare

results identified in FE and established patient samples. In this context, the most notable finding in ROI work is that none of the FE studies published to date have found significant group differences in ACC_L gray matter.^{21,67,68,73} In contrast, both of the studies that parcellated the ACC_P separately reported gray matter reductions in their FE samples,^{68,73} suggesting that the earliest changes in schizophrenia occur in paralimbic regions. Consistent with this view, a recent longitudinal study of childhood-onset schizophrenia found the earliest gray matter reductions extended across the dorsal and rostral ACC_P and spread to encompass the ACC_L over a 5-year period. Such findings are also consistent with evidence of gray matter reductions in the rostral ACC_P prior to schizophrenia onset⁸¹ longitudinal changes in the rostral and dorsal ACC_P during the transition to psychosis,⁸¹ and more diffuse reductions extending across the rostral, dorsal, and subcallosal ACC_P in FE patients,^{68,73} with further reductions possibly occurring after the first episode.⁸⁹

However, not all imaging findings support a paralimbic to limbic progression of abnormalities in schizophrenia. As indicated in figure 2, comparing the peaks of gray

Table 3. Details of Studies Examining Anterior Cingulate Volume and/or Cortical Thickness in Schizophrenia

Metric	Study	Sample ^a	Region ^b	Measures ^c	Findings
Volume	Highley et al ⁹⁷	24 SZ; 28 CON	Bilateral ACG	Stereology of gray and white matter volume	No group differences
	Ongur et al ⁹⁹ (2001)	11 SZ; 11 CON	s-24 ^d	Stereology of gray matter volume	No group differences
	Stark et al ⁹⁶ (2004)	12 SZ; 14 CON	Bilateral 24/24' & 32/32' ^e	Stereology of gray matter volume	No group differences
	Kreczmanski et al ⁹⁸	13(13) SZ; 13(13) CON	Bilateral 24'	Stereology of grey matter volume	SZ < CON bilaterally
Thickness	Benes et al ¹⁰¹	11 SZ; 12 CON	r-24 ^f	Laminar thickness	No group differences
	Bouras et al ¹⁰⁰	44 SZ; 55 CON	Left d-24a-b; & s-24a	Laminar thickness	SZ < CON in LII, V, VI of s-24; total thickness decreased in 24'
	Kreczmanski et al ⁹⁸	13(13) SZ; 13(13) CON	Left and right 24'	Total cortical thickness	SZ < CON bilaterally

Note: Studies were published before September 2007 and identified using the online PubMed database using the following search terms: schiz* (or psychosis) and cing*; schiz* (or psychosis) and paracing*; schizo* (or psychosis) and MRI. SZ = schizophrenia patients; CON = control; L = cortical layer; ACG = anterior cingulate gyrus; d-, r-, and s- refer to dorsal, rostral, and subcallosal subregions, respectively, of the anterior cingulate cortex.

^aThe number of males in each sample is not presented as few studies reported the gender composition of their samples.

^bWhere we were confident the ROIs described by the authors were similar to the anterior cingulate cortex subregions we illustrated in figure 1, we have used our terminology. In cases where we were uncertain, we retained the ROI nomenclature assigned by the authors.

^cAll stereological studies used the Cavalieri principle to calculate volume.

^dSpecimens were obtained randomly from left and right hemispheres.

^eThese authors studied the entire regions, as defined using cytoarchitectonic criteria, but did not differentiate between areas 24 and 24' or areas 32 and 32'.

^fThe hemisphere from which samples were taken was not specified.

matter differences identified in WBM studies of FE and chronic patients does not reveal clear, regionally specific changes associated with illness stage. Furthermore, not all longitudinal studies have reported evidence for a progression of ACC abnormalities. Job et al⁸⁴ failed to find any evidence of longitudinal changes in ACC gray matter in genetic high-risk individuals who either developed schizophrenia or subthreshold psychotic symptoms, although power may have been limited due to restricted sample sizes. In a larger sample, Whitford et al⁹⁰ found no evidence of excess ACC gray matter reduction in the first 2–3 years following schizophrenia onset, nor were excess reductions found in a separate 5-year follow-up study of patients with established schizophrenia.⁹¹

In summary, while there is some cross-sectional and longitudinal evidence to suggest that the earliest ACC changes in schizophrenia appear in the rostral ACC_P prior to psychosis onset, extend across the ACC_P during the transition to a FE psychosis, and spread to engulf limbic areas with continued illness, not all data support this view. Medication is likely to complicate interpretation of these findings, following evidence that exposure to atypical antipsychotics is associated with increased ACC gray matter over time whereas treatment with typical agents is associ-

ated with decreased ACC gray matter.⁹² Further longitudinal work that accounts for these medication effects will therefore be necessary to better characterize the trajectory of ACC changes across the course of schizophrenia.

Neuropathology of the ACC in schizophrenia and bipolar disorder

Are volume changes apparent in postmortem samples?

The preceding discussion indicates that most imaging studies in schizophrenia have found evidence for reduced ACC gray matter. However, anatomical changes detected using MRI may result from a variety of nonpathological physiological and developmental processes,^{93–95} highlighting the need to validate such findings with postmortem techniques. This task is complicated by the relative paucity of postmortem work published in this area and the considerable variability in the ACC subregions sampled (see table 3).

Two postmortem studies, both examining the volume of the entire anterior cingulate gyrus, found no significant volumetric differences,^{96,97} while one focusing on dorsal area 24' reported reduced volume in both the left and right hemispheres of schizophrenia patients.⁹⁸ In a separate

report, no group differences were found in the subcallosal portion of area 24,⁹⁹ consistent with the aforementioned MRI findings suggesting few changes in this region. However, some of these studies collapsed data from samples taken from both hemispheres,^{96,99} adding noise to the group comparisons. Moreover, only one study attempted to control for differences in overall brain size.⁹⁷ The sole postmortem investigation of paralimbic ACC found no significant differences.⁹⁶

Three studies have investigated ACC laminar thickness in patients with schizophrenia. Two studies examining dorsal area 24⁷ both found reductions in total cortical thickness (collapsed across all layers), with one reporting a bilateral reduction⁹⁸ and the other examining left hemisphere samples only.¹⁰⁰ Bouras *et al.*¹⁰⁰ also reported reduced thickness in specific layers of subcallosal area 24, while the only study of rostral area 24 found no significant differences in laminar thickness.¹⁰¹ Together, these findings suggest that schizophrenia is associated with volumetric and thickness reductions, at least in the dorsal and subcallosal ACC. These results are broadly consistent with the gray matter reductions reported in imaging research, although more postmortem studies are required before firm conclusions can be drawn.

Is there evidence of cell loss?

Cortical gray matter reductions are often interpreted as reflecting neuronal loss, although providing unambiguous evidence for neuronal loss is a nontrivial task as a definitive answer requires precise counting of each neuron within a defined region, a goal that poses several technical challenges (see^{102,103} for detailed discussion). Only 2 studies have estimated absolute cell counts in the ACC of schizophrenia patients (see table 4). The first, by Ongur *et al.*,⁹⁹ found no differences in overall neuronal number in subcallosal area 24, consistent with their finding of no changes in the gray matter volume of this region. The second, by Stark *et al.*,⁹⁶ examined multiple sections through the limbic (24/24⁷) and paralimbic (32/32⁷) ACC and also found no differences.

Most cell-counting studies have examined cell density rather than absolute cell number. Cell density is a more practical measure because it can be obtained from a restricted tissue sample rather than the entire extent of a region. It therefore estimates the relative cellular abundance per unit volume, rather than providing an absolute cell count. The reported findings have been somewhat contradictory, with decreases,^{101,104,105} increases,¹⁰⁶ and no changes^{99,100,107,108} being found in patients relative to controls (see table 4). Part of this inconsistency is likely related to differences in the precise ACC subregion sampled. For example, most studies of dorsal area 24⁷ have reported no changes in neuronal density,^{99,100,107} with one reporting increased density in patients.¹⁰⁶ Only 2 studies have examined the subcallosal ACC region

separately,^{99,100} with neither reporting group differences in overall neuron density. However, they did find a decrease in the density of large-diameter neurons and an increase in small-diameter neurons in both subcallosal and dorsal regions, suggesting a selective shrinkage of large (presumably pyramidal) neurons. (Reports by others of changes in neuron size have been variable; see table 4.) Findings in the rostral ACC have been more consistent, although all the work in this area has been conducted by one group (table 4). A recent meta-analysis of their findings¹⁹ suggests that, while the density of both pyramidal and nonpyramidal neurons is reduced in schizophrenia patients, the reduction is greater for pyramidal neurons. In contrast, patients with bipolar disorder showed larger reductions in nonpyramidal neuron density. Independent replication of these results will be critical in establishing their generalizability.

In summary, the only 2 studies reporting absolute cell counts do not support neuronal loss in the ACC of schizophrenia patients, while the much larger literature examining cell density suggests that there are indeed reductions in the number of neurons per unit volume in some subregions. However, for a reduction in neuronal density to reflect neuronal loss, the degree of neuronal loss would either have to be accompanied by no change in cortical volume, or the reduction in neuron number would need to exceed the magnitude of any volumetric reduction since findings of reduced neuron density may also arise if neuron number remains unchanged but volume is increased (see¹⁰⁹ for similar arguments). Given the aforementioned MRI and neuropathological evidence for gray matter reductions in some ACC subregions, any reductions in neuron density would need to exceed the magnitude of the volumetric decrement to be interpreted as neuronal loss. Differences in cell-counting methodologies and subregions sampled across studies make it difficult to obtain a robust estimate of the magnitude of the density or volumetric reductions observed, and the 4 studies that have measured neuron density and gray matter thickness or volume concurrently have yielded inconsistent results: Benes *et al.*¹⁰¹ found that minimal change in rostral ACC thickness was accompanied by a 40% reduction in pyramidal and 16% reduction in nonpyramidal neurons; Bouras *et al.*¹⁰⁰ reported larger reductions in thickness than neuron density in dorsal and subcallosal subregions; Ongur *et al.*⁹⁹ reported comparable reductions in density and volume in the subcallosal ACC; and Stark *et al.*⁹⁶ found no differences in either neuron density or volume in areas 24 and 32. Such results suggest that neuronal loss may be more pronounced in the rostral ACC, consistent with other reports of quite large (~50%) reductions in some neuronal subtypes in this area.¹¹⁰ However, differences in cell-counting techniques might contribute to inconsistencies across studies, given the ongoing debate regarding the accuracy and validity of 2- vs 3-dimensional methods (see¹⁰³ and related

Table 4. Details of cell-counting and synaptic morphology studies of the anterior cingulate cortex in schizophrenia.

Study	Sample ^a	Region ^b	Measures	Major findings
Benes et al ¹⁰⁴	9 SZ; 10 CON	ACC	2D neuron & glial density & size; neuron/glia ratio.	SZ<CON neuron density in L5; no changes in neuron size, glial density, or neuron/glia ratio.
Benes et al ¹¹¹	10 SZ; 10 CON	24	Inter-cellular & inter-aggregate distance of neurons & glia.	SZ>CON inter-neuronal & inter-neuronal aggregate distance; SZ<CON diameter of neuronal aggregates. No changes in glial arrangement.
Benes et al ¹¹⁹	7 SZ; 7 CON	ACC	NFP-200-IR vertical & horizontal axon number.	SZ>CON number of vertical axons in L2 & 3; no changes in horizontal axonal number.
Benes et al ¹⁰⁵	18 SZ; 12 CON	24	2D PN & small neuron density.	SZ<CON small neuron density in L2-6; no changes in PN density.
Aganova et al ¹¹⁵	5 SZ; 7 CON	24	EM of synaptic density ^c .	SZ>CON axospinous & dendritic synapse density; SZ<CON axodendritic synapse density.
Benes et al ¹²⁰	17 SZ; 15 CON	24	IHC - Density of glutamate -IR axonal fibers	SZ>CON density of small & large caliber vertical fibers.
Benes et al ¹²¹	10 SZ; 15 CON	BA 24	IHC - Density of TH-IR varicose fibers	SZ >CON density of TH-IR fibers in L5 & L6 of NPL; SZ<CON density of fibers in apposition with small neurons relative to those in apposition with large neurons in L2; no differences in density of fibers in apposition with small or large neurons.
Ongur et al ⁹⁹	11 SZ; 11 CON ^d	s-24	3D neuron & glial number, density & size.	SZ>CON number of large neurons & SZ<CON number of small neurons; no changes in overall neuronal or glial number or density.
Benes et al ¹⁰¹	11 SZ; 12 CON	r-24	2D PN, NP, & glial density; NP & PN size.	SZ<CON PN density in L5; no changes in glial density or neuron size. (Abercrombie correction yielded generally similar findings.)
Bouras et al ¹⁰⁰	44 SZ; 55 CON	Left d-24a-b & s-24a	3D neuron density & size; axonal & dendritic morphology	SZ<CON reduced maximal neuron diameter in L5 of d24 & L6 of s24; SZ had less large & more small diameter neurons in both ROIs; no changes in neuron density; no differences in axonal/dendritic morphology in sub-group of 3 patients and 3 controls.
Cotter et al ¹⁰⁷	15 SZ; 15 CON	d-24b	3D neuron & glial density & size.	SZ<CON glial density in L6 (did not survive correction for multiple comparisons); no changes in neuron density or size.
Broadbelt et al ²⁰	11 SZ; 11 CON	r-32	Number of primary & secondary basilar dendrites	SZ<CON number of primary & secondary basilar dendrites in L3 & 5.
Jones et al ¹⁰⁸	7 SZ; 7 CON	r-32	PN density.	No differences in PN density in L3 or L5.
Chana et al ¹⁰⁶	15 SZ; 15 CON	d-24c	2D neuron & glial density, size & spatial clustering.	SZ>CON neuron density in L5 & 6; SZ>CON glial size in L1, 3, & 5; SZ<CON neuron size in L3 & 5; no changes in glial density, or neuronal or glial clustering.

Table 4. Continued

Study	Sample ^a	Region ^b	Measures	Major findings
Stark <i>et al</i> ⁹⁶	12 SZ; 14 CON	Bilateral 24/24' & 32/32', ^c	3D neuronal & glial number & density.	SZ < CON glial number in area 24; no changes in glial density or neuronal number or density; no changes in neuronal or glial number or density in area 32.
Steiner <i>et al</i> ²²²	16 SZ; 16 CON	r-ACC	IHC & 2D counting of HLA-DR-IR microglial density.	No differences in HLA-DR-IR glial density.

Note: Studies were published before September 2007 and identified using the online PubMed database using the following search terms: schiz* (or psychosis) and cing*; schiz* (or psychosis) and paracing*; schizo* (or psychosis) and MRI. SZ = Schizophrenia patients; CON = control; ACC = anterior cingulate cortex; d-, r-, and s- refer to dorsal, rostral, and subcallosal subregions, respectively, of the ACC; 2D = 2-dimensional; 3D = 3-dimensional; L = cortical layer; PN = pyramidal neurons; NP = non-pyramidal neurons; NPL = neuropil; EM = electron micrograph; IHC = immunohistochemistry; IR = immunoreactive; NFP-200 = neurofilament protein 200-immunoreactive; TH = tyrosine hydroxylase; HLA = human leukocyte antigen.

^aThe number of males in each sample is not presented as few studies reported the gender composition of their samples.

^bWhere we were confident the regions-of-interest described by the authors were similar to the ACC subregions we illustrated in figure 1, we have used our terminology. In cases where we were uncertain, we retained the ROI nomenclature assigned by the authors.

^cThese authors also examined synaptic morphology, but reported no statistical results.

^dThe authors reported results from 2 separate samples. Only results from the larger sample are reported here (results were generally consistent across samples).

^eThese authors studied the entire regions, as defined using cytoarchitectonic criteria. Unless otherwise specified, all other studies restricted their analyses to specific sections.

commentaries). In this context, it is noteworthy that studies employing 3-dimensional methods have been less likely to find significant differences in cell density (see table 4). The lack of studies examining the same sub-region using these different approaches complicates comparison of findings reported by different research groups. However, one early report by Benes and Bird¹¹¹ suggested that interneuronal distance is increased in the ACC of schizophrenia patients, supporting the notion that any reductions in cortical volume are not accompanied by an increase in packing density, which would be expected if cell number were unchanged. Findings of either no change^{106,107,101,104,99} or a reduction in ACC glial density⁹⁶ in schizophrenia patients suggest that, if neuronal loss does occur in this disorder, it is not accompanied by the gliotic reactions associated with traditional neurodegenerative processes.^{1,112}

Is there evidence of changes in the inter-cellular neuropil?

Accumulating evidence implicates synaptic pathology in schizophrenia^{113,114}. The first study of ACC synaptic morphology in the disorder was conducted by Aganov and colleagues¹¹⁵, who found decreased density of axospinous and axodendritic synapses in a small (n = 5) sample. A later study investigating a larger sample (n = 11) found reduced dendritic density in layers III and V of rostral area 32²⁰ consistent with reports of decreased expression of synaptic proteins in the ACC of schizophrenia patients^{108,116–118}.

In rostral area 24, Benes *et al.*¹¹⁹ reported an increase in the number of vertical afferents entering layers II and III in schizophrenia patients. These afferents were later confirmed to be glutamatergic in nature¹²⁰. In separate work, they found reduced density of fibers immunoreactive for tyrosine hydroxylase in the inter-neuronal neuropil, combined with a relative increase in the density of such fibers in apposition with small compared to large neurons¹²¹. Collectively, these findings suggest that the ACC of schizophrenia patients possesses excess glutamatergic input, aberrant wiring of glutamatergic and dopaminergic circuits, and reduced synaptic and dendritic density.

Are the changes secondary to antipsychotic treatment?

As previously mentioned, some MRI studies have found that medication can affect ACC gray matter measures, although the precise nature of such influences remains contentious. Only 2 studies of ACC gray matter in antipsychotic-naive patients have been conducted: an ROI study that found no differences between patients and controls⁶⁷ and a WBM report finding that, relative to drug-free patients with psychosis (both schizophreniform and affective patients), those treated with typicals showed reduced ACC gray matter while those treated with atypicals showed no differences.¹²² We have found no differences in ACC gray matter between FE schizophrenia patients taking typical or atypical antipsychotics, after

accounting for the confounding influence of PCS variability.⁶⁸ While our study did not include unmedicated patients, findings of pre-onset changes in UHR individuals suggest that medication effects are insufficient to account for all the ACC gray matter reductions associated with schizophrenia.^{80,81} The duration of antipsychotic treatment may still play an important role however, given the aforementioned evidence suggesting that cumulative exposure to typical and atypical agents may have a differential effect on ACC gray matter over time,^{70,92} although several authors have failed to find any correlations between ACC gray matter measures and antipsychotic exposure.^{52,53,88}

In postmortem work, restrictions on tissue availability make it difficult to comprehensively rule out treatment influences on the findings. Some authors have tested for medication effects by dividing their sample into patients taking or not taking medications prior to death,¹⁰¹ or examining statistical associations between indices of antipsychotic exposure and the measures of interest^{104,107} (the latter is also commonly used to rule out an influence of other confounds associated with tissue handling and processing or demographic characteristics). However, given that the initial sample is often small, the power of such secondary analyses is limited. Most of the patients studied by Bouras et al¹⁰⁰ lived prior to the introduction of neuroleptics, suggesting that not all neuropathological changes are attributable to medication effects, although these authors only found differences in ACC laminar thickness and neuron size, not density. Research in nonhuman primates suggests that, in some brain regions, antipsychotic exposure produces increased cortical volume and glial density with no change in neuronal number, findings that contrast with human data.¹²³ Further characterization of the cellular changes induced by psychotropic medications will be necessary to facilitate interpretation of neuropathological research.

Bridging the gap: implications for pathophysiology

To summarize, the available MRI data suggest that gray matter reductions in some ACC subregions, particularly dorsal and rostral areas, are a robust finding and are present prior to psychosis onset in some categories of high-risk individuals. There is some evidence to suggest that the earliest changes appear in the rostral ACC_P, extend across the entire paralimbic region during the transition to psychosis, and spread to engulf limbic regions with ongoing illness, but more longitudinal data are required to confirm this. The postmortem findings indicate that these changes are accompanied by a reduction in neuronal, synaptic, and dendritic density, as well as increased afferentation, in some subregions. Given these data, how might the neuropathological and neuroimaging findings be integrated in a manner that provides clues regarding underlying pathophysiological mechanisms?

One important question is whether these changes are specific to the ACC. Volumetric reductions are commonly found in MRI studies of different brain regions in schizophrenia, although their neuropathological concomitants are not always the same. For example, reductions in dendritic density have been observed in both cingulate and prefrontal cortices,^{20,124} but the repeated reports of reduced cell density in some ACC subregions contrast with findings in the prefrontal cortex, where either no differences^{125–127} or density increases^{128,129} are more commonly found. Similarly, the increased density of ACC glutamatergic afferents identified by Benes et al¹¹⁹ was not observed in prefrontal area 10, although a similar increase is apparent in the entorhinal cortex of schizophrenia patients,¹³⁰ implying similar pathologies may characterize functionally related networks.¹³¹ Such findings indicate that attributing differences in MRI measures of gray matter to a unitary process may be inaccurate and that a greater appreciation of the regional specificity of pathological processes in schizophrenia is required.¹³² Indeed, the findings reviewed in this article indicate that there is considerable heterogeneity even across ACC subregions.

When considering the histopathological correlates of gray matter reductions observed with MRI, an often overlooked fact that some authors^{95,133,134} have drawn attention to is that the cortical neuropil, as represented in T1-weighted imaging (the most commonly used protocol in volumetric studies), reflects the contribution of signals emanating from various neuronal and non-neuronal tissue compartments, including glial cell bodies, dendrites and spines, blood vessels, intracortical fibers, and extracellular components. Consequently, differences in cortical gray matter may result from variations in nonneuronal tissue. Indeed, the fraction of cortical volume occupied by axons has been estimated at approximately 29%,¹³⁵ suggesting that up to one-third of the signal in T1-imaged cortex originates from white matter.¹³⁴ Based on these findings, Paus¹³⁴ and Sowell et al¹³³ have argued that reports of longitudinal reductions in cortical gray matter during the course of normal adolescent development^{94,136–138} may actually reflect ongoing myelination of axonal fibers penetrating the cortical mantle, rather than (or in addition to) the synaptic pruning that is thought to occur throughout adolescence in some brain regions.^{139,140} In this context, findings that schizophrenia patients show increased ACC afferentation^{119,120} suggest that myelination of these excess connections throughout adolescence and early adulthood may contribute to the gray matter reductions observed on MRI. This may also be related to findings of progressive gray matter reductions during transition to psychosis⁸¹ and in the first few years following illness onset^{89,141} because cingulate fibers continue to myelinate well into adulthood.^{142,143} However, an excess of afferent input has not yet been demonstrated in all ACC subregions, so it is unclear

whether this process can explain all the gray matter reductions observed in the area.

An additional limitation associated with positing myelination of excess afferents as the sole cause of the gray matter reductions observed in the ACC is that it cannot account for reports of reduced synaptic and cell density in the region. Excessive synaptic pruning during adolescence is commonly proposed as a key pathophysiological mechanism in schizophrenia,¹⁴⁴ and might partially account for the observed pre-onset grey matter reductions in the ACC and possible progression of these changes with continued illness, but it cannot explain the reductions in cell density. As previously discussed, the most straightforward interpretation of such findings is that they reflect cell loss. To some extent, the magnitude of cell density relative to volume reductions indirectly supports this conclusion, raising questions regarding the underlying mechanisms involved. Apoptosis is commonly invoked as a candidate mechanism because it is associated with cell death in the absence of gliosis, although arguments supporting its role have been based largely on speculative grounds. Indeed, the available postmortem data suggest that there is a downregulation, rather than increase, of apoptotic activity in schizophrenia. Benes *et al.*¹⁴⁵ have found decreased DNA fragmentation, a marker of oxidative stress, in rostral ACC neurons, while studies of hippocampal slices by this group revealed a downregulation of several proapoptotic genes, which contrasted with the general increases seen in patients with bipolar disorder.¹⁴⁶ In temporal cortex, Jarskog *et al.*¹⁴⁷ found no evidence for elevations in the proapoptotic protein caspase 3. They also found reduced expression of the antiapoptotic protein Bcl-2 and an increase in the Bax/Bcl-2 ratio, which they interpreted as reflecting a vulnerability to apoptosis.^{147,148} Jarskog and coworkers^{114,149,150} have argued that these findings may reflect a compensatory downregulation following increased apoptotic activity occurring around the time of the illness. However, experimental data are lacking, and evidence supporting the occurrence of apoptotic cell death, as defined by ultrastructural criteria, throughout the mature brain appears limited.^{151,152} It is also possible that alterations in the expression of apoptotic proteins arise through their involvement in other functions.¹⁵³

An alternative mechanism that can cause cell death in the mature brain without lasting gliosis arises from hypofunction of the *N*-methyl-D-aspartate receptor (NMDAR), a pathology receiving increasing support as a basis for schizophrenia.^{154–156} According to one theory, impaired excitation of NMDARs on GABAergic interneurons results in a net reduction of inhibitory tone and consequent increase in glutamatergic and cholinergic transmission at non-NMDA glutamate and muscarinic receptor sites.¹⁵⁷ Evidence for its role in schizophrenia pathophysiology is based on findings

that NMDAR antagonism with agents such as phencyclidine and ketamine produces psychotic symptoms and schizophrenia-like cognitive deficits in healthy individuals^{158–161} and exacerbates psychotic symptomatology in schizophrenia patients.^{156,162,163} In rodents, NMDAR antagonism can cause marked neuronal injury and/or death with only transient gliosis,^{164,165} and the peak period of neuronal sensitivity to such toxic effects occurs between puberty and adulthood¹⁶⁶—the period of highest risk for schizophrenia onset.¹⁶⁷ This apparent delay in vulnerability parallels human clinical data indicating that children are relatively immune to the psychotogenic effects of phencyclidine.^{168,169}

While much of the rodent work indicates retrosplenial areas are the most sensitive to the toxic effects of NMDAR hypofunction,¹⁶⁵ neuroimaging studies suggest that the ACC may be particularly vulnerable in humans. PET work has shown that ketamine administration causes marked blood flow and metabolism increases in the ACC that correlate with measures of psychotic symptoms in both healthy controls and schizophrenia patients.^{170–173} One recent study found that while both patients and controls showed increased ACC blood flow following ketamine infusion, the magnitude of the increase was much larger in the patient group,¹⁷² suggesting the ACC shows heightened sensitivity to the effects of NMDAR hypofunction in people with schizophrenia. That these blood flow increases are related to excess glutamatergic transmission is suggested by *in vivo* spectroscopy studies demonstrating elevated levels of glutamine, a metabolic precursor to glutamate, in the ACC of medication-naïve FE schizophrenia patients^{174,175}, and in healthy volunteers following ketamine administration¹⁷⁶. Post-mortem data showing large (>50%) decreases in the density of ACC GABAergic neurons bearing NMDAR subunits are also consistent with deficient stimulation of this receptor on GABAergic cells in the region¹¹⁰. Such abnormalities are likely to be potentiated in adolescence and early adulthood by the ongoing myelination of excess glutamatergic afferents to the region^{142,143}. NMDAR hypofunction can also contribute to grey matter volume reductions by affecting synaptic density¹⁷⁷, although apoptotic processes may also play a role¹¹⁴. Indeed, it is likely that expression of apoptotic proteins is altered in response to toxic events associated with NMDAR hypofunction¹⁷⁸, so an important avenue of future research will be to better understand interactions between these processes. It must be remembered however, that the evidence for neuronal loss in the ACC remains indirect, based primarily on studies of cell density rather than absolute number. The fact that only two studies, both in relatively small samples, have reported absolute cell counts concurrently with cortical volume means that further work is required to unambiguously interpret reports of reduced neuron density as evidence of cell loss.

Conclusions

The considerable methodological variability across studies makes it difficult to draw firm conclusions regarding the precise nature of ACC pathology in schizophrenia. In this regard, the gap between neuroimaging and neuropathology still needs to be bridged. Nonetheless, the evidence reviewed in this article suggests abnormalities in the region are a common finding and suggests strategies for future research that will facilitate more accurate characterization of relevant pathophysiological mechanisms. For neuroimaging researchers, these involve more longitudinal work tracking neuroanatomical changes from the high-risk to chronic illness stages that considers the influence anatomical variability has on the resulting measures. For neuropathologists, comparison of absolute cell counts in cytoarchitecturally defined regions with concurrent measures of cortical volume and thickness will be necessary to characterize the cellular basis of MRI-based morphometric changes. Continued integration of findings from these 2 fields will help identify neurobiological endophenotypes that can guide molecular work aimed at treatment development.

Acknowledgments

This research was supported by the Melbourne Neuropsychiatry Centre (Sunshine Hospital), Department of Psychiatry, the University of Melbourne, the National Health and Medical Research Council (ID 236175; 350241), and the Ian Potter Foundation. SJW was supported by a NHMRC Clinical Career Development Award and a NARSAD Young Investigator Award. AF was supported by a JN Peters Fellowship and NHMRC CJ Martin Fellowship (ID: 454797). MY was supported by a NHMRC Clinical Career Development Award (ID: 509345).

References

- Harrison PJ. The neuropathology of schizophrenia: a critical review of the data and their interpretation. *Brain*. 1999;122:593–624.
- Weinberger DR. Implications of normal brain development for the pathogenesis of schizophrenia. *Arch Gen Psychiatry*. 1987;44:660–669.
- Wright IC, Rabe-Hesketh S, Woodruff PW, David AS, Murray RM, Bullmore ET. Meta-analysis of regional brain volumes in schizophrenia. *Am J Psychiatry*. 2000;157(1):16–25.
- Pantelis C, Yucel M, Wood SJ, et al. Structural brain imaging evidence for multiple pathological processes at different stages of brain development in schizophrenia. *Schizophr Bull*. 2005;31(3):672–696.
- Shenton ME, Dickey CC, Frumin M, McCarley RW. A review of MRI findings in schizophrenia. *Schizophr Res*. 2001;49(1–2):1–52.
- Paus T. Primate anterior cingulate cortex: where motor control, drive and cognition interface. *Nat Rev Neurosci*. 2001;2:417–424.
- Ridderinkhof KR, Ullsperger M, Crone EA, Nieuwenhuis S. The role of the medial frontal cortex in cognitive control. *Science*. 2004;306(5695):443–447.
- Botvinick M, Braver TS, Barch DM, Carter CS, Cohen JD. Conflict monitoring and cognitive control. *Psychol Rev*. 2001;108(3):624–652.
- Rushworth MF, Buckley MJ, Behrens TE, Walton ME, Bannerman DM. Functional organization of the medial frontal cortex. *Curr Opin Neurobiol*. 2007;17(2):220–227.
- Walton ME, Croxson PL, Behrens TE, Kennerley SW, Rushworth MF. Adaptive decision making and value in the anterior cingulate cortex. *Neuroimage*. 2007;36(suppl 2):T142–T154.
- Devinsky O, Morrell MJ, Vogt BA. Contributions of anterior cingulate cortex to behaviour. *Brain*. 1995;118:279–306.
- Bush G, Luu P, Posner MI. Cognitive and emotional influences in anterior cingulate cortex. *Trends Cogn Sci*. 2000;4(6):215–222.
- Vogt BA, Finch DM, Olson CR. Functional heterogeneity in cingulate cortex: the anterior executive and posterior evaluative regions. *Cereb Cortex*. 1992;2:435–443.
- Amodio DM, Frith CD. Meeting of minds: the medial frontal cortex and social cognition. *Nat Rev Neurosci*. 2006;7(4):268–277.
- Benes FM. The defects of affect and attention in schizophrenia: a possible neuroanatomical substrate. In: Matthysse S, Levy DL, Kagan J, Benes FM, eds. *Psychopathology: The Evolving Science of Mental Disorder*. New York, NY: Cambridge University Press; 1996:127–151.
- Picard N, Strick PL. Motor areas of the medial wall: a review of their location and functional activation. *Cereb Cortex*. 1996;6(3):342–353.
- Vogt BA. Pain and emotion interactions in subregions of the cingulate gyrus. *Nat Rev Neurosci*. 2005;6(7):533–544.
- Andreasen NC, Paradiso S, O’Leary DS. “Cognitive dysmetria” as an integrative theory of schizophrenia: a dysfunction in cortical-subcortical-cerebellar circuitry? *Schizophr Bull*. 1998;24(2):203–218.
- Todtenkopf MS, Vincent SL, Benes FM. A cross-study meta-analysis and three-dimensional comparison of cell counting in the anterior cingulate cortex of schizophrenic and bipolar brain. *Schizophr Res*. 2005;73(1):79–89.
- Broadbelt K, Byne W, Jones LB. Evidence for a decrease in basilar dendrites of pyramidal cells in schizophrenic medial prefrontal cortex. *Schizophr Res*. 2002;58(1):75–81.
- Szeszko PR, Bilder RM, Lencz T, et al. Reduced anterior cingulate gyrus volume correlates with executive dysfunction in men with first-episode schizophrenia. *Schizophr Res*. 2000;43(2–3):97–108.
- McGuire PK, Quasted DJ, Spence SA, Murray RM, Frith CD, Liddle PF. Pathophysiology of ‘positive’ thought disorder in schizophrenia. *Br J Psychiatry*. 1998;173:231–235.
- Snitz BE, MacDonald A, 3rd, Cohen JD, Cho RY, Becker T, Carter CS. Lateral and medial hypofrontality in first-episode schizophrenia: functional activity in a medication-naïve state and effects of short-term atypical antipsychotic treatment. *Am J Psychiatry*. 2005;162(12):2322–2329.
- Lahti AC, Holcomb HH, Weiler MA, et al. Clozapine but not haloperidol re-establishes normal task-activated rCBF patterns in schizophrenia within the anterior cingulate cortex. *Neuropsychopharmacology*. 2004;29(1):171–178.
- Drevets WC, Ongur D, Price JL. Neuroimaging abnormalities in the subgenual prefrontal cortex: implications for the

- pathophysiology of familial mood disorders. *Mol Psychiatry*. 1998;3(3):190–191220–226.
26. Vogt BA, Nimchinsky EA, Vogt LJ, Hof PR. Human cingulate cortex: surface features, flat maps, and cytoarchitecture. *J Comp Neurol*. 1995;359:490–506.
 27. Yücel M, Stuart GW, Maruff P, et al. Hemispheric and gender-related differences in the gross morphology of the anterior cingulate/paracingulate cortex in normal volunteers: an MRI morphometric study. *Cereb Cortex*. 2001;11:17–25.
 28. Paus T, Tomaiuolo F, Otkay N, et al. Human cingulate and paracingulate sulci: pattern, variability, asymmetry, and probabilistic map. *Cereb Cortex*. 1996;6:207–214.
 29. Fornito A, Yücel M, Wood SJ, et al. Morphology of the paracingulate sulcus and executive cognition in schizophrenia. *Schizophr Res*. 2006;88(1–3):192–197.
 30. Fornito A, Yücel M, Wood SJ, et al. Individual differences in anterior cingulate/paracingulate morphology are related to executive functions in healthy males. *Cereb Cortex*. 2004;14:424–431.
 31. Heckers S, Weiss AP, Deckersbach T, Goff DC, Morecraft RJ, Bush G. Anterior cingulate cortex activation during cognitive interference in schizophrenia. *Am J Psychiatry*. 2004;161(4):707–715.
 32. Yücel M, Pantelis C, Stuart GW, et al. Anterior cingulate activation during stroop task performance: a PET to MRI coregistration study of individual patients with schizophrenia. *Am J Psychiatry*. 2002;159(2):251–254.
 33. Artiges E, Martelli C, Naccache L, et al. Paracingulate sulcus morphology and fMRI activation detection in schizophrenia patients. *Schizophr Res*. 2006;82(2–3):143–151.
 34. Fornito A, Wood SJ, Whittle S, et al. Variability of the paracingulate sulcus and morphometry of the medial frontal cortex: associations with cortical thickness, surface area, volume and sulcal depth. *Hum Brain Mapp*. 2008;29(2):222–236.
 35. Steele JD, Lawrie SM. Segregation of cognitive and emotional function in the prefrontal cortex: a stereotactic meta-analysis. *Neuroimage*. 2004;21(3):868–875.
 36. Paus T, Koski L, Caramanos Z, Westbury C. Regional differences in the effects of task difficulty and motor output on blood flow response in the human anterior cingulate cortex: a review of 107 PET activation studies. *Neuroreport*. 1998;9(9):R37–R47.
 37. Koski L, Paus T. Functional connectivity of the anterior cingulate cortex within the human frontal lobe: a brain-mapping meta-analysis. *Exp Brain Res*. 2000;133:55–65.
 38. Margulies DS, Kelly AM, Uddin LQ, Biswal BB, Castellanos FX, Milham MP. Mapping the functional connectivity of anterior cingulate cortex. *Neuroimage*. 2007;37(2):579–588.
 39. Gusnard DA, Akbudak E, Shulman GL, Raichle ME. Medial prefrontal cortex and self-referential mental activity: relation to a default mode of brain function. *Proc Natl Acad Sci U S A*. 2001;98(7):4259–4264.
 40. Gusnard DA, Raichle ME. Searching for a baseline: functional imaging and the resting human brain. *Nat Rev Neurosci*. 2001;2(10):685–694.
 41. Critchley HD, Mathias CJ, Josephs O, et al. Human cingulate cortex and autonomic control: converging neuroimaging and clinical evidence. *Brain*. 2003;126(pt 10):2139–2152.
 42. Mega MS, Cummings JL. The cingulate and cingulate syndromes. In: Trimble MR, Cummings JL, eds. *Contemporary Behavioural Neurology*. Boston, MA: Butterworth-Heinemann; 1997:189–213.
 43. Crum WR, Griffin LD, Hill DLG, Hawkes DJ. Zen and the art of medical image registration: correspondance, homology, and quantity. *Neuroimage*. 2003;20:1425–1437.
 44. Bookstein FL. “Voxel-based morphometry” should not be used with imperfectly registered images. *Neuroimage*. 2001;14(6):1454–1462.
 45. Fornito A, Whittle S, Wood SJ, Velakoulis D, Pantelis C, Yücel M. The influence of sulcal variability on morphometry of the human anterior cingulate and paracingulate cortex. *Neuroimage*. 2006;33(3):843–854.
 46. Ashburner J, Friston KJ. Voxel-based morphometry—the methods. *Neuroimage*. 2000;11(6 pt 1):805–821.
 47. Thompson PM, Hayashi KM, Sowell ER, et al. Mapping cortical change in Alzheimer’s disease, brain development, and schizophrenia. *Neuroimage*. 2004;23(suppl 1):S2–S18.
 48. Davatzikos C, Genc A, Xu D, Resnick SM. Voxel-based morphometry using the RAVENS maps: methods and validation using simulated longitudinal atrophy. *Neuroimage*. 2001;14(6):1361–1369.
 49. Bullmore ET, Suckling J, Overmeyer S, Rabe-Hesketh S, Taylor E, Brammer MJ. Global, voxel, and cluster tests, by theory and permutation, for a difference between two groups of structural MR images of the brain. *IEEE Trans Med Imaging*. 1999;18(1):32–42.
 50. Fischl B, Sereno MI, Tootell RBH, Dale AM. High-resolution intersubject averaging and a coordinate system for the cortical surface. *Hum Brain Mapp*. 1999;8:272–284.
 51. Zhou SY, Suzuki M, Hagino H, et al. Volumetric analysis of sulci/gyri-defined in vivo frontal lobe regions in schizophrenia: precentral gyrus, cingulate gyrus, and prefrontal region. *Psychiatry Res*. 2005;139(2):127–139.
 52. Mitelman SA, Shihabuddin L, Brickman AM, Hazlett EA, Buchsbaum MS. Volume of the cingulate and outcome in schizophrenia. *Schizophr Res*. 2005;72(2–3):91–108.
 53. Goldstein JM, Goodman JM, Seidman LJ, et al. Cortical abnormalities in schizophrenia identified by structural magnetic resonance imaging. *Arch Gen Psychiatry*. 1999;56:537–547.
 54. Yamasue H, Iwanami A, Hirayasu Y, et al. Localized volume reduction in prefrontal, temporolimbic, and paralimbic regions in schizophrenia: an MRI parcellation study. *Psychiatry Res*. 2004;131(3):195–207.
 55. Suzuki M, Zhou SY, Hagino H, et al. Morphological brain changes associated with Schneider’s first-rank symptoms in schizophrenia: a MRI study. *Psychol Med*. 2005;35(4):549–560.
 56. Fujiwara H, Hirao K, Namiki C, et al. Anterior cingulate pathology and social cognition in schizophrenia: a study of gray matter, white matter and sulcal morphometry. *Neuroimage*. 2007;36(4):1236–1245.
 57. Szeszko PR, Robinson DG, Sevy S, et al. Anterior cingulate grey-matter deficits and cannabis use in first-episode schizophrenia. *Br J Psychiatry*. 2007;190:230–236.
 58. Wang L, Hosakere M, Trein JC, et al. Abnormalities of cingulate gyrus neuroanatomy in schizophrenia. *Schizophr Res*. 2007;93(1–3):66–78.
 59. Qiu A, Younes L, Wang L, et al. Combining anatomical manifold information via diffeomorphic metric mappings for studying cortical thinning of the cingulate gyrus in schizophrenia. *Neuroimage*. 2007;37(3):821–833.
 60. Convit A, Wolf OT, de Leon MJ, et al. Volumetric analysis of the pre-frontal regions: findings in aging and schizophrenia. *Psychiatry Res*. 2001;107(2):61–73.

61. Riffkin J, Yücel M, Maruff P, et al. A manual and automated MRI study of anterior cingulate and orbito-frontal cortices, and caudate nucleus in obsessive-compulsive disorder: comparison with healthy controls and patients with schizophrenia. *Psychiatry Res.* 2005;138:99–113.
62. Szendi I, Kiss M, Racsmány M, et al. Correlations between clinical symptoms, working memory functions and structural brain abnormalities in men with schizophrenia. *Psychiatry Res.* 2006;147(1):47–55.
63. Haznedar MM, Buchsbaum MS, Hazlett EA, Shihabuddin L, New A, Siever LJ. Cingulate gyrus volume and metabolism in the schizophrenia spectrum. *Schizophr Res.* 2004;71(2–3):249–262.
64. Takahashi T, Kawasaki Y, Kurokawa K, et al. Lack of normal structural asymmetry of the anterior cingulate gyrus in female patients with schizophrenia: a volumetric magnetic resonance imaging study. *Schizophr Res.* 2002;55(1–2):69–81.
65. Choi JS, Kang DH, Kim JJ, et al. Decreased caudal anterior cingulate gyrus volume and positive symptoms in schizophrenia. *Psychiatry Res.* 2005;139(3):239–247.
66. Noga JT, Aylward E, Barta PE, Pearlson GD. Cingulate gyrus in schizophrenic patients and normal volunteers. *Psychiatry Res.* 1995;61(4):201–208.
67. Crespo-Facorro B, Kim J, Andreasen NC, O'Leary DS, Magnotta V. Regional frontal abnormalities in schizophrenia: a quantitative gray matter volume and cortical surface size study. *Biol Psychiatry.* 2000;48(2):110–119.
68. Fornito A, Yücel M, Wood SJ, et al. Surface-based morphometry of the anterior cingulate cortex in first episode schizophrenia. *Hum Brain Mapp.* 2008;29(4):478–489.
69. Takahashi T, Suzuki M, Kawasaki Y, et al. Perigenual cingulate gyrus volume in patients with schizophrenia: a magnetic resonance imaging study. *Biol Psychiatry.* 2003;53(7):593–600.
70. Kopelman A, Andreasen NC, Nopoulos P. Morphology of the anterior cingulate gyrus in patients with schizophrenia: relationship to typical neuroleptic exposure. *Am J Psychiatry.* 2005;162(10):1872–1878.
71. Hirayasu Y, Shenton ME, Salisbury DF, et al. Subgenual cingulate cortex volume in first-episode psychosis. *Am J Psychiatry.* 1999;156(7):1091–1093.
72. Coryell W, Nopoulos P, Drevets W, Wilson T, Andreasen NC. Subgenual prefrontal cortex volumes in major depressive disorder and schizophrenia: diagnostic specificity and prognostic implications. *Am J Psychiatry.* 2005;162(9):1706–1712.
73. Lopez-Garcia P, Aizenstein HJ, Snitz BE, Walter RP, Carter CS. Automated ROI-based brain parcellation analysis of frontal and temporal brain volumes in schizophrenia. *Psychiatry Res.* 2006;147(2–3):153–161.
74. Yücel M, Stuart GW, Maruff P, et al. Paracingulate morphologic differences in males with established schizophrenia: a magnetic resonance imaging morphometric study. *Biol Psychiatry.* 2002;52:15–23.
75. Le Provost JB, Bartres-Faz D, Paillere-Martinot ML, et al. Paracingulate sulcus morphology in men with early-onset schizophrenia. *Br J Psychiatry.* 2003;182:228–232.
76. Goghari VM, Rehm K, Carter CS, MacDonald AW, 3rd. Regionally specific cortical thinning and gray matter abnormalities in the healthy relatives of schizophrenia patients. *Cereb Cortex.* 2007;17(2):415–424.
77. McIntosh AM, Job DE, Moorhead TW, Harrison LK, Forrester K, Lawrie SM, Johnstone EC. Voxel-based morphometry of patients with schizophrenia or bipolar disorder and their unaffected relatives. *Biol Psychiatry.* 2004;56(8):544–552.
78. McIntosh AM, Job DE, Moorhead WJ, et al. Genetic liability to schizophrenia or bipolar disorder and its relationship to brain structure. *Am J Med Genet B Neuropsychiatr Genet.* 2006;141(1):76–83.
79. McDonald C, Bullmore ET, Sham PC, et al. Association of genetic risks for schizophrenia and bipolar disorder with specific and generic brain structural endophenotypes. *Arch Gen Psychiatry.* 2004;61(10):974–984.
80. Job DE, Whalley HC, McConnell S, Glabus M, Johnstone EC, Lawrie SM. Voxel-based morphometry of grey matter densities in subjects at high risk of schizophrenia. *Schizophr Res.* 2003;64(1):1–13.
81. Pantelis C, Velakoulis D, McGorry PD, et al. Neuroanatomical abnormalities before and after onset of psychosis: a cross-sectional and longitudinal MRI comparison. *Lancet.* 2003;361:281–288.
82. Yung AR, Phillips LJ, McGorry PD, et al. Prediction of psychosis. A step towards indicated prevention of schizophrenia. *Br J Psychiatry Suppl.* 1998;172(33):14–20.
83. Borgwardt SJ, Riecher-Rössler A, Dazzan P, et al. Regional gray matter volume abnormalities in the at risk mental state. *Biol Psychiatry.* 2007;61(10):1148–1156.
84. Job DE, Whalley HC, Johnstone EC, Lawrie SM. Grey matter changes over time in high risk subjects developing schizophrenia. *Neuroimage.* 2005;25(4):1023–1030.
85. Fornito A, Malhi GS, Lagopoulos J, et al. Anatomical abnormalities of the anterior cingulate cortex and paracingulate cortex in patients with bipolar I disorder. *Psychiatry Res.* 2008;162(2):123–132.
86. Kawasaki Y, Suzuki M, Nohara S, et al. Structural brain differences in patients with schizophrenia and schizotypal disorder demonstrated by voxel-based morphometry. *Eur Arch Psychiatry Clin Neurosci.* 2004;254(6):406–414.
87. Yoneyama E, Matsui M, Kawasaki Y, et al. Gray matter features of schizotypal disorder patients exhibiting the schizophrenia-related code types of the Minnesota Multiphasic Personality Inventory. *Acta Psychiatr Scand.* 2003;108(5):333–340.
88. Takahashi T, Suzuki M, Kawasaki Y, et al. Volumetric magnetic resonance imaging study of the anterior cingulate gyrus in schizotypal disorder. *Eur Arch Psychiatry Clin Neurosci.* 2002;252(6):268–277.
89. Farrow TF, Whitford TJ, Williams LM, Gomes L, Harris AW. Diagnosis-related regional gray matter loss over two years in first episode schizophrenia and bipolar disorder. *Biol Psychiatry.* 2005;58(9):713–723.
90. Whitford TJ, Grieve SM, Farrow TF, et al. Progressive grey matter atrophy over the first 2-3 years of illness in first-episode schizophrenia: a tensor-based morphometry study. *Neuroimage.* 2006;32(2):511–519.
91. van Haren NE, Hulshoff Pol HE, Schnack HG, et al. Focal gray matter changes in schizophrenia across the course of the illness: a 5-year follow-up study. *Neuropsychopharmacology.* 2007;32(10):2057–2066.
92. McCormick L, Decker L, Nopoulos P, Ho BC, Andreasen N. Effects of atypical and typical neuroleptics on anterior cingulate volume in schizophrenia. *Schizophr Res.* 2005;80(1):73–84.
93. Weinberger DR, McClure RK. Neurotoxicity, neuroplasticity, and magnetic resonance imaging morphometry: what is

- happening in the schizophrenic brain? *Arch Gen Psychiatry*. 2002;59:533–558.
94. Sowell ER, Thompson PM, Toga AW. Mapping changes in the human cortex throughout the span of life. *Neuroscientist*. 2004;10(4):372–392.
 95. Paus T, Collins DL, Evans AC, Leonard G, Pike B, Zijdenbos A. Maturation of white matter in the human brain: a review of magnetic resonance studies. *Brain Res Bull*. 2001;54(3):255–266.
 96. Stark AK, Uylings HB, Sanz-Arigitia E, Pakkenberg B. Glial cell loss in the anterior cingulate cortex, a subregion of the prefrontal cortex, in subjects with schizophrenia. *Am J Psychiatry*. 2004;161(5):882–888.
 97. Highley JR, Walker MA, Esiri MM, McDonald B, Harrison PJ, Crow TJ. Schizophrenia and the frontal lobes: post-mortem stereological study of tissue volume. *Br J Psychiatry*. 2001;178:337–343.
 98. Kreczmanski P, Schmidt-Kastner R, Heinsen H, Steinbusch HW, Hof PR, Schmitz C. Stereological studies of capillary length density in the frontal cortex of schizophrenics. *Acta Neuropathol*. 2005;109(5):510–518.
 99. Ongur D, Drevets WC, Price JL. Glial reduction in the subgenual prefrontal cortex in mood disorders. *Proc Natl Acad Sci U S A*. 1998;95(22):13290–13295.
 100. Bouras C, Kovari E, Hof PR, Riederer BM, Giannakopoulos P. Anterior cingulate cortex pathology in schizophrenia and bipolar disorder. *Acta Neuropathol (Berl)*. 2001;102(4):373–379.
 101. Benes FM, Vincent SL, Todtenkopf M. The density of pyramidal and nonpyramidal neurons in anterior cingulate cortex of schizophrenic and bipolar subjects. *Biol Psychiatry*. 2001;50(6):395–406.
 102. West MJ. Stereological methods for estimating the total number of neurons and synapses: issues of precision and bias. *Trends Neurosci*. 1999;22(2):51–61.
 103. Benes FM, Lange N. Two-dimensional versus three-dimensional cell counting: a practical perspective. *Trends Neurosci*. 2001;24(1):11–17.
 104. Benes FM, Davidson J, Bird ED. Quantitative cytoarchitectural studies of the cerebral cortex of schizophrenics. *Arch Gen Psychiatry*. 1986;43(1):31–35.
 105. Benes FM, McSparren J, Bird ED, SanGiovanni JP, Vincent SL. Deficits in small interneurons in prefrontal and cingulate cortices of schizophrenic and schizoaffective patients. *Arch Gen Psychiatry*. 1991;48(11):996–1001.
 106. Chana G, Landau S, Beasley C, Everall IP, Cotter D. Two-dimensional assessment of cytoarchitecture in the anterior cingulate cortex in major depressive disorder, bipolar disorder, and schizophrenia: evidence for decreased neuronal somal size and increased neuronal density. *Biol Psychiatry*. 2003;53(12):1086–1098.
 107. Cotter D, Mackay D, Landau S, Kerwin R, Everall I. Reduced glial cell density and neuronal size in the anterior cingulate cortex in major depressive disorder. *Arch Gen Psychiatry*. 2001;58(6):545–553.
 108. Jones LB, Johnson N, Byne W. Alterations in MAP2 immunocytochemistry in areas 9 and 32 of schizophrenic prefrontal cortex. *Psychiatry Res*. 2002;114(3):137–148.
 109. Selemon LD, Goldman-Rakic PS. The reduced neuropil hypothesis: a circuit based model of schizophrenia. *Biol Psychiatry*. 1999;45(1):17–25.
 110. Woo TU, Walsh JP, Benes FM. Density of glutamic acid decarboxylase 67 messenger RNA-containing neurons that express the N-methyl-D-aspartate receptor subunit NR2A in the anterior cingulate cortex in schizophrenia and bipolar disorder. *Arch Gen Psychiatry*. 2004;61(7):649–657.
 111. Benes FM, Bird ED. An analysis of the arrangement of neurons in the cingulate cortex of schizophrenic patients. *Arch Gen Psychiatry*. 1987;44(7):608–616.
 112. Seldon HL. Does brain white matter growth expand the cortex like a balloon? Hypothesis and consequences. *Laterality*. 2005;10(1):81–95.
 113. Harrison PJ, Weinberger DR. Schizophrenia genes, gene expression, and neuropathology: on the matter of their convergence. *Mol Psychiatry*. 2005;10(1):40–68.
 114. Glantz LA, Gilmore JH, Lieberman JA, Jarskog LF. Apoptotic mechanisms and the synaptic pathology of schizophrenia. *Schizophr Res*. 2006;81(1):47–63.
 115. Aganova EA, Uranova NA. Morphometric analysis of synaptic contacts in the anterior limbic cortex in the endogenous psychoses. *Neurosci Behav Physiol*. 1992;22(1):59–65.
 116. Landen M, Davidsson P, Gottfries CG, Mansson JE, Blennow K. Reduction of the synaptophysin level but normal levels of glycerophospholipids in the gyrus cinguli in schizophrenia. *Schizophr Res*. 2002;55(1–2):83–88.
 117. Davidsson P, Gottfries J, Bogdanovic N, et al. The synaptic-vesicle-specific proteins rab3a and synaptophysin are reduced in thalamus and related cortical brain regions in schizophrenic brains. *Schizophr Res*. 1999;40(1):23–29.
 118. Blennow K, Bogdanovic N, Heilig M, Grenfeldt B, Karlsson I, Davidsson P. Reduction of the synaptic protein rab3a in the thalamus and connecting brain regions in post-mortem schizophrenic brains. *J Neural Transm*. 2000;107(8–9):1085–1097.
 119. Benes FM, Majojcha R, Bird ED, Marotta CA. Increased vertical axon numbers in cingulate cortex of schizophrenics. *Arch Gen Psychiatry*. 1987;44(11):1017–1021.
 120. Benes FM, Sorensen I, Vincent SL, Bird ED, Sathi M. Increased density of glutamate-immunoreactive vertical processes in superficial laminae in cingulate cortex of schizophrenic brain. *Cereb Cortex*. 1992;2(6):503–512.
 121. Benes FM, Todtenkopf MS, Taylor JB. Differential distribution of tyrosine hydroxylase fibers on small and large neurons in layer II of anterior cingulate cortex of schizophrenic brain. *Synapse*. 1997;25(1):80–92.
 122. Dazzan P, Morgan KD, Orr K, et al. Different effects of typical and atypical antipsychotics on grey matter in first episode psychosis: the AESOP study. *Neuropsychopharmacology*. 2005;30(4):765–774.
 123. Selemon LD, Lidow MS, Goldman-Rakic PS. Increased volume and glial density in primate prefrontal cortex associated with chronic antipsychotic drug exposure. *Biol Psychiatry*. 1999;46(2):161–172.
 124. Glantz LA, Lewis DA. Dendritic spine density in schizophrenia and depression. *Arch Gen Psychiatry*. 2001;58(2):203.
 125. Cullen TJ, Walker MA, Eastwood SL, Esiri MM, Harrison PJ, Crow TJ. Anomalies of asymmetry of pyramidal cell density and structure in dorsolateral prefrontal cortex in schizophrenia. *Br J Psychiatry*. 2006;188:26–31.
 126. Miguel-Hidalgo JJ, Dubey P, Shao Q, Stockmeier C, Rajkowska G. Unchanged packing density but altered size of neurofilament immunoreactive neurons in the prefrontal cortex in schizophrenia and major depression. *Schizophr Res*. 2005;76(2–3):159–171.
 127. Cotter D, Mackay D, Chana G, Beasley C, Landau S, Everall IP. Reduced neuronal size and glial cell density in

- area 9 of the dorsolateral prefrontal cortex in subjects with major depressive disorder. *Cereb Cortex*. 2002;12(4):386–394.
128. Selemon LD, Rajkowska G, Goldman-Rakic PS. Elevated neuronal density in prefrontal area 46 in brains from schizophrenic patients: application of a three-dimensional, stereologic counting method. *J Comp Neurol*. 1998;392(3):402–412.
 129. Rajkowska G, Selemon LD, Goldman-Rakic PS. Neuronal and glial somal size in the prefrontal cortex: a postmortem morphometric study of schizophrenia and Huntington disease. *Arch Gen Psychiatry*. 1998;55(3):215–224.
 130. Longson D, Deakin JF, Benes FM. Increased density of entorhinal glutamate-immunoreactive vertical fibers in schizophrenia. *J Neural Transm*. 1996;103(4):503–507.
 131. Benes FM. Emerging principles of altered neural circuitry in schizophrenia. *Brain Res Rev*. 2000;31(2–3):251–269.
 132. Selemon LD. Regionally diverse cortical pathology in schizophrenia: clues to the etiology of the disease. *Schizophr Bull*. 2001;27(3):349–377.
 133. Sowell ER, Peterson BS, Thompson PM, Welcome SE, Henkenius AL, Toga AW. Mapping cortical change across the human life span. *Nat Neurosci*. 2003;6(3):309–315.
 134. Paus T. Mapping brain maturation and cognitive development during adolescence. *Trends Cogn Sci*. 2005;9(2):60–68.
 135. Braitenberg V. Brain size and number of neurons: an exercise in synthetic neuroanatomy. *J Comp Neurosci*. 2001;10(1):71–77.
 136. Gogtay N, Giedd JN, Lusk L, et al. Dynamic mapping of human cortical development during childhood through early adulthood. *Proc Natl Acad Sci U S A*. 2004;101(21):8174–8179.
 137. Sowell ER, Thompson PM, Leonard CM, Welcome SE, Kan E, Toga AW. Longitudinal mapping of cortical thickness and brain growth in normal children. *J Neurosci*. 2004;24(38):8223–8231.
 138. Sowell ER, Thompson PM, Tessner KD, Toga AW. Mapping continued brain growth and gray matter density reduction in dorsal frontal cortex: inverse relationships during postadolescent brain maturation. *J Neurosci*. 2001;21(22):8819–8829.
 139. Huttenlocher PR. Synaptic density in human frontal cortex—developmental changes and effects of aging. *Brain Res*. 1979;163(2):195–205.
 140. Huttenlocher PR. Morphometric study of human cerebral cortex development. *Neuropsychologia*. 1990;28(6):517–527.
 141. Vidal CN, Rapoport JL, Hayashi KM, et al. Dynamically spreading frontal and cingulate deficits mapped in adolescents with schizophrenia. *Arch Gen Psychiatry*. 2006;63(1):25–34.
 142. Benes FM. Myelination of cortical-hippocampal relays during late adolescence. *Schizophr Bull*. 1989;15(4):585–593.
 143. Cunningham MG, Bhattacharyya S, Benes FM. Amygdalo-cortical sprouting continues into early adulthood: implications for the development of normal and abnormal function during adolescence. *J Comp Neurol*. 2002;453(2):116–130.
 144. McGlashan TH, Hoffman RE. Schizophrenia as a disorder of developmentally reduced synaptic connectivity. *Arch Gen Psychiatry*. 2000;57(7):637–648.
 145. Benes FM, Walsh J, Bhattacharyya S, Sheth A, Berretta S. DNA fragmentation decreased in schizophrenia but not bipolar disorder. *Arch Gen Psychiatry*. 2003;60(4):359–364.
 146. Benes FM, Matzilevich D, Burke RE, Walsh J. The expression of proapoptosis genes is increased in bipolar disorder, but not in schizophrenia. *Mol Psychiatry*. 2006;11(3):241–251.
 147. Jarskog LF, Selinger ES, Lieberman JA, Gilmore JH. Apoptotic proteins in the temporal cortex in schizophrenia: high Bax/Bcl-2 ratio without caspase-3 activation. *Am J Psychiatry*. 2004;161(1):109–115.
 148. Jarskog LF, Gilmore JH, Selinger ES, Lieberman JA. Cortical bcl-2 protein expression and apoptotic regulation in schizophrenia. *Biol Psychiatry*. 2000;48(7):641–650.
 149. Jarskog LF. Apoptosis in schizophrenia: pathophysiologic and therapeutic considerations. *Curr Opin Psychiatry*. 2006;19(3):307–312.
 150. Jarskog LF, Glantz LA, Gilmore JH, Lieberman JA. Apoptotic mechanisms in the pathophysiology of schizophrenia. *Prog Neuropsychopharmacol Biol Psychiatry*. 2005;29(5):846–858.
 151. Olney JW. Excitotoxicity, apoptosis and neuropsychiatric disorders. *Curr Opin Pharmacol*. 2003;3(1):101–109.
 152. Buss RR, Sun W, Oppenheim RW. Adaptive roles of programmed cell death during nervous system development. *Annu Rev Neurosci*. 2006;29:1–35.
 153. McLaughlin B. The kinder side of killer proteases: caspase activation contributes to neuroprotection and CNS remodeling. *Apoptosis*. 2004;9(2):111–121.
 154. Stahl SM. Beyond the dopamine hypothesis to the NMDA glutamate receptor hypofunction hypothesis of schizophrenia. *CNS Spectr*. 2007;12(4):265–268.
 155. Javitt DC. Glutamate and schizophrenia: phencyclidine, N-methyl-D-aspartate receptors, and dopamine-glutamate interactions. *Int Rev Neurobiol*. 2007;78:69–108.
 156. Krystal JH, D'Souza DC, Mathalon D, Perry E, Belger A, Hoffman R. NMDA receptor antagonist effects, cortical glutamatergic function, and schizophrenia: toward a paradigm shift in medication development. *Psychopharmacology (Berl)*. 2003;169(3–4):215–233.
 157. Farber NB, Kim SH, Dikranian K, Jiang XP, Heinkel C. Receptor mechanisms and circuitry underlying NMDA antagonist neurotoxicity. *Mol Psychiatry*. 2002;7(1):32–43.
 158. Allen RM, Young SJ. Phencyclidine-induced psychosis. *Am J Psychiatry*. 1978;135(9):1081–1084.
 159. Luisada PV. The phencyclidine psychosis: phenomenology and treatment. *NIDA Res Monogr*. 1978;21:241–253.
 160. Luisada PV, Brown BI. Clinical management of the phencyclidine psychosis. *Clin Toxicol*. 1976;9(4):539–545.
 161. Erard R, Luisada PV, Peele R. The PCP psychosis: prolonged intoxication or drug-precipitated functional illness? *J Psychedelic Drugs*. 1980;12(3–4):235–251.
 162. Lahti AC, Weiler MA, Tamara Michaelidis BA, Parwani A, Tamminga CA. Effects of ketamine in normal and schizophrenic volunteers. *Neuropsychopharmacology*. 2001;25(4):455–467.
 163. Lahti AC, Koffel B, LaPorte D, Tamminga CA. Subanesthetic doses of ketamine stimulate psychosis in schizophrenia. *Neuropsychopharmacology*. 1995;13(1):9–19.
 164. Fix AS, Wightman KA, O'Callaghan JP. Reactive gliosis induced by MK-801 in the rat posterior cingulate/retrosplenial cortex: GFAP evaluation by sandwich ELISA and immunocytochemistry. *Neurotoxicology*. 1995;16(2):229–237.
 165. Olney JW, Farber NB. Glutamate receptor dysfunction and schizophrenia. *Arch Gen Psychiatry*. 1995;52:998–1007.

166. Farber NB, Wozniak DF, Price MT. Age-specific neurotoxicity in the rat associated with NMDA receptor blockade: potential relevance to schizophrenia? *Biol Psychiatry*. 1995;38(12):788–796.
167. Schurhoff F, Golmard JL, Szoke A, et al. Admixture analysis of age at onset in schizophrenia. *Schizophr Res*. 2004;71(1):35–41.
168. Karp HN, Kaufman ND, Anand SK. Phencyclidine poisoning in young children. *J Pediatr*. 1980;97(6):1006–1009.
169. Welch MJ, Correa GA. PCP intoxication in young children and infants. *Clin Pediatr (Phila)*. 1980;19(8):510–514.
170. Holcomb HH, Lahti AC, Medoff DR, Weiler M, Tamminga CA. Sequential regional cerebral blood flow brain scans using PET with H₂(15)O demonstrate ketamine actions in CNS dynamically. *Neuropsychopharmacology*. 2001;25(2):165–172.
171. Lahti AC, Holcomb HH, Medoff DR, Tamminga CA. Ketamine activates psychosis and alters limbic blood flow in schizophrenia. *Neuroreport*. 1995;6(6):869–872.
172. Holcomb HH, Lahti AC, Medoff DR, Cullen T, Tamminga CA. Effects of noncompetitive NMDA receptor blockade on anterior cingulate cerebral blood flow in volunteers with schizophrenia. *Neuropsychopharmacology*. 2005;30(12):2275–2282.
173. Vollenweider FX, Leenders KL, Scharfetter C, Maguire P, Stadelmann O, Angst J. Positron emission tomography and fluorodeoxyglucose studies of metabolic hyperfrontality and psychopathology in the psilocybin model of psychosis. *Neuropsychopharmacology*. 1997;16(5):357–372.
174. Theberge J, Bartha R, Drost DJ, et al. Glutamate and glutamine measured with 4.0 T proton MRS in never-treated patients with schizophrenia and healthy volunteers. *Am J Psychiatry*. 2002;159(11):1944–1946.
175. Bartha R, Williamson PC, Drost DJ, et al. Measurement of glutamate and glutamine in the medial prefrontal cortex of never-treated schizophrenic patients and healthy controls by proton magnetic resonance spectroscopy. *Arch Gen Psychiatry*. 1997;54(10):959–965.
176. Rowland LM, Bustillo JR, Mullins PG, et al. Effects of ketamine on anterior cingulate glutamate metabolism in healthy humans: a 4-T proton MRS study. *Am J Psychiatry*. 2005;162(2):394–396.
177. Hajszan T, Leranath C, Roth RH. Subchronic phencyclidine treatment decreases the number of dendritic spine synapses in the rat prefrontal cortex. *Biol Psychiatry*. 2006;60(6):639–644.
178. Ikonomidou C, Bosch F, Miksa M, et al. Blockade of NMDA receptors and apoptotic neurodegeneration in the developing brain. *Science*. 1999;283(5398):70–74.
179. Holmes CJ, Hoge R, Collins L, Woods R, Toga AW, Evans AC. Enhancement of MR images using registration for signal averaging. *J Comp Assist Tomogr*. 1998;22(2):324–333.
180. Wright IC, Ellison ZR, Sharma T, Friston KJ, Murray RM, McGuire PK. Mapping of grey matter changes in schizophrenia. *Schizophr Res*. 1999;35:1–14.
181. Sowell ER, Levitt J, Thompson PM, et al. Brain abnormalities in early-onset schizophrenia spectrum disorder observed with statistical parametric mapping of structural magnetic resonance images. *Am J Psychiatry*. 2000;157(9):1475–1484.
182. Foong J, Symms MR, Barker GJ, et al. Neuropathological abnormalities in schizophrenia: evidence from magnetization transfer imaging. *Brain*. 2001;124(pt 5):882–892.
183. Hulshoff Pol HE, Schnack HG, Mandl RC, et al. Focal gray matter density changes in schizophrenia. *Arch Gen Psychiatry*. 2001;58(12):1118–1125.
184. Paillere-Martinot M, Caclin A, Artiges E, et al. Cerebral gray and white matter reductions and clinical correlates in patients with early onset schizophrenia. *Schizophr Res*. 2001;50(1–2):19–26.
185. Sigmundsson T, Suckling J, Maier M, et al. Structural abnormalities in frontal, temporal, and limbic regions and interconnecting white matter tracts in schizophrenic patients with prominent negative symptoms. *Am J Psychiatry*. 2001;158(2):234–243.
186. Wilke M, Kaufmann C, Grabner A, Putz B, Wetter TC, Auer DP. Gray matter-changes and correlates of disease severity in schizophrenia: a statistical parametric mapping study. *Neuroimage*. 2001;13(5):814–824.
187. Ananth H, Popescu I, Critchley HD, Good CD, Frackowiak RS, Dolan RJ. Cortical and subcortical gray matter abnormalities in schizophrenia determined through structural magnetic resonance imaging with optimized volumetric voxel-based morphometry. *Am J Psychiatry*. 2002;159(9):1497–1505.
188. Job DE, Whalley HC, McConnell S, Glabus M, Johnstone EC, Lawrie SM. Structural gray matter differences between first-episode schizophrenics and normal controls using voxel-based morphometry. *Neuroimage*. 2002;17(2):880–889.
189. Kubicki M, Shenton ME, Salisbury DF, et al. Voxel-based morphometric analysis of gray matter in first episode schizophrenia. *Neuroimage*. 2002;17(4):1711–1719.
190. Shapleske J, Rossell SL, Chitnis XA, et al. A computational morphometric MRI study of schizophrenia: effects of hallucinations. *Cereb Cortex*. 2002;12(12):1331–1341.
191. Suzuki M, Nohara S, Hagino H, et al. Regional changes in brain gray and white matter in patients with schizophrenia demonstrated with voxel-based analysis of MRI. *Schizophr Res*. 2002;55(1–2):41–54.
192. Bagary MS, Symms MR, Barker GJ, Mutsatsa SH, Joyce EM, Ron MA. Gray and white matter brain abnormalities in first-episode schizophrenia inferred from magnetization transfer imaging. *Arch Gen Psychiatry*. 2003;60(8):779–788.
193. Kuperberg GR, Broome MR, McGuire PK, et al. Regionally localized thinning of the cerebral cortex in schizophrenia. *Arch Gen Psychiatry*. 2003;60:878–888.
194. Marcelis M, Suckling J, Woodruff P, Hofman P, Bullmore E, van Os J. Searching for a structural endophenotype in psychosis using computational morphometry. *Psychiatry Res*. 2003;122(3):153–167.
195. Salgado-Pineda P, Baeza I, Perez-Gomez M, et al. Sustained attention impairment correlates to gray matter decreases in first episode neuroleptic-naive schizophrenic patients. *Neuroimage*. 2003;19(2 pt 1):365–375.
196. Ha TH, Youn T, Ha KS, et al. Gray matter abnormalities in paranoid schizophrenia and their clinical correlations. *Psychiatry Res*. 2004;132(3):251–260.
197. Moorhead TW, Job DE, Whalley HC, Sanderson TL, Johnstone EC, Lawrie SM. Voxel-based morphometry of comorbid schizophrenia and learning disability: analyses in normalized and native spaces using parametric and non-parametric statistical methods. *Neuroimage*. 2004;22(1):188–202.
198. Salgado-Pineda P, Junque C, Vendrell P, et al. Decreased cerebral activation during CPT performance: structural and

- functional deficits in schizophrenic patients. *Neuroimage*. 2004;21(3):840–847.
199. Antonova E, Kumari V, Morris R, et al. The relationship of structural alterations to cognitive deficits in schizophrenia: a voxel-based morphometry study. *Biol Psychiatry*. 2005; 58(6):457–467.
 200. Davatzikos C, Shen D, Gur RC, et al. Whole-brain morphometric study of schizophrenia revealing a spatially complex set of focal abnormalities. *Arch Gen Psychiatry*. 2005; 62(11):1218–1227.
 201. Jayakumar PN, Venkatasubramanian G, Gangadhar BN, Janakiramaiah N, Keshavan MS. Optimized voxel-based morphometry of gray matter volume in first-episode, anti-psychotic-naïve schizophrenia. *Prog Neuropsychopharmacol Biol Psychiatry*. 2005;29(4):587–591.
 202. McDonald C, Bullmore E, Sham P, et al. Regional volume deviations of brain structure in schizophrenia and psychotic bipolar disorder: computational morphometry study. *Br J Psychiatry*. 2005;186:369–377.
 203. Narr KL, Toga AW, Szeszko P, et al. Cortical thinning in cingulate and occipital cortices in first episode schizophrenia. *Biol Psychiatry*. 2005;58(1):32–40.
 204. Whitford TJ, Farrow TF, Gomes L, Brennan J, Harris AW, Williams LM. Grey matter deficits and symptom profile in first episode schizophrenia. *Psychiatry Res*. 2005;139(3): 229–238.
 205. Neckelmann G, Specht K, Lund A, et al. MR morphometry analysis of grey matter volume reduction in schizophrenia: association with hallucinations. *Int J Neurosci*. 2006; 116(1):9–23.
 206. Ohnishi T, Hashimoto R, Mori T, et al. The association between the Val158Met polymorphism of the catechol-O-methyl transferase gene and morphological abnormalities of the brain in chronic schizophrenia. *Brain*. 2006;129(pt 2): 399–410.
 207. Park HJ, Lee JD, Chun JW, et al. Cortical surface-based analysis of 18F-FDG PET: measured metabolic abnormalities in schizophrenia are affected by cortical structural abnormalities. *Neuroimage*. 2006;31(4):1434–1444.
 208. Chua SE, Cheung C, Cheung V, et al. Cerebral grey, white matter and csf in never-medicated, first-episode schizophrenia. *Schizophr Res*. 2007;89(1–3):12–21.
 209. Kasperek T, Prikryl R, Mikl M, Schwarz D, Ceskova E, Krupa P. Prefrontal but not temporal grey matter changes in males with first-episode schizophrenia. *Prog Neuropsychopharmacol Biol Psychiatry*. 2007;31(1):151–157.
 210. Kawasaki Y, Suzuki M, Kherif F, et al. Multivariate voxel-based morphometry successfully differentiates schizophrenia patients from healthy controls. *Neuroimage*. 2007;34(1): 235–242.
 211. Pagsberg AK, Baare WF, Raabjerg Christensen AM, et al. Structural brain abnormalities in early onset first-episode psychosis. *J Neural Transm*. 2007;114(4):489–498.
 212. Yamada M, Hirao K, Namiki C, et al. Social cognition and frontal lobe pathology in schizophrenia: a voxel-based morphometric study. *Neuroimage*. 2007;35(1):292–298.
 213. Good CD, Johnsrude IS, Ashburner J, Henson RN, Friston KJ, Frackowiak RS. A voxel-based morphometric study of ageing in 465 normal adult human brains. *Neuroimage*. 2001;14(1 pt 1):21–36.
 214. Talairach J, Tournoux P. *Co-planar Stereotaxic Atlas of the Human Brain*. New York, NY: Thieme; 1988.
 215. Brett M, Johnsrude IS, Owen AM. The problem of functional localization in the human brain. *Nat Rev Neurosci*. 2002;3(3):243–249.
 216. Szeszko PR, Bilder RM, Lencz T, et al. Investigation of frontal lobe subregions in first-episode schizophrenia. *Psychiatry Res*. 1999;90:1–15.
 217. Marquardt RK, Levitt JG, Blanton RE, et al. Abnormal development of the anterior cingulate in childhood-onset schizophrenia: a preliminary quantitative MRI study. *Psychiatry Res*. 2005;138(3):221–233.
 218. Yamasue H, Fukui T, Fukuda R, et al. 1H-MR spectroscopy and gray matter volume of the anterior cingulate cortex in schizophrenia. *Neuroreport*. 2002;13(16):2133–2137.
 219. Caviness VS, Jr, Meyer J, Makris N, Kennedy DN. MRI-based topographic parcellation of human neocortex: An anatomically specified method with estimate of reliability. *J Cogn Neurosci*. 1996;8(6):566–587.
 220. Crespo-Facorro B, Kim JJ, Andreasen NC, et al. Human frontal cortex: an MRI-based parcellation method. *Neuroimage*. 1999;10:500–519.
 221. Takahashi T, Suzuki M, Zhou SY, et al. Lack of normal gender differences of the perigenual cingulate gyrus in schizophrenia spectrum disorders. A magnetic resonance imaging study. *Eur Arch Psychiatry Clin Neurosci*. 2004; 254(5):273–280.
 222. Steiner J, Mawrin C, Ziegeler A, et al. Distribution of HLA-DR-positive microglia in schizophrenia reflects impaired cerebral lateralization. *Acta Neuropathol*. 2006;112(3): 305–316.