

Abrupt onset of type 1 diabetes mellitus during recombinant interferon-alpha 2b therapy in a patient with chronic hepatitis B

Yuan-Yuan Lv, Bing-Yin Shi, Hui Guo

Yuan-Yuan Lv, Bing-Yin Shi, Hui Guo, Department of Endocrinology, First Affiliated Hospital, Medical School of Xi'an Jiaotong University, Xi'an 710061, Shaanxi Province, China

Author contributions: Lv YY and Shi BY contributed equally to this work; Lv YY, Shi BY and Guo H treated the patient; Lv YY and Shi BY designed the immunofluorescence test; Lv YY performed the test and wrote the paper.

Correspondence to: Bing-Yin Shi, Department of Endocrinology, First Affiliated Hospital, Medical School of Xi'an Jiaotong University, 277 Yanta West Road, Xi'an 710061, Shaanxi Province, China. shibingy@126.com

Telephone: +86-29-85323974 Fax: +86-29-85323974

Received: May 19, 2008 Revised: July 7, 2008

Accepted: July 14, 2008

Published online: August 7, 2008

Lv YY, Shi BY, Guo H. Abrupt onset of type 1 diabetes mellitus during recombinant interferon-alpha 2b therapy in a patient with chronic hepatitis B. *World J Gastroenterol* 2008; 14(29): 4713-4715 Available from: URL: <http://www.wjgnet.com/1007-9327/14/4713.asp> DOI: <http://dx.doi.org/10.3748/wjg.14.4713>

INTRODUCTION

Interferon-alpha (IFN- α) is now widely used in the treatment of chronic hepatitis B and C. Systemic side effects of IFN- α therapy can affect numerous organ systems. These adverse reactions include flu-like syndrome, hematological abnormalities, cardiovascular and central nervous symptoms, gastrointestinal symptoms, pulmonary dysfunction, depression and retinopathy. Besides, IFN- α has been shown to be related to the development of a variety of autoimmune diseases, including systemic lupus erythematosus (SLE), rheumatoid arthritis (RA) and autoimmune thyroid diseases (AITDs). However, the development of type 1 diabetes mellitus (DM) is relatively rare and few patients with positive islet cell autoantibody (ICAb) or glutamic acid decarboxylase autoantibody (GADAb) have been reported^[1-3]. Here, we report the first case of a patient suffering from chronic hepatitis B who had an unexpected onset of type 1 DM during IFN- α 2b therapy in China.

CASE REPORT

A 33-year-old woman with a body mass index (BMI) of 22.49 kg/m² was treated with recombinant human IFN- α 2b at a dosage of 3 million units (MU) once every other day from April 2006 because of hepatitis B. Ten months after IFN- α 2b treatment, both hepatitis B e antigen (HBeAg) and HBV DNA became negative, and serum aminotransferases returned to normal. However, 13 mo after initiation of IFN- α 2b treatment (reaching 585 MU of total dose in May 2007), the patient complained of weakness, polydipsia, polyuria and a rapid weight loss (5 kg within 10 d). She was then admitted to our hospital. Her clinical data on admission are shown in Table 1. Urinalysis showed glucosuria and ketonuria.

Abstract

We describe a case of a 33-year-old female patient with chronic hepatitis B who developed type 1 diabetes mellitus (DM) after a 13-mo period of treatment with recombinant human interferon-alpha (IFN- α) 2b. The patient presented with polydipsia, polyuria, hyperglycemia, diabetic ketoacidosis, combined with C-peptide secretion deficiency and positive islet cell autoantibody (ICAb). IFN- α 2b treatment was terminated and instead insulin treatment was initiated. Five months after cessation of the recombinant human IFN- α 2b therapy, the patient remained insulin-dependent. Her serum HBV DNA became negative and serum transaminase returned to the normal level after a 10-mo period of IFN therapy. Type 1 DM induced by IFN- α is relatively rare in patients with chronic hepatitis B. We should pay more attention to patients on IFN- α therapy to avoid destruction of pancreatic beta cells. This is the first case report from China.

© 2008 The WJG Press. All rights reserved.

Key words: Interferon-alpha; Islet cell autoantibody; Type 1 diabetes mellitus; Autoimmune disease; Chronic hepatitis B

Peer reviewer: Satoshi Yamagiwa, MD, PhD, Division of Gastroenterology and Hepatology, Niigata University Graduate School of Medical and Dental Sciences, 757 Asahimachi-dori 1, Chuo-ku, Niigata 951-8510, Japan

Table 1 Laboratory findings in the patient on admission

| Laboratory findings | |
|-------------------------------|---------------------------|
| Urinalysis | |
| Glucose | (+++) |
| Ketobody | (++++) |
| Protein | (-) |
| CBC | |
| RBC | $3.94 \times 10^{12}/L$ |
| Hb | 124 g/L |
| WBC | $5.1 \times 10^9/L$ |
| Plt | $62 \times 10^9/L$ |
| Blood chemistry | |
| Fasting plasma glucose | 31.7 mmol/L (570.6 mg/dL) |
| Arterial blood gas analysis | |
| pH | 7.314 |
| PCO ₂ | 35.1 mmHg |
| PO ₂ | 70.6 mmHg |
| HCO ₃ ⁻ | 11.5 mmol/L |
| BE | -3.6 mmol/L |
| TP | 87.1 g/L |
| ALB | 48 g/L |
| AST | 36 IU/L |
| ALT | 40 IU/L |
| ALP | 98 IU/L |
| GGT | 21 IU/L |
| Serology | |
| HbA1c | 10.0% |
| HBs Ag | (+) |
| HBs Ab | (-) |
| HBe Ag | (-) |
| HBe Ab | (-) |
| HBcAb | (+) |
| HBV DNA (PCR) | < 1000 copies/mL |
| IgG | 18.37 g/L |
| IgA | 2.79 g/L |
| IgM | 1.87 g/L |
| TSH | 0.636 mIU/mL |
| FT3 | 4.03 pmol/L |
| FT4 | 16.3 pmol/L |
| TPOAb | (-) |
| TgAb | (-) |
| ANA | (-) |
| Anti-DNA Ab | (-) |
| RF | (-) |

Fasting plasma glucose and glycosylated hemoglobin (HbA1c) were 31.7 mmol/L (570.6 mg/dL) and 10.0%, respectively. Arterial blood gas analysis showed metabolic acidosis. Serum aspartate aminotransferase (AST) and alanine aminotransferase (ALT) were within normal range. Hepatitis B surface antigen (HBsAg) and anti-HB core antibody (HBcAb) in serum were positive. The fasting plasma C-peptide level was low. The curve of C-peptide response to 75 g glucose load was flat (Table 2). The serum ICAb was positive (Figure 1). The patient had no family history of type 1 DM or other autoimmune disorders. She had no symptoms of other autoimmune diseases. Other autoantibodies including thyroid peroxidase antibody (TPOAb), thyroglobulin antibody (TgAb), antinuclear antibody (ANA), anti-dsDNA antibody, anti-RNP, anti-SSA, anti-SSB, and rheumatoid factor (RF) were all negative. Taken together, clinical and laboratory data confirmed the diagnosis of type 1 DM with ketoacidosis. Administration of IFN was immediately terminated. Her clinical condition improved with diet

Table 2 Results of oral glucose tolerance test (75 g)

| Time (min) | Blood glucose (mmol/L) | C-peptide (pmol/mL) |
|------------|------------------------|---------------------|
| 0 | 7.5 | 0.29 |
| 30 | 10.8 | 0.40 |
| 60 | 15.0 | 0.61 |
| 120 | 18.3 | 0.77 |
| 180 | 14.1 | 0.78 |

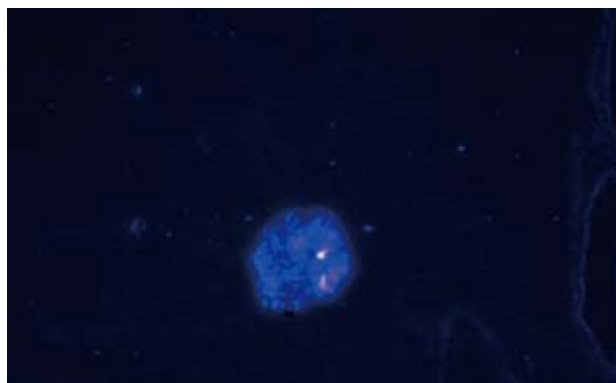


Figure 1 Positive islet cell autoantibody in pancreas from a mouse at 1:40 serum dilution tested by immunofluorescence assay ($\times 200$).

therapy, intravenous fluids and insulin therapy (isophane protamine biosynthetic human insulin, Novolin[®] R, Novo Nordisk, Denmark). Ketonuria disappeared after 12 h insulin therapy for. Following normalization of the acute metabolic disturbances, intensive insulin therapy was recommended with four daily doses of subcutaneous insulin: each before every meal and last at bedtime. Four days later, fasting plasma glucose decreased to 5.6 mmol/L (100 mg/dL). Five months after cessation of IFN- α 2b therapy, the patient remained insulin dependent with a daily requirement of 20 units Novolin[®] 30R. The plasma C-peptide level was still low. Serum HbA1c level was 6.5%. Serum aminotransferase was normal, and serum HBV DNA remained undetectable.

DISCUSSION

IFN- α has different biologic effects (antiviral, antiproliferative, immunomodulatory), and has been used in treatment of chronic viral hepatitis for nearly 20 years^[4]. IFN- α acts on many target cells and organs. The thyroid represents the main target for autoimmunity associated with IFN- α therapy. Although several reports indicate a beneficial effect on glucose metabolism^[5-7], IFN- α has been considered to have a variety of effects on pancreatic beta cells^[1-3,8,9]. In 1992, Fabris *et al*^[10] reported the first case of type 1 DM in a chronic hepatitis C patient treated with IFN- α and concluded that IFN could trigger autoimmune destruction of pancreatic beta cells.

IFN- α therapy-induced autoimmunity of pancreatic beta cells has been evaluated in some studies^[11-14]. The prevalence of ICAb, GADAb, insulin autoantibody (IAA), and/or tyrosine-like phosphatase autoantibody

(IA2Ab) is not generally increased in patients with chronic viral infection prior to IFN- α therapy compared with normal control subjects. In 50% of the previously reported patients, markers of pancreatic autoimmunity predated treatment, the majority of cases having a genetic predisposition (HLA-DR3/-DR4 was positive)^[15]. However, after IFN- α treatment, the prevalence of pancreatic autoantibodies may increase from 3% to 7% with type 1 DM developed in a few cases. Therefore, IFN- α therapy may induce type 1 DM in genetically and immunologically predisposed individuals.

The exact mechanism underlying the development of type 1 DM in chronic viral hepatitis patients treated with IFN- α is unclear. A variety of mechanisms may account for the effect of IFN- α on pancreatic beta cell dysfunction^[14]. First, IFN- α activates the oligoadenylate synthase-RnaseL pathway and the protein kinase R pathway, thus inducing apoptosis of pancreatic beta cells. Second, IFN- α may stimulate a counter regulatory hormone secretion (growth hormone, glucagon, *etc.*), thus resulting in impaired glucose tolerance. Third, regarding type 1 DM, IFN- α may favor the development of Th1 immune reaction and thereby contribute to the development of autoimmune disease by activating CD4 lymphocytes secreting IL-2, IFN- γ , and tumor necrosis factor. IFN- α is also associated with over-expression of MHC class I antigens in human islets of pancreas. In addition to IFN- α , HCV infection can increase the frequency of pancreatic autoimmunity. That is why IFN- α -induced type 1 DM is relatively rare in chronic hepatitis B patients.

Transient insulin dependency was observed in some cases and permanent insulin administration was required in the other reported cases. These data demonstrate that in some cases the autoimmune attack is at least partially reversible with interruption of interferon therapy^[15].

In conclusion, development of type 1 DM should be considered as one of the risk consequences after IFN- α therapy. In order to avoid it, administration of IFN- α in special patients should be evaluated, weighing the risk of diabetes and the benefit of the treatment. We conclude that patients having positive islet autoantibodies, HLA-DR3/-DR4, impaired glucose regulation, or positive family history of diabetes mellitus, should be considered to have a higher risk of developing type 1 DM following IFN- α treatment^[13]. Physicians should be cautious of the use of IFN therapy.

REFERENCES

- 1 Mofredj A, Howaizi M, Grasset D, Licht H, Loison S, Devergie B, Demontis R, Cadranel JF. Diabetes mellitus during interferon therapy for chronic viral hepatitis. *Dig Dis Sci* 2002; **47**: 1649-1654
- 2 Cozzolongo R, Betterle C, Fabris P, Paola Albergoni M,

- Lanzilotta E, Manghisi OG. Onset of type 1 diabetes mellitus during peginterferon alpha-2b plus ribavirin treatment for chronic hepatitis C. *Eur J Gastroenterol Hepatol* 2006; **18**: 689-692
- 3 Radhakrishnan S, Upadhyay A, Mohan N, Dhar A, Walia HK, Zubaidi G. Late development of diabetes mellitus after interferon-alfa and ribavirin therapy for chronic hepatitis C: a case report. *Med Princ Pract* 2005; **14**: 281-283
- 4 Betterle C, Fabris P, Zanchetta R, Pedini B, Tositti G, Bosi E, de Lalla F. Autoimmunity against pancreatic islets and other tissues before and after interferon-alpha therapy in patients with hepatitis C virus chronic infection. *Diabetes Care* 2000; **23**: 1177-1181
- 5 Konrad T, Vicini P, Zeuzem S, Toffolo G, Briem D, Lormann J, Herrmann G, Wittmann D, Lenz T, Kusterer K, Teuber G, Cobelli C, Usadel KH. Interferon-alpha improves glucose tolerance in diabetic and non-diabetic patients with HCV-induced liver disease. *Exp Clin Endocrinol Diabetes* 1999; **107**: 343-349
- 6 Konrad T, Zeuzem S, Vicini P, Toffolo G, Briem D, Lormann J, Herrmann G, Berger A, Kusterer K, Teuber G, Cobelli C, Usadel KH. Evaluation of factors controlling glucose tolerance in patients with HCV infection before and after 4 months therapy with interferon-alpha. *Eur J Clin Invest* 2000; **30**: 111-121
- 7 Tai TY, Lu JY, Chen CL, Lai MY, Chen PJ, Kao JH, Lee CZ, Lee HS, Chuang LM, Jeng YM. Interferon-alpha reduces insulin resistance and beta-cell secretion in responders among patients with chronic hepatitis B and C. *J Endocrinol* 2003; **178**: 457-465
- 8 Tosone G, Borgia G, Gentile I, Cerini R, Conte MC, Orlando R, Piazza M. A case of pegylated interferon alpha-related diabetic ketoacidosis: can this complication be avoided? *Acta Diabetol* 2007; **44**: 167-169
- 9 Jabr FI, Ordinario MM. Sudden onset of diabetic ketoacidosis during pegylated interferon alfa therapy. *Am J Med* 2003; **115**: 158-159
- 10 Fabris P, Betterle C, Floreani A, Greggio NA, de Lazzari F, Naccarato R, Chiaramonte M. Development of type 1 diabetes mellitus during interferon alfa therapy for chronic HCV hepatitis. *Lancet* 1992; **340**: 548
- 11 Piquer S, Hernandez C, Enriquez J, Ross A, Esteban JL, Genesa J, Bonifacio E, Puig-Domingo M, Simo R. Islet cell and thyroid antibody prevalence in patients with hepatitis C virus infection: effect of treatment with interferon. *J Lab Clin Med* 2001; **137**: 38-42
- 12 Wesche B, Jaeckel E, Trautwein C, Wedemeyer H, Falorni A, Frank H, von zur Muhlen A, Manns MP, Brabant G. Induction of autoantibodies to the adrenal cortex and pancreatic islet cells by interferon alpha therapy for chronic hepatitis C. *Gut* 2001; **48**: 378-383
- 13 Wasmuth HE, Stolte C, Geier A, Gartung C, Matern S. Induction of multiple autoantibodies to islet cell antigens during treatment with interferon alpha for chronic hepatitis C. *Gut* 2001; **49**: 596-597
- 14 Soultati AS, Dourakis SP, Alexopoulou A, Deutsch M, Archimandritis AJ. Simultaneous development of diabetic ketoacidosis and Hashitoxicosis in a patient treated with pegylated interferon-alpha for chronic hepatitis C. *World J Gastroenterol* 2007; **13**: 1292-1294
- 15 Fabris P, Floreani A, Tositti G, Vergani D, De Lalla F, Betterle C. Type 1 diabetes mellitus in patients with chronic hepatitis C before and after interferon therapy. *Aliment Pharmacol Ther* 2003; **18**: 549-558

S- Editor Li DL L- Editor Wang XL E- Editor Ma WH