



Case report

## **Choroidal metastasis from tubulopapillary renal cell carcinoma: a case report**

Ibrahim Elghissassi\*, Hanane Inrhaoun, Nabil Ismaili and Hassan Errihani

Address: Department of Medical Oncology, National Institute of Oncology, Rabat, Morocco

Email: IE\* - i\_elghissassi@hotmail.com; HI - in\_hanane@yahoo.fr; NI - Nabil@yahoo.fr; HE - h\_errihani@yahoo.fr

\* Corresponding author

Received: 21 March 2009 Accepted: 30 May 2009 Published: 29 June 2009

*Cases Journal* 2009, **2**:6681 doi: 10.4076/1757-1626-2-6681

This article is available from: <http://casesjournal.com/casesjournal/article/view/6681>

© 2009 Elghissassi et al; licensee Cases Network Ltd.

This is an Open Access article distributed under the terms of the Creative Commons Attribution License (<http://creativecommons.org/licenses/by/3.0>), which permits unrestricted use, distribution, and reproduction in any medium, provided the original work is properly cited.

### **Abstract**

Choroidal metastases from renal carcinoma are rare. Most reported cases describe a clear cell carcinoma histologic subtype. Metastatic tubulopapillary renal cell carcinoma to the choroid plexus is very exceptional.

We report the case of a 31-year-old man with a history of tubulopapillary renal cell carcinoma who presented two years later with metastatic disease to lungs and presternal soft tissue and three months after with choroidal metastasis revealed on ophthalmoscopic examination and magnetic resonance imaging.

The case is discussed in the framework of the existing literature about the clinical features, treatment, and prognosis of this very rare condition.

### **Introduction**

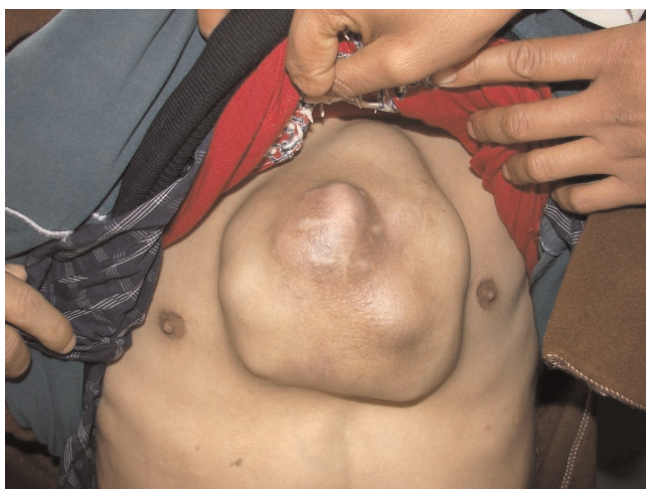Kidney cancer accounts for approximately 2.5% of all adult cancers. Clear cell carcinoma is the most common histologic subtype followed by tubulopapillary renal cell carcinoma (TPRCC) who represents about 10% of all renal cell tumours [1]. This tumor metastasizes most frequently to lung, liver, bone, and subcutaneous tissues. Choroidal metastasis from TPRCC is extremely rare. The present study describes a case of choroidal metastasis from a TPRCC.

### **Case presentation**

A 31-year-old Berber Moroccan man was admitted in June 2005 for investigation of painless haematuria. His medical history was otherwise unremarkable. A suspicious left

kidney mass was discovered and the patient underwent left radical nephrectomy. Pathological examination reported 'moderately differentiated' TPRCC. The tumour was confined to the pelvis, with no evidence of distant metastases at this stage.

Two years later, he presented with a rapidly growing mass located on midline anterior chest wall (Figure 1). Thoracic CT-scan showed irregularity and sclerosis of lower part of sternum with a large presternal soft tissue mass and multiple opacities throughout both lung fields consistent with pulmonary metastases. A radionuclide bone scan revealed a single area of uptake of radiotracer in the sternum. Abdominopelvic CT-scan was normal. Routine hematological, liver function and renal function tests



**Figure 1.** A midline anterior chest wall mass.

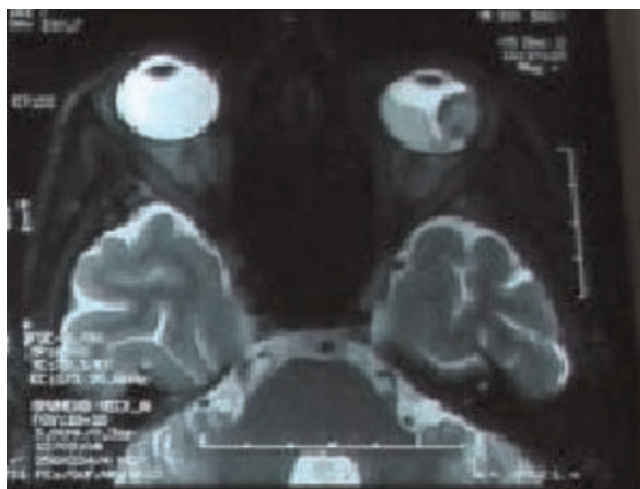
were within normal ranges. A biopsy of the mass was performed and histopathological examination confirmed the diagnosis of metastatic TPRCC.

The patient received medical treatment which included interferon alfa-2a (9 MIU subcutaneously three times weekly) and bevacizumab (10 mg/kg every 2 weeks). After three months of this treatment, a repeat thoracic and abdominopelvic CT scan demonstrated a progressive disease with increasing of the presternal mass by 40% and appearance of multiple liver metastases. Furthermore, the patient developed severe headaches and blurred vision in the left eye. Ophthalmoscopic examination of the left eye showed a yellow choroidal mass, measuring about half a disc diameter and located below and lateral to the macular area, which was highly characteristic of choroidal metastasis. Cerebral magnetic resonance imaging was performed and showed a left lateral choroidal mass with secondary retinal detachment. This radiological aspect was consistent with the diagnosis of choroidal metastasis (Figure 2). Radiation therapy was begun to the left eye, but the patient's condition deteriorated rapidly and he died two weeks later.

### Discussion

The first choroidal metastasis case was described by Perl in 1872 [2]. Godfredsen, reported a 0.07% incidence of clinically detected choroidal metastasis in patients with systemic malignancy in 1944 [3]. Since then, the reported incidence of choroidal metastasis has been increasing related to advances in ophthalmic diagnostic techniques and the treatment of systemic cancers [4].

Although breast and lung cancers represent the most common source of choroidal metastases, malignancies of



**Figure 2.** A left lateral choroidal mass with secondary retinal detachment on magnetic resonance imaging.

the gastrointestinal tract, kidney, prostate and skin have all been reported to metastasize to the choroid [5]. Most reported cases of metastasis to the choroid plexus from renal cell carcinoma describe a clear cell carcinoma histologic subtype. The mechanism of this association is still unclear. Choroidal metastasis from TPRCC, as in our case, remains very exceptional [6].

Clinically, the most common symptoms are blurring of vision, photopsia, floaters and pain whereas some patients may be asymptomatic. Typical ophthalmoscopic features include one or multiples creamy yellow choroidal lesions associated in some advanced cases with secondary retinal detachment [7].

In patients with metastatic cancer to the choroids, the most appropriate treatment seems to be a course of external beam radiation therapy. Radiotherapy can improve vision with a high response rate (63-89%) [8] and prevent pain and secondary glaucoma [9]. Systemic chemotherapy or hormonotherapy may be effective to control choroidal metastasis with 26-81% tumor control rate reported [10,11]. In cases of painful blind eye, enucleation may be considered [12].

The prognosis for choroidal metastasis is generally poor. The median survival was found to be as short as 8 months after the onset of metastatic disease [13].

Choroidal metastasis from renal carcinoma is a rare condition that should not be overlooked. A high index of suspicion and adequate investigation of patients with visual complaints and history of renal carcinoma are needed.

## Abbreviations

TPRCC, Tubulopapillary renal cell carcinoma; CT, Computed tomography.

## Consent

Written informed consent was obtained from the patient's wife for publication of this case report. A copy of the written consent is available for review by the Editor-in-Chief of this journal.

## Competing interests

The authors declare that they have no competing interests.

## Authors' contributions

IE and HI were major contributors in writing the manuscript. NI and HE involved in revising the manuscript. All authors read and approved the final manuscript.

## References

1. Sibony M, Vieillefond A: **Non clear cell renal cell carcinoma. 2008 update in renal tumor pathology.** *Ann Pathol* 2008, **28**:381-401.
2. Perl M: **Contributions to pathology of tumours.** *Virchow's Arch Pathol Anat* 1872, **56**:445-448.
3. Godtfredsen E: **On frequency of secondary carcinoma of choroid.** *Acta Ophthalmol* 1944, **22**:394-400.
4. Bloch RS, Gartner S: **The incidence of ocular metastatic carcinoma.** *Arch Ophthalmol* 1971, **85**:673-675.
5. Shields CL, Shields JA, Gross NE, Schwartz GP, Lally SE: **Survey of 520 uveal metastases.** *Ophthalmology* 1997, **104**:1265-1276.
6. Kadrian D, Tan L: **Single choroid plexus metastasis 16 years after nephrectomy for renal cell carcinoma: case report and review of the literature.** *J Clin Neurosci* 2004, **11**:88-91.
7. Soysal HG: **Metastatic tumors of the uvea in 38 eyes.** *Can J Ophthalmol* 2007, **42**:832-835.
8. Smith JA, Gragoudas ES, Dreyer EB: **Uveal metastases.** *Int Ophthalmol Clin* 1997, **37**:183-199.
9. Rudoler SB, Corn BV, Shields CL, De Potter P, Hyslop T, Shields JA, Curran WJ Jr: **External beam irradiation for choroid metastases: identification of factors predisposing to long-term sequelae.** *Int J Radiat Oncol Biol Phys* 1997, **38**:251-256.
10. Demirci H, Shields CL, Chao A, Shields J: **Uveal metastasis from breast cancer in 264 patients.** *Am J Ophthalmol* 2003, **136**:264-271.
11. Soysal HG: **Metastatic tumors of the uvea in 38 eyes.** *Can J Ophthalmol* 2007, **42**:832-835.
12. Volpe NJ, Albert DM: **Metastasis to the uvea.** In *Principles and Practice of Ophthalmology*. 2nd edition. Edited by Albert DM & Jakobiec FA. Philadelphia: W.B. Saunders Company; 2000:5073-5080.
13. Shields CL: **Plaque radiotherapy for the management of uveal metastasis.** *Curr Opin Ophthalmol* 1998, **9**:31-37.

## Do you have a case to share?

Submit your case report today

- Rapid peer review
- Fast publication
- PubMed indexing
- Inclusion in Cases Database

Any patient, any case, can teach us something



**CASES  
NETWORK**

[www.casesnetwork.com](http://www.casesnetwork.com)