



Case report

Haemolytic anaemia secondary to arsenic poisoning: a case report

Nuno Correia^{1*}, Catarina Carvalho², Fernando Friões³, José P Araújo³,
Jorge Almeida³ and Ana Azevedo^{1,4}

Addresses: ¹Department of Internal Medicine, Hospital São João, Alameda Prof. Hernâni Monteiro, 4200 – 319 Porto, Portugal

²Department of Nephrology, Hospital São João, Alameda Prof. Hernâni Monteiro, 4200 – 319 Porto, Portugal

³Intermediate Care Unit, Department of Internal Medicine, Hospital São João, Alameda Prof. Hernâni Monteiro, 4200 – 319 Porto, Portugal

⁴Department of Hygiene and Epidemiology, University of Porto Medical School, Alameda Prof. Hernâni Monteiro, 4200 – 319 Porto, Portugal

Email: NC* - nunovox@gmail.com; CC - catarinagcarvalho@sapo.pt; FF - fbfrioes@gmail.com; JPA - pauloaraujo@iol.pt;

JA - jorge.salmeida@hsjoao.min-saude.pt; AA - anavez@med.up.pt

* Corresponding author

Received: 12 May 2009 Accepted: 16 July 2009 Published: 11 August 2009

Cases Journal 2009, 2:7768 doi: 10.4076/1757-1626-2-7768

This article is available from: <http://casesjournal.com/casesjournal/article/view/7768>

© 2009 Correia et al.; licensee Cases Network Ltd.

This is an Open Access article distributed under the terms of the Creative Commons Attribution License (<http://creativecommons.org/licenses/by/3.0>), which permits unrestricted use, distribution, and reproduction in any medium, provided the original work is properly cited.

Abstract

We report the case of a 56-year-old white man who presented at the Emergency Department for evaluation of dark-red urine. Rapid development of acute renal failure and haemolytic anaemia initially elicited the hypothesis of a haemolytic-uremic syndrome. A previous exposure to a gas mixture containing arsenic and copper was later recognized as the probable aetiology while other differential diagnoses were excluded. Chelating treatment was promptly initiated before laboratorial confirmation of arsenic and copper poisoning. Renal and haematological recovery was gradually observed and the patient survived with no sequelae.

Introduction

Haemolytic anaemia may be secondary to a wide range of causes either inherited or acquired. The former include disturbances affecting haemoglobin, the membrane-cytoskeleton complex and enzyme deficiency states. The latter include mechanical destruction, drugs, infections, autoimmune disorders or toxic agents.

Toxic agents are an uncommon cause of haemolysis, which may develop even in people without metabolic abnormalities. Many chemicals, due to their oxidative potential, can lead to haemolysis. Other agents act through non oxidative, largely unknown mechanisms, such as arsine, stibine, copper, and lead [1].

Acute poisoning with heavy metals is a rare cause for evaluation in the Emergency Department. Its identification may prove difficult particularly in unconscious patients with no obvious history. A low-level exposure may even be disregarded by the patient himself. This may challenge the initial approach for a problem which can result in a lethal outcome.

Case presentation

A 56-year-old white man was referred to our Emergency Department (ED) for evaluation of dark-red urine.

The patient complained of a general feeling of sickness, diffuse muscle pain, transient episodes of diaphoresis and

chills, with no fever, associated with nausea and bilious vomiting for the past 24 hours. The appearance of dark-red coloured urine, resembling blood, motivated his search for medical care.

He denied abdominal pain or any recent traumatic event. His past medical history was positive for chronic gastritis. He had no past of nephrolithiasis or haematological disorders. He was taking a protein-pump inhibitor and denied use of any over-the-counter substances. He was an occasional pipe smoker and had no history of alcohol abuse or illicit drug consumption. His family history was unremarkable.

On physical examination, his blood pressure was 132/78 mmHg, with a heart rate of 78 beats per minute, a tympanic temperature of 36.8°C, and a respiratory rate of 18 breaths per minute. There were no signs of dehydration. He had no costovertebral angle tenderness. He had no chronic liver disease stigmata. Further examination, including neurological evaluation, was unremarkable. Initial laboratory data included: Hb = 13.8 g/dL, MCV = 101.4 fL, MCHC = 32.3 g/dL, RDW = 79.8 fl, WBC = 18.01 × 10⁹/L, PLT = 209 × 10⁹/L; CRP = 8.5 mg/L, Cr = 1.55 mg/dL, Urea = 80 mg/dL. Urinalysis revealed proteinuria (3+), leukocyturia (80 cells/HPF), numerous renal tubular epithelial cells, no erythrocyturia, and absent nitrites or urobilinogen. Urinary tract ultrasound excluded signs of lithiasis or obstruction and revealed bilateral renal parenchyma hyperechogenicity and slight perirenal oedema at the right kidney; bladder wall visualization did not show suspicious lesions and the prostate was normal.

He was admitted to the Urology Department for a suspected urinary tract infection. A few hours later his condition deteriorated. He developed jaundice, fever

(38.6°C), diarrhoea and mental confusion. His blood panel revealed a normocytic normochromic anaemia with anisocytosis (Hb = 8.0 g/dL, RDW = 83.2 fl), predominantly indirect hyperbilirubinemia (TB = 5.82 mg/dL, DB = 0.51 mg/dL), high LDH (4415 U/L), elevation of inflammatory markers (WBC = 20.85 × 10⁹/L, CRP = 108 mg/L) and worsening renal dysfunction (Cr = 3.59 mg/dL, Urea = 188 mg/dL) (Table 1).

He was transferred to the Intermediate Care Unit of the Internal Medicine Department. Additional exams included an ECG with normal sinus rhythm and normal QTc interval (416 ms), a normal chest X-ray, a blood smear with rare schizocytes, negative direct and indirect Coombs tests and a fractional excretion of sodium of 3.49%. These data pointed to a haemolytic cause for the rapidly worsening anaemia (Table 1) and acute renal failure in this context.

The association of acute renal failure and haemolytic anaemia elicited the hypothesis of a haemolytic-uremic syndrome. Considering other causes for a haemolytic physiopathology which could not be immediately excluded and the severity of the clinical condition of the patient, plasmapheresis with fresh frozen plasma was initiated and RBC transfused as needed.

Clinical history was revisited. The patient owned a factory of zippers where chemical compounds were frequently used in plating techniques. At this time the patient recalled accidental inhalation of a possible toxic gas nearly 32 hours before, while performing a new plating process wearing no protection. The gas resulted from the mixture of a so-called "tin's oxidant" with a metal alloy. This exposure lasted no longer than 5 minutes and nearly 4 hours later he remembered feeling "sick". Detailed

Table 1. In-hospital laboratorial course

	Day 1	Day 1*	Day 2	Day 3	Day 5	Day 6	Day 8	Day 10	Day 18
Hb, g/dL	13.8	11.5	8.0	9.4	8.7	7.9	9.3	9.9	10
WBC × 10 ⁹ /L	18.01	18.44	20.85	10.56	8.71	8.64	12.39	11.82	12.74
PLT × 10 ⁹ /L	209	167	141	69	89	89	124	250	299
CRP, mg/L	8.5	25.4	108.7	52	40.9	28.8	85.5	104	87.9
AST, U/L		112	121			207	57	34	35
ALT, U/L		33	36			193	156	91	31
γGT, U/L		18	19						27
ALP, U/L		71	62						43
TB, mg/dL		2.06	5.82	6.16		0.94	1.02	0.66	0.63
DB, mg/dL		0.43	0.51	0.48		0.23	0.72	0.15	0.14
LDH, U/L			4115	1430		997	659	549	289
Urea, mg/dL	80	135	188	182	144	112	70	65	59
Cr, mg/dL	1.55	2.56	3.59	4.96	4.43	4.34	3.45	3.86	2.79

Exposure to a gas mixture containing arsenic and copper occurred nearly 32 hours before initial medical evaluation. One session of plasmapheresis was performed at in-hospital day 2. Penicillamine was administered from day 4 to 7, followed by dimercaprol during 10 days. Transfusion with 1 pack of red blood cells was performed at day 2. Haemolytic anaemia, renal dysfunction and hepatotoxicity recovered gradually after chelation therapy.

* Laboratorial results at approximately 12 hours of admission.

information about this chemical substance was immediately requested.

At day 3, nearly 90 hours after the accidental exposure, the composition of the toxic substance was known. "Tin's oxidant", as the patient named it, included 40-45% of chlorhydric acid (HCl), 1.2-1.4% of copper sulphate (CuSO₄), and 5-6% of arsenic trioxide (As₂O₃). Plasmapheresis was stopped at this time.

Blood and 24-hour urine samples were sent to the laboratory for measurement of arsenic and copper levels. Chelation treatment was initiated with Penicillamin (1800mg/day *per os*), before laboratorial confirmation, in order to address both copper and arsenic intoxication. Initial therapy with intramuscular Dimercaprol was postponed due to thrombocytopenia.

The patient completed 3 days of Penicillamin, followed by the administration of intramuscular Dimercaprol 200 mg at the following regime: 4-hourly in the first 6 days, then 6-hourly at day 7 and 8, and 12-hourly at day 9 and 10. Simultaneously, forced alkalinisation was performed, with fluid therapy as necessary.

Quantitative measurements were available at in-hospital day 7 and confirmed high levels of arsenic and copper in urine and blood (Table 2). Further measurements demonstrated a progressive decline under the expected chelation reaction (Figure 1). In repeated blood gas analysis there was no methaemoglobin, a possible consequence of copper intoxication.

During in-hospital stay, patient's symptoms gradually vanished and recovery of haematological, renal and liver disturbances was observed. He did not present any neurological or respiratory abnormalities. Syalorrhea and inflammatory signs at intramuscular injection sites developed as a consequence of dimercaprol treatment. After 13 days of chelation he was discharged and referred for follow-up appointments at the Internal Medicine and Nephrology Outpatient Clinic.

One month later he remained asymptomatic. Physical examination was unremarkable. Six months later his haemoglobin level and renal function were normal

Table 2. Arsenic and copper blood and urine concentration 90 hours after exposure (available at in-hospital day 7)

	Results (µg/L)	Normal values
Arsenic		
24h urine	445	<100 µg/L
Blood	297	<70 µg/L
Copper		
24h urine	137.9	15-60 µg/L
Blood	745	0.7-1.5 µg/L

Arsenic and copper quantification

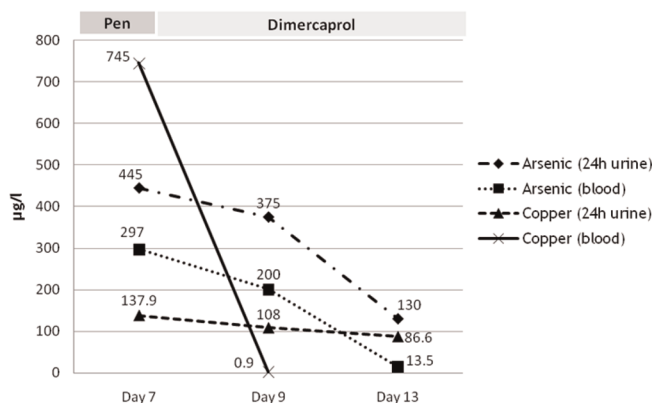


Figure 1. Plotted concentrations of arsenic and copper in blood and urine samples under chelation therapy. Chelating therapy was preceded, three days before, by one session of plasmapheresis. Penicillamine (Pen) was administrated between days 4 and 7, followed by dimercaprol from days 8 to 18. Normal values: arsenic (24 h urine) <100 µg/L; arsenic (blood) <70 µg/L; copper (24 h urine) = 15-60 µg/L; copper (blood) = 0.7-1.5 µg/L.

(Hb = 14.8 g/dL; MCV = 89.1 fL; MCHC = 34.1 g/dL; Cr = 1.02 mg/dL, Urea = 46 mg/dL). The patient was discharged.

Discussion

Arsenic is one the four most hazardous toxicants, along with cadmium, lead, and mercury. Metal poisoning can result from exposure to inhaled dusts, fumes or vapours. Another possible route comes from ingestion of contaminated food, drinks or by hand-to-mouth exposure [2-4].

This patient presented with many of the classical clinical findings attributed to arsenic acute intoxication. Initial unspecific features of acute gastrointestinal findings may be underappreciated, particularly if a recent exposure is not known. Acute toxicity with arsenic manifests within hours as nausea, vomiting, diarrhea, abdominal pain. Severe poisoning may result in multi-organ failure, delirium, seizures, coma, and ultimately death. If the patient survives, bone marrow suppression, peripheral neuropathy and skin lesions may develop [2-4].

Haemolytic anemia secondary to acute intoxication with arsenic is a well-recognized effect [2-4]. Arsenic-related haemolysis may also be a consequence of chronic intoxication [5].

The gaseous state is one the most toxic forms of arsenic [6]. Cases of intoxication with arsine gas have been published mostly as a result of accidental work-related exposures [6-9].

Because arsine is nonirritating and produces no immediate symptoms, persons exposed to hazardous levels may be unaware of its presence. In contrast with reported cases following arsenic poisoning [8,10-17], our patient did not develop respiratory failure.

Additionally, direct heart toxicity may result in disturbances of the electrical conduction system [2-4,15]. One report described an early manifestation of *torsade de pointes* after acute arsenic poisoning [18].

We can only retrospectively speculate about the initial exposure dosage, which possibly was not high enough to implicate direct respiratory or cardiac damage.

Treatment should be promptly initiated under high suspicion of a recent intoxication. Primary treatment in acute arsenic poisoning involves rapid decontamination and early initiation of chelation therapy with agents such as dimercaprol (British Anti-Lewisite, BAL), edentate (EDTA), succimer (DMSA, dimercaptosuccinic acid) and penicillamine. No specific antidote is available and there are no controlled trials regarding different therapeutic strategies [2-4].

A recent case report has suggested plasma exchange as an effective early treatment intervention for acute arsenic poisoning [19]. In our case, plasmapheresis was performed regarding the hypothesis of a haemolytic-uremic syndrome, before any toxicodrome was suspected. However, it may have contributed for the benign clinical course since chelating treatment was only initiated nearly 100 hours after exposure.

In this case, it is not possible to separate the haemolytic effect of copper from the arsenic one, since copper intoxication may also cause haemolysis [20]. Methaemoglobinemia is a frequent complication of copper poisoning which may require additional therapeutic strategies [20]. Its absence in the presented case points against a major contribution of this metal in patient's clinical course.

Conclusion

We report a rare case of haemolytic anaemia following arsenic and copper acute intoxication. The unusual nature of this aetiology and the delayed awareness of a possible toxic exposure challenged the diagnosis.

Common consequences of arsenic poisoning are haemolysis and renal failure.

Because of the severity of the clinical course, including multi-organ failure and a high risk of death, therapeutic strategies should presumptively be initiated without

formal laboratory confirmation. Evidence-based treatment options are limited. Use of chelating agents, such as dimercaprol, is recommended. Whether plasma exchange should be a primary, an alternative or additional treatment option remains unclear, although its early use may be an effective treatment.

Abbreviations

ALP, alkaline phosphatase; Cr, creatinine; CRP, C-reactive protein; DB, direct bilirubin; FENa, fractional excretion of sodium; γ GT, gamma glutamyl transpeptidase; Hb, haemoglobin; HPF, high power field; LDH, lactate dehydrogenase; MCHC, mean corpuscular haemoglobin concentration; MCV, medium corpuscular volume; PLT, platelet; RDW, red cell distribution width; TB, total bilirubin; WBC, white blood cell.

Consent

Written informed consent was obtained from the patient for publication of this case report. A copy of the written consent is available for the review by the Editor-in-Chief of this journal.

Competing interests

The authors declare that they have no competing interests.

Authors' contributions

NC gathered patient information, interpreted data, did literature research, and wrote the first draft of the manuscript. CC contributed majorly to preparation of the manuscript and participated in management of plasmapheresis. JPA, JA and FF were responsible for the patient during admission to Intermediate Care Unit, including differential diagnosis, confirmation of final diagnosis and treatment decisions. AA was responsible for the management of the patient after discharge from the Intermediate care Unit and follow up at the outpatient clinic. All authors were involved in the clinical management of the patient, and read and approved the final manuscript.

Acknowledgements

The authors are grateful to Prof. Dra. Maria de Lourdes Bastos, Head of the Laboratory of Toxicology of the Faculty of Pharmacy of the University of Porto, for the collaboration in toxicological analyses.

References

- Luzzato L: **Hemolytic Anemias and Anemia Due to Acute Blood Loss**. In *Harrison's Principle Internal Medicine*. 17th edition. Edited by Fauci AS, Braunwald E, Kasper DL, Hauser SL, Longo DL, Jameson JL, Loscalzo J. New-York: McGraw-Hill; 2008, 652-662.
- Arsenic exposure and poisoning**. [<http://www.uptodate.com>]
- Ratnaike RH: **Acute and chronic arsenic toxicity**. *Postgrad Med J* 2003, **79**:391-396.
- Ford M: **Arsenic**. In *Goldfrank's toxicologic emergencies*. 7th edition. Edited by Goldfrank LR, Flomenbaum NE, Lewin N, Howland MA, Hoffman R, Nelson L. New York: McGraw-Hill; 2002, 1183-1195.

5. Lee JJ, Kim YK, Cho SH, Park KS, Chung JJ, Cho D, Ryang DW, Kim HJ: **Hemolytic anemia as a sequel of arsenic intoxication following long-term ingestion of traditional Chinese medicine.** *J Korean Med Sci* 2004, **19**:127-129.
6. Pakulska D, Czerczak S: **Hazardous effects of arsine: a short review.** *Int J Occup Med Environ Health* 2006, **19**:36-44.
7. Romeo L, Apostoli P, Kovacic M, Martini S, Brugnone F: **Acute arsine intoxication as a consequence of metal burnishing operations.** *Am J Ind Med* 1997, **32**:211-216.
8. Barbee JY Jr, Prince TS: **Acute respiratory distress syndrome in a welder exposed to metal fumes.** *South Med J* 1999, **92**:510-512.
9. Sanz Guajardo A, Montero Garcia A, Moreno Heredia E, Sánchez Sicilia L: **Hemolysis and acute renal failure in collective arsine poisoning (study of 5 cases).** *Rev Clin Esp* 1970, **119**:525-532.
10. Dueñas-Laita A, Pérez-Miranda M, González-López MA, Martín-Escudero JC, Ruiz-Mambrilla M, Blanco-Varela J: **Acute arsenic poisoning - case report.** *Lancet* 2005, **365**:1982.
11. Isbister GK, Dawson AH: **Arsenic trioxide poisoning: a description of two acute overdoses.** *Hum Exp Toxicol* 2004, **23**:359-364.
12. Lai MW, Boyer EW, Kleinman ME, Rodig NM, Ewald MB: **Acute arsenic poisoning in two siblings.** *Pediatrics* 2005, **116**:249-257.
13. Wang EE, Mahajan N, Wills B, Leikin J: **Successful treatment of potentially fatal heavy metal poisonings.** *J Emerg Med* 2007, **32**:289-294.
14. Vantroyen B, Heillier JF, Meulemans A, Michels A, Buchet JP, Vanderschueren S, Haufroid V, Sabbe M: **Survival after a lethal dose of arsenic trioxide.** *J Toxicol Clin Toxicol* 2004, **42**:889-895.
15. Civantos DP, López Rodríguez A, Aguado-Borruey JM, Narvaez JA: **Fulminant malignant arrhythmia and multiorgan failure in acute arsenic poisoning.** *Chest* 1995, **108**:1774-1775.
16. Greenberg C, Davies S, McGowan T, Schorer A, Drage C: **Acute respiratory failure following severe arsenic poisoning.** *Chest* 1979, **76**:596-598.
17. Bolliger CT, van Zijl P, Louw JA: **Multiple organ failure with the adult respiratory distress syndrome in homicidal arsenic poisoning.** *Respiration* 1992, **59**:57-61.
18. Ortega Carnicer J, Ruiz Lorenzo F, Mañas García D, Ceres Alabau F: **Torsades de Pointes precoces y elevación sérica de la troponina I debidas a intoxicación aguda por arsénico.** *Med Intensiva* 2006, **30**:77-80.
19. Song Y, Wang D, Li H, Hao F, Ma J, Xia Y: **Severe acute arsine poisoning treated by plasma exchange.** *Clin Toxicol (Phila)* 2007, **45**:721-727.
20. Franchitto N, Gandia-Mailly P, Georges B, Galinier A, Telmon N, Ducassé JL, Rougé D: **Acute copper sulphate poisoning: a case report and literature review.** *Resuscitation* 2008, **78**:92-96.

Do you have a case to share?

Submit your case report today

- Rapid peer review
- Fast publication
- PubMed indexing
- Inclusion in Cases Database

Any patient, any case, can teach us something



**CASES
NETWORK**

www.casesnetwork.com