

Gallstone Obstructive Ileus 3 Years Post-cholecystectomy to a Patient with an Old Ileoileal Anastomosis

The present case is one of gallstone obstructive ileus due to gallstones 3 yr after laparoscopic cholecystectomy. It is interesting because of the sex of the patient, the fact that ileus occurred 3 yr after cholecystectomy and that the localization of the obstruction was an old side-to-side ileoileal anastomosis due to a diverticulectomy following intussusception of Meckels' diverticulum at the age of 3.

Key Words : Gallstones; Ileus

TS Papavramidis¹, S Potsi²,
D Paramythiotis¹, A Michalopoulos¹,
VN Papadopoulos¹, V Douros¹,
A Pantoleon², A Foutzila-Kalogera²,
I Ekonomou², and N Harlaftis¹

1st Propedeutic Surgical Clinic¹, Department of
Radiology², Aristotle University of Thessaloniki,
A.H.E.P.A. University Hospital, Thessaloniki, Greece

Received : 22 October 2007
Accepted : 22 June 2008

Address for correspondence

Theodosis Papavramidis, M.D.
1st Propedeutic Surgical Clinic, Aristotle University of
Thessaloniki, A.H.E.P.A. University Hospital, 30
Korytsas Str, Panorama, Thessaloniki 55236, Greece
Tel : +30-2310-344835, Fax : +30-6944536972
E-mail : papavramidis@hotmail.com

INTRODUCTION

Gallstone ileus is an infrequent cause of intestinal obstruction, responsible for 1-4% of all mechanical intestinal obstructions (1). It is due to a gallstone larger than 2.5 cm in diameter that usually obstructs terminal jejunum. The gallstone usually enters the bowel via a cholecystoenteric fistula (2), resulting from recurrent attacks of cholecystitis. Gallstone ileus is usually a disease of the elderly and occurs more frequently in females (3).

The present case is interesting because, 1) the patient was a young male; 2) the ileus occurred 3 yr after cholecystectomy and 3) the localization of the obstruction was an old side-to-side ileoileal anastomosis due to a diverticulectomy following intussusception of Meckels' diverticulum at the age of 3.

CASE REPORT

A 44-yr-old man presented to the emergency department with lower abdominal pain of 3 days' duration, associated with nausea, diarrhea and failure to pass flatus and feces. The last year he presented again with an episode of severe abdominal pain, but the abdominal examination was unremarkable.

His medical anamnesis reports Gilbert syndrome, appendectomy and Meckel's diverticulectomy due to intussus-

ception at the age of three, and laparoscopic cholecystectomy three years before admission.

Physical examination showed mild abdominal distension, tenderness in the epigastrium, and dehydration with breaking of the skin and glue tongue. Auscultation revealed high-pitched abdominal sounds. Laboratory studies revealed a haematocrit of 35.4%, hemoglobin of 11.7 g/dL and white blood cell count 8.700/ μ L with a predominance of polymorph nuclear cells (66.4%). His liver function tests were all within normal limits with total bilirubin of 7.6 mg/dL.

Plain films of the abdomen showed multiple air-fluid interfaces in the small intestine and colon full of gas. There was no evidence of pneumobilia, but there were surgical clips at the anatomic area of the right upper quadrant. Two calcified opacities were detected in the left iliac fossa at the supine radiograph (RX), which changed location at the erect RX (Fig. 1). At profile plain RX of the abdomen the two intraluminal abnormalities appeared in the dilated small bowel of terminal ileum (Fig. 1), compatible with gallstones.

Ultrasonography (US) was performed revealing edema and thickening of the bowel wall and dilatation of the loops of small bowel, which showed active peristalsis diagnostic of mechanical small bowel obstruction. Gallstones were identified within the dilated bowel as floating hyper-echoic foci producing distal acoustic shadowing reflections, which moved when the patient's position was, changed (Fig. 2).

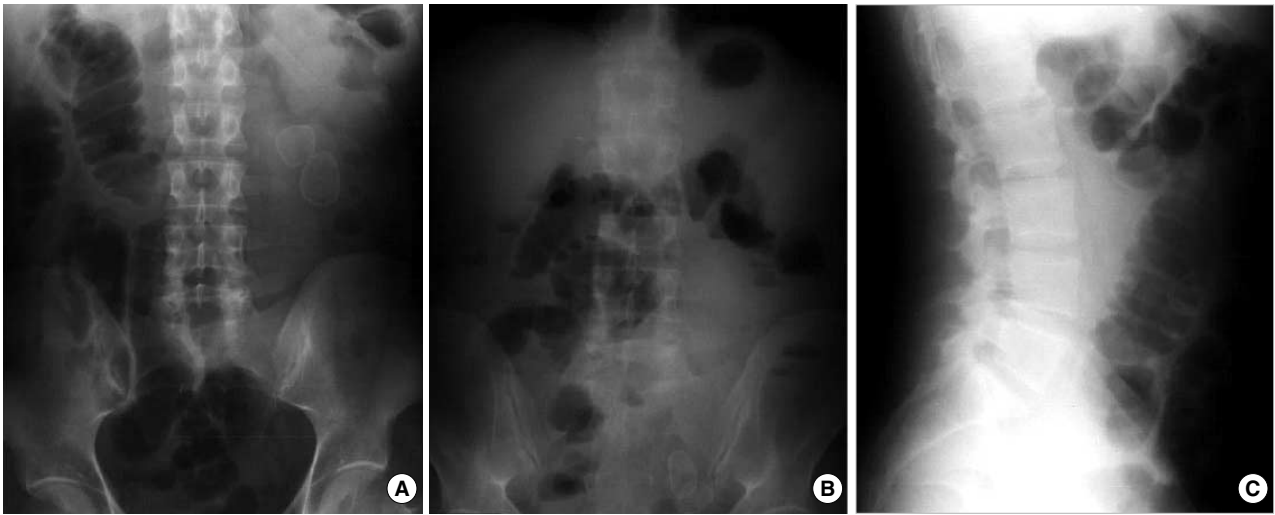


Fig. 1. Two calcified opacities were detected in the left iliac fossa at the supine radiograph (RX), (A) which changed location at the erect RX. (B) At profile plain RX of the abdomen these two intraluminal abnormalities appeared in the dilated small bowel of terminal ileum, (C) compatible with gallstones.

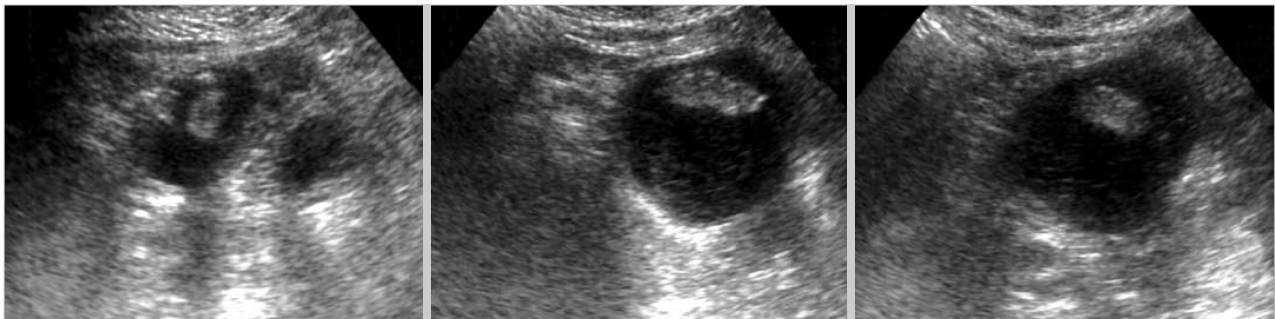

Fig. 2. Gallstones were identified within the dilated bowel as floating hyper-echoic foci producing distal acoustic shadowing reflections, which moved when the patient's position was changed.

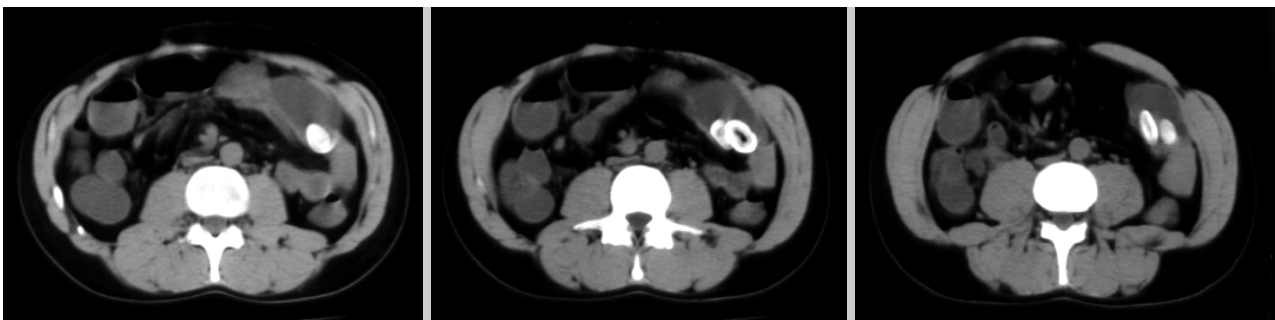

Fig. 3. CT scans showed multiple air-fluid interfaces the distended small bowel loops and two big ectopic peripheral calcified stones with radiolucent centers in the dilated small bowel.

The computed tomography (CT) showed multiple air-fluid interfaces, distended small bowel loops and two big ectopic peripheral calcified stones with radiolucent centers in the dilated small bowel of terminal ileum. One of them had a thick calcified surface and hypo-dense center which the form is like Mercedes-Benz figure. The stones had an average diameter

of 3 cm (Fig. 3).

The patient underwent exploratory laparotomy. A restricted side-to-side ileoileic anastomosis was found at the terminal ileum together with multiple adhesions. Adhesiolysis was performed and excision of the previous anastomosis. A new laterolateral ileoileic anastomosis was performed. In the excised

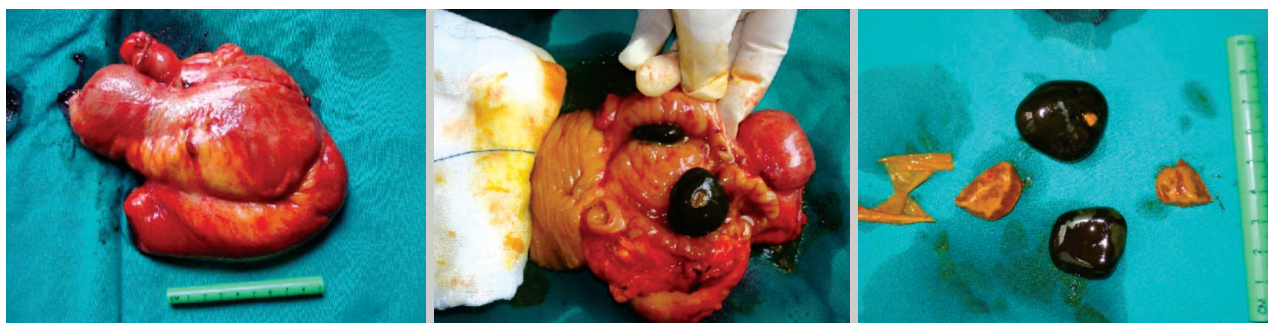

Fig. 4. Side-to-side ileoileic anastomosis. The stone's colour was black and their size was about 3 cm in diameter.

Table 1. Chemical analysis of the gallstones. Values are expressed at mg/g of dry weight of stone powder

| Organic | mg/g | Inorganic | mg/g |
|-------------------|--------|------------------|-------|
| Total cholesterol | 513.26 | K ⁺ | 3.17 |
| Total bilirubin | 4.97 | Na ⁺ | 0.58 |
| Bile acids | 20.53 | Ca ²⁺ | 28.20 |
| Fatty acids | 13.98 | Mg ²⁺ | 11.03 |
| Triglycerides | 31.57 | P | 8.98 |
| Phospholipids | 6.54 | Oxalate | 6.99 |
| Soluble proteins | 102.87 | | |

intestine two calculi sized approximately 3 cm were removed by enterotomy. The patient's postoperative course was uneventful (Fig. 4). Pathology revealed bilirubin stones. Furthermore, in order to have chemical analysis the stones were powdered in a pestle and mortar and dissolved in different solvents depending upon the type of chemical constituent to be analyzed. The results of the chemical analysis are presented in Table 1.

DISCUSSION

The pathogenesis of gallstone ileus necessitates the presence of a gallstone in the intestinal lumen, the most common route of entry being a cholecystenteric fistula resulting from recurrent attacks of cholecystitis. A cholecystoduodenal fistula was demonstrated in 68% of patients with gallstone ileus by Clavien et al. (4). Stones passing spontaneously through the ampulla of Vater have also been reported to cause gallstone ileus (5), besides the fact that more than 80% of gallstones entering the gut are excreted uneventfully (6). The present patient had recurrent attacks of cholelithiasis and underwent laparoscopic cholecystectomy. The existence or not of a bilioenteric fistula is unknown. Concerning the present patient, we can't identify the way through which the stones arrived to the intestine, but we are pretty sure that they enlarged in the gut, at the site of the old anastomosis. The stones had probably remained in the anastomosis and under dyskinesia and stasis the bacterial overgrowth caused

large gallstone formation. The localization of the stones further explained the symptoms of the patient-notably intermittent partial obstruction- during the last two year. Probably the bilirubin stones impacted and disimpacted within the old anastomosis that resulted in presentation and relief of the symptoms.

Rigler's criteria (7): 1) air or contrast medium in the biliary tree, 2) visualization of the stone in the intestine, 3) change in position of a previously observed stone, and 4) radiologic evidence of intestinal obstruction are pathognomonic in the diagnosis of gallstone ileus. In the present case three out of these four criteria were fulfilled and, even if the images were typical, the diagnosis of gallstone ileus was many times challenged due to the prior cholecystectomy. At this point we have to agree with Lassandro et al. (8) that CT shows important details such as: the evidence of endoluminal stones, their size and their number. CT may also detect ectopic stones and allow the diagnosis of gallstone ileus before severe intestinal obstruction from stone impaction occurs.

Gallstone ileus usually requires urgent surgery to relieve intestinal obstruction. Although enterolithotomy alone remains the popular operative method in most reports, the one-stage procedure composed of enterolithotomy, cholecystectomy and repair of fistula is necessary, if indicated (9). Tan et al. (10) compared the two surgical strategies of enterolithotomy alone and enterolithotomy with cholecystectomy for the emergent treatment of gallstone ileus, and concluded that both procedures are safe with no mortality, but the better surgical option is enterolithotomy. Recently, Chou et al. (11) proposed endoscopic approach to remove gallstones, but their size constitute a technical difficulty in order to apply. Bowel resection is only indicated when there is intestinal perforation or ischemia (12). In the present case, no dilemma involving cholecystectomy was posed since the organ was priority removed. Furthermore, bowel resection was necessary due to the stenosis of the old anastomosis and the multiple adhesions.

In conclusion, gallstone obstructive ileus has to be considered in a differential diagnosis of mechanical ileus, even in the absence of gallbladder. Furthermore, even when not all of the Rigler's criteria are fulfilled then the biliary stone has to be considered as etiologic factor. Finally, when suspicion

for gallstone ileus appears then CT has to be the diagnostic modality to be employed.

REFERENCES

1. Lassandro F, Gagliardi N, Scuderi M, Pinto A, Gatta G, Mazzeo R. *Gallstone ileus analysis of radiological findings in 27 patients. Eur J Radiol* 2004; 50: 23-9.
2. Masannat Y, Masannat Y, Shatnawei A. *Gallstone Ileus: a review. Mt Sinai J Med* 2006; 73: 1132-4.
3. Gelbman A. *Clinical quiz. Gallstone ileus with cholecystocolonic fistula. Emerg Radiol* 2006; 12: 199-200.
4. Clavien PA, Richon J, Burgan S, Rohner A. *Gallstone ileus. Br J Surg* 1990; 77: 737-42.
5. Deitz DM, Standage BA, Pinson CW, McConnell DB, Krippaehne WW. *Improving the outcome in gallstone ileus. Am J Surg* 1986; 151: 572-6.
6. Piedad OH, Wels PB. *Spontaneous internal biliary fistula, obstructive and nonobstructive types: twenty-year review of 55 cases. Ann Surg* 1972; 175: 75-80.
7. Rigler LG, Borman CN, Noble JF. *Gallstone obstruction: pathogenesis and roentgen manifestations. JAMA* 1941; 117: 1753-9.
8. Lassandro F, Romano S, Ragozzino A, Rossi G, Valente T, Ferrara I, Romano L, Grassi R. *Role of helical CT in diagnosis of gallstone ileus and related conditions. AJR Am J Roentgenol* 2005; 185: 1159-65.
9. Zuegel N, Hehl A, Lindemann F, Witte J. *Advantages of one-stage repair in case of gallstone ileus. Hepatogastroenterology* 1997; 44: 59-62.
10. Tan YM, Wong WK, Ooi LL. *A comparison of two surgical strategies for the emergency treatment of gallstone ileus. Singapore Med J* 2004; 45: 69-72.
11. Chou JW, Hsu CH, Liao KF, Lai HC, Cheng KS, Peng CY, Yang MD, Chen YF. *Gallstone ileus: report of two cases and review of the literature. World J Gastroenterol* 2007; 13: 1295-8.
12. Syme RG. *Management of gallstone ileus. Can J Surg* 1989; 32: 61-4.