

Abortive Intestinal Infection With an *Escherichia coli-Shigella flexneri* Hybrid Strain

SAMUEL B. FORMAL, E. H. LABREC, T. H. KENT, AND S. FALKOW

Walter Reed Army Institute of Research, Washington, D.C.

Received for publication 18 December 1964

ABSTRACT

FORMAL, SAMUEL B., (Walter Reed Army Institute of Research, Washington, D.C.), E. H. LABREC, T. H. KENT, AND S. FALKOW. Abortive intestinal infection with an *Escherichia coli-Shigella flexneri* hybrid strain. *J. Bacteriol.* **89**:1374-1382. 1965.—The mechanism of the apparent loss of virulence of an *Escherichia coli-Shigella flexneri* hybrid strain was studied. The parent *Shigella* strain caused a fatal enteric infection when fed to starved guinea pigs, and signs of dysentery followed its oral administration to monkeys. The hybrid strain failed to produce any apparent symptoms when fed to either of these species. The parent strain was shown to invade the intestinal mucosa of starved guinea pigs. This caused a severe inflammatory reaction in the lamina propria, which progressed to ulceration of the intestinal epithelium and resulted in death of the animal. The hybrid strain also invaded the intestinal mucosa and produced an inflammatory reaction. In this case, the inflammatory reaction subsided, the intestine returned to normal within 4 days after challenge, and the animal survived. Both fluorescent-antibody techniques and in vivo growth studies have shown that the hybrid strain can not maintain itself in the intestinal mucosa. Preliminary studies have indicated that a similar situation also exists in the monkey. It is concluded that the virulence of dysentery bacilli rests not only in the capacity to reach the lamina propria, but also in the ability to multiply in this region.

LaBrec et al. (1964) showed that an essential step in achieving a fatal enteric infection in starved guinea pigs by *Shigella flexneri* is the penetration of the intestinal epithelial cell by the infecting organism. The pathogen then gains entrance to the underlying lamina propria, where it multiplies and results in acute enteritis with ulceration. In the starved guinea pig this infection causes death, and in the monkey it produces the classical signs of bacillary dysentery. Dysentery bacilli which are rendered incapable of penetrating the epithelial barrier by spontaneous mutation cause neither death nor intestinal lesions in the starved guinea pig and apparently are innocuous when fed to monkeys.

Starved guinea pigs also survive challenge with *S. flexneri* organisms which have acquired the *rha⁺-xyl⁺* region of the *Escherichia coli* K-12 genome by mating (Falkow et al., 1963). The purpose of this communication is to describe experiments demonstrating that these hybrids, which appear to be avirulent in the starved guinea pig model, have in fact retained their ability to penetrate the bowel epithelium but have lost their capacity to maintain themselves within the intestinal mucosa.

MATERIALS AND METHODS

Cultures. *S. flexneri* 2a strain 2457T has been used in our previous work (Formal et al., 1963; LaBrec et al., 1964). It causes a fatal enteric infection when fed to starved guinea pigs (Formal et al., 1958) and classical bacillary dysentery when orally administered to rhesus monkeys (LaBrec et al., 1964). The Hfr *E. coli* K-12 strain W1895 used in these experiments was described previously (Falkow et al., 1963). The genetic characteristics of these strains pertinent to this investigation are shown in Table 1.

Media. Meat extract-agar (MEA) was used for routine cultivation of strains. Brain Heart Infusion (BHI) broth (Difco) was used both to suspend the challenge organisms and for in vitro growth studies. Penassay broth (Difco) was employed in recombination experiments. Minimal agar employed for the selection and purification of genetic hybrids was prepared as described by Falkow, Rownd, and Baron (1962).

Mating procedures. Bacterial recombination experiments were carried out as described by Falkow et al. (1963).

In vitro growth studies. The growth of *S. flexneri* in vitro was assayed by turbidimetric means. The strains were grown overnight on MEA plates. The organisms were harvested in BHI broth, and

TABLE 1. Genetic characteristics of bacterial strains*

Organism	Auxotrophic characters				Utilization of					Indole production	Pili antigen	Mating polarity
	met	nic	asp	lac	ara	rha	xyl	mal	fuc			
<i>Shigella flexneri</i> 2a strain 2457T	+	-	-	-	-	-	-	-	-	-	-	F ⁻
<i>Escherichia coli</i> K-12 W1895	-	+	+	+	+	+	+	+	+	+	+	Hfr

* The following abbreviations are used: thr, threonine; leu, leucine; met, methionine; nic, nicotinic acid; asp, aspartate; his, histidine; lac, lactose; ara, arabinose; rha, rhamnose; xyl, xylose; mal, maltose; fuc, fucose; + = synthesis or utilization; - = not synthesized or utilized. F⁻, recipient; Hfr, high frequency of recombination donor.

dilutions were made to contain approximately 10⁷ organisms per milliliter. The broth cultures were incubated at 37 C with agitation. The turbidity was recorded spectrophotometrically at 650 m μ , and growth curves were constructed.

In vivo growth studies. The method used to estimate the *in vivo* growth of *S. flexneri* 2a strains in the small intestine of starved guinea pigs was described previously (Formal et al., 1963).

Oral infection of guinea pigs. Guinea pigs of the Hartley or Walter Reed strain weighing 300 to 400 g were used. They were deprived of food for 4 days and then fed 5 \times 10⁷ to 1 \times 10⁸ challenge organisms suspended in 10 ml of BHI broth by stomach tube. Immediately after challenge, 1 ml of tincture of opium was injected intraperitoneally. The animals were observed for 3 days after challenge. Virulent strains produce ulcerative lesions of the bowel and subsequent death in approximately 80% of the animals. Animals fed avirulent cells survive and do not exhibit any bowel lesions (Schneider and Formal, 1963; LaBrec et al., 1964).

Infection of HeLa cells. The details of this procedure were described previously (LaBrec et al., 1964). Strains of dysentery bacilli considered to be virulent invade and multiply within HeLa cell monolayers; strains thought to be avirulent do not.

Guinea pig keratoconjunctivitis test. The details of this procedure were described by Mackel, Langley, and Venice (1961). Strains considered to be virulent enter the corneal epithelial cells (Piéchaud, Szturm-Rubensten, and Piéchaud, 1958) and cause keratoconjunctivitis; strains thought to be avirulent do not.

Oral infection of monkeys. Rhesus monkeys (*Maccaca mulata*) weighing 2.3 to 3.6 kg were used. They were housed in individual cages, and their stools were examined daily for at least 1 week for evidence of bacterial pathogens. The challenge consisted of approximately 5 \times 10¹⁰ organisms suspended in 20 ml of BHI broth and was administered by stomach tube. The animals were then observed twice daily for 1 week for evidence of diarrhea.

Fluorescent-antibody and histological studies. Fluorescent-antibody studies on frozen tissue sections were carried out as previously described

(LaBrec et al., 1964; LaBrec and Formal, 1961). Tissues for histological study were fixed in neutral buffered formalin and processed by routine methods.

RESULTS

Matings between the *E. coli* K-12 donor strain W1895 and the recipient *S. flexneri* 2a strain 2457T were performed, and the mating mixture was plated on a medium selective for *Shigella* which had received the *E. coli* genes determining the fermentation of xylose. The resulting hybrid clones were isolated and analyzed for the inheritance of unselected genetic traits from the *Escherichia* parent. A single hybrid strain, X16, which had incorporated the *E. coli* markers *ara*⁺, *rha*⁺, *xyl*⁺, and *mal*⁺ was selected for further study.

The colonial appearance of this strain was granular, giving a suggestion of roughness. Saline suspensions of the organisms, however, did not agglutinate when heated to 100 C, and the organisms did not agglutinate in 0.2% acriflavine or in undiluted normal rabbit serum. The surface antigenic structure of the hybrid was similar to that of the parent *Shigella* strain as indicated by reciprocal agglutinin adsorption tests. Both the parent and the hybrid strain were equally toxic for mice when suspensions of acetone-killed and dried cells were injected intraperitoneally (LD₅₀ = 5 mg). In confirmation of a previous report from this laboratory (Falkow et al., 1963), this hybrid did not cause a fatal enteric infection when fed to starved guinea pigs (Table 2). The mechanism of this apparent loss of virulence was not investigated at that time.

The virulence of dysentery bacilli is reflected in several experimental systems other than in their ability to kill pretreated guinea pigs. The hybrid X16 strain was further characterized by its ability to produce keratoconjunctivitis and to invade and multiply within HeLa cells. Approximately 10⁸ cells of the parental or hybrid strains were dropped into the conjunctival sac of guinea

TABLE 2. Deaths observed in starved guinea pigs after the oral administration of parent and hybrid strains*

Strain	Deaths†
<i>Shigella flexneri</i> 2a strain 2457T.....	18/26
<i>Escherichia coli</i> K-12 strain W1895.....	0/11
Hybrid strain X16.....	1/28

* Animals were starved for 4 days; the challenge consisted of 5×10^7 to 1×10^8 bacteria; 1 ml of tincture of opium was injected intraperitoneally after challenge.

† Number dead per number challenged. Data pooled from three experiments.

pigs (three animals per strain). Within 72 hr, animals receiving both the parental *Shigella* strain and the hybrid strain exhibited a purulent keratoconjunctivitis (Fig. 1 and 2). The eyes of the animals which had received the *E. coli* donor strain remained normal. Similar results were found when the three strains were tested in the HeLa cell system. Within 7 hr after inoculation, both the X16 strain and the virulent parent were observed within HeLa cells (Fig. 3 and 4).

Although the hybrid strain did not cause a fatal enteric infection in starved guinea pigs, it was apparent that it had retained the ability to invade epithelial cells. We therefore re-examined hybrid X16 in the starved guinea pig model to determine whether it could cause an intestinal lesion. Groups of six starved animals, challenged by the oral route with either of the two parental strains or the hybrid strain, were killed at various times up to 7 days after challenge, and their intestinal tracts were studied. The intestinal tract of animals receiving the donor *E. coli* strain remained normal throughout. In animals fed the parental *S. flexneri* 2457T strain, acute inflammatory changes occurred in the ileum and cecum as early as 8 hr and became severe with ulceration by 24 to 48 hr (Fig. 5). By 72 hr postchallenge, 80% of the animals fed the parental dysentery strain had died. Animals fed the hybrid strain exhibited a less severe acute inflammatory change, which began to recede by 24 hr. By 72 hr, the inflammatory reaction had noticeably subsided, and by 4 days the intestinal mucosa was nearly normal (Fig. 6).

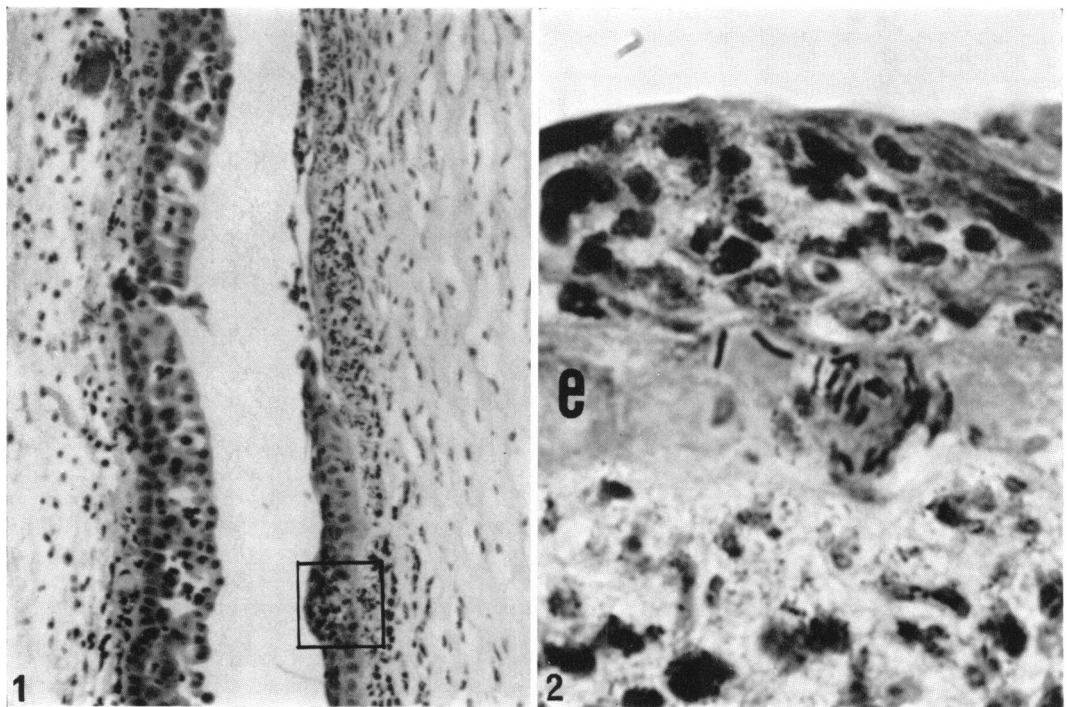


FIG. 1. Guinea pig cornea (right surface) and conjunctiva 24 hr after instillation of the hybrid strain of *Shigella flexneri* 2a. Corneal ulceration with subepithelial polymorphonuclear neutrophil infiltration is evident in the upper half of the right surface. Hematoxylin and eosin stain. $\times 160$.

FIG. 2. Inset of Fig. 1. Bacilli can be seen within the epithelial cells (e). Acute inflammatory cells are present beneath the epithelium and on the epithelial surface. Giemsa stain. $\times 1,280$.

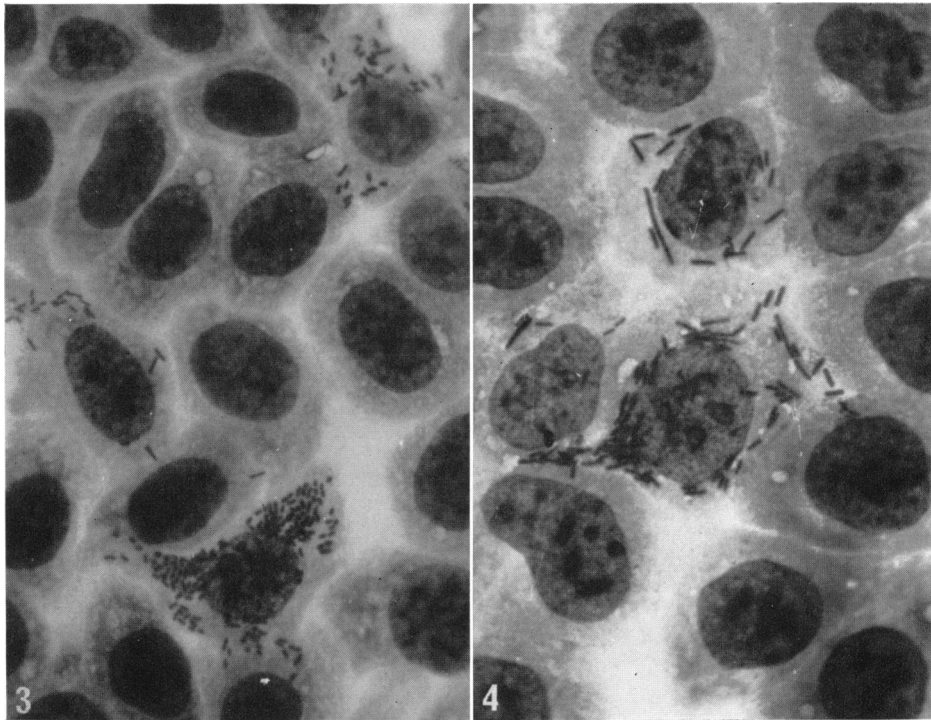


FIG. 3. *HeLa* cell monolayer 7 hr after inoculation with the parent strain of *Shigella flexneri* 2a. Several cells containing organisms can be seen. Giemsa stain. Original magnification, $\times 420$.

FIG. 4. *HeLa* cell monolayer 7 hr after inoculation with the hybrid strain of *Shigella flexneri* 2a. Intracellular localization of the bacilli is seen. The hybrid strain has a tendency to grow in long forms in *HeLa* cells and in the medium. Giemsa stain. Original magnification, $\times 540$.

A possible explanation of this "abortive infection" was revealed in fluorescent-antibody studies of frozen sections of intestine from these animals. At 8 to 12 hr after oral administration of the hybrid strain, moderate to large numbers of specifically fluorescing bacilli were seen in the lumen of the intestine. At these times, organisms were observed in the epithelial cells and in the lamina propria of the mucosa (Fig. 7). At 24 hr, however, few morphologically intact bacilli were seen in the lamina propria. Instead, the majority of the specifically fluorescing material appeared to be bacterial debris (Fig. 8). Most of this material was found within tissue histiocytes and polymorphonuclear leukocytes, but some extracellular material was noted. At 48 hr, four of the six animals retained some fluorescing material in phagocytes of the mucosa, but the amount was considerably reduced from that seen at 24 hr. In only one of the animals were any morphologically intact bacilli seen. At 72 hr, no *Shigella* or bacterial debris could be found in the tissue or in the intestinal lumen. In contrast, large numbers of intact, specifically fluorescing *Shigella* were

observed in the intestinal mucosa of animals 24 hr postchallenge with the parental 2457T strain. The *E. coli* donor strain was seen in moderate numbers in the intestinal lumen at 12 hr, but very few were present at 24 hr.

The inability of the hybrid strain to maintain itself *in vivo* was further confirmed by bacterial counts on the small intestine and its contents—a major region of bacterial growth in this experimental model (Formal et al., 1963). Although the hybrid strain maintained itself well for 8 hr postchallenge, by 24 hr the number of viable hybrid cells was markedly reduced (Fig. 9). This was not due to a difference in the rate of growth, because both strains multiplied equally well *in vitro* (Fig. 10).

The parent *Shigella* strain and the hybrid were fed to rhesus monkeys in doses of approximately 5×10^{10} cells to compare the effect of these strains in this animal. The signs observed in animals fed the parent *Shigella* strain were not different from those previously described (LaBrec et al., 1964). Of 45 animals which were fed the parent *S. flexneri* strain, 11 developed classical bacillary

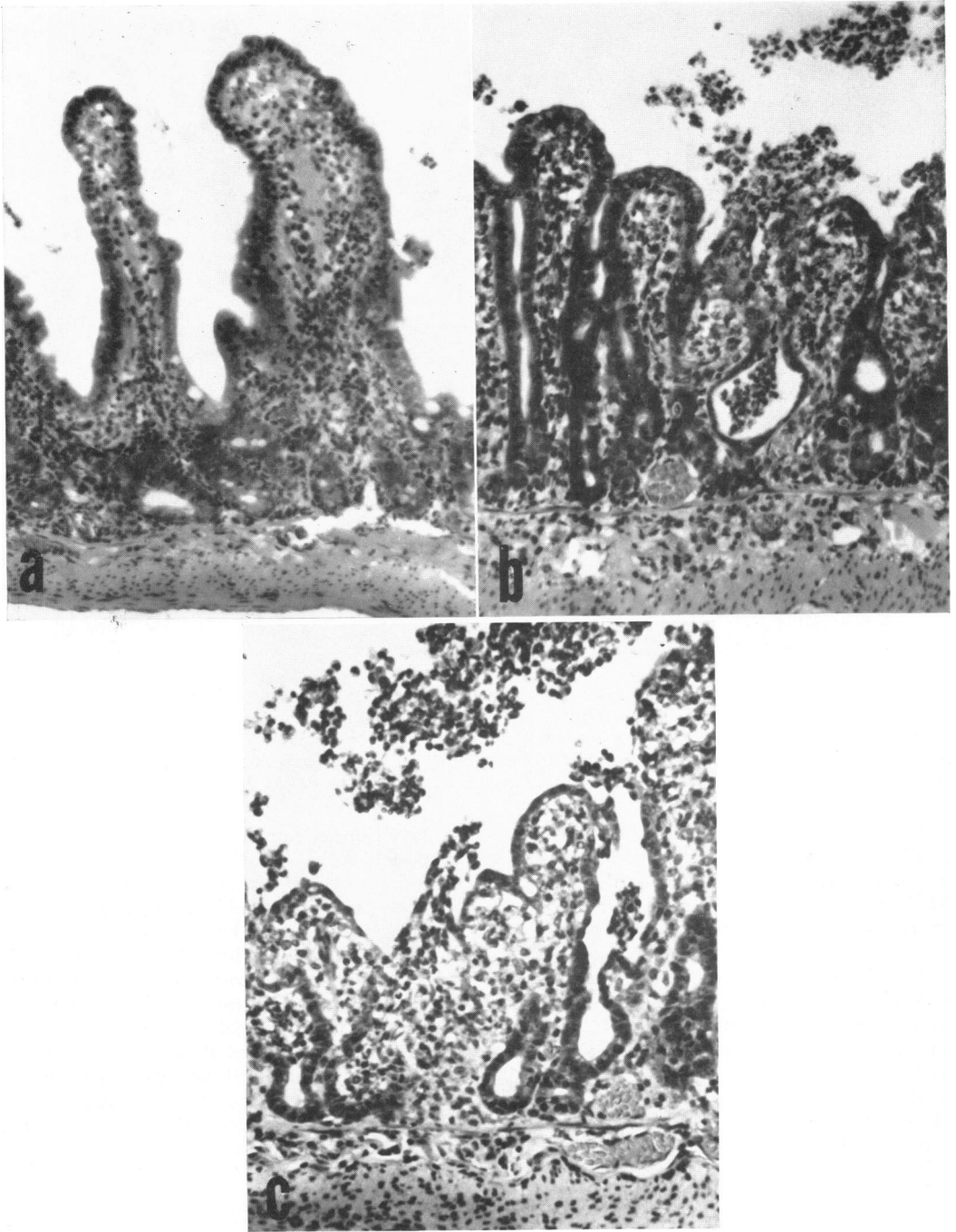


FIG. 5. Guinea pig ileum from animals killed at various intervals after oral challenge with the parent *Shigella flexneri* 2a strain. (a) At 8 hr. Note the acute inflammatory reaction with swollen villi and polymorphonuclear neutrophil infiltrate. (b) At 24 hr. The inflammatory reaction has progressed with purulent exudate in the crypts and lumen, focal ulceration, altered epithelial cells, and blunting and fusion of villi. (c) At 48 hr. The inflammatory reaction is more severe with attenuated surface epithelium, areas of ulceration, and purulent exudate in the lumen. Hematoxylin and eosin stain. Ca. $\times 200$.

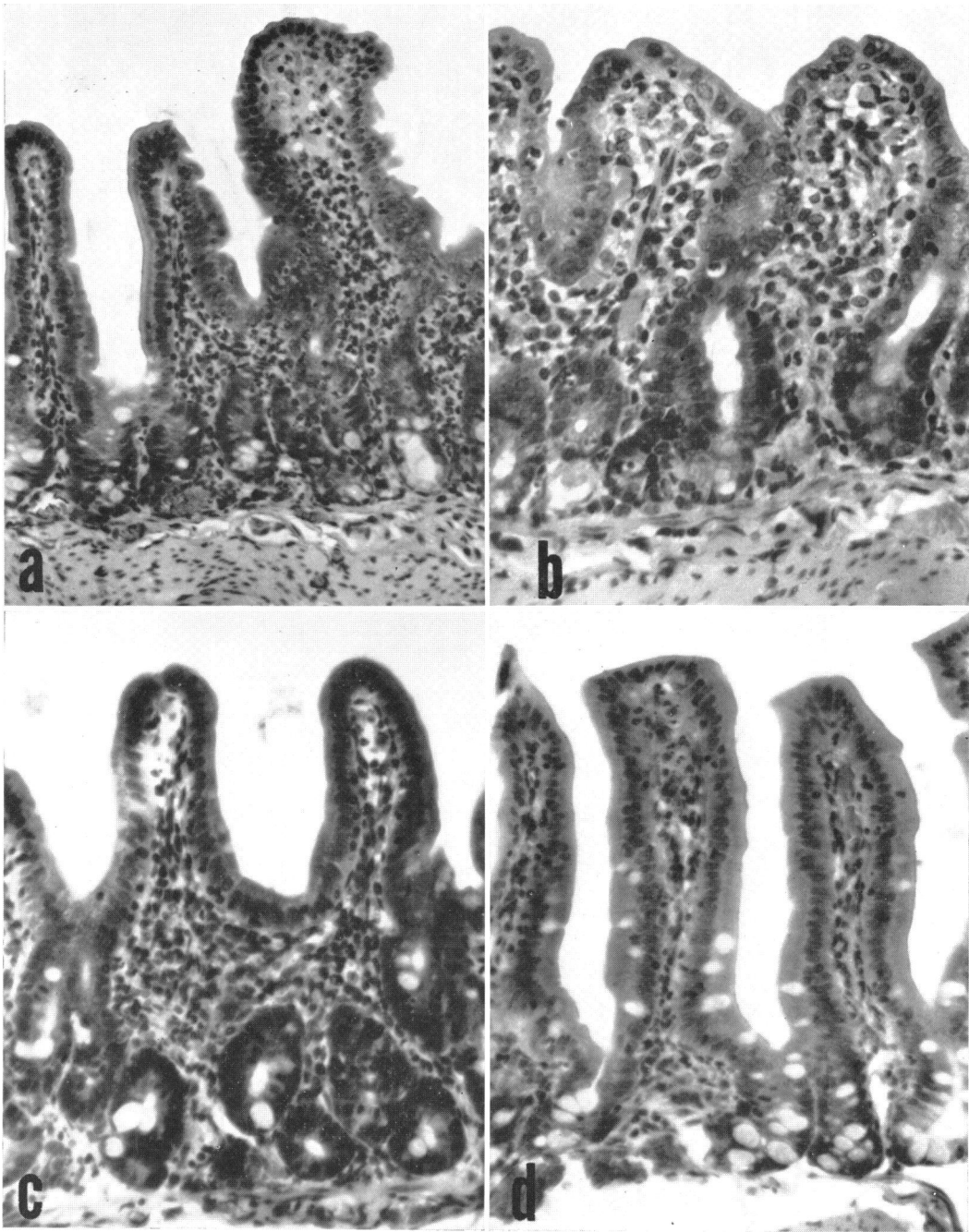


FIG. 6. Guinea pig ileum from animals killed at various intervals after oral challenge with the hybrid *Shigella flexneri* 2a strain. (a) At 8 hr. Acute inflammatory reaction similar to 5a. (b) At 24 hr. The acute neutrophilic reaction has subsided and the lamina propria contains predominantly chronic inflammatory cells. Epithelial cell damage is at maximum with short villi and elongated crypts. (c) At 48 hr. The villi have partially regenerated and the inflammatory reaction has decreased. (d) At 72 hr. The mucosa is nearly normal. Compare sequence with Fig. 5. Hematoxylin and eosin stain. Ca. $\times 200$.

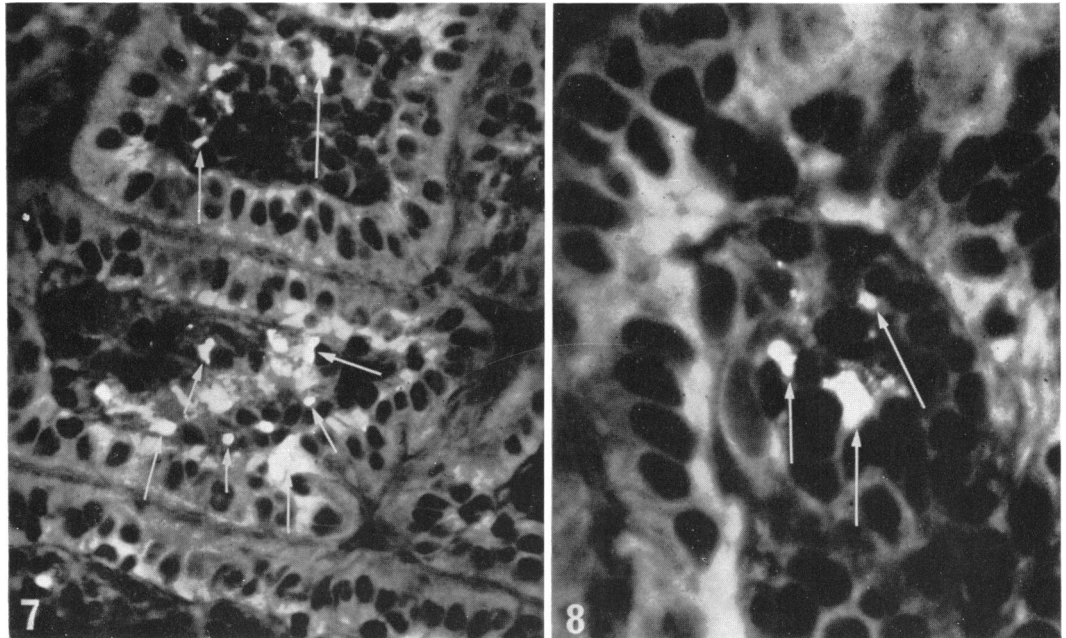


FIG. 7. Frozen section of ileum from a guinea pig killed 12 hr after oral challenge. The section was treated with fluorescein-labeled rabbit anti-*Shigella flexneri* 2a globulin. Fluorescing organisms of the hybrid *Shigella* strain (arrows) can be seen in the lamina propria and villus epithelium. Original magnification, $\times 240$.

FIG. 8. Frozen section of ileum from a guinea pig sacrificed 24 hr after oral challenge. The section was treated with fluorescein-labeled rabbit anti-*Shigella flexneri* 2a globulin. Antigenic material from phagocytosed and digested *S. flexneri* 2a hybrid organisms can be seen as amorphous fluorescent masses (arrows) within phagocytic cells in the lamina propria of a single villus. Original magnification, $\times 540$.

dysentery with diarrheal stools containing blood and mucus; 9 others exhibited severe diarrhea; and the remaining 25 appeared normal. Of 43 animals fed the hybrid, 4 had a single diarrheal stool without blood or mucus. Six monkeys were killed 24 hr after challenge with the hybrid X16 strain. Two of these exhibited a mild acute colitis. Fluorescent-antibody studies revealed specifically fluorescing intact bacilli within the epithelium and lamina propria of the cecum and colon in three of these animals. Fluorescing bacterial debris was noted in phagocytic cells in the lamina propria. Large amounts of bacterial antigen and whole bacilli were also seen in the luminal contents. In all animals, the ileum appeared normal.

DISCUSSION

In a previous study (Falkow et al., 1963), we reported that *E. coli-Shigella* hybrids rarely caused a fatal enteric infection in starved guinea pigs, provided that the virulent recipient *Shigella* strain incorporated the *rha*⁺-*xyl*⁺ region of the *E. coli* chromosome into its genome. The mechanism of this apparent loss of virulence was not studied at that time. Subsequent work (LaBrec et al., 1964) demonstrated that penetration of

the intestinal epithelial cell by the bacterium is an essential step in the pathogenesis of bacillary dysentery. Dysentery bacilli which were incapable of penetrating the intestinal epithelial barrier acted like nonpathogenic *E. coli* when fed to starved guinea pigs or to monkeys. For a time, we assumed that the *rha*⁺-*xyl*⁺ *Shigella* hybrids fell into this category; i.e., they had lost their capacity to kill starved guinea pigs due to a loss in ability to penetrate into the intestinal mucosa. The present study shows that this assumption was not correct and suggests that not only invasion but the ability to multiply in tissue is an important factor in determining the virulence of dysentery bacilli.

Our initial experiments indicated that the apparent avirulence of the hybrid strain was not due to an inability on its part to penetrate epithelial cells. Indeed, the hybrid appeared to invade the epithelial cells of the cornea and HeLa cells in culture as well as did the highly virulent parent strain. In the intestinal tract, both the parental and the hybrid strains had the ability to reach the lamina propria and cause an acute inflammatory reaction. It is at this point that the difference between the two strains became dis-

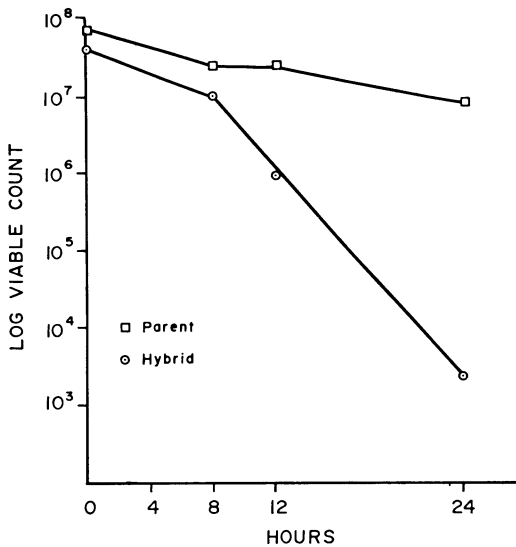


FIG. 9. *In vivo* growth of the parent and hybrid strains of *Shigella flexneri* 2a in the small intestine of guinea pigs starved 4 days and then fed approximately 5×10^7 viable cells of either the parent or hybrid strain. The points on the curves represent the geometric mean of the number of viable organisms recovered from the entire small intestine of four animals.

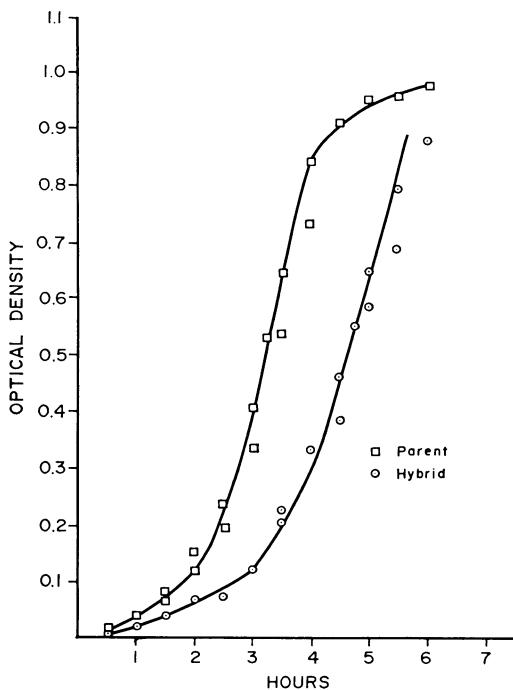


FIG. 10. *In vitro* rate of growth of the parent and hybrid strains of *Shigella flexneri* 2a in Brain Heart Infusion broth.

cernible. By 48 hr after infection of starved guinea pigs with the hybrid, there were few, if any, viable organisms of the challenge strain in the bowel; the intestinal mucosa returned to normal in approximately 4 days, and the animals survived. On the other hand, in most of the animals infected with the parental *Shigella* strain, the challenge organism persisted in the lamina propria, the inflammatory reaction was progressive with ulceration, and the animals died.

In monkeys, our evidence that the hybrid *Shigella* penetrates the intestinal epithelium but does not proliferate is more tenuous because of the small number of animals studied and the variable response of the monkey to oral challenge with *S. flexneri*. The lack of the classic signs of dysentery in 43 monkeys challenged with the hybrid strain, together with the evidence of mucosal penetration with only mild colitis in 2 of 6 monkeys, supports the findings obtained in the guinea pig.

The present work further emphasizes that results of indicator tests for the virulence of *S. flexneri* strains must be interpreted with caution. The ability to produce disease in species which are natural hosts must obviously be the final criterion of pathogenicity. Previously, we demonstrated that a spontaneous *S. flexneri* mutant of high mouse virulence was incapable of producing intestinal lesions in the starved guinea pig or symptoms of dysentery in monkeys, because it was incapable of penetrating the intestinal epithelial cell and reaching the lamina propria when fed to these animal species (LaBrec et al., 1961). The capacity to cause keratoconjunctivitis or to penetrate HeLa cells seems to correlate well with the ability to enter intestinal epithelial cells. However, even if a particular strain is positive in these two indicator models, it need not necessarily possess all the attributes necessary for pathogenicity, for these tests do not reflect the organism's ability to multiply in tissue. At the moment, the capacity to cause intestinal lesions and death in the starved guinea pig model appears to be a reliable indicator for this property. Hybrid and mutant strains of *S. flexneri* have proved to be a valuable tool for investigating the various steps which occur in intestinal infections. Their use in other bacterial species will no doubt result in adding much to our knowledge of enteric diseases.

LITERATURE CITED

- FALKOW, S., R. ROWND, AND L. S. BARON. 1962. Genetic homology between *Escherichia coli* K-12 and *Salmonella*. *J. Bacteriol.* **84**:1303-1312.
- FALKOW, S., H. SCHNEIDER, L. S. BARON, AND S. B. FORMAL. 1963. Virulence of *Escherichia-*

- Shigella* genetic hybrids for the guinea pig. J. Bacteriol. **86**:1251-1258.
- FORMAL, S. B., G. D. ABRAMS, H. SCHNEIDER, AND H. SPRINZ. 1963. Experimental *Shigella* infections. VI. Role of the small intestine in an experimental infection in guinea pigs. J. Bacteriol. **85**:119-125.
- FORMAL, S. B., G. J. DAMMIN, E. H. LABREC, AND H. SCHNEIDER. 1958. Experimental *Shigella* infections: characteristics of a fatal infection produced in guinea pigs. J. Bacteriol. **75**:604-610.
- LABREC, E. H., AND S. B. FORMAL. 1961. Experimental *Shigella* infections. IV. Fluorescent antibody studies of an infection in guinea pigs. J. Immunol. **87**:562-572.
- LABREC, E. H., H. SCHNEIDER, T. J. MAGNANI, AND S. B. FORMAL. 1964. Epithelial cell penetration as an essential step in the pathogenesis of bacillary dysentery. J. Bacteriol. **88**:1503-1518.
- MACKEL, D. C., L. F. LANGLEY, AND L. A. VENICE. 1961. The use of the guinea pig conjunctivae as an experimental model for the study of virulence of *Shigella* organisms. Am. J. Hyg. **73**:219-223.
- PIÉCHAUD, M., S. SZTUM-RUBENSTEN, AND D. PIÉCHAUD. 1958. Evolution histologique de la kérato-conjonctivite à bacillus dysentériques du cobaye. Ann. Inst. Pasteur **94**:298-309.
- SCHNEIDER, H., AND S. B. FORMAL. 1963. Spontaneous loss of guinea pig virulence in a strain of *Shigella flexneri* 2a. Bacteriol. Proc., p. 66.