



Published in final edited form as:

Am J Med Genet A. 2009 January ; 149A(1): 6–28. doi:10.1002/ajmg.a.32612.

Elements of Morphology: Standard Terminology for the Head and Face

Judith E. Allanson^{1,*}, Christopher Cunniff², H. Eugene Hoyme³, Julie McGaughran⁴, Max Muenke⁵, and Giovanni Neri⁶

¹Department of Genetics, Children's Hospital of Eastern Ontario, Ottawa, Canada ²Section of Medical and Molecular Genetics, Department of Pediatrics, University of Arizona, Tucson, Arizona ³Department of Pediatrics, University of South Dakota, Sioux Falls, South Dakota ⁴Royal Children's Hospital, Genetic Health Queensland, Brisbane, Australia ⁵National Human Genome Research Institute, Medical Genetics Branch, National Institutes of Health, Bethesda, Maryland ⁶Istituto di Genetica Medica, Universita Cattolica, Roma, Italy

Abstract

An international group of clinicians working in the field of dysmorphology has initiated the standardization of terms used to describe human morphology. The goals are to standardize these terms and reach consensus regarding their definitions. In this way, we will increase the utility of descriptions of the human phenotype and facilitate reliable comparisons of findings among patients. Discussions with other workers in dysmorphology and related fields, such as developmental biology and molecular genetics, will become more precise. Here we introduce the anatomy of the craniofacies and define and illustrate the terms that describe the major characteristics of the cranium and face.

Keywords

nomenclature; definitions; anatomy; anthropometry; head; cranium; face; neck; chin; maxilla; mandible

INTRODUCTION

General

This paper is part of a series of six papers defining the morphology of regions of the human body [Biesecker et al., 2008; Carey et al., 2008; Hall et al., 2008; Hennekam et al., 2008; Hunter et al., 2008]. The series is accompanied by an introductory article describing general aspects of this study [Allanson et al., 2008]. The reader is encouraged to consult the introduction when using the definitions. The definitions are listed alphabetically based on the physical feature, not the modifier. When a feature is indicated in the text in ***Bold-italics***, a definition is available either in this paper or one of the accompanying papers.

The appearance of facial morphology varies considerably with facial expression and movement, and depending on the position of the observer and observed person. When assessing a feature, the head of the observed person should be held in the Frankfurt horizontal, with the facial and neck muscles relaxed, eyes open, lips making gentle contact, and facial

*Correspondence to: Dr. Judith E. Allanson, Department of Genetics, Children's Hospital of Eastern Ontario, 401 Smyth Road, Ottawa, ON, Canada K1H 8L1. allanson@cheo.on.ca.

expression neutral. The face of the observer should be at the same height as the face of the observed person.

Anatomy of the Face and Cranium

Head shape and upper face shape are closely related to the shape of the bony skull. Figures 1 and 2 show the bony anatomy of the face. Many anthropological landmarks, bony and soft tissue, are illustrated in Figures 3 and 4.

The Anatomy of the Various Structures is Described in More Detail Below.

Cranium: The upper part of the skull consists of paired frontal and parietal bones and a single posterior occipital bone (Figs. 1 and 2). In early life these bones are separated by five major sutures (Figs. 1 and 2). Three, the coronal, lambdoidal and squamosal, are paired, and two, the sagittal and metopic, are single. Cranial growth normally occurs perpendicular to each of these major sutures.

Forehead: The part of the face above the eyebrows, below the hairline and between the temples. The paired frontalis muscles join in the midline and adhere to the superficial fascia over the frontal bone. These muscles effect forehead wrinkling or frowning. They have no bony attachments, but inferiorly the fibres blend with the muscles encircling the eyelids. From these attachments the fibers are directed upward, and join the galea aponeurotica below the coronal suture. The galea aponeurotica is a layer of dense fibrous tissue which covers the upper part of the cranium and attaches posteriorly to the occipital bone. It is closely connected to the integument by the firm, dense, fibro-fatty layer which forms the superficial fascia of the scalp. It cannot be wrinkled or furrowed because it does not contain muscle fibres. The anterior hairline is typically situated at the junction of frontalis muscle and galea aponeurotica.

Glabella: The most prominent point on the frontal bone above the root of the nose.

Supra-orbital ridge: The supraorbital portion of the frontal bones.

Midface: This is a region and not an anatomical term. It extends, superiorly, from the inferior orbital margin to, inferiorly, the level of nasal base. It is formed by the maxilla (upper jaw) and zygoma. Traditionally, the nose and premaxilla are not included in the midface.

Maxilla: These paired bones form, by their union, the upper jaw and contain the upper dentition. Each assists in forming the boundaries of three cavities—the palate, floor and lateral wall of the nose (frontal or malar process), and floor of the orbit. Each bone consists of a body and four processes—zygomatic, malar (frontal), alveolar and palatine.

Malar process (syn. frontal process): The most medial and superior part of the maxilla. It forms the medial border of the inferior bony orbit, and is contiguous with the lateral boundary of the nasal bridge.

Zygoma: The part of the temporal bone of the skull that forms the prominence of the cheek. It is also known as the zygomatic bone or arch, the malar bone (creating confusion with the malar process of the maxilla), the cheek bone and the yoke bone. The zygomatic arch is composed of the malar process of the maxilla, medially, the zygoma, centrally, and the temporal bone, posterolaterally. It forms part of the part of the lateral wall and floor of the orbit.

Premaxilla: The part of the maxilla in which the 4 upper incisors develop, which forms the primary palate, and underlies the philtrum and upper lip.

Lower face: The part of the face between the mouth and the inferior point of the chin

Cheek: The soft tissues between the zygoma and mandible

Mandible: The lower jaw in which the lower teeth reside. It consists of a curved, horizontal portion, the body, and two perpendicular portions, the rami, which unite with the ends of the body nearly at right angles.

Chin: The inferior portion of the face lying inferior to the lower lip and including the central prominence of the lower jaw

Neck: The part of the body connecting the head with the shoulders

DEFINITIONS

CRANIUM

Acrocephaly: See *Turricephaly*

Brachycephaly—Definition: Cephalic index greater than 81% (Fig. 5). *objective* OR

Apparently shortened anteroposterior dimension (length) of the head compared to width. *subjective*

Comments: Cephalic index is the ratio of head width expressed as a percentage of head length. The normal range is 76–80.9%. Head length is measured between the glabella (the most prominent point on the frontal bone above the root of the nose) and the most prominent part of the occiput in the midline, using spreading calipers. Head width is measured between the most lateral points of the parietal bones on each side of the head, using spreading calipers. Cephalic index standards are derived from Caucasians and have limited relevance for other races and ethnicities. Current norms also have limited validity because of changes in infant sleeping position and consequent changes in head shape. New data should be developed. Brachycephaly is distinct from *Flat occiput*, but both can be present in the same individual and should be coded separately.

Dolichocephaly—Definition: Cephalic index less than 76% (Fig. 6). *objective* OR

Apparently increased antero-posterior length of the head compared to width. *subjective*

Comments: Cephalic index is the ratio of head width expressed as a percentage of head length. The normal range is 76–80.9%. Head length is measured between the glabella (the most prominent point on the frontal bone above the root of the nose) and the most prominent part of the occiput in the midline, using spreading calipers. Head width is measured between the most lateral points of the parietal bones on each side of the head, using spreading calipers. Cephalic index standards are derived from Caucasians and have limited relevance for other races and ethnicities. Current norms have limited validity because of changes in infant sleeping position and consequent changes in head shape. New data should be developed. Dolichocephaly is distinct from *Prominent occiput*, but both can be present in the same individual and should be coded separately. Scaphocephaly is a subtype of dolichocephaly where the anterior and posterior aspects of the cranial vault are pointed (boat-shaped).

Head circumference, enlarged: See *Macrocephaly*

Head circumference, reduced: See *Microcephaly*

Kleeblattschädel: See *Skull, cloverleaf*

Macrocephaly—Definition: Occipitofrontal (head) circumference greater than 97th centile compared to appropriate, age matched, sex-matched normal standards (Fig. 7). *objective* OR

Apparently increased size of the cranium. *subjective*

Comments: Head circumference is measured from just above the glabella (the most prominent point on the frontal bone above the root of the nose) to the most posterior prominent point of the occipital bone using a tape measure. Some standard charts are organized by centiles [Hall et al., 2007], others by standard deviations [Farkas, 1981]. It is important to add an indication of how far above the normal standard the head circumference is if an accurate assessment of this can be made. Macrocephaly is an absolute term. The term relative macrocephaly can be used when the head size centile exceeds the centile for height, for example, head size at the 75th centile with height at the 5th centile for age and sex.

Synonyms: Head circumference, enlarged; OFC, large.

Replaces: Macrocranium

Macrocranium: See *Macrocephaly*

Microcephaly—Definition: Occipitofrontal (head) circumference (OFC) less than 3rd centile compared to appropriate, age matched, normal standards (Fig. 8). *objective* OR

Apparently decreased size of the cranium. *subjective*

Comments: Head circumference is measured from just above the glabella (the most prominent point on the frontal bone above the root of the nose) to the most posterior prominent point of the occipital bone using a tape measure. Some standard charts are organized by centiles [Hall et al., 2007], others by standard deviations [Farkas, 1981]. It is important to add an indication of how far below the normal standard the head circumference is if an accurate assessment of this can be made. Microcephaly is an absolute term. The term relative microcephaly can be used when the head size centile is less than the centile for height, for example, head size at the 3rd centile with height at the 75% for age and sex.

Synonyms: Head circumference, reduced small; OFC, small.

Replaces: Microcranium

Microcranium: See *Microcephaly*

Occiput, Flat—Definition: Reduced convexity of the occiput (posterior part of skull) (Fig. 9). *subjective*

Comments: Reduced convexity of the occiput gives an appearance of flattening. There are no objective measures for convexity of the occiput, and evaluation depends heavily on the experience of the observer. This finding may or may not be accompanied by *Brachycephaly* (which should be coded separately), and may be observed more frequently when an infant is placed to sleep on his/her back.

Occiput, Prominent—Definition: Increased convexity of the occiput (posterior part of the skull) (Fig. 10). *subjective*

Comments: Increased convexity of the occiput gives an appearance of prominence. There are no objective measures for convexity of the occiput, and evaluation depends heavily on the

experience of the observer. This finding may or may not be accompanied by *Dolichocephaly*, but this should be coded separately.

OFC, enlarged: See *Macrocephaly*

OFC, reduced: See *Microcephaly*

Oxycephaly: See *Turriccephaly*

Plagiocephaly—Definition: Asymmetric head shape, which is usually a combination of unilateral occipital flattening with ipsilateral frontal prominence, leading to rhomboid cranial shape (Fig. 11). *subjective*

Comments: Plagiocephaly may affect the posterior skull alone.

Scaphocephaly: See *Dolichocephaly*

Skull, Cloverleaf—Definition: Trilobar skull configuration when viewed from the front or behind (Fig. 12). *subjective*

Synonym: Kleeblattschädel

Trigonocephaly—Definition: Wedge-shaped, or triangular head, with the apex of the triangle at the midline of the forehead and the base of the triangle at the occiput (Fig. 13). *subjective*

Comments: This shape should be assessed from above, with the examiner looking down on the head of the patient.

Turriccephaly—Definition: Tall head relative to width and length (Fig. 14). *subjective*

Comments: This feature may have previously been considered to overlap with or include a tall forehead. *Turriccephaly* is present when the head appears tall (*subjective*) and head length and width are reduced compared to normal age-related standards (*objective*). Head length is measured between the glabella (the most prominent point on the frontal bone above the root of the nose) and the most prominent part of the occiput in the midline, using spreading calipers. Head width is measured between the most lateral points of the parietal bones on each side of the head, using spreading calipers. The term *acrocephaly* (or *oxycephaly*) is used when there is *turriccephaly* and the top of the skull assumes a cone shape.

SCALP HAIR

Cowlick: See *Hair, frontal upsweep*

Crown, double: See *Hair whorl, abnormal position*

Frontal Balding—Definition: Absence of hair in the anterior midline and/or parietal areas (Fig. 15). *subjective*

Hair, Frontal Upsweep—Definition: Upward and/or sideward growth of anterior hair (Fig. 16). *subjective*

Replaces: Cowlick, which may be considered pejorative.

Hair Whorl, Abnormal Number—Definition: More than two clockwise hair whorls.
objective

Comments: Most individuals have one clockwise hair whorl at a single point on the scalp lateral to the midline but close to the vertex of the skull. Five percent of the population has two whorls (Fig. 17). A double hair whorl is sometimes referred to as a double crown. In 10%, whorl direction is counter-clockwise.

Hair Whorl, Abnormal Position—Definition: Hair growth from a single point on the scalp in any location other than lateral to the midline and close to the vertex of the skull (Fig. 18).
objective

Comments: Placement of hair whorl should be described as parietal, vertex, eccentric, etc. In addition, the number of hair whorls should be noted. Five percent of the population has two whorls.

Hairline, High Anterior—Definition: Distance between the hairline (trichion) and the glabella (the most prominent point on the frontal bone above the root of the nose), in the midline, more than two SD above the mean (Fig. 19a,b). *objective* OR

Apparently increased distance between the hairline and the glabella. *subjective*

Comments: This measurement is carried out with sliding calipers [Farkas, 1981].

This feature gives the appearance of a tall forehead, and may or may not include reduction of hair in the temporal areas. This can be distinguished from male pattern baldness as the hairline is the superior boundary of the muscular forehead, which can be actively wrinkled, in contrast to the scalp where no wrinkling can occur. In addition, texture of the skin of the scalp differs from the texture of the skin over the forehead.

Synonym: Forehead, tall

Hairline, Low Anterior—Definition: Distance between the hairline (trichion) and the glabella (the most prominent point on the frontal bone above the root of the nose), in the midline, more than two SD below the mean (Fig. 20a,b). *objective* OR

Apparently decreased distance between the hairline and the glabella. *subjective*

Comments: This measurement is carried out with sliding calipers [Farkas, 1981].

This feature gives the appearance of a short forehead. It is distinct from hirsutism of the forehead. In the latter, orientation of hair growth is lateral and texture and density of hair differs from scalp hair.

Synonym: Forehead, short

Hairline, Low Posterior—Definition: Hair on the neck extends more inferiorly than usual (Fig. 21). *subjective*

Comments: This feature is often seen in later childhood, as the neck lengthens, in an individual who was born with redundant nuchal skin, which should be assessed and coded separately.

Scalp Hair, Sparse—Definition: Decreased number of hairs per unit area (Fig. 22).
subjective

Comments: Hypotrichosis should not be used as a synonym as, formally, it means underdevelopment of the hair. No normal values for number of hairs per unit area exist.

Replaces: Scalp hair, thinning; Scalp hair, thin

Scalp hair, thin: See *Scalp hair, sparse*

Scalp hair, thinning: See *Scalp hair, sparse*

Widow's Peak—Definition: Frontal hairline with bilateral arcs to a low point in the midline of the forehead (Fig. 23). *subjective*

Comments: The hair may need to be pulled back to recognize this feature. Historically, English widows in the 18th century wore a black hat, triangular in shape, with a point facing forward in the midline.

FACE

Brows, prominent: See *Supraorbital ridges, prominent*

Brows, underdeveloped: See *Supraorbital ridges, underdeveloped*

Face, Broad—Definition: Bizygomatic (upper face) and bigonial (lower face) width greater than 2 SD above the mean (Fig. 24). *objective* OR

An apparent increase in the width of the face. *subjective*

Comments: Objective measurement of upper facial width is made with spreading calipers. The tips of the calipers are passed over the zygomatic arches until maximum width is determined. Objective measurement of the lower face is made with spreading calipers, with the tips firmly pressed against the inferomedial surface of the angle of the mandible [Farkas, 1981]. Broad face is distinct from *Round face*.

Face, Coarse—Definition: Absence of fine and sharp appearance of brows, nose, lips, mouth and chin, usually because of rounded and heavy features or thickened skin with or without thickening of subcutaneous and bony tissues (Fig. 25). *subjective*

Comments: Note that this is a bundled term, which conveys an impression or gestalt. It is nonetheless a useful term. Note that the word coarse may be considered pejorative by some.

Synonyms: Lineaments, coarse; Features, coarse.

Face, elongated: See *Face, long*

Face, Expressionless—This term, which is synonymous with dull expression or hypomimic face, is not defined here as it describes a functional not a structural feature (reduced facial movement leads to reduced crease formation).

Face, Flat—Definition: Absence of concavity or convexity of the face when viewed in profile (Fig. 26). *subjective*

Comments: A useful guide is to imagine that a line connecting the glabella to the anterior most part of the mandible touches the top of the philtrum where it meets the base of the columella. The glabella is the most prominent point on the frontal bone above the root of the nose. If the

superior philtrum is anterior to this line the face is convex, if the superior philtrum is posterior to this line the face is concave.

Face, Hypotonic—This term is to be deleted as it is a functional, not anatomic, descriptor. Also, it is not a unitary objective finding and instead represents a conclusion based on a number of features that are defined elsewhere. These include reduced nasolabial folds, laxity and drooping of lateral supraorbital skin and ptosis, mouth held open and reduced facial expression.

Face, Long—Definition: Facial height (length) is more than 2 SD above the mean (Fig. 27). *objective* OR

An apparent increase in the height (length) of the face. *subjective*

Comments: Objective measurement of face height is made with sliding calipers from the nasion, just above the depth of the nasal root, to the gnathion, the inferior border of the mandible, both in the midline [Farkas, 1981]. Long face is distinct from **Narrow face**.

Synonym: Face, elongated

Face, Narrow—Definition: Bizygomatic (upper face) and bigonial (lower face) width are more than 2 SD below the mean (Fig. 28). *objective* OR

An apparent reduction in the width of the upper and lower face. *subjective*

Comments: Objective measurement of upper facial width is made with spreading calipers. The tips of the calipers are passed over the zygomatic arches until maximum width is determined. Objective measurement of the lower face is made with spreading calipers, with the tips firmly pressed against the inferomedial surface of the angle of the mandible [Farkas, 1981]. Narrow face is distinct from **Long face**.

Face, Prematurely Aged—This term is to be deleted as it represents a conclusion based on a number of features, such as thin skin, more prominent subcutaneous venous patterning, lack of subcutaneous fat, excessive wrinkles, and pigmentary changes, that are defined elsewhere.

Face, Round—Definition: Facial appearance is more circular than usual, as viewed from the front (Fig. 29). *subjective*

Comment: While a **Broad face** may have rounded cheeks, a Round face appears to be as long as it is broad.

Face, Short—Definition: Facial height (length) is more than 2 SD below the mean (Fig. 30). *objective* OR

An apparent decrease in the height (length) of the face. *subjective*

Comments: Objective measurement of face height is made with sliding calipers from the nasion, just above the depth of the nasal root to the gnathion, the inferior border of the mandible, both in the midline [Farkas, 1981]. Short face is distinct from **Wide face**.

Face, Small—This term is to be deleted as it represents a combination of two terms: **Narrow face** and **Short face**. Both are defined elsewhere.

Face, Square—Definition: Facial contours, as viewed from the front, show a broad upper face/cranium and lower face/mandible, creating a square appearance (Fig. 31). *subjective*

Comments: Square face shape is usually related to increased lower facial width (a bigonial distance more than 2 SD above the mean). In **Broad jaw** the lower face is wider than the upper face.

Face, Triangular—Definition: Facial contour, as viewed from the front, triangular in shape, with breadth at the temples and tapering to a narrow chin (Fig. 32). *subjective*

Comment: This feature is distinct from **Narrow jaw** where width of the midface is unchanged.

Features, coarse: See **Face, coarse**

Lineaments, coarse: See **Face, coarse**

FOREHEAD

Bitemporal narrowing: See **Forehead, narrow**

Brows, prominent: See **Supraorbital ridges, prominent**

Brows, underdeveloped: See **Supraorbital ridges, underdeveloped**

Forehead, Broad—Definition: Width of the forehead or distance between the frontotemporales is more than 2 SD above the mean (Fig. 33). *objective OR*

Apparently increased distance between the two sides of the forehead. *subjective*

Comments: Frontotemporalis is a point lateral to the vertical component of the supraorbital ridge, where there is a hollowing. Spreading caliper tips are placed in the deepest part of that hollow [Farkas, 1981]. This term should not be confused with **Prominent forehead**.

Synonym: Forehead, wide

Forehead, bulging: See **Forehead, prominent** and **Frontal bossing**

Forehead, high: See **Hairline, high anterior**

Forehead, low: See **Hairline, low anterior**

Forehead, Narrow—Definition: Width of the forehead or distance between the frontotemporales is more than two SD below the mean (Fig. 34). *objective OR*

Apparently narrow inter-temporal region. *subjective*

Comments: Frontotemporalis is a point lateral to the vertical component of the supraorbital ridge, where there is a hollowing. Spreading caliper tips are placed in the deepest part of that hollow [Farkas, 1981].

Synonyms: Bitemporal narrowing; Intertemporal narrowing

Forehead, Prominent—Definition: Forward prominence of the entire forehead, due to protrusion of the frontal bone (Fig. 35). *subjective*

Comments: This is not the same as **Frontal bossing** (see below).

Replaces: Forehead, bulging

Forehead, short: See *Hairline, low anterior*

Forehead, Sloping—Definition: Inclination of the anterior surface of the forehead from the vertical more than 2 SD above the mean (Fig. 36). *objective* OR

Apparently excessive posterior sloping of the forehead in a lateral view. *subjective*

Comments: Measurement requires an angle meter, inclined on the anterior surface of the forehead, in the midline, along a line connecting the hairline to the glabella, compared to the vertical [Farkas, 1981] with the head held in the Frankfurt horizontal.

Forehead, tall: See *Hairline, high anterior*

Forehead, wide: See *Forehead, broad*

Forehead Creases, Vertical—Definition: Vertical soft tissue creases in the midline of the forehead, often extending from the hairline to the brow, and seen with facial expression, or when the face is at rest (Fig. 37). *subjective*

Frontal Bossing—Definition: Bilateral bulging of the lateral frontal bone prominences with relative sparing of the midline (Fig. 38). *subjective*

Comments: This is not the same as *Prominent forehead* (see above)

Replaces: Forehead, bulging

Glabella, Depressed—Definition: Posterior positioning of the midline forehead between the supraorbital ridges (Fig. 39). *subjective*

Comments: The glabella is the area of the forehead in the midline between the supraorbital ridges, just above the nasal root. The term “depressed” used here is not meant to signify an active process.

Glabella, Prominent—Definition: Forward protrusion of the glabella (Fig. 40). *subjective*

Comments: The glabella is the area of the forehead in the midline between the supraorbital ridges, just above the nasal root.

Intertemporal narrowing: See *Forehead, narrow*

Metopic Depression—Definition: Linear vertical groove in the midline of the forehead, extending from hairline to glabella (Fig. 41). *subjective*

Comments: There is no underlying bony defect (metopism).

Metopic Ridge, Prominent—Definition: Vertical bony ridge positioned in the midline of the forehead (Fig. 42). *subjective*

Comments: The ridge may extend from the hairline to the glabella or may be partial.

Synonym: Metopic suture, prominent

Metopic suture, prominent: See *Metopic ridge, prominent*

Supraorbital ridges, flattened: See *Supraorbital ridges, underdeveloped*

Supraorbital ridges, hypoplastic: See *Supraorbital ridges, underdeveloped*

Supraorbital ridges, hyperplastic: See *Supraorbital ridges, prominent*

Supraorbital Ridges, Prominent—Definition: Greater than average forward and/or lateral protrusion of the supraorbital portion of the frontal bones (Fig. 43). *subjective*

Comments: The ridges need not be thickened or heavy to be prominent.

Replaces: Supraorbital ridges, hyperplastic; Brows, prominent

Supraorbital Ridges, Underdeveloped—Definition: Flatness of the supraorbital portion of the frontal bones (Fig. 44). *subjective*

Synonyms: Supraorbital ridges, flattened

Replaces: Supraorbital ridges, hypoplastic; Brows, underdeveloped

MAXILLA AND MIDFACE

Cheekbone, flat: See *Cheekbone, underdeveloped*

Cheekbone Prominence—Definition: Enlargement of the zygomatic process of the temporal bone of the skull, which forms the middle and lateral inferior orbital margin (Fig. 45). *subjective*

Synonym: Zygomatic prominence

Replaces: Zygomatic hyperplasia

Cheekbone Underdevelopment—Definition: Reduction in size of the zygomatic process of the temporal bone of the skull, which forms the middle and lateral inferior orbital margin (Fig. 46). *subjective*

Synonym: Cheekbone, flat; Zygomatic underdevelopment

Replaces: Zygomatic hypoplasia

Cheeks, Full—Definition: Increased prominence or roundness of the soft tissues between the zygomata and mandible (Fig. 47). *subjective*

Cheeks, Sunken—Definition: Lack or loss of the soft tissues between the zygomata and mandible (Fig. 48). *subjective*

Comments: This appearance is found more often in edentulous patients.

Malar Flattening—Definition: Underdevelopment of the malar (frontal) process of the maxilla, appreciated in profile and/or by palpation (Fig. 49). *subjective*

Comments: The malar process is the most medial and superior portion of the maxilla, contiguous with the lateral boundary of the nasal bridge.

Replaces: Malar hypoplasia (surface examination cannot distinguish hypoplasia from hypotrophy)

Malar hyperplasia: See *Malar prominence*

Malar hypertrophy: See *Malar prominence*

Malar hypoplasia: See *Malar flattening*

Malar Prominence—Definition: Prominence of the malar (frontal) process of the maxilla and infraorbital area, appreciated in profile and from in front of the face (Fig. 50). *subjective*

Comments: The malar process is the most medial and superior portion of the maxilla, contiguous with the lateral boundary of the nasal bridge.

Replaces: Malar hypertrophy; malar hyperplasia

Midface hyperplasia: See *Midface prominence*

Midface hypertrophy: See *Midface prominence*

Midface hypoplasia: See *Midface retrusion*

Midface Prominence—Definition: Anterior positioning of the infraorbital and perialar regions, or increased convexity of the face, or increased nasolabial angle (Fig. 51). *subjective*

Comments: This term represents increased size of the maxilla (upper jaw) in length (increased midface height) or depth (midface prominence). In the presence of normal mandible size, maxillary prominence may give the appearance of retrognathia.

Replaces: Midface hyperplasia; Midface hypertrophy

Midface Retrusion—Definition: Posterior positioning and/or vertical shortening of the infraorbital and perialar regions, or increased concavity of the face and/or reduced nasolabial angle (Fig. 52). *subjective*

Comments: This term represents underdevelopment of the maxilla (upper jaw) in length (decreased midface height) or depth (retrusion of the maxilla). In the presence of normal mandible size, midface retrusion may give the appearance of prognathism. Caution should be used in making this assessment in edentulous patients. This is different from a *Flat face*.

Replaces: Midface hypoplasia

Nasolabial crease, hypoplastic: See *Nasolabial fold, underdeveloped*

Nasolabial crease, prominent: See *Nasolabial fold, prominent*

Nasolabial crease, underdeveloped: See *Nasolabial fold, underdeveloped*

Nasolabial fold, hypoplastic: See *Nasolabial fold, underdeveloped*

Nasolabial Fold, Prominent—Definition: Exaggerated bulkiness of the crease or fold of skin running from the lateral margin of the nose, where nasal base meets the skin of the face, to a point just lateral to the corner of the mouth (cheilion, or commissure) (Fig. 53). *subjective*

Comments: Increasing prominence with age is usual.

Synonym: Nasolabial crease, prominent

Nasolabial Fold, Underdeveloped—Definition: Reduced bulkiness of the crease or fold of skin running from the lateral margin of the nose, where nasal base meets the skin of the face, to a point just lateral to the corner of the mouth (cheilion or commissure) (Fig. 54). *subjective*

Synonym: Nasolabial crease, underdeveloped

Replaces: Nasolabial crease, hypoplastic; Nasolabial fold, hypoplastic

Premaxillary hyperplasia: See *Premaxillary prominence*

Premaxillary hypoplasia: See *Premaxillary underdevelopment*

Premaxillary Prominence—Definition: Overdevelopment of the premaxilla (Fig. 55). *subjective*

Comments: As a consequence of prominence of the premaxilla, the overlying structures, the nose and philtrum, may appear prominent. There is increased convexity of the face and an increased nasolabial angle. In the presence of a normal sized mandible, retrognathia may be appreciated.

Replaces: Premaxillary hyperplasia

Premaxillary Underdevelopment—Definition: Reduction in size of the premaxilla (Fig. 56). *subjective*

Comments: As a consequence of underdevelopment of the premaxilla, the overlying structures, the nose and philtrum, may appear flattened. There is increased concavity of the face and a reduced nasolabial angle. In the presence of a normal sized mandible, prognathism may be appreciated.

Replaces: Premaxillary hypoplasia

Zygomatic hyperplasia: See *Cheekbone prominence*

Zygomatic hypoplasia: See *Cheekbone underdevelopment*

Zygomatic prominence: See *Cheekbone prominence*

Zygomatic underdevelopment: See *Cheekbone underdevelopment*

MANDIBLE

Chin, retruded: See *Retrognathia*

Habsburg/Hapsburg chin: See *Prognathism*

Habsburg/Hapsburg jaw: See *Prognathism*

Jaw, Broad—Definition: Bigonial distance (lower facial width) more than 2 SD above the mean (Fig. 57). *objective* OR

Apparently increased width of the lower jaw (mandible) when viewed from the front. *subjective*

Comments: The lower jaw is measured from the right gonion to the left gonion using spreading calipers. The gonion is the point at the angle of the bony mandible where the ramus changes direction to become the body of the mandible. It faces inferiorly and medially and is best found

by placing a finger over the outward facing angle and rolling the finger downwards and inwards [Farkas, 1981]. When a broad jaw is accompanied by a broad upper face the term **Square face** is used.

Synonyms: Jaw, wide; Mandible, broad; Mandible, wide; Lower face, broad; Lower face, wide

Jaw, Narrow—Definition: Bigonial distance (lower facial width) more than 2 SD below the mean (Fig. 58). *objective* OR

Apparently decreased width of the lower jaw (mandible) when viewed from the front.
subjective

Comments: This dimension is measured from the right gonion to the left gonion using spreading calipers. The gonion is the point at the angle of the bony mandible where the ramus changes direction to become the body of the mandible. It faces inferiorly and medially and is best found by placing a finger over the outward facing angle and rolling the finger downwards and inwards [Farkas, 1981].

Synonyms: Mandible, narrow; Lower face, narrow

Jaw, small: See **Micrognathia**

Jaw, wide: See **Jaw, broad**

Lower face, broad: See **Jaw, broad**

Lower face, narrow: See **Jaw, narrow**

Lower face, wide: See **Jaw, broad**

Mandible, broad: See **Jaw, broad**

Mandible narrow: See **Jaw, narrow**

Mandible, wide: See **Jaw, wide**

Mandible, Cleft—Definition: Midline deficiency of the mandible and some or all overlying tissues (Fig. 59). *objective*

Mandible, narrow: See **Jaw, narrow**

Mandible, retruded: See **Retrognathia**

Mandible, wide: See **Jaw, broad**

Micrognathia—Definition: Apparently reduced length and width of the mandible when viewed from the front but not from the side (Fig. 60). *subjective*

Comments: This is a bundled term comprising shortening and narrowing of the mandible and chin. It is defined here as it is a term in common usage.

Synonyms: Micrognathism; Jaw, small

Micrognathism: See **Micrognathia**

Prognathia: See **Prognathism**

Prognathism—Definition: Anterior protrusion of the mandibular alveolar ridge beyond the vertical plane of the maxillary alveolar ridge, best appreciated in profile (Fig. 61). *subjective*

Comments: The examiner must use judgment to distinguish a protruding mandible from an *Underdeveloped premaxilla* or *Retruded midface*, either of which may be accompanied by class III malocclusion.

Synonym: Prognathia

Replaces: Habsburg chin; Hapsburg chin; Habsburg jaw; Hapsburg jaw

Retrognathia—Definition: Posteriorly positioned lower jaw, which is set back from the plane of the face when viewed from the side but not from the front (Fig. 62). *subjective*

Comments: This feature may be accompanied by micrognathia (microretrognathia) in which case both retrognathia and micrognathia should be specified and coded separately. Alternatively, it may be a mismatch in the relative position of the mandible and premaxilla, with normal mandibular length and premaxillary prominence and is accompanied by a class II malocclusion.

Synonyms: Chin, retruded; Mandible, retruded; Retrognathism

Retrognathism: See *Retrognathia*

CHIN

Chin, Broad—Definition: Increased width of the midpoint of the mandible (mental protuberance) and overlying soft tissue (Fig. 63). *subjective*

Comments: Micrognathia is a term that represents reduction in size of both length and width of the chin. By contrast, increases in chin size are coded separately as *Tall chin* and *Broad chin*.

Chin, cleft: See *Chin, vertical crease*

Chin Dimple—Definition: A persistent midline depression of the skin over the fat pad of the chin (Fig. 64). *subjective*

Comments: The borders of the depression are round.

Chin, Horizontal Crease—Definition: Horizontal crease or fold situated below the vermilion border of the lower lip and above the fatty pad of the chin, with the face at rest (Fig. 65). *subjective*

Chin, H-Shaped Crease—Definition: H-shaped crease in the fat pad of the chin (Fig. 66). *subjective*

Comments: The H-shape must be distinguished from *Vertical crease of the chin*.

Synonym: Chin, H-shaped groove.

Chin, H-shaped groove: See *Chin, H-shaped crease*

Chin, long: See *Chin, tall*

Chin, Pointed—Definition: A marked tapering of the lower face to the chin (Fig. 67). *subjective*

Comments: The two rami of the mandible meet at an acute angle.

Chin, Short—Definition: Decreased vertical distance from the vermilion border of the lower lip to the inferior-most point of the chin (Fig. 68). *subjective*

Comments: *Micrognathia* is used when the chin is both short (vertical dimension) and narrow (horizontal dimension).

Chin, Tall—Definition: Increased vertical distance from the vermilion border of the lower lip to the inferior-most point of the chin (Fig. 69). *subjective*

Synonym: Chin, long

Chin, Vertical Crease—Definition: Vertical crease in the fat pad of the chin with the face at rest (Fig. 70). *subjective*

Comments: A vertical crease must be distinguished from an *H-shaped crease of the chin*.

Replaces: Chin, cleft

NECK

Bull-neck: See *Neck, broad*

Neck, Broad—Definition: Increased width of the neck when viewed from the front or back (Fig. 71). *subjective*

Comments: Neck circumference may provide an objective measure of increase in width. Neck circumference is measured in a horizontal plane at the level of the most prominent portion of the thyroid cartilage, using a tape measure, with the head held erect and eyes facing forward. See *Neck webbing* for a related finding.

Synonyms: Neck, thick; Neck, wide

Replaces: Bull-neck

Neck, Long—Definition: Increased distance from the point where neck and shoulders meet to the inferior margin of the occipital bone (Fig. 72). *subjective*

Comments: No objective measure is available

Neck, Short—Definition: Decreased distance from the point where neck and shoulders meet to the inferior margin of the occipital bone (Fig. 73). *subjective*

Comments: No objective measure is available

Neck, thick: See *Neck, broad*

Neck Webbing—Definition: A paravertically oriented fold of skin on the posterolateral aspect of the neck, usually extending from the mastoid region of the skull to the acromion, and best appreciated in frontal or posterior view (Fig. 74). *subjective*

Comments: This feature is often accompanied by a *Low posterior hairline*, but this should be coded separately.

Synonym: Pterygium colli

Neck, wide: See *Neck, broad*

Nuchal Skin, Redundant—Definition: Excess skin around the neck, often lying in horizontal folds (Fig. 75). *subjective*

Comments: With age and increased vertical growth of the neck, excess nuchal skin may disappear and the neck may become broad or webbed. If the skin folds are vertical or paravertical, the term *Neck webbing* should be used.

Pterygium colli: See *Neck webbing*

Acknowledgments

We are grateful to Astrid Sibbes for drawing Figures 1–4. This paper was reviewed and edited by the co-Chairs of the International Dysmorphology Terminology working group (Judith Allanson, Leslie Biesecker, John Carey, and Raoul Hennekam). This review and editing was necessary to increase the consistency of formatting and content among the six manuscripts [Allanson et al., 2008; Biesecker et al., 2008; Carey et al., 2008; Hall et al., 2008; Hennekam et al., 2008; Hunter et al., 2008]. While the authors of the papers are responsible for the original definitions and drafting of the papers, final responsibility for the content of each paper is shared by the authors and the four co-Chairs.

References

- Allanson JE, Biesecker LG, Carey JC, Hennekam RC. Elements of morphology: Introduction. *Am J Med Genet Part A* 2008;149A:2–5. [PubMed: 19127575]
- Biesecker LG, Aase JM, Clericuzio C, Gurrieri F, Temple K, Toriello H. Elements of morphology: Standard terminology for the hands and feet. *Am J Med Genet Part A* 2008;149A:93–127. [PubMed: 19125433]
- Carey JC, Cohen MM Jr, Curry C, Devriendt K, Holmes L, Verloes A. Elements of morphology: Standard terminology for the lips, mouth, and oral region. *Am J Med Genet Part A* 2008;149A:77–92. [PubMed: 19125428]
- Farkas, LG. Anthropometry of the head and face in medicine. New York: Elsevier; 1981.
- Hall, JG.; Allanson, JE.; Gripp, K.; Slavotinek, A. Handbook of normal physical measurements. Vol. 2. New York: Oxford University Press; 2007.
- Hall BD, Graham JM Jr, Cassidy SB, Opitz JM. Elements of morphology: Standard terminology for the periorbital region. *Am J Med Genet Part A* 2008;149A:29–39. [PubMed: 19125427]
- Hennekam RC, Cormier-Daire V, Hall J, Méhes K, Patton M, Stevenson R. Elements of morphology: Standard terminology for the nose and philtrum. *Am J Med Genet Part A* 2008;149A:61–76. [PubMed: 19152422]
- Hunter AGW, Frias F, Gillessen-Kaesbach G, Hughes HE, Jones KL, Wilson L. Elements of morphology: Standard terminology for the ear. *Am J Med Genet Part A* 2008;149A:40–60. [PubMed: 19152421]

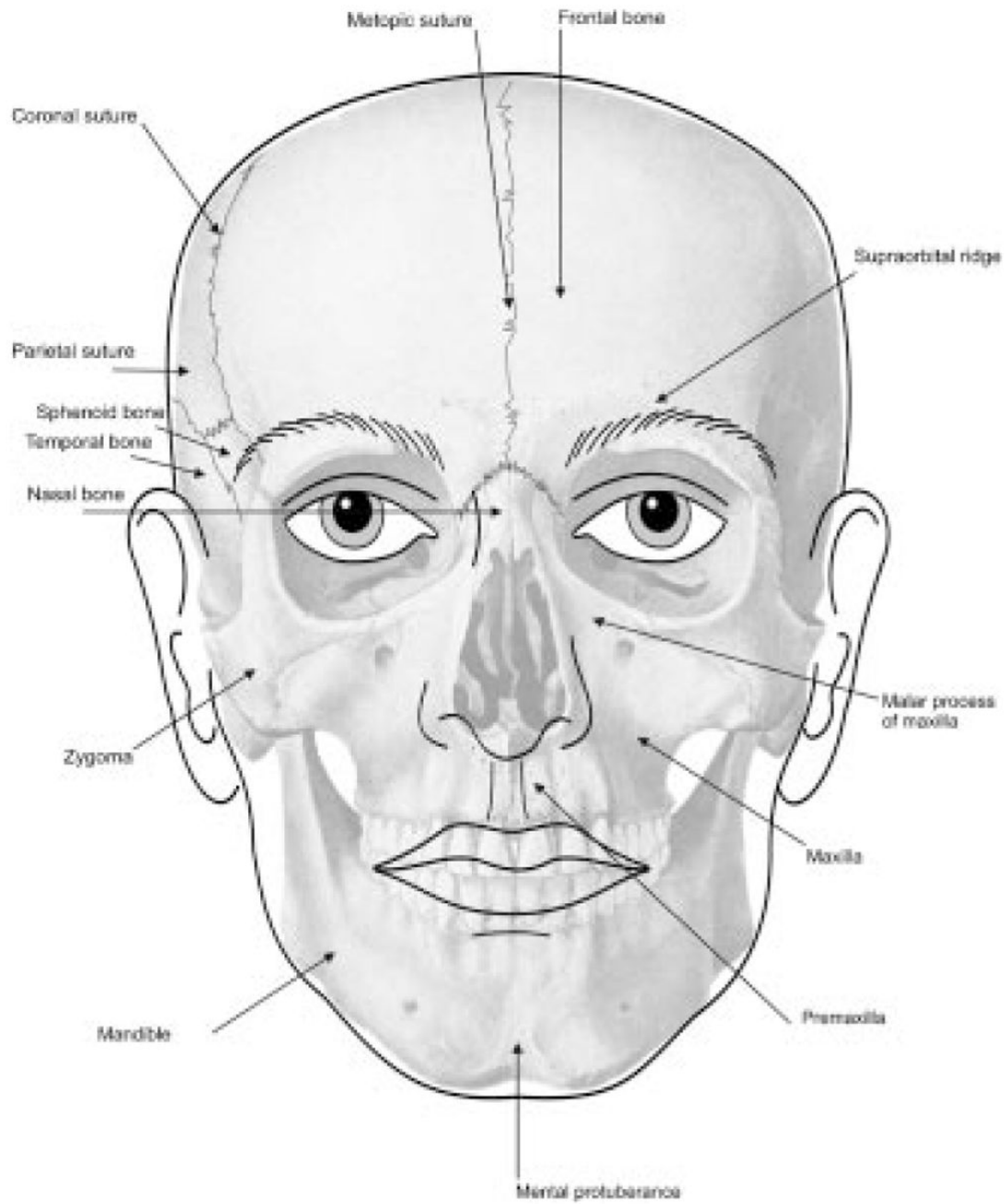


FIG. 1.
An antero-posterior view of the cranium and face shows bony landmarks.

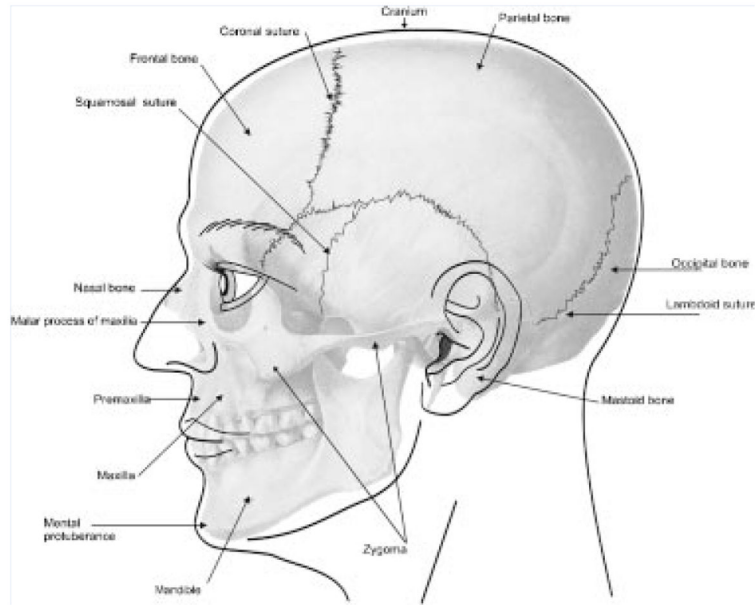


FIG. 2.
A lateral view of the cranium and face shows bony landmarks.

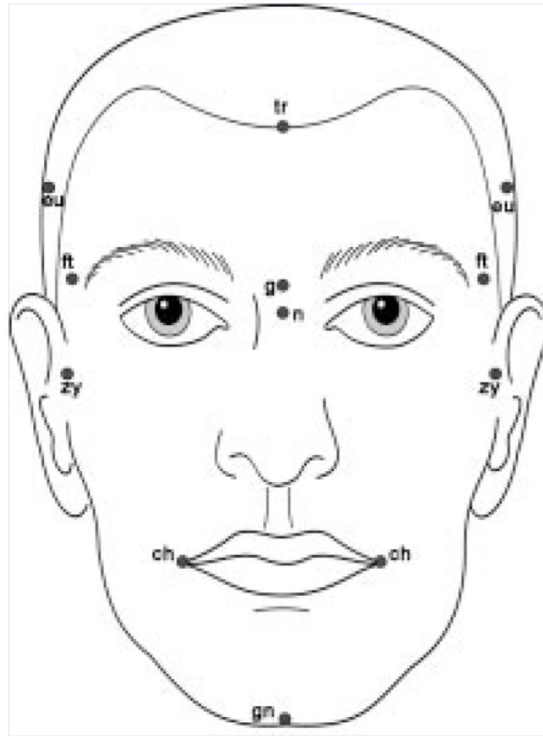


FIG. 3. Anthropological landmarks of the face, frontal view, which are described in this paper.

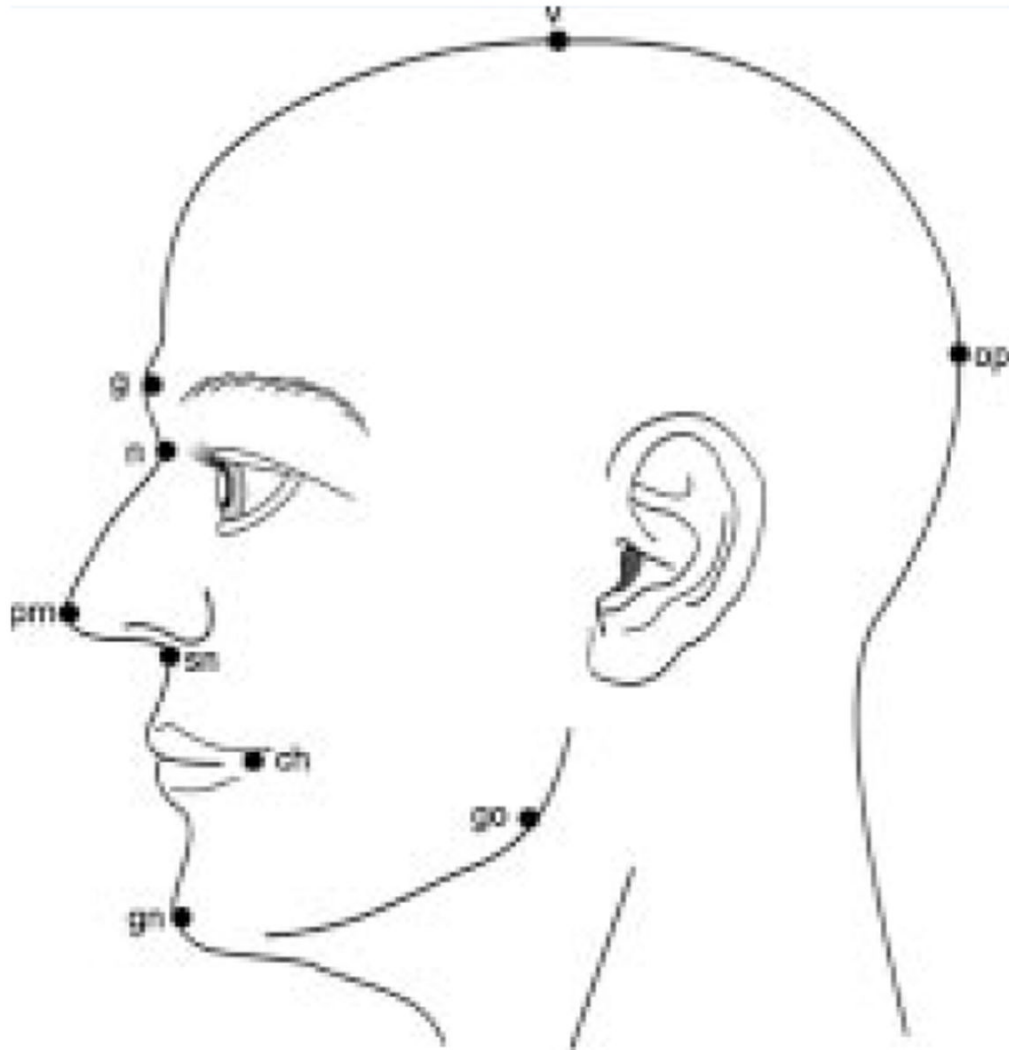


FIG. 4.
Anthropological landmarks of the face, lateral view, which are described in this paper.

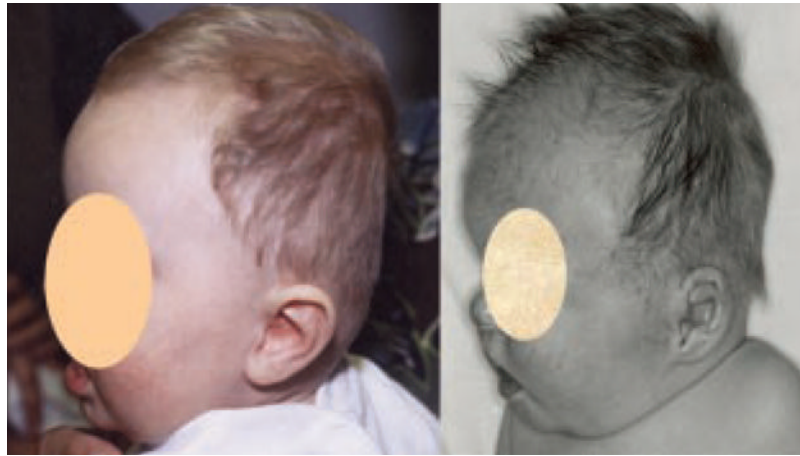

FIG. 5.
Brachycephaly: The skull has a reduced antero-posterior dimension with the back of the head appearing to have reduced convexity.

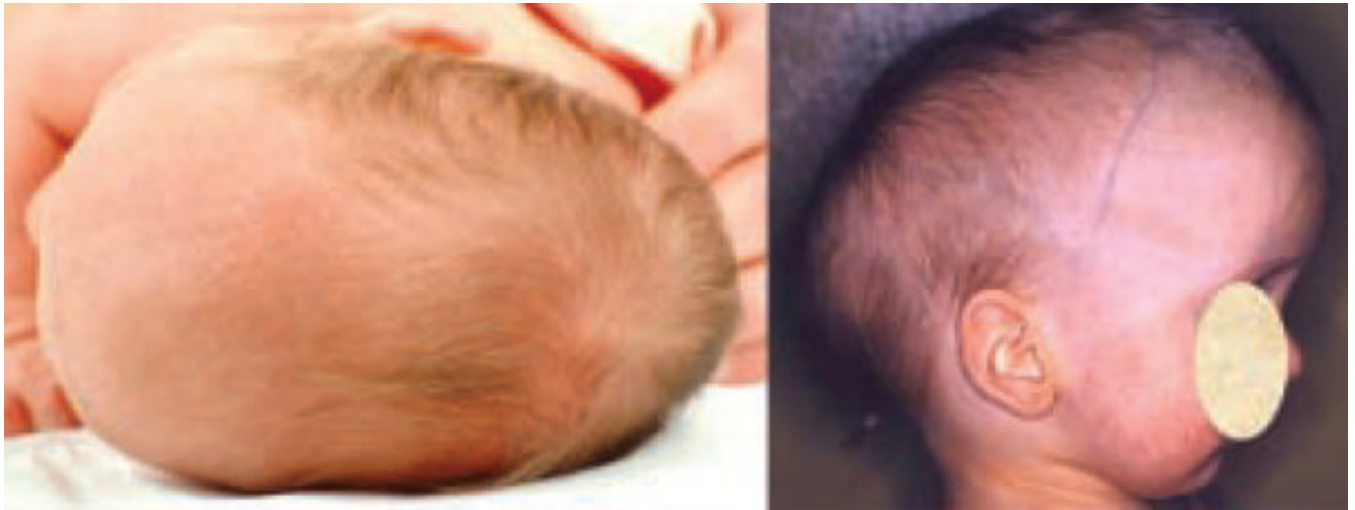

FIG. 6.
Dolichocephaly. The skull has an increased antero-posterior dimension. Scaphocephaly is demonstrated on the right. Note that this subtype of dolichocephaly is “boat-shaped” with pointed anterior and posterior aspects of the cranial vault.

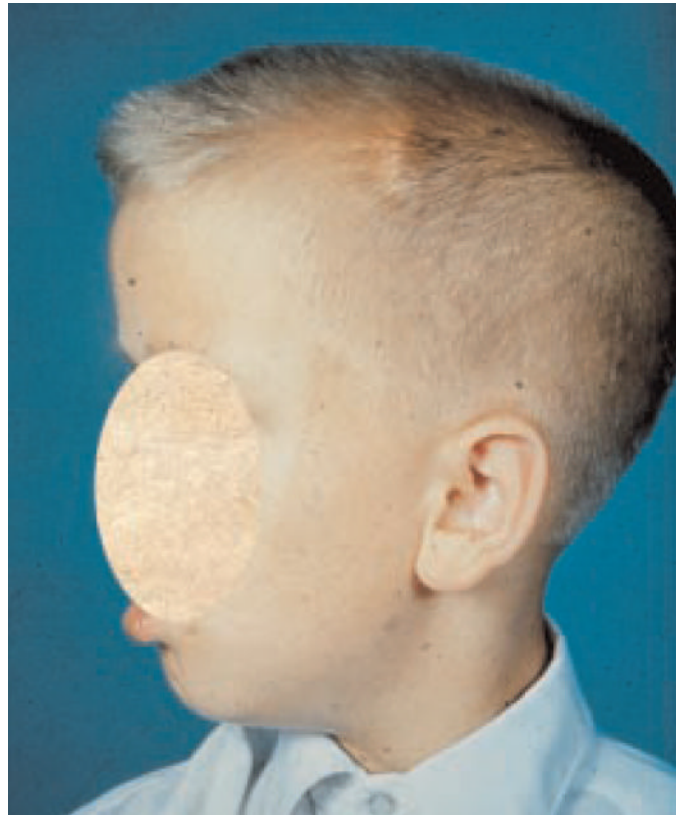

FIG. 7. *Macrocephaly*. Note the increased size of the cranium. Differences in size are difficult to appreciate but increased head size in this child is notable because of comparison with the smaller face.

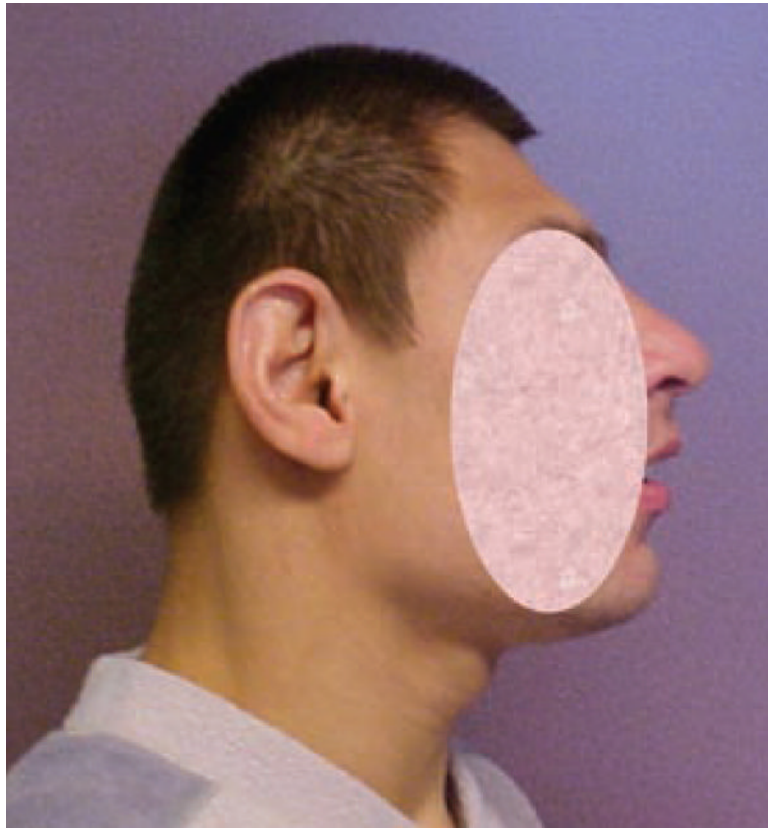

FIG. 8.
Microcephaly. Decreased size of the cranium is accompanied by marked posterior sloping of the forehead.

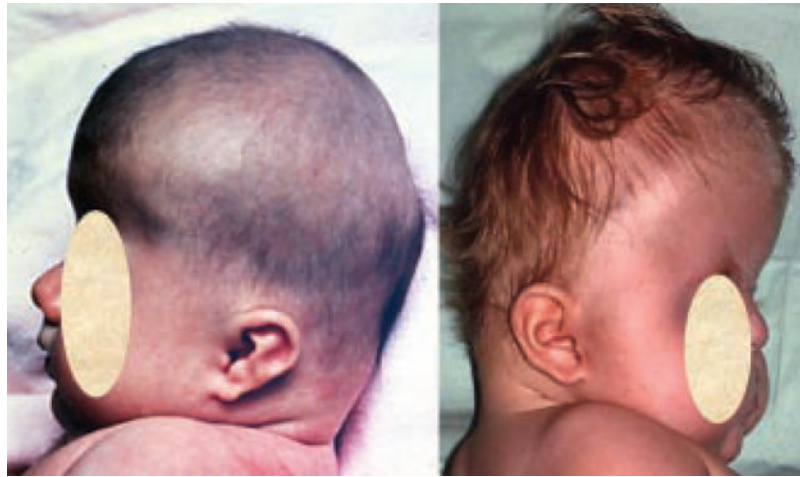

FIG. 9. Occiput, flat

There is reduced convexity of the occiput giving an appearance of flattening of the back of the skull.

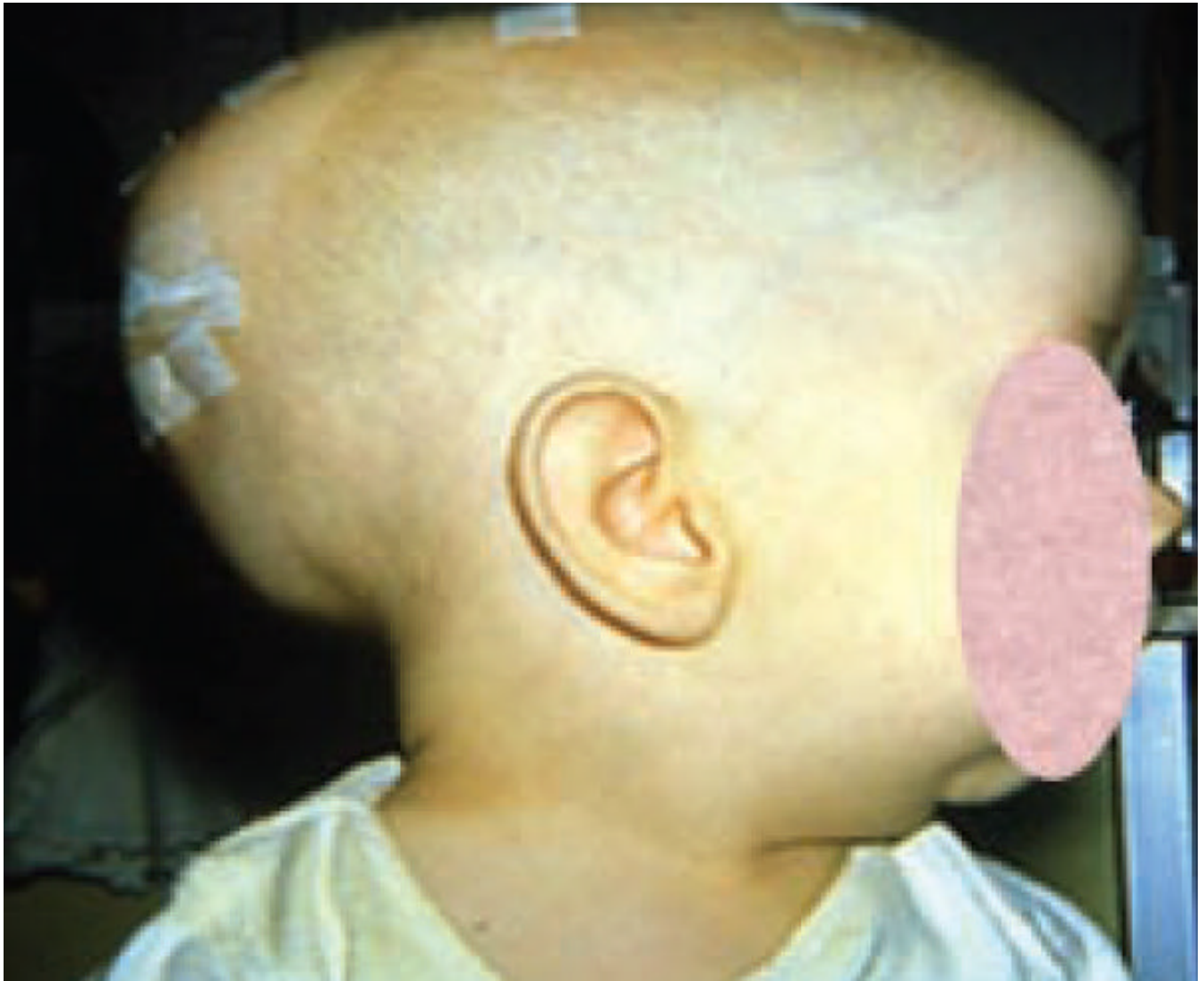

FIG. 10. Occiput, prominent
The posterior part of the skull shows increased convexity.

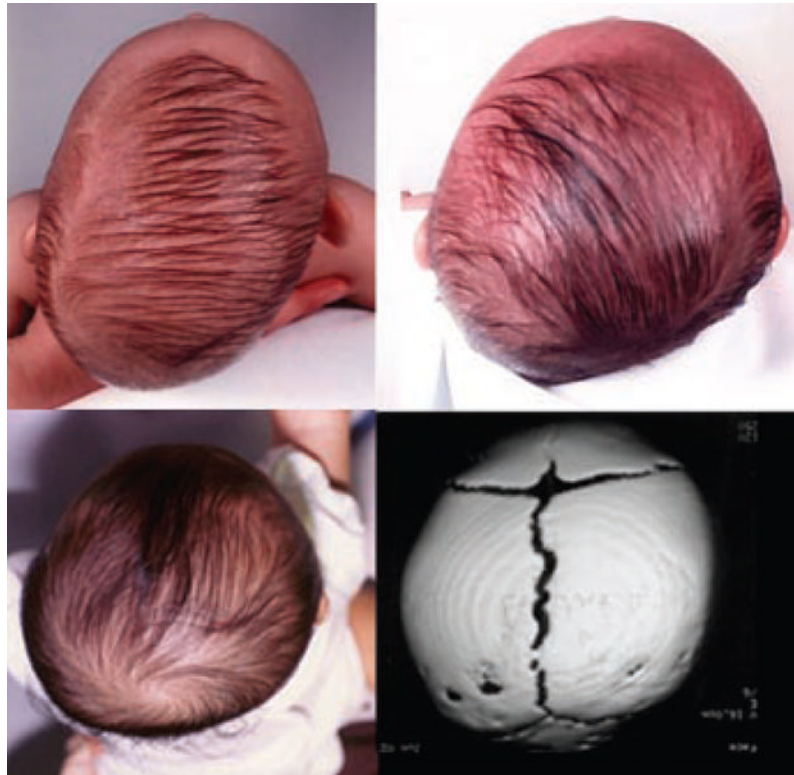


FIG. 11. *Plagiocephaly*. There is asymmetry of head shape: Note that one can see a combination of unilateral occipital flattening with ipsilateral frontal prominence, leading to rhomboid cranial shape or asymmetry of the posterior skull alone. These figures are kindly provided by John Graham Jr.

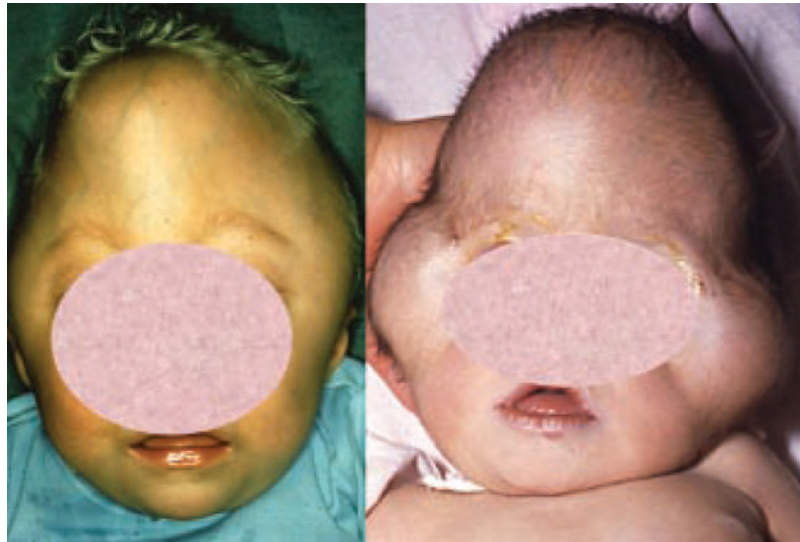

FIG. 12. Skull, Cloverleaf

The skull has a trilobar configuration when viewed from the front or behind.

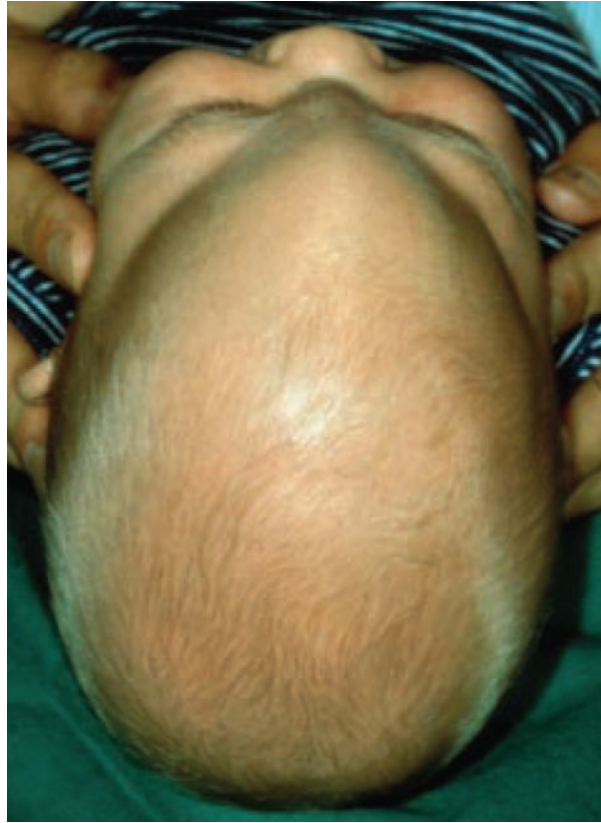

FIG. 13. *Trigonocephaly*. Note the wedge-shaped, or triangular head, with the apex of the triangle at the midline of the forehead and the base of the triangle at the occiput.

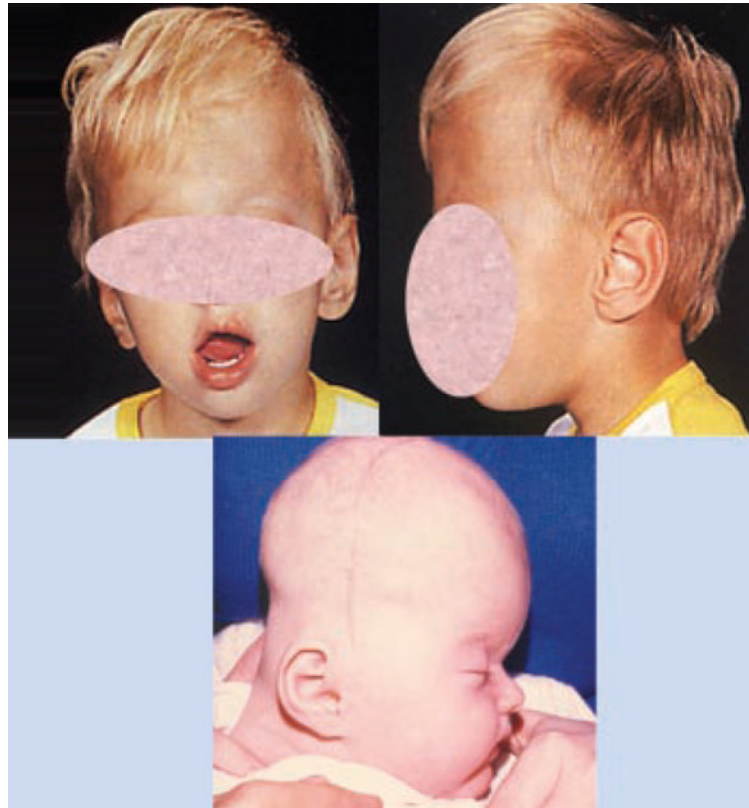


FIG. 14. *Turricephaly*. The head is tall head relative to its width and length. The terms acrocephaly or oxycephaly are used when there is turricephaly and the top of the skull assumes a cone shape (lower image).

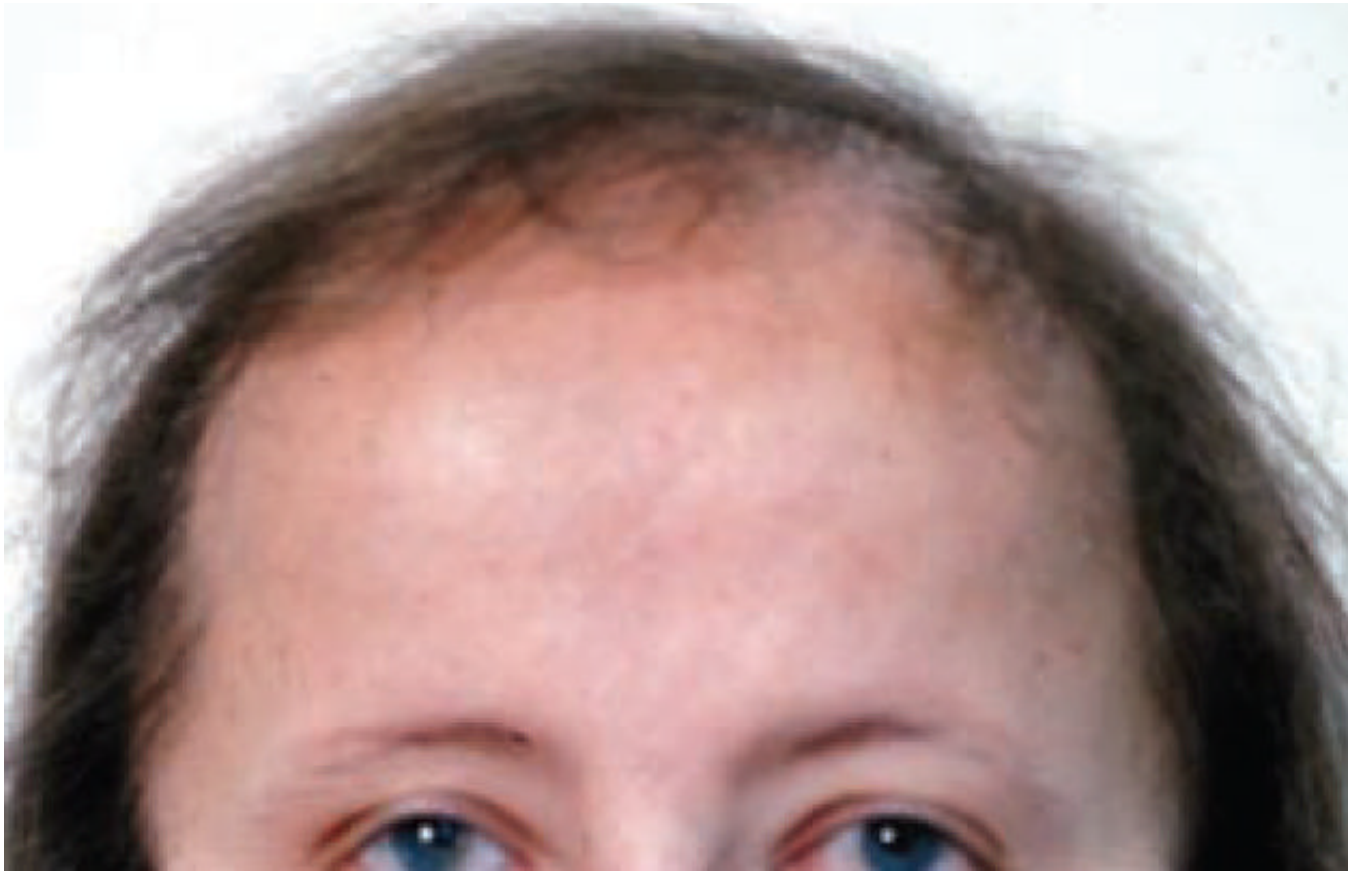

FIG. 15. Frontal balding
Note the absence of hair in the anterior midline and/or parietal areas.



FIG. 16. Hair, frontal upsweep
Note the pattern of upward and sideward growth of anterior hair.

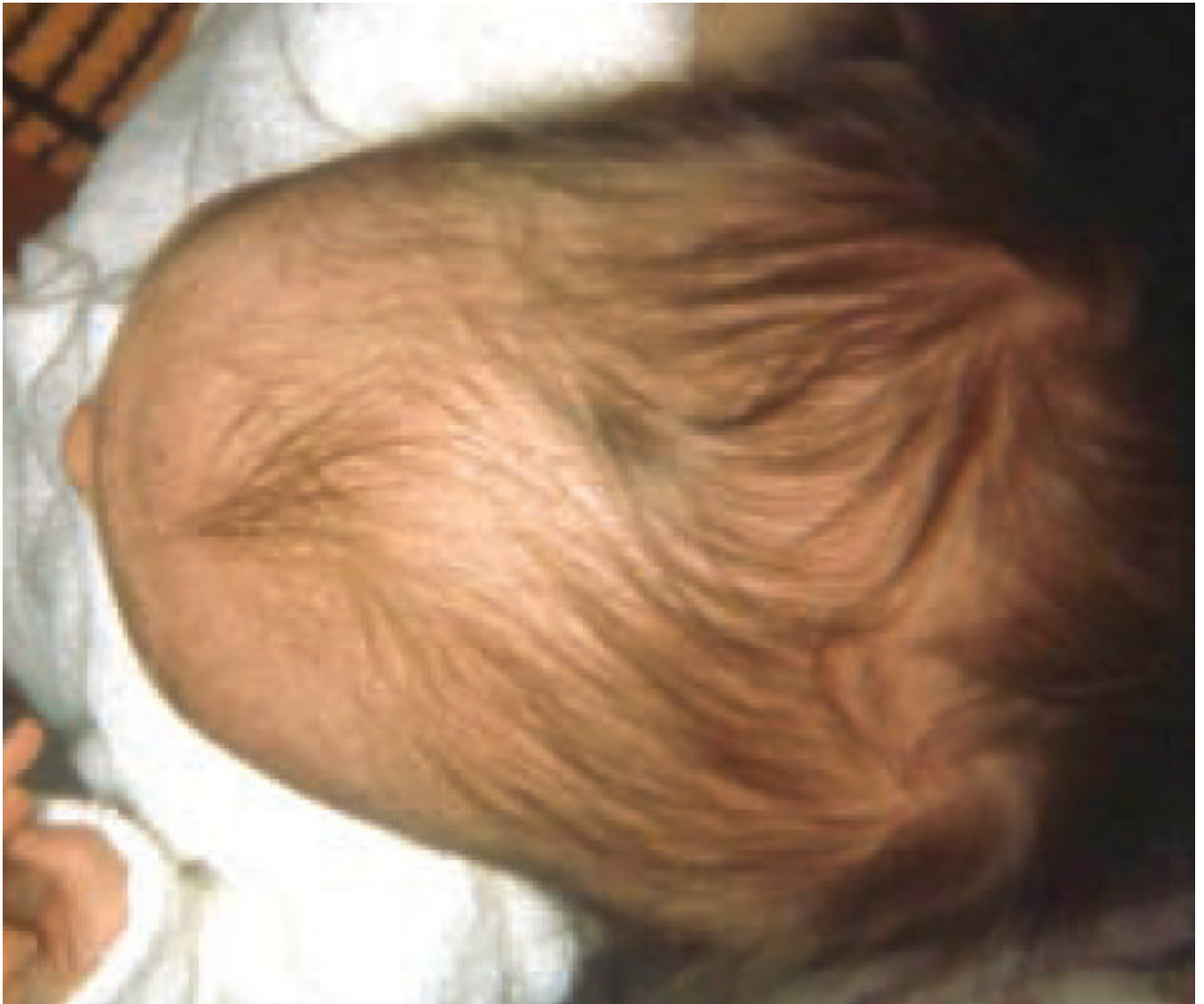

FIG. 17.
Hair whorl, double.

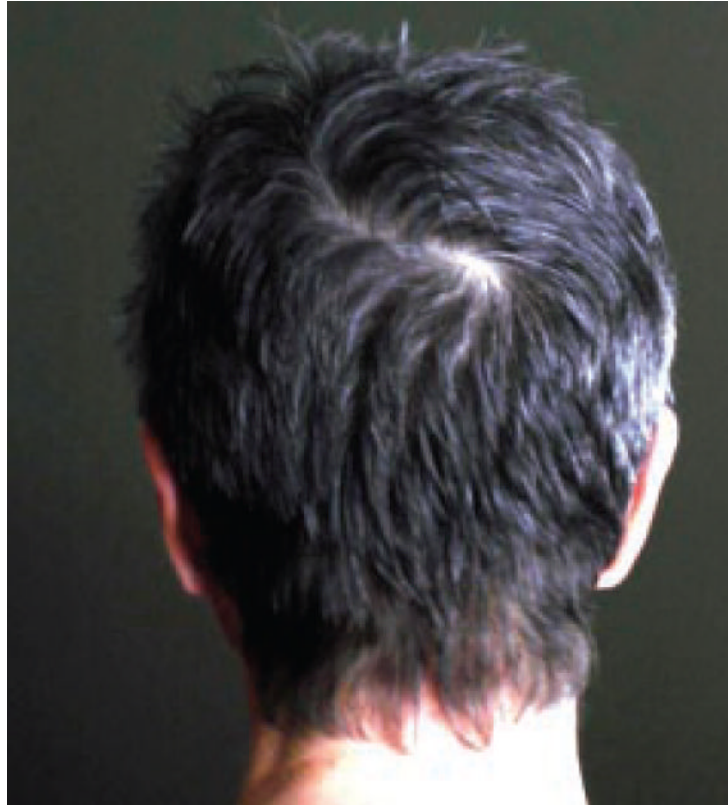


FIG. 18. Hair whorl, abnormal position

The hair whorl is positioned postero-inferiorly than its usual location lateral to the midline and close to the vertex of the skull.

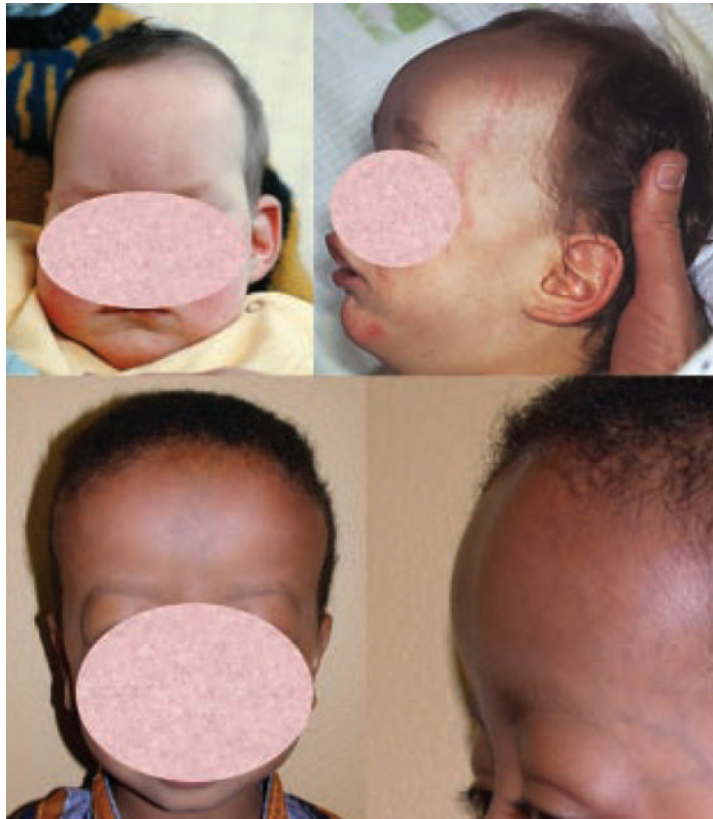

FIG. 19. Hairline, high anterior
The high anterior hairline contributes to an appearance of tall forehead.

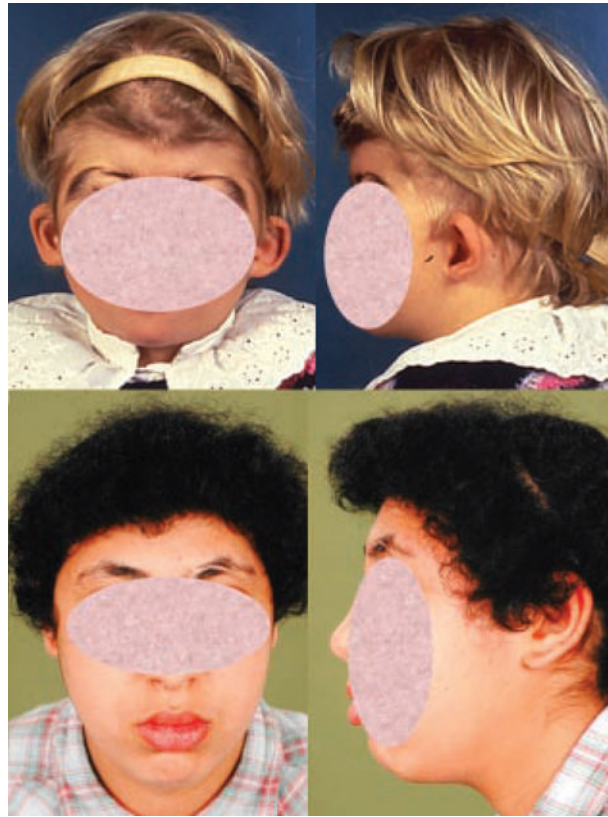

FIG. 20. Hairline, low anterior

The low anterior hairline contributes to an appearance of short forehead.



FIG. 21. Hairline, low posterior
Hair on the neck extends more inferiorly than usual, particularly in the lateral aspects.

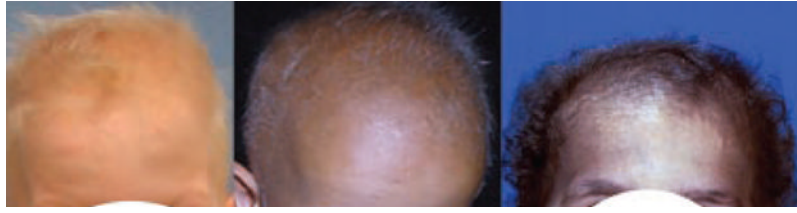

FIG. 22. Scalp hair, sparse
Hair density is reduced giving a thinned appearance.

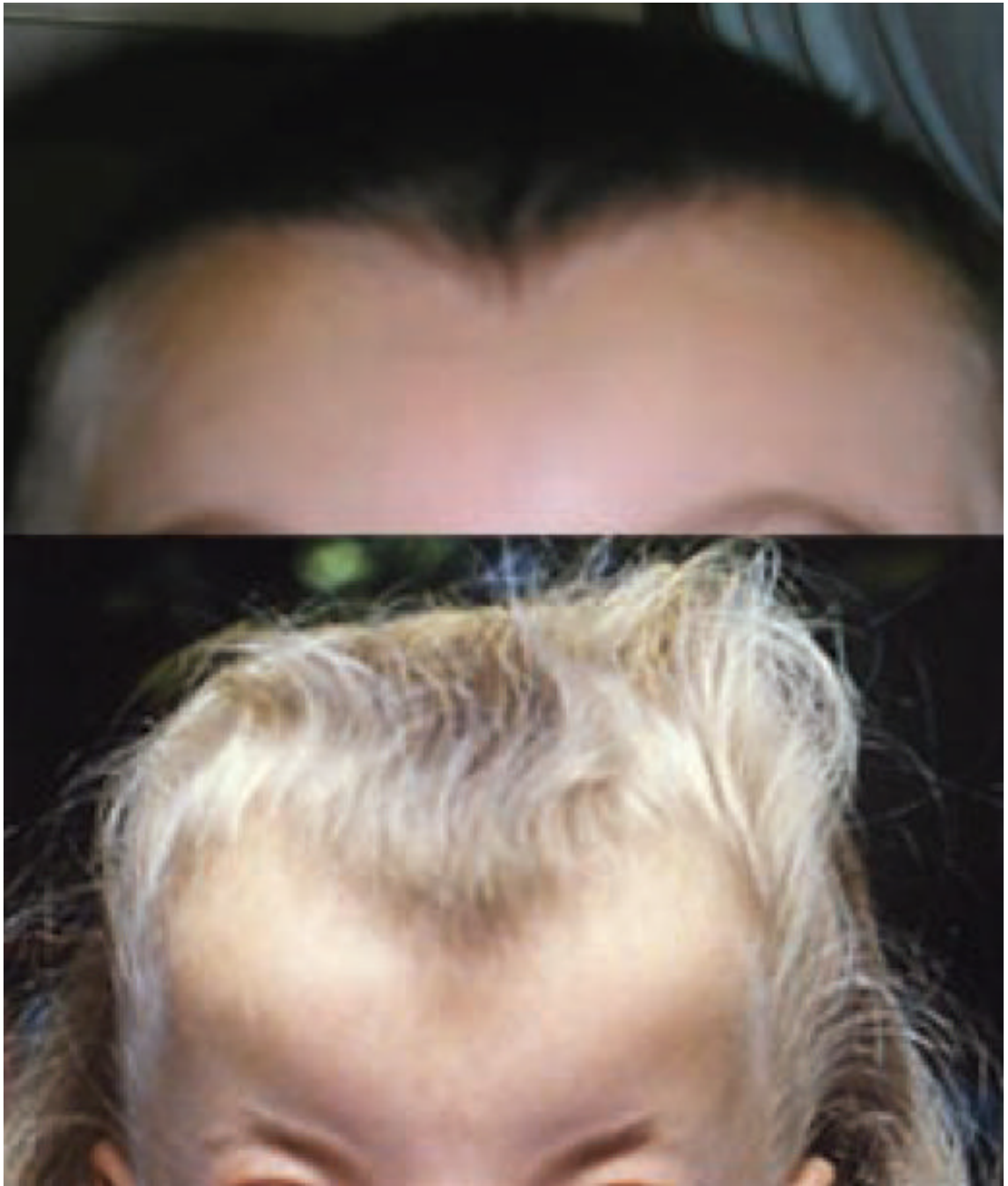

FIG. 23. Widow's peak
Frontal hairline shows bilateral arcs to a low point in the midline of the forehead.

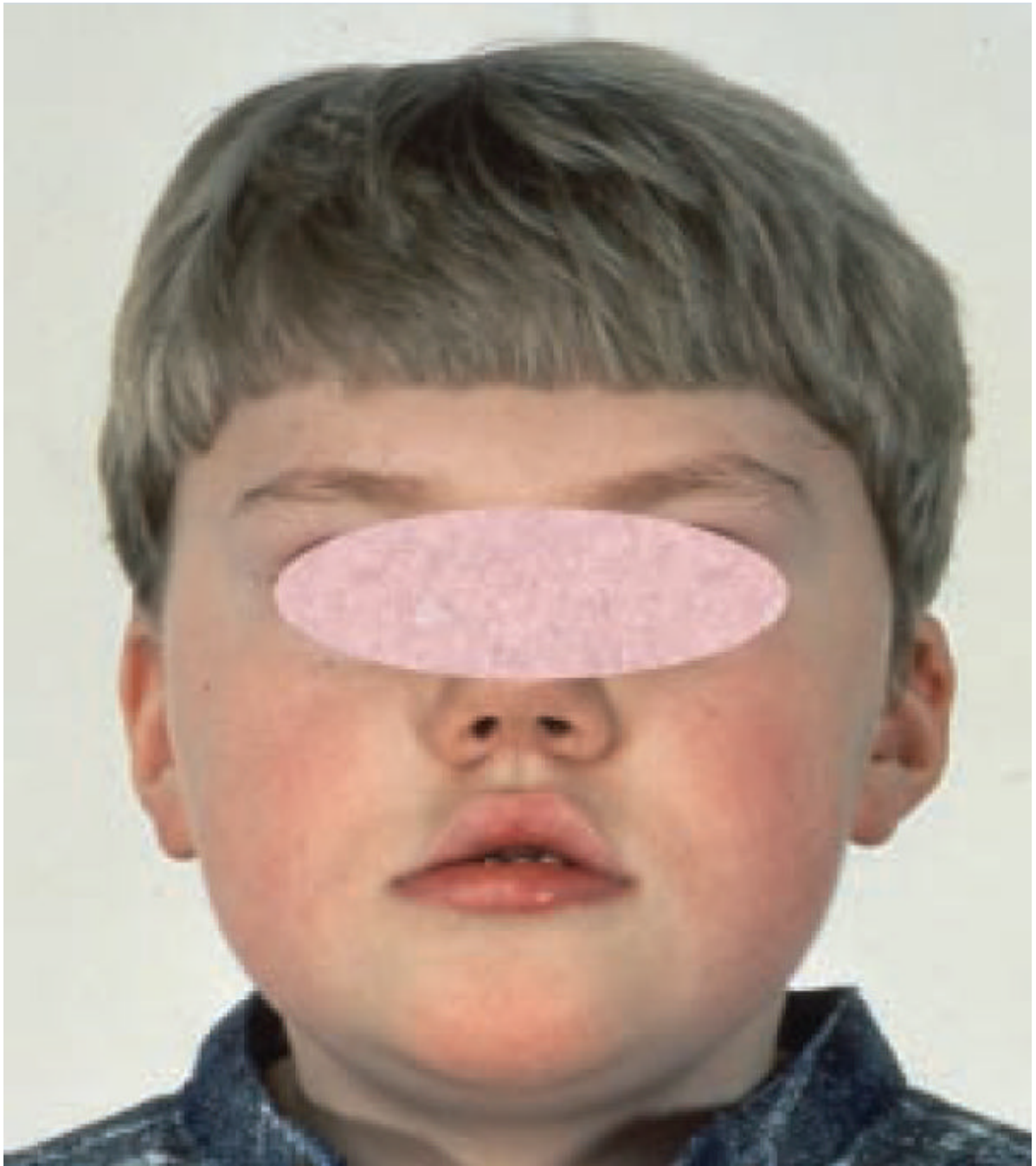


FIG. 24. Face, broad
An increased width of the upper and lower face.

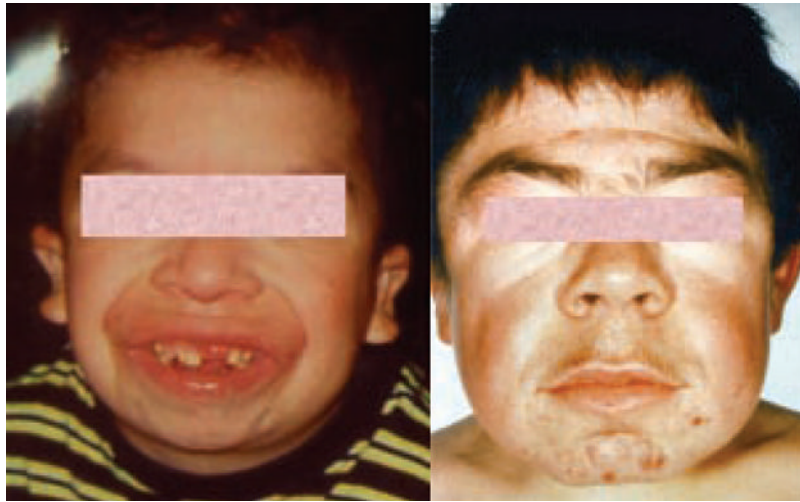

FIG. 25. Face, coarse

Facial features lack the usual fine and sharp appearance and are rounded and heavy with thickened skin, subcutaneous or bony tissues.

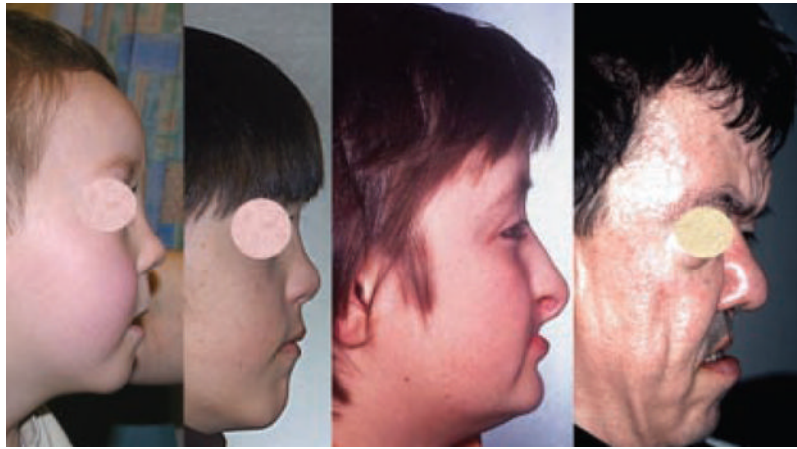

FIG. 26. Face, flat

The profile of the face is flat with no concavity or convexity.

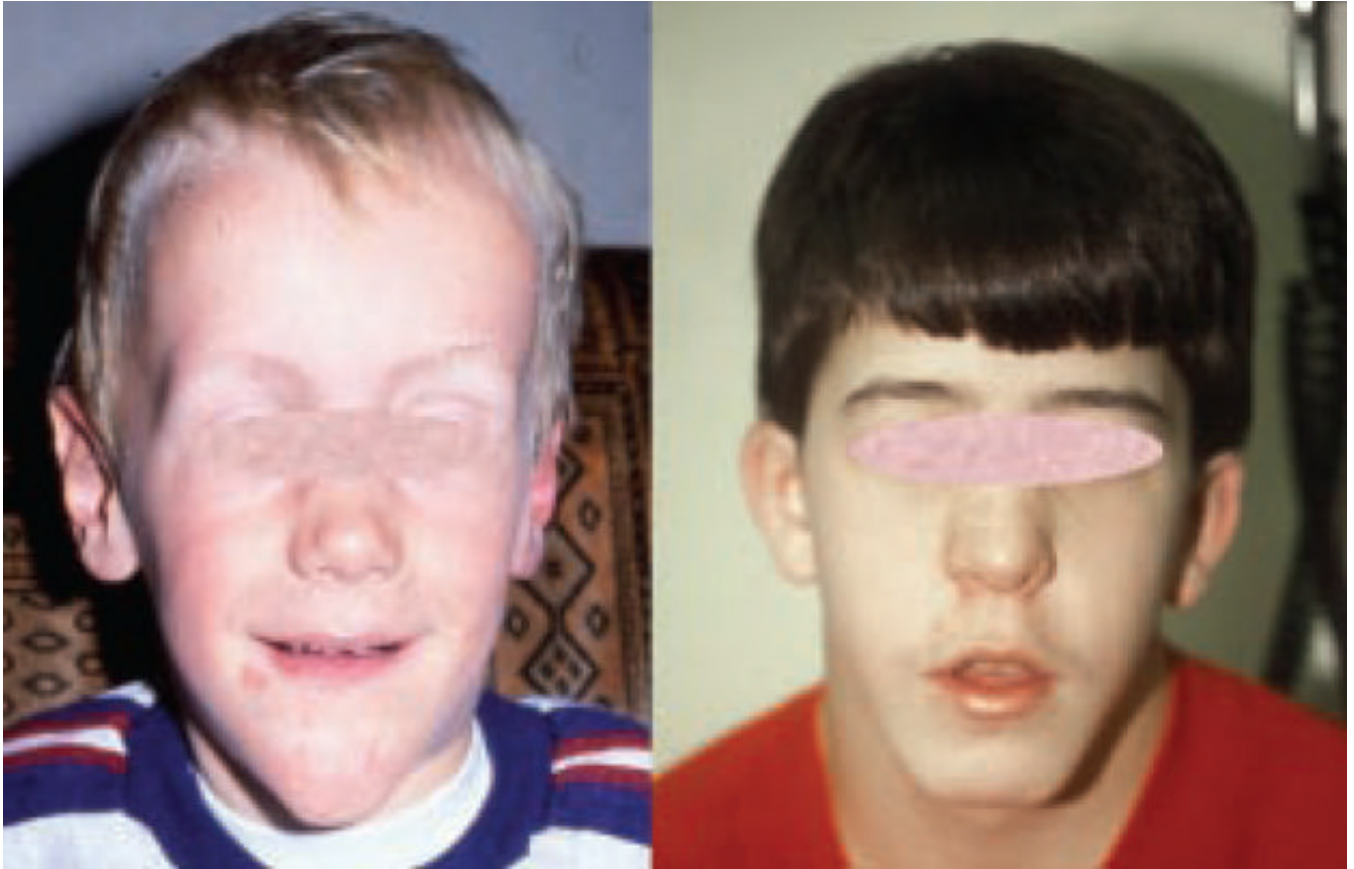

FIG. 27. Face, long

Height (length) of the face is increased in comparison to face width. Without actual measurement it can be difficult to decide whether increased height or reduced width is real.

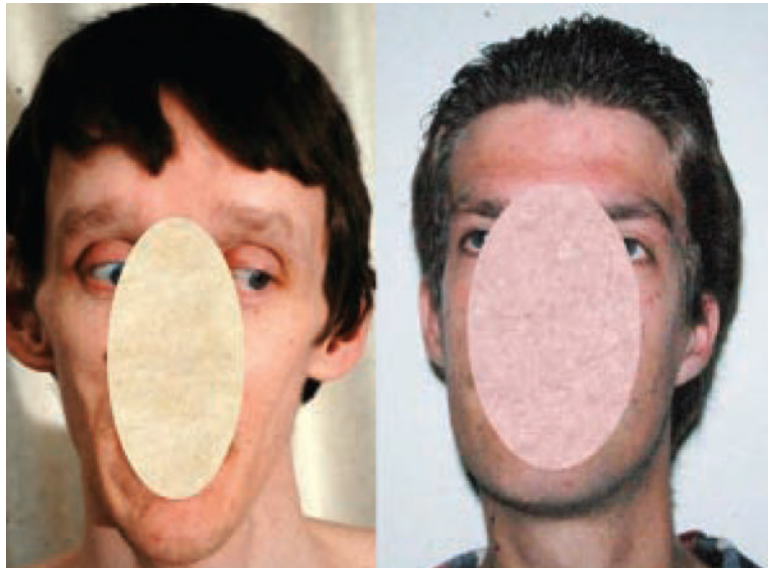

FIG. 28. Face, narrow

There is reduction in width of the upper and lower face. Without actual measurement it can be difficult to decide whether increased height or reduced width is real.

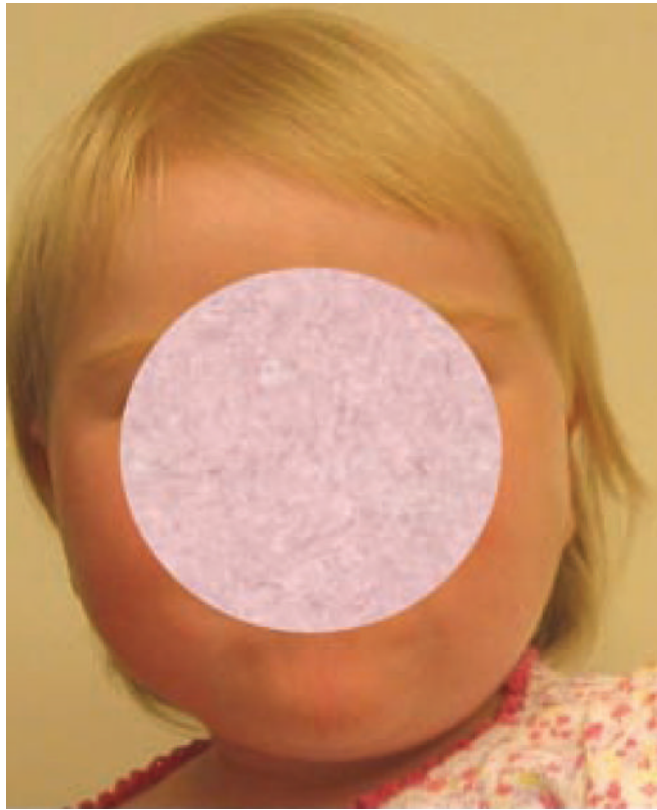


FIG. 29. Face, round
Facial appearance is more circular than usual.

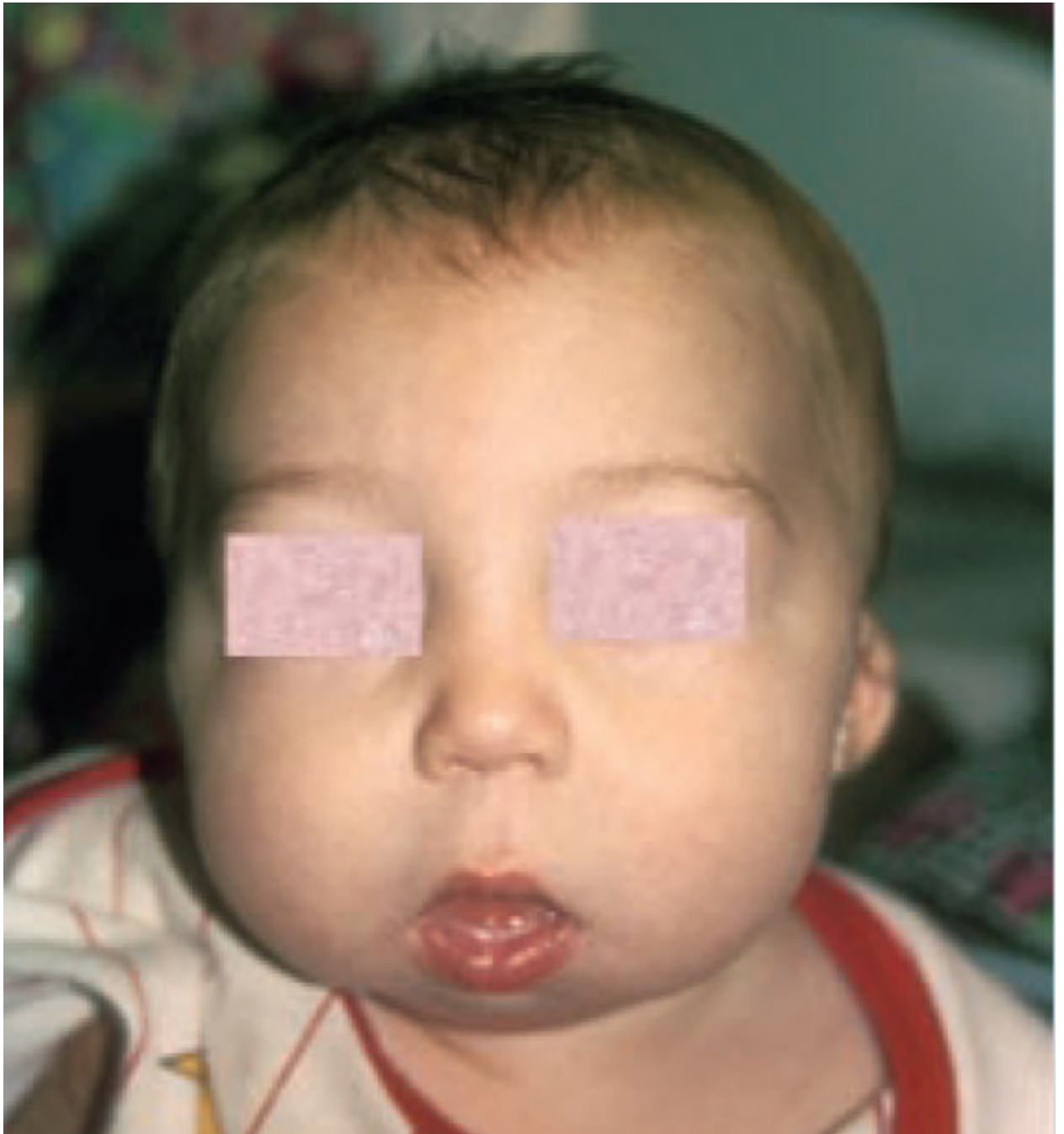

FIG. 30. Face, short

Decreased height (length) of the face is usually appreciated in comparison to face width and it may be difficult to decide whether reduced height or increased width is present without measurement.

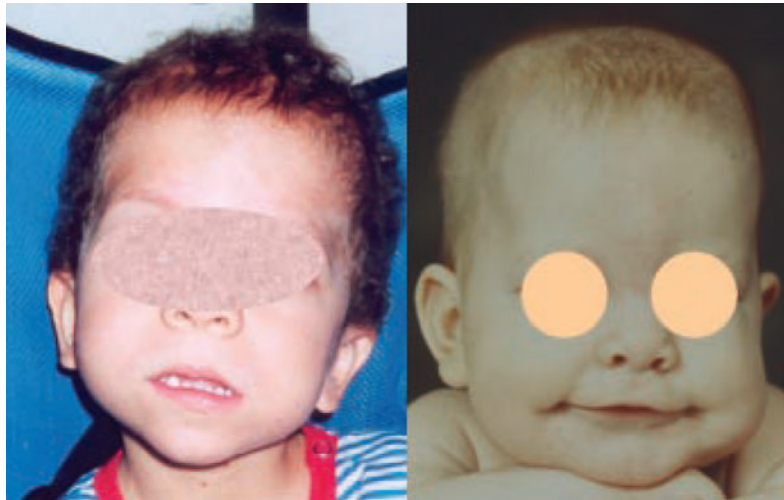

FIG. 31. Face, square
The upper face/cranium and lower face/mandible are both broad, creating a square appearance.

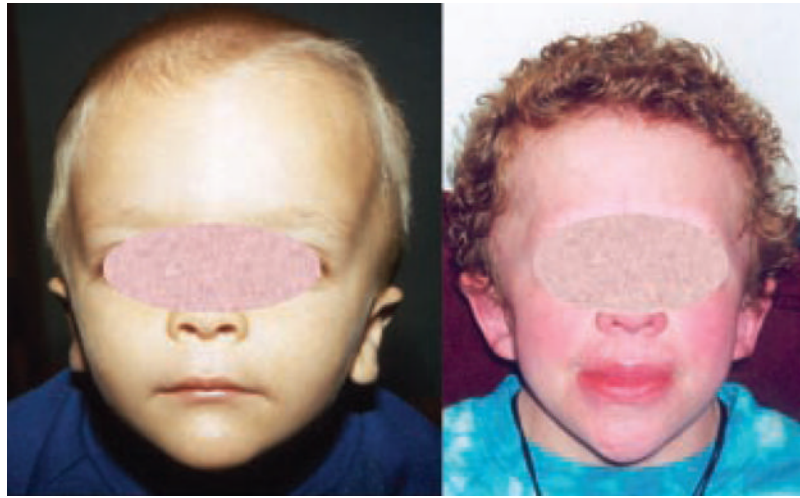

FIG. 32. Face, triangular

Facial contours are triangular in shape, with breadth at the temples tapering to a narrow chin.

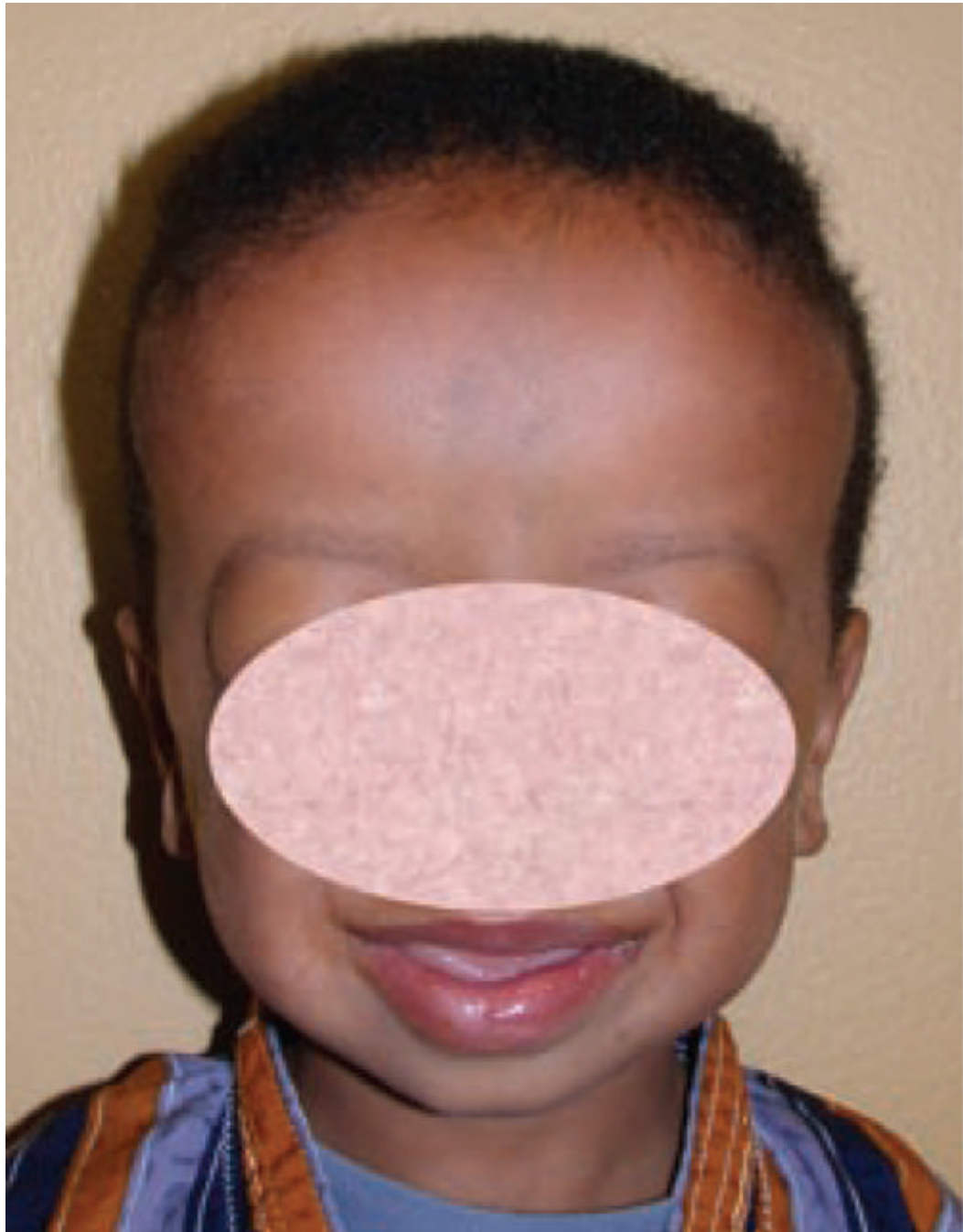

FIG. 33. Forehead, broad

Note the increased distance between the two sides of the forehead.

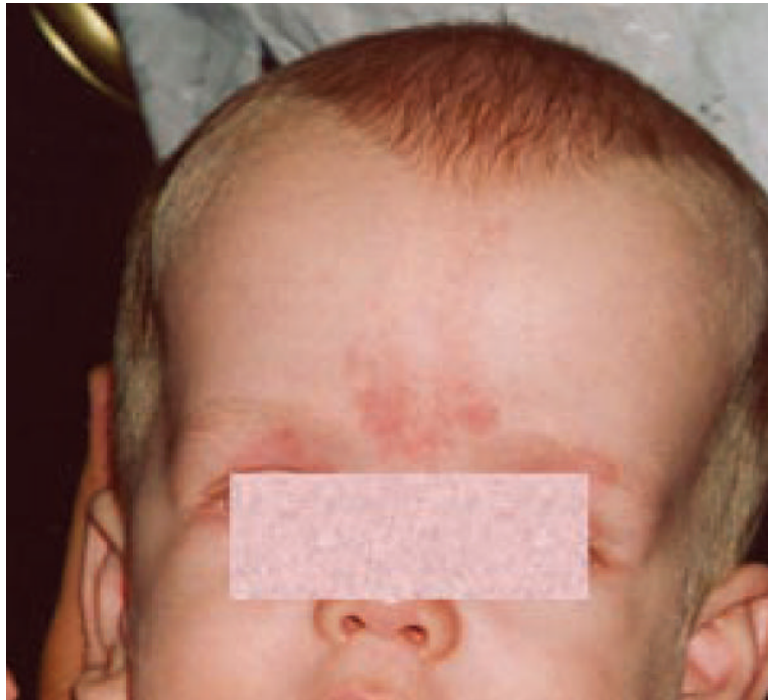

FIG. 34. Forehead, narrow

Note the decreased distance between the two sides of the forehead with narrowing at the temples.

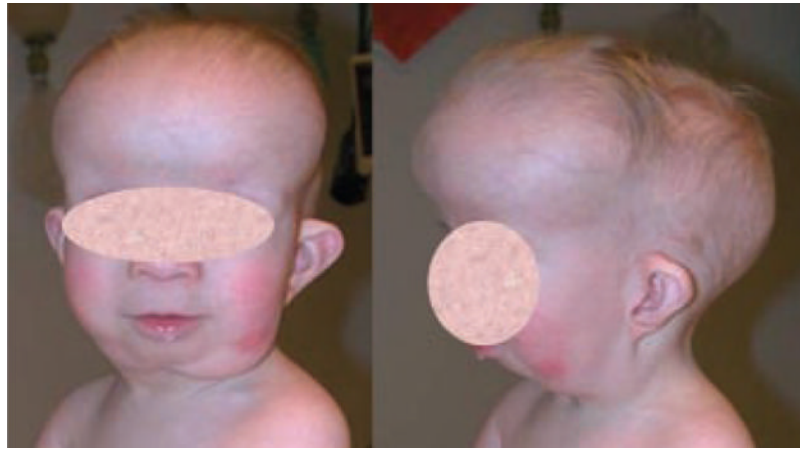


FIG. 35. Forehead, prominent

The entire forehead is prominent due to protrusion of the frontal bone.

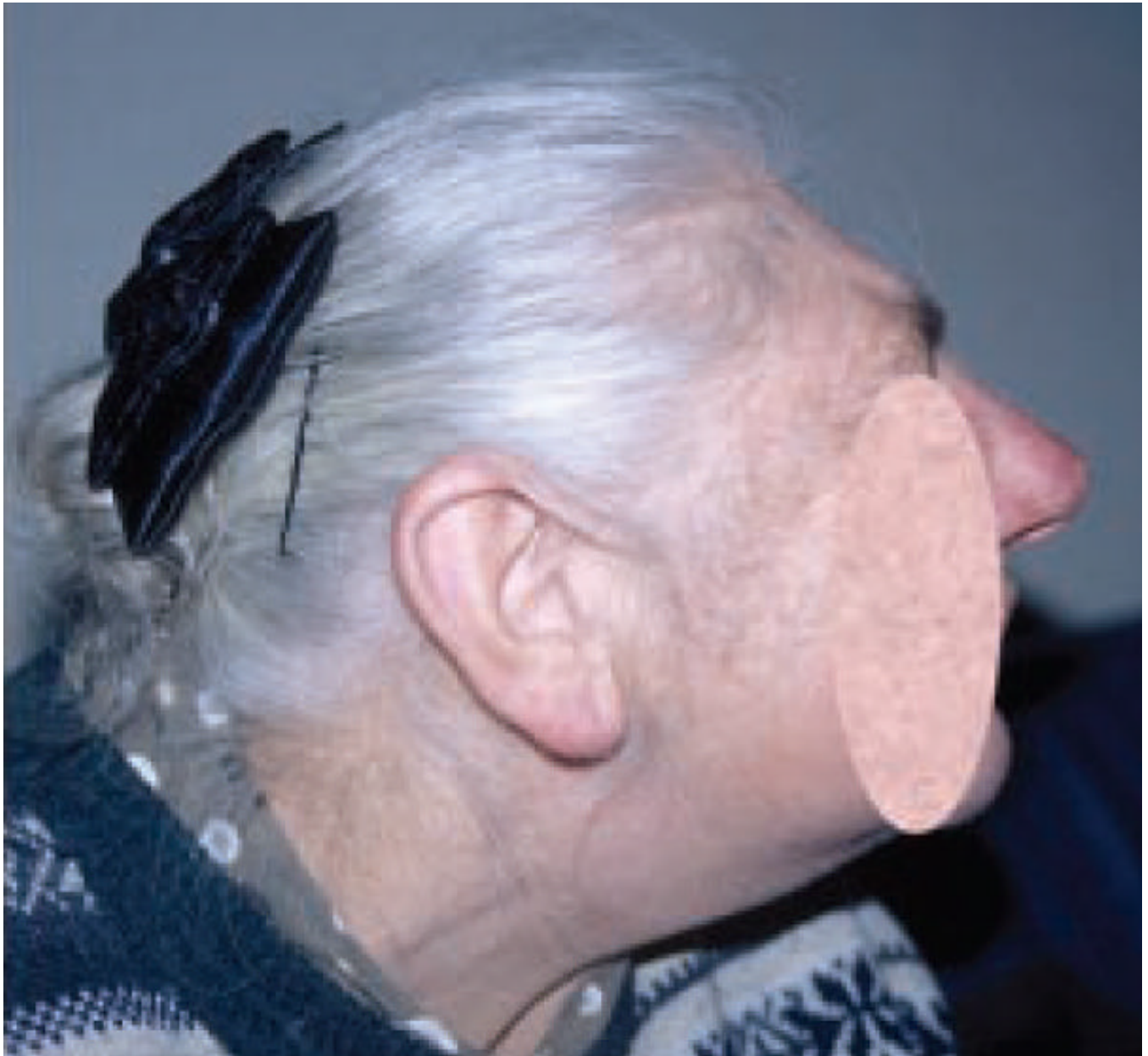

FIG. 36. Forehead, sloping
The anterior surface of the forehead slopes posteriorly in an excessive manner.

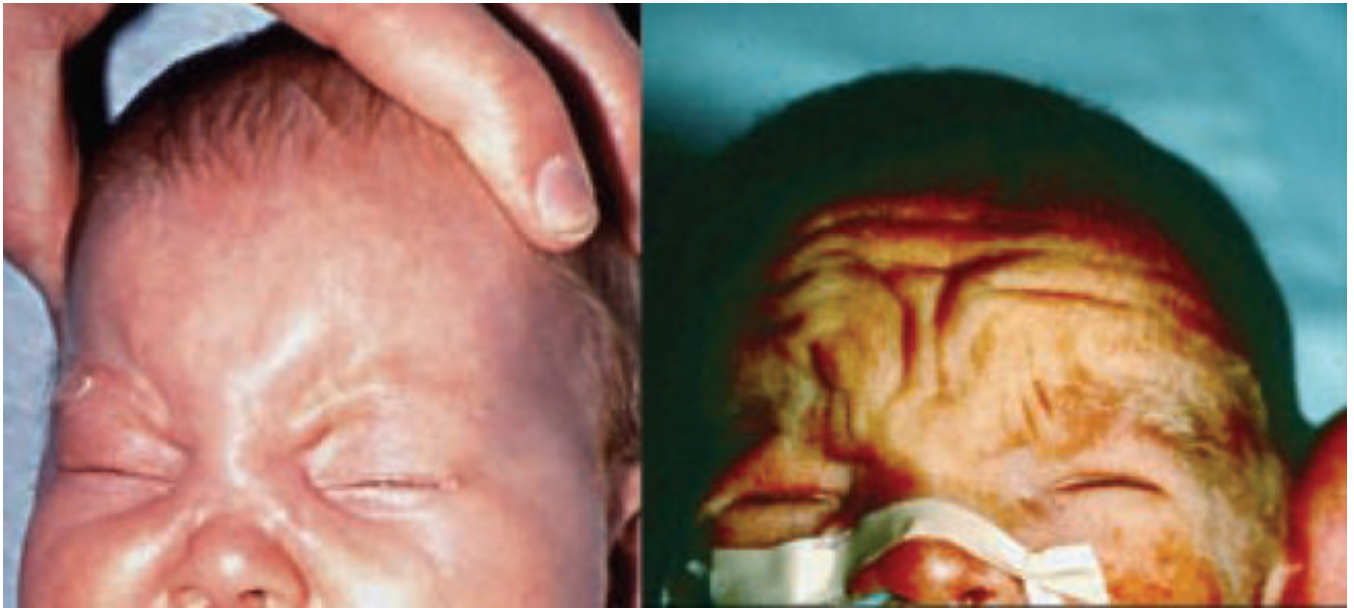

FIG. 37. Forehead creases, vertical

Vertical soft tissue creases are noted in the midline of the forehead. These often extending from the hairline to the brow.

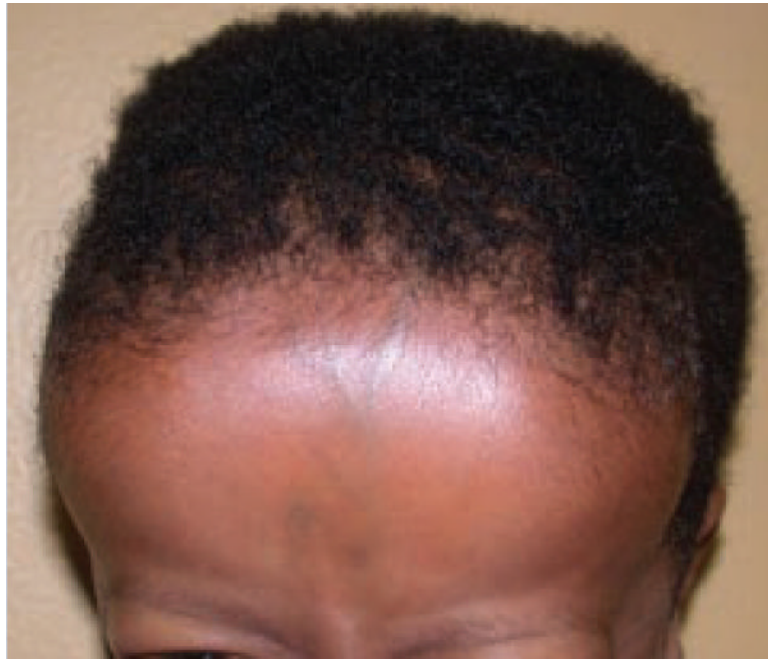

FIG. 38. Frontal bossing
There is bilateral bulging of the lateral aspects of the forehead with relative sparing of the midline.

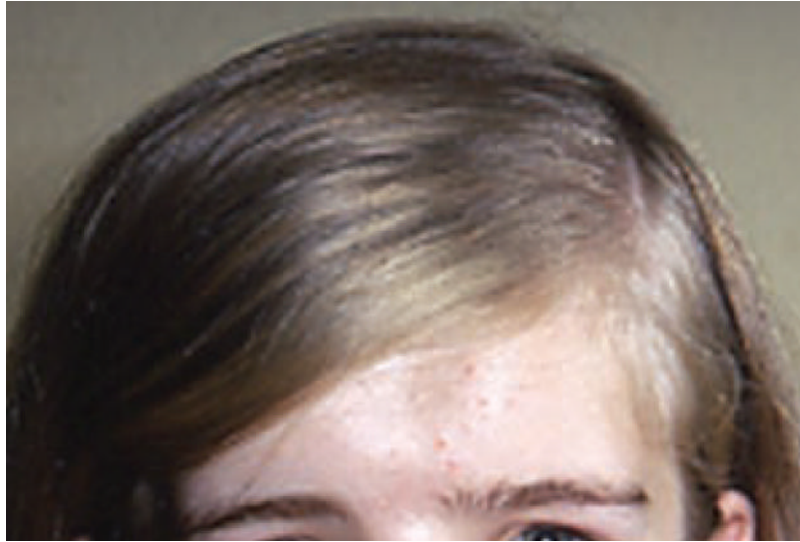

FIG. 39. Glabella, depressed
Note the depression of the midline forehead between the supraorbital ridges.

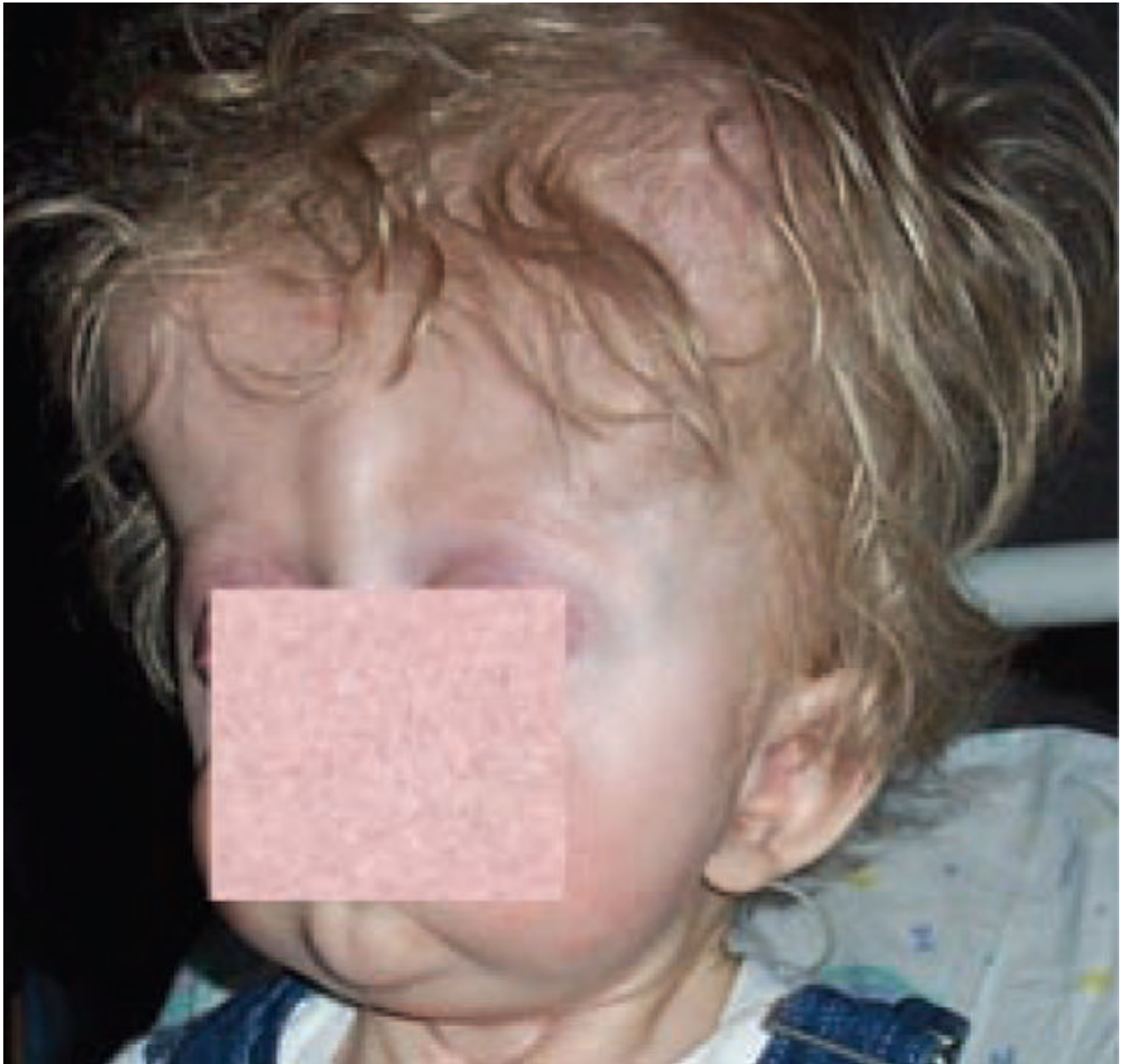

FIG. 40. Glabella, prominent

Note prominence of the glabella, the area of the forehead in the midline between the supraorbital ridges, just above the nasal root.

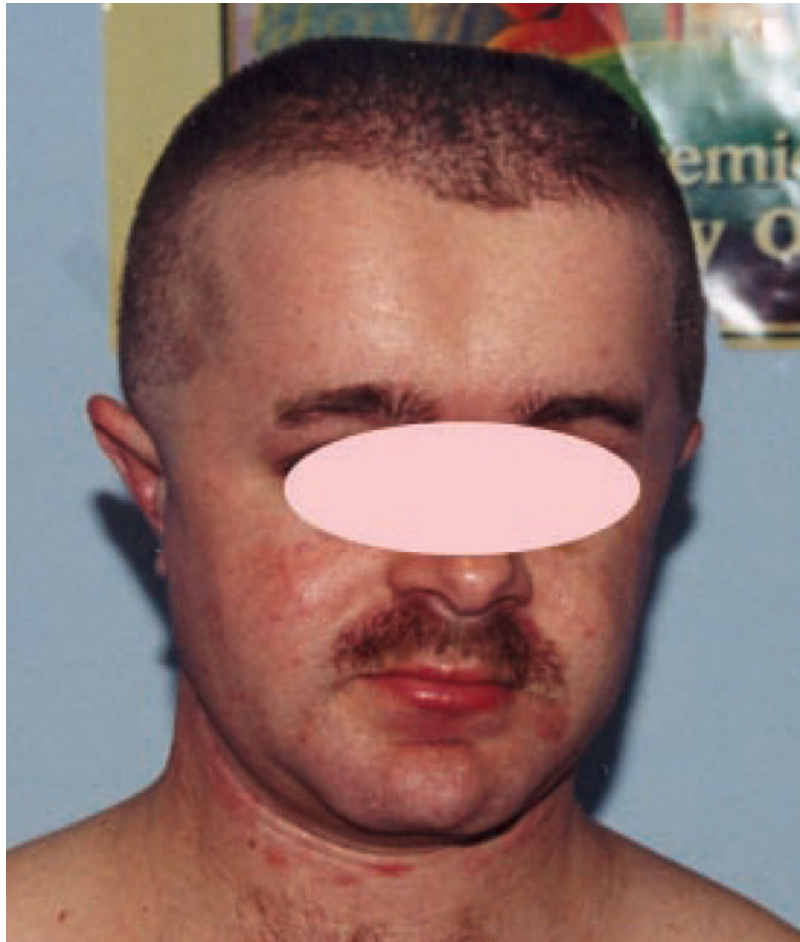

FIG. 41. Metopic depression
There is a linear vertical groove in the midline of the forehead, extending from hairline to glabella.

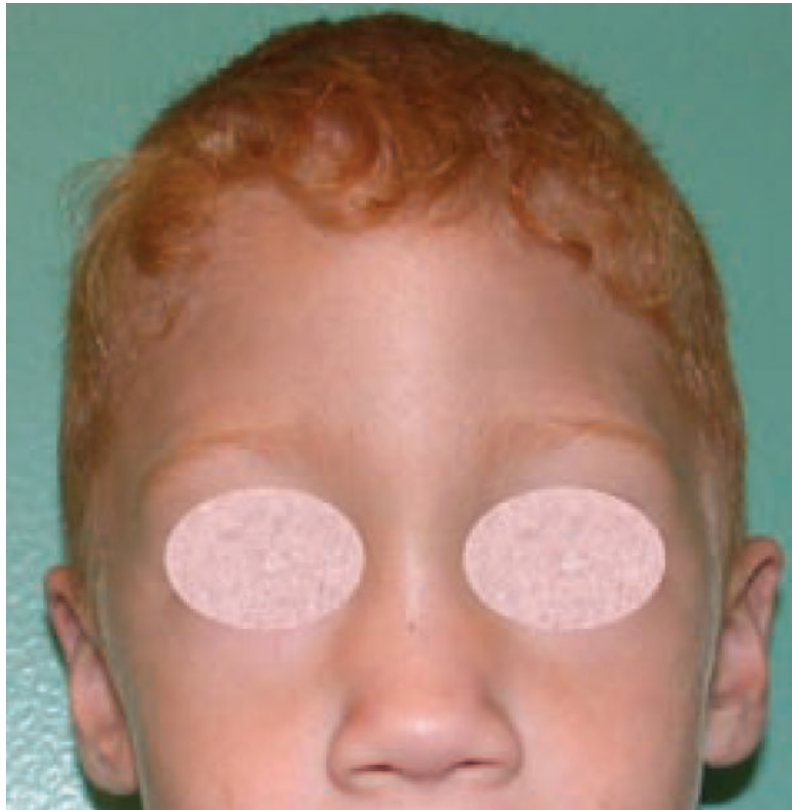

FIG. 42. Metopic ridge, prominent
Note the vertical bony ridge in the midline of the forehead.

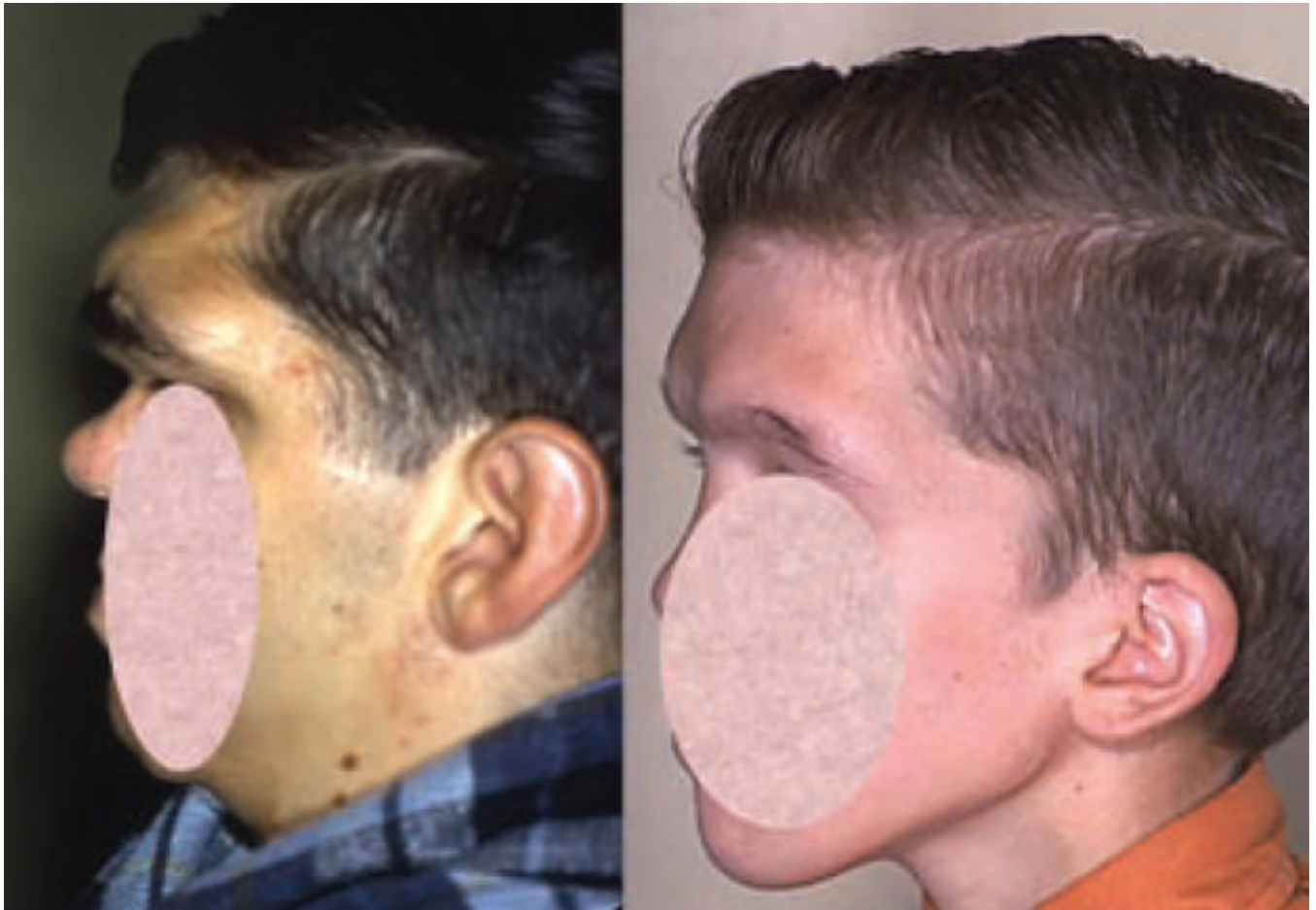

FIG. 43. Supraorbital ridges, prominent
The supraorbital portion of the frontal bones protrudes forward and laterally.

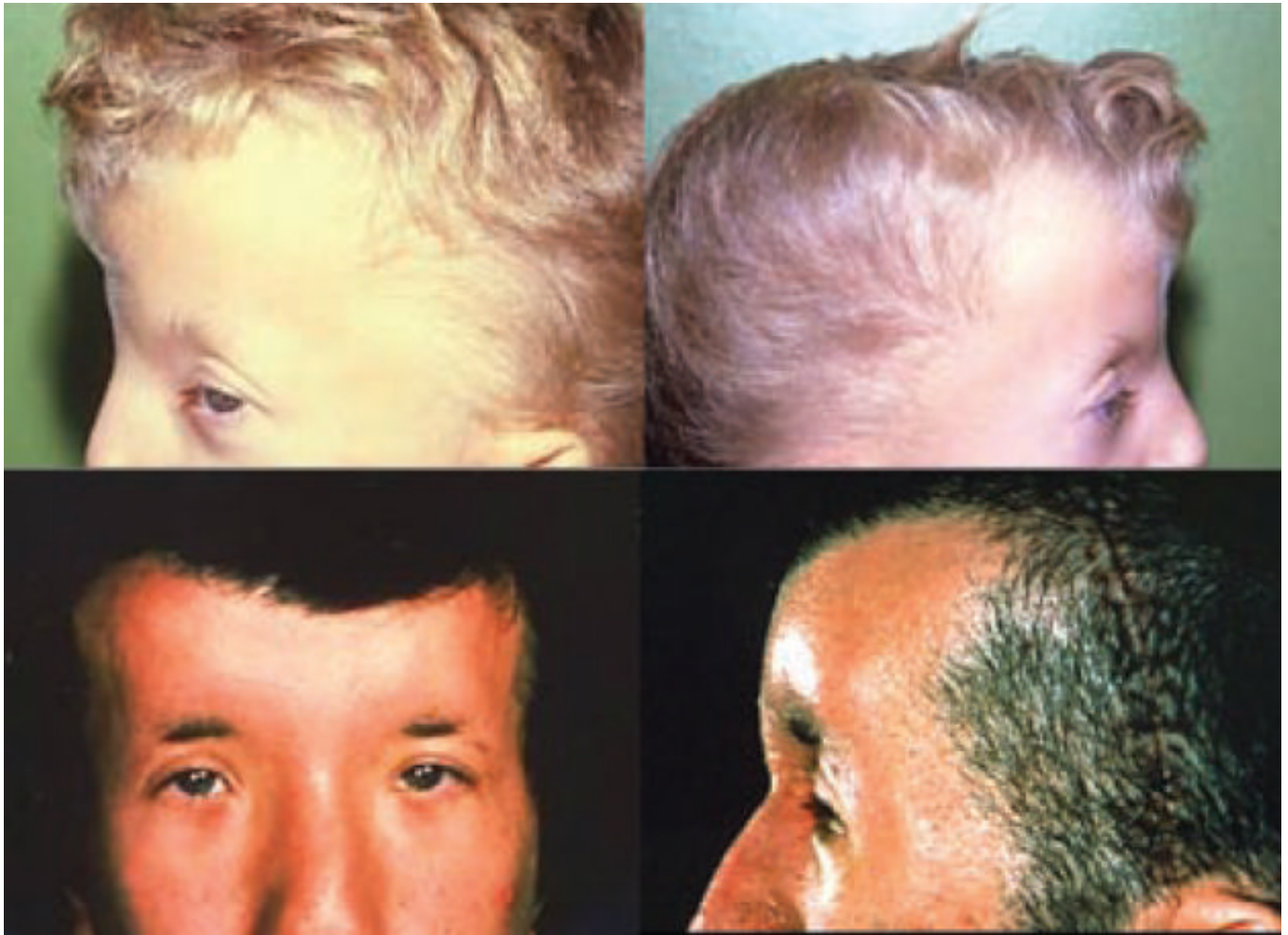

FIG. 44. Supraorbital ridges, underdeveloped
The supraorbital portion of the frontal bones is less prominent than usual.

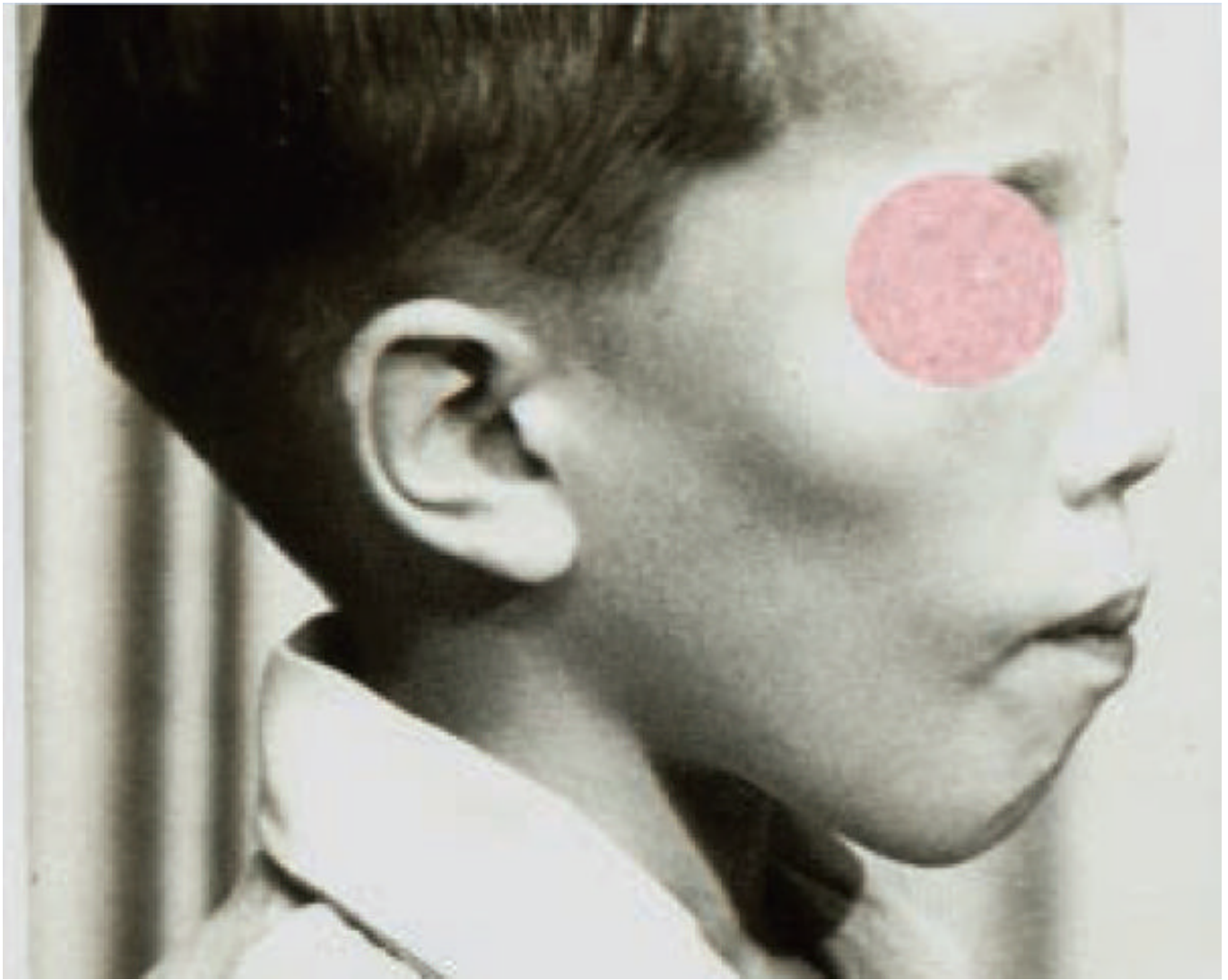


FIG. 45. Cheekbone prominence
The cheekbones overlying the zygoma of the temporal bone of the skull are more prominent than usual.

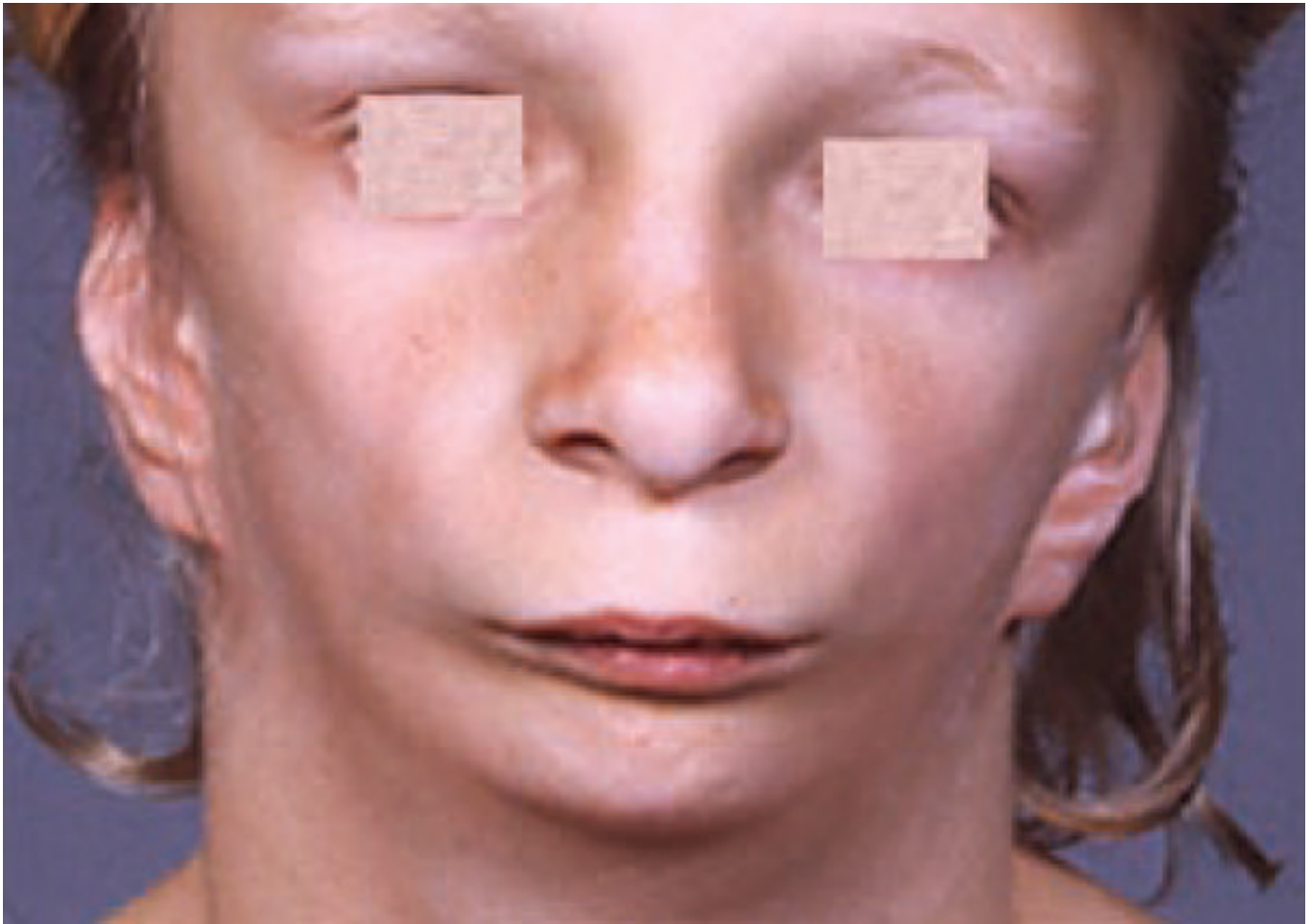

FIG. 46. Cheekbone underdevelopment

The cheekbones overlying the zygoma of the temporal bone of the skull are less prominent than usual.

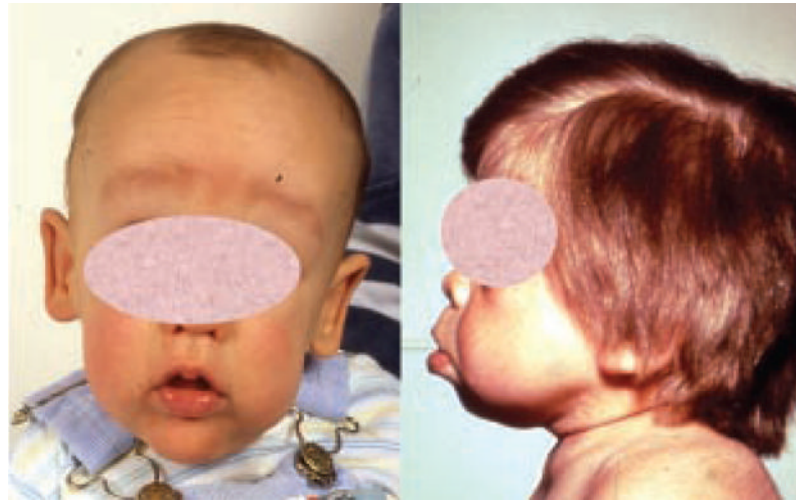

FIG. 47. Cheeks, full

Note the increased prominence or roundness of the soft tissues between the cheekbones and mandible.

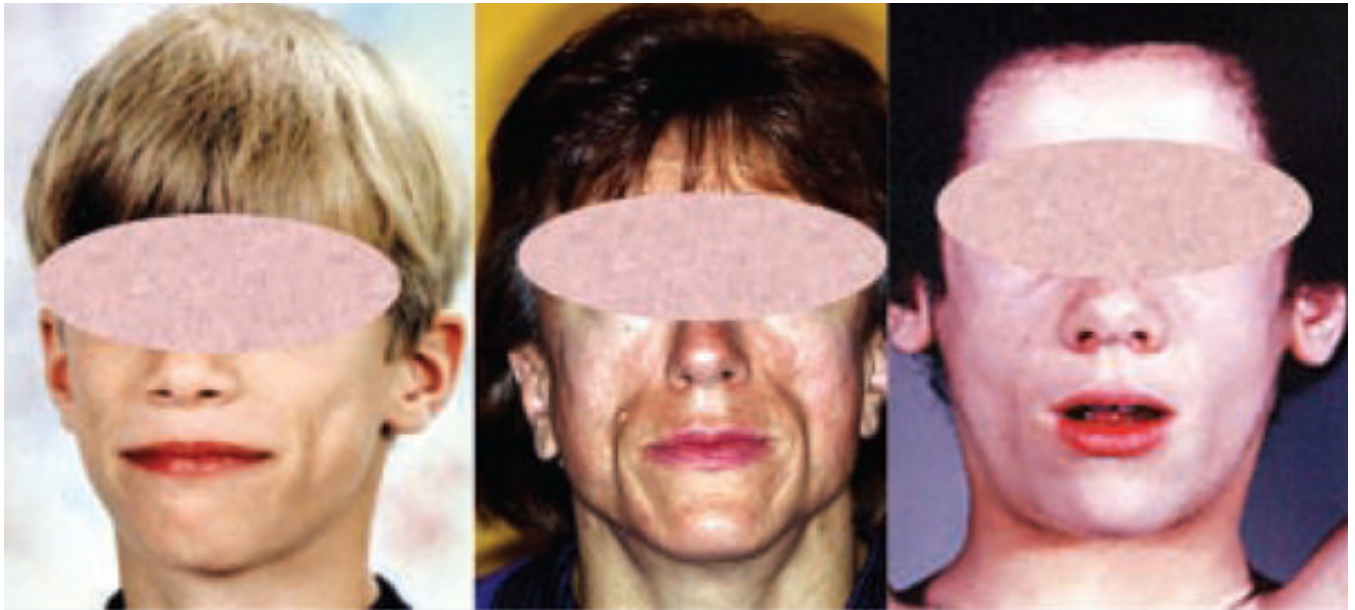

FIG. 48. Cheeks, sunken
Note the reduced prominence or fullness of the soft tissues between the cheekbones and mandible.

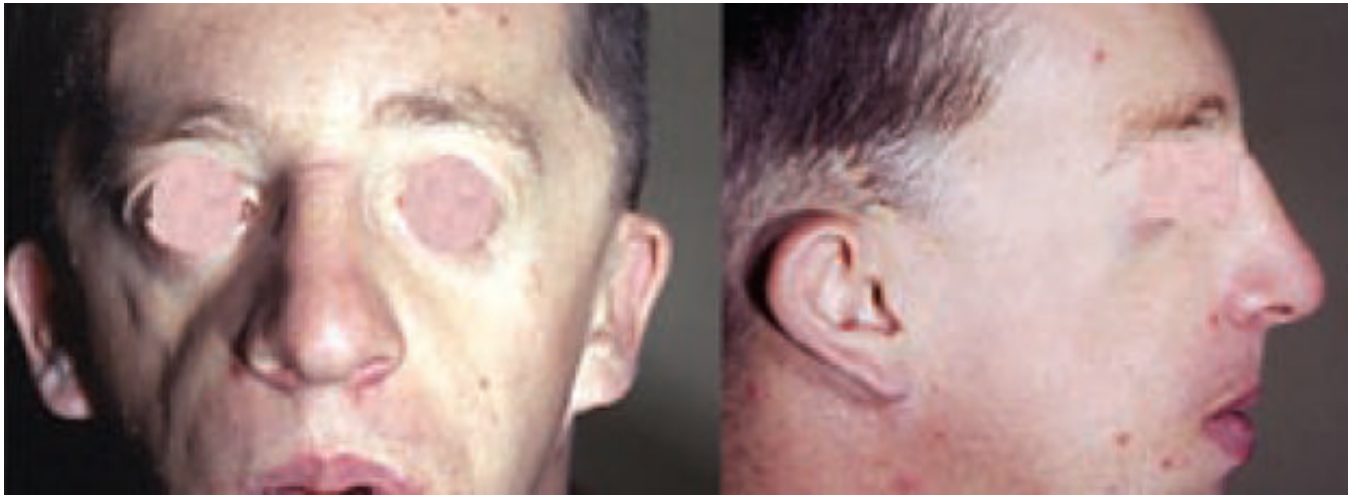

FIG. 49. Malar flattening

Note the underdevelopment of bony tissues lateral to the nasal bridge extending from the inner corner of the eye to the medial aspect of the cheekbone.

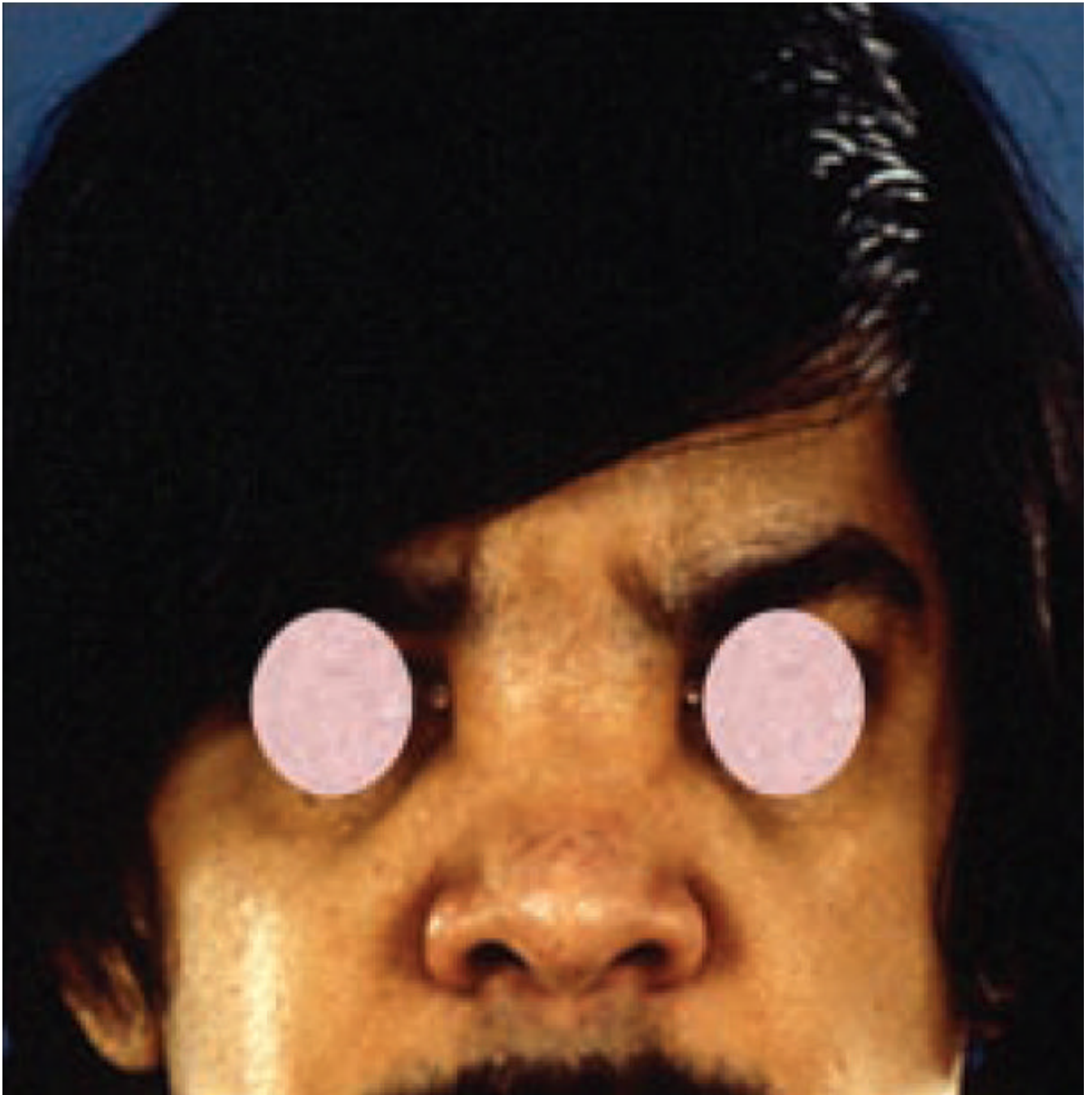


FIG. 50. Malar prominence

Note the prominence of bony tissues lateral to the nasal bridge extending from the inner corner of the eye to the medial aspect of the cheekbone.

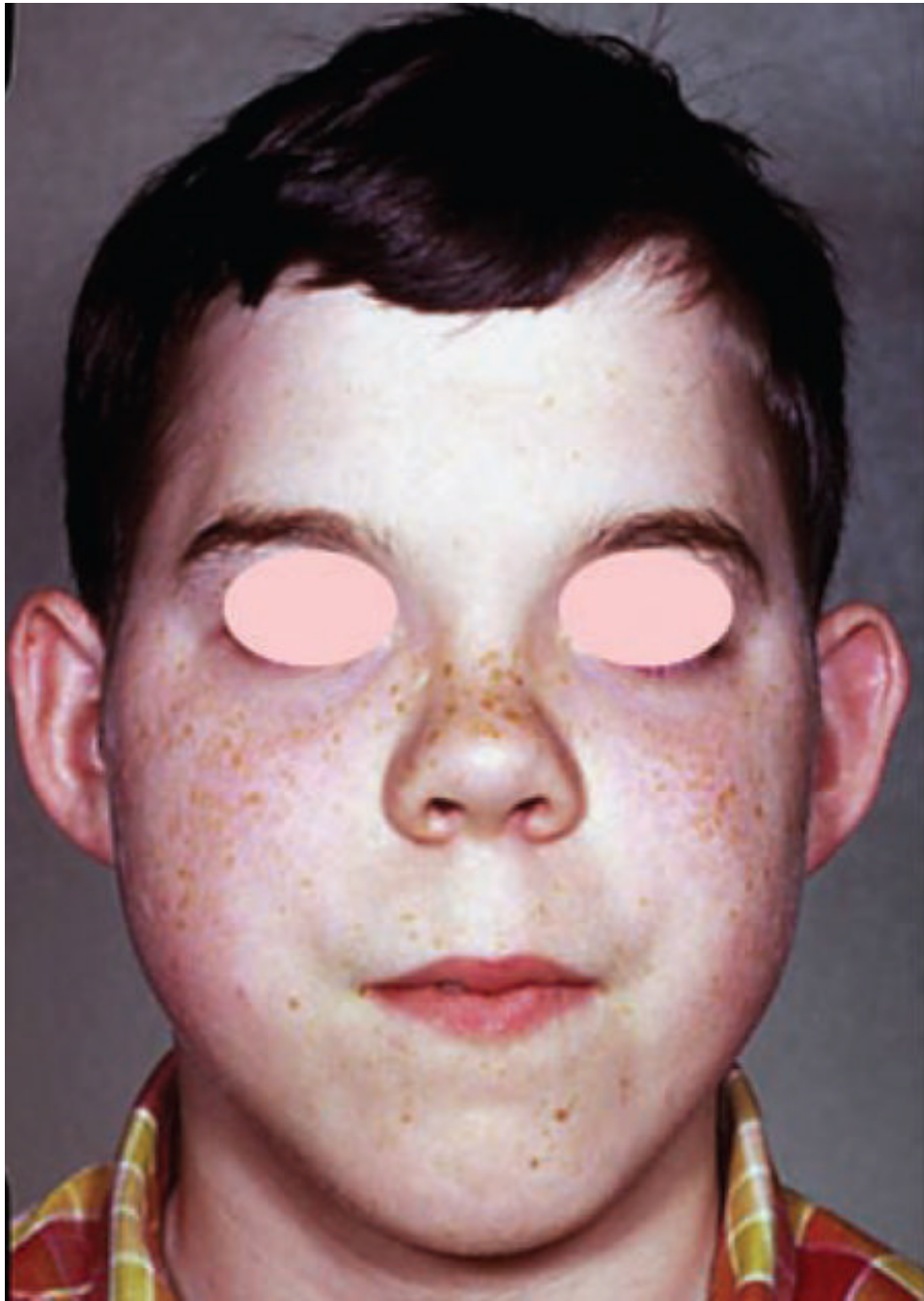

FIG. 51. Midface prominence

Note prominence of the infraorbital and perialar regions leading to more pronounced convexity of the face and increased nasolabial angle.

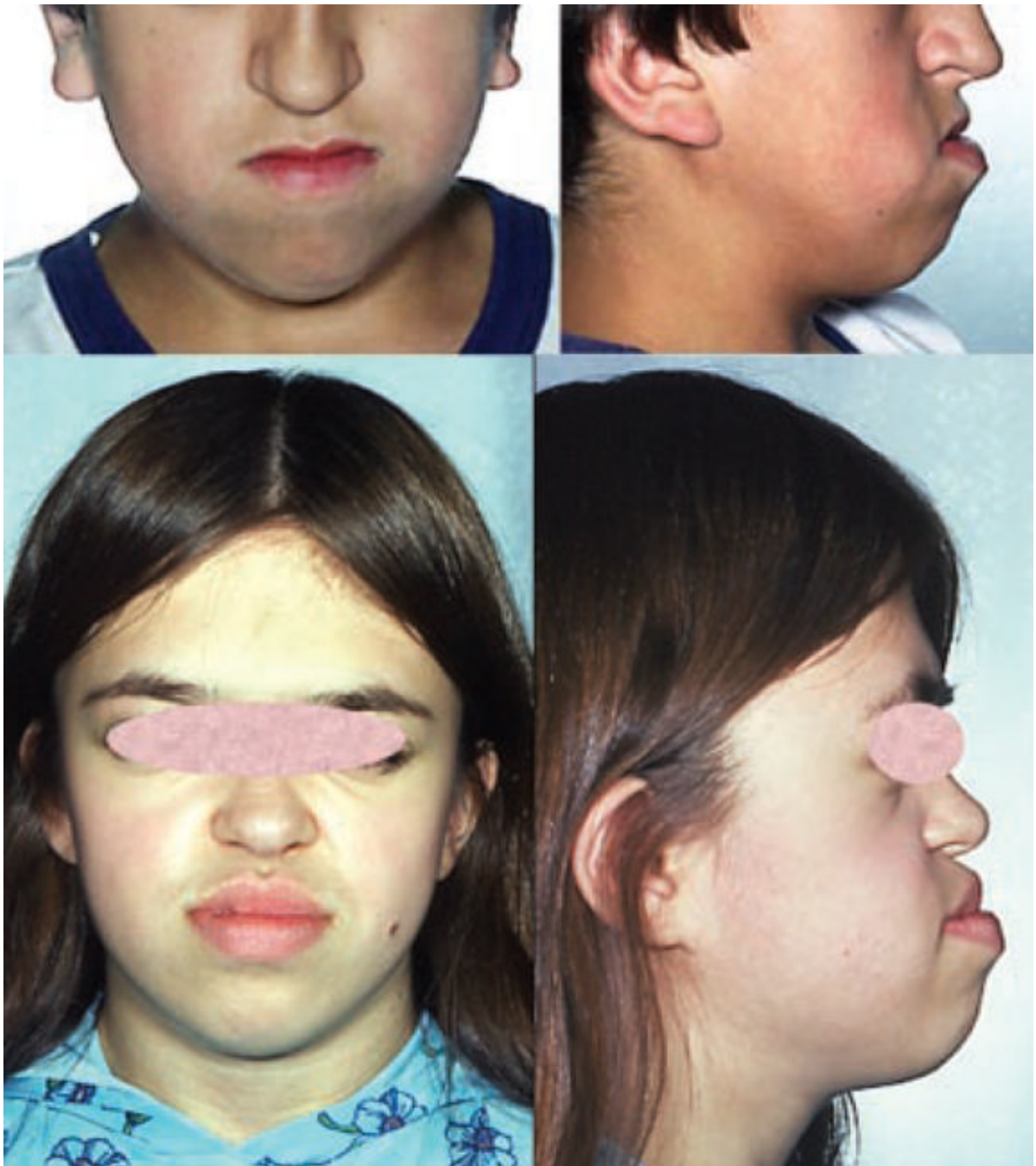

FIG. 52. Midface retrusion

Note underdevelopment of the infra-orbital and peri-alar regions leading to more pronounced concavity of the face and reduced nasolabial angle. This gives the appearance of prognathia.

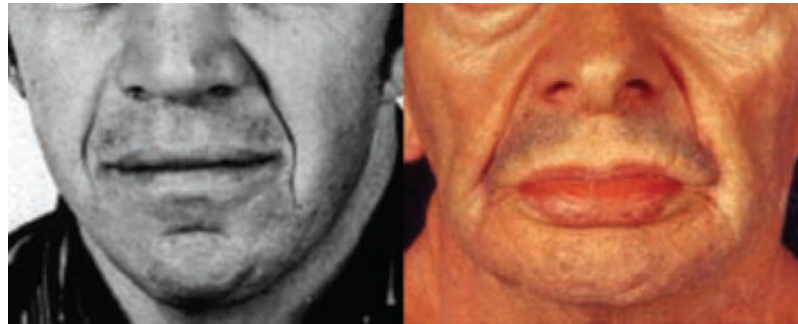

FIG. 53. Nasolabial fold, prominent

The crease or fold of skin running from the lateral margin of the nose, where nasal base meets the skin of the face, to a point just lateral to the corner of the mouth is more prominent than usual.

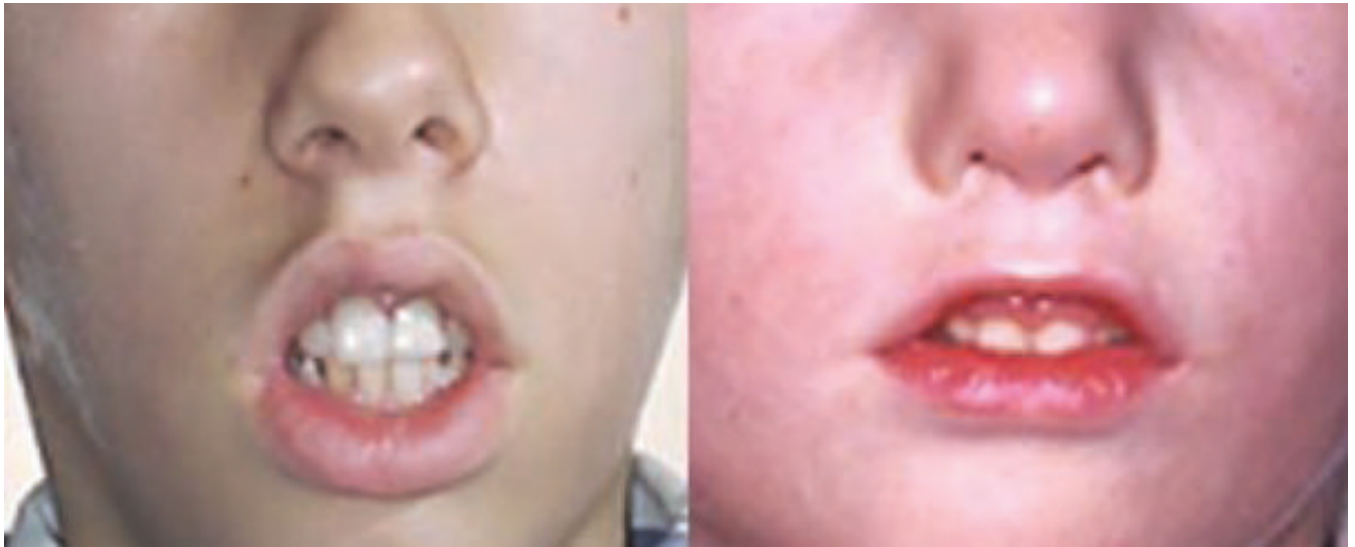

FIG. 54. Nasolabial fold, underdeveloped

The crease or fold of skin running from the lateral margin of the nose, where nasal base meets the skin of the face, to a point just lateral to the corner of the mouth is less prominent than usual.

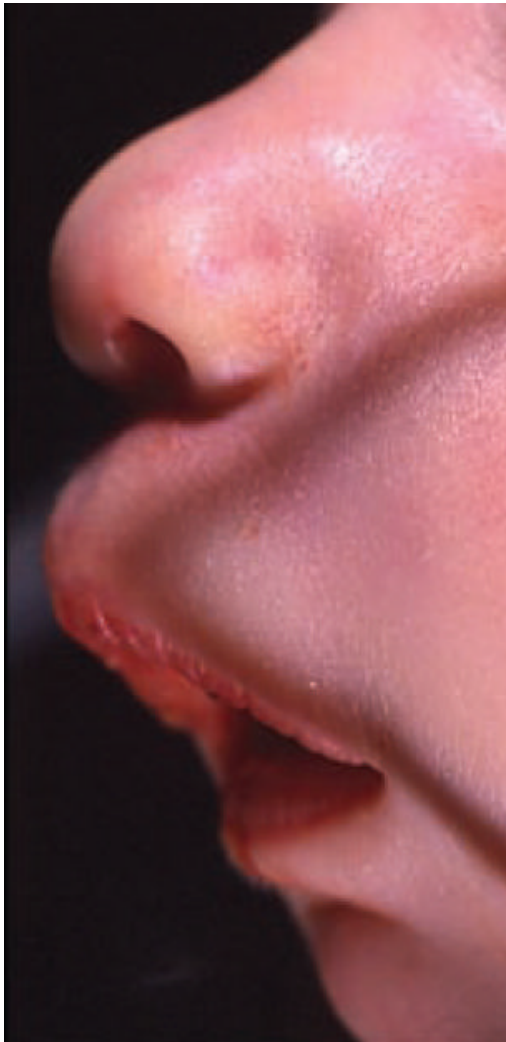

FIG. 55. Premaxillary prominence

Note increased convexity of the face and an increased nasolabial angle giving the impression of retrognathia.

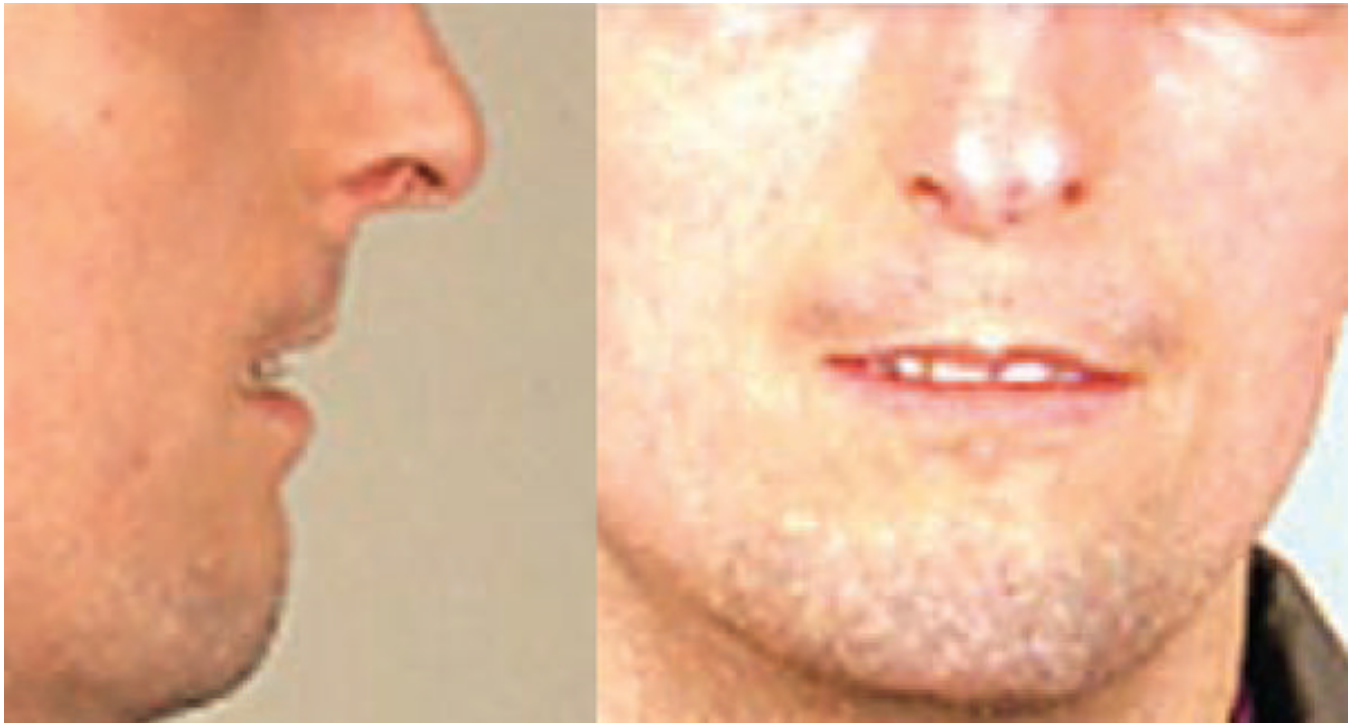

FIG. 56. Premaxillary underdevelopment
Note decreased convexity of the face and nasolabial angle giving the impression of prognathia.

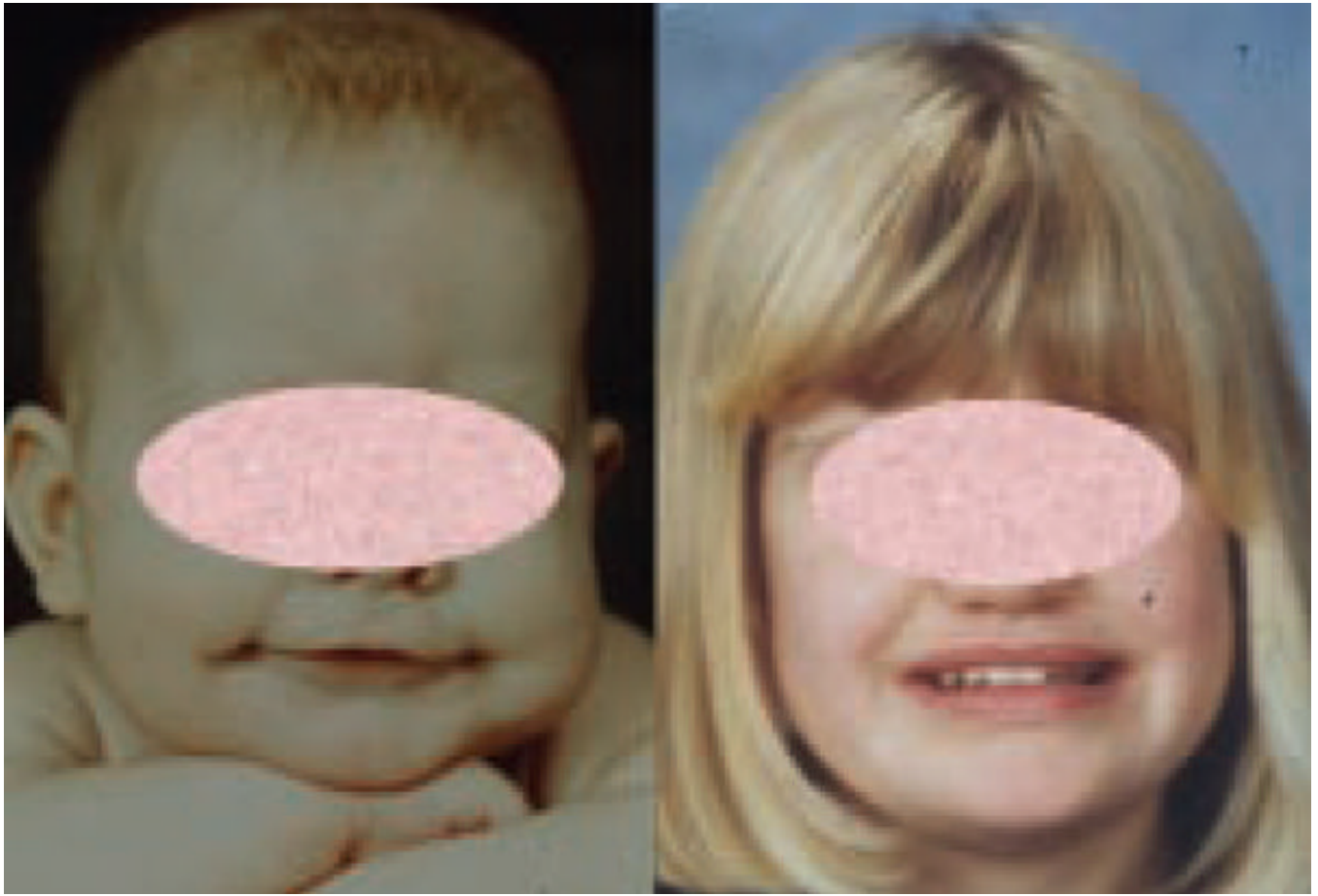

FIG. 57. Jaw, broad
Note increased width of the lower jaw (mandible).

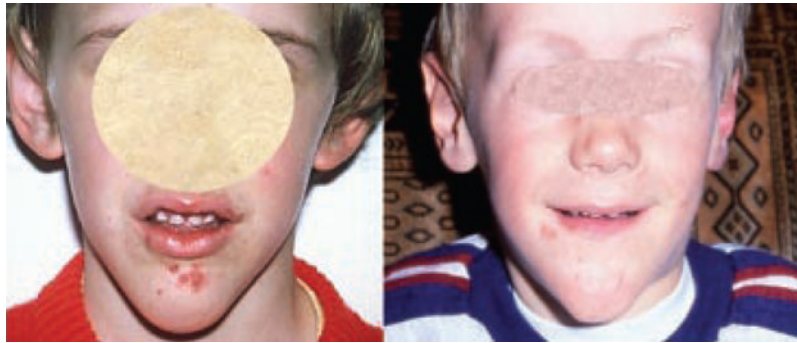

FIG. 58. Jaw, narrow
Note decreased width of the lower jaw (mandible).

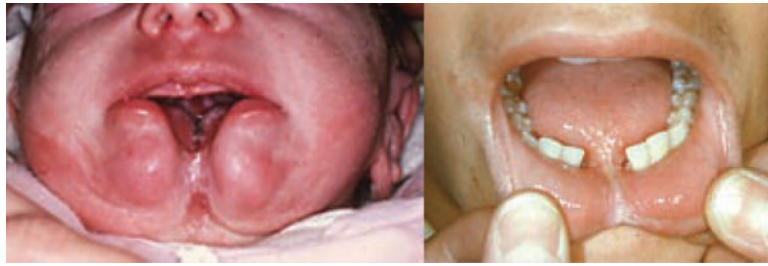

FIG. 59. Mandible, cleft
There is a complete midline deficiency of the mandible on the left and deficiency of overlying tissues on the right.

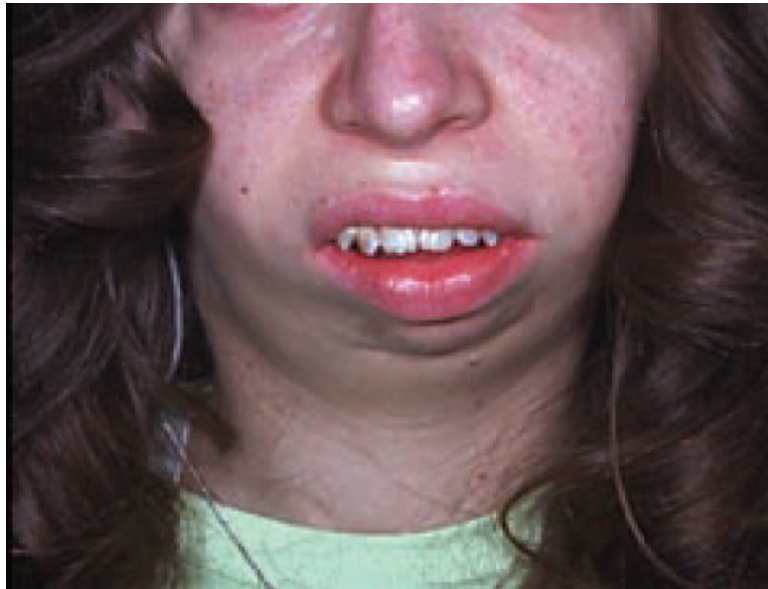

FIG. 60.
Micrognathia. There is shortening and narrowing of the mandible and chin.

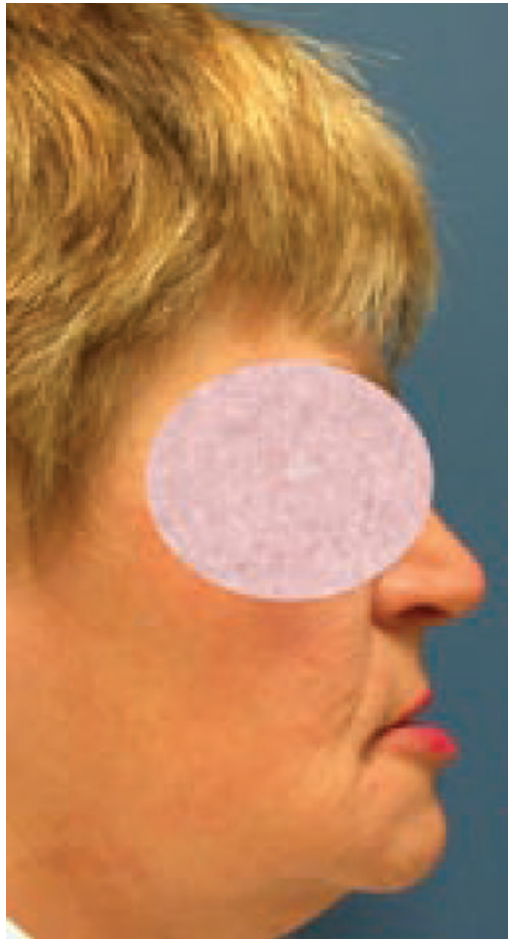

FIG. 61.
Prognathism. There is anterior protrusion of the mandible such that the alveolar ridge extends beyond the vertical plane of the maxillary alveolar ridge.

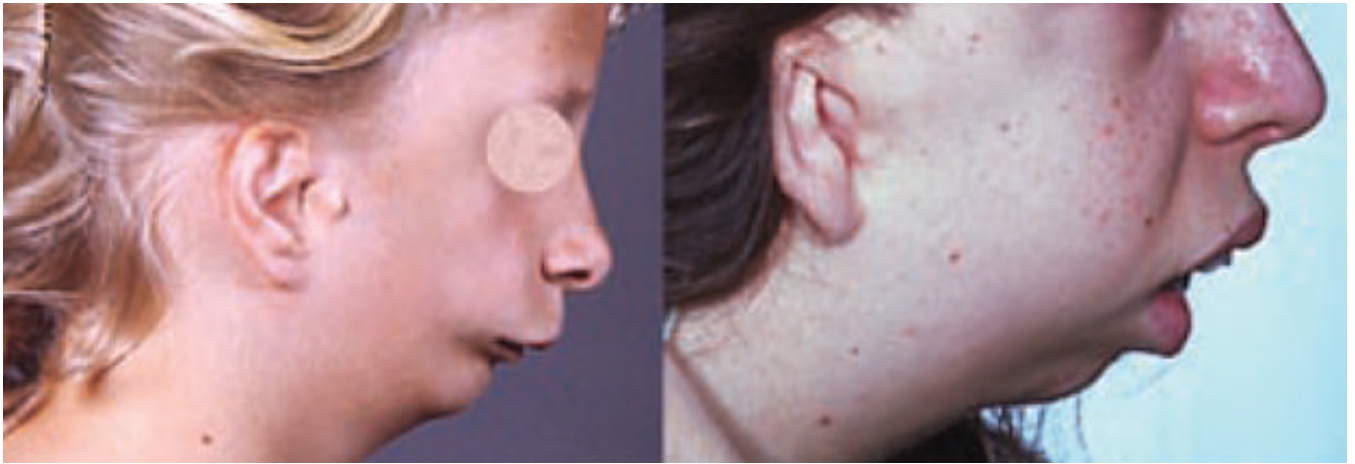

FIG. 62.
Retrognathia. The lower jaw is set back from the plane of the face.

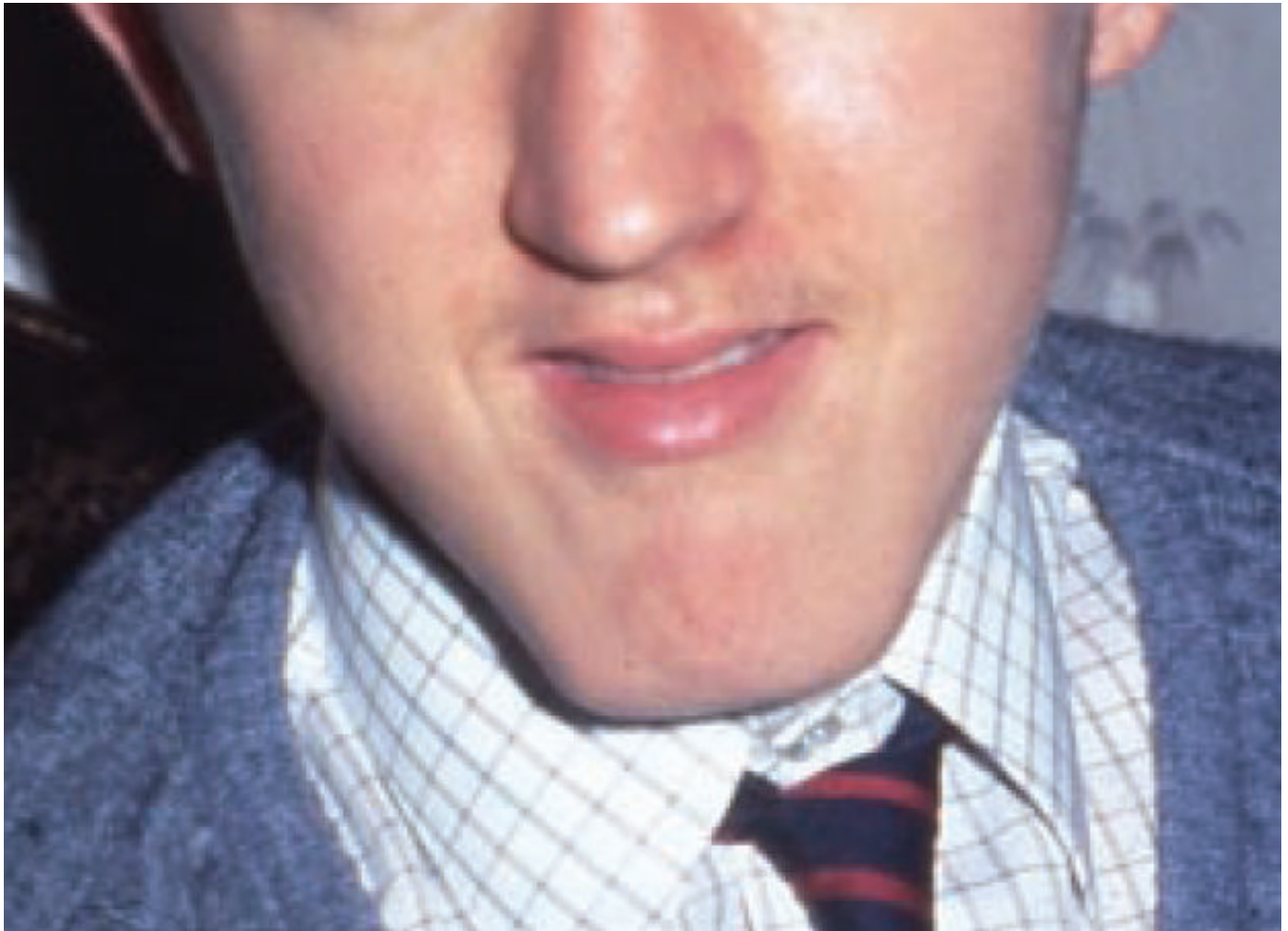

FIG. 63. Chin, broad

The midpoint of the mandible (mental protuberance) and overlying soft tissue is broader than usual.

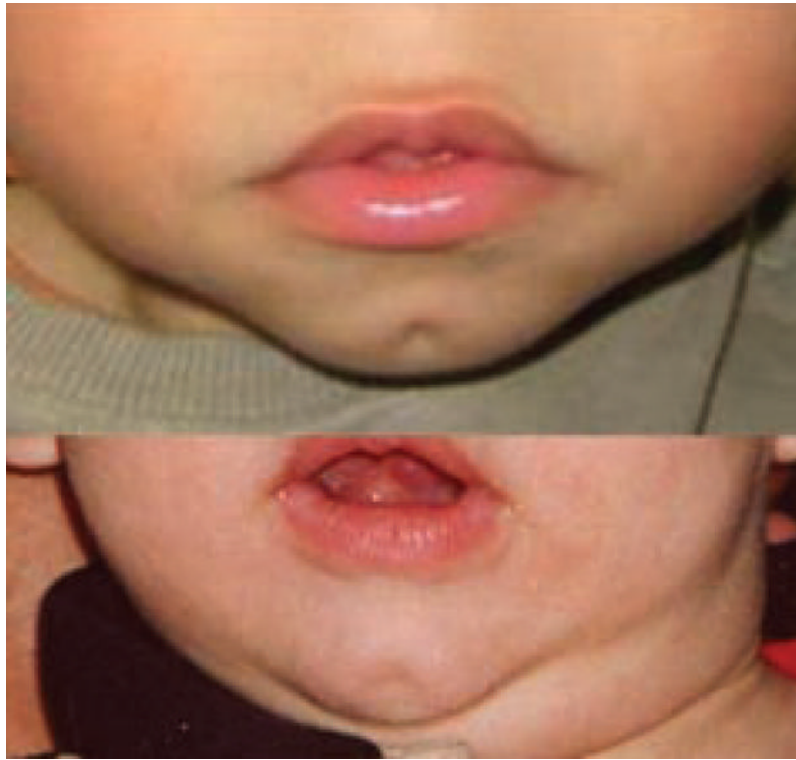

FIG. 64. Chin dimple

Note the midline depression of the skin over the fat pad of the chin.

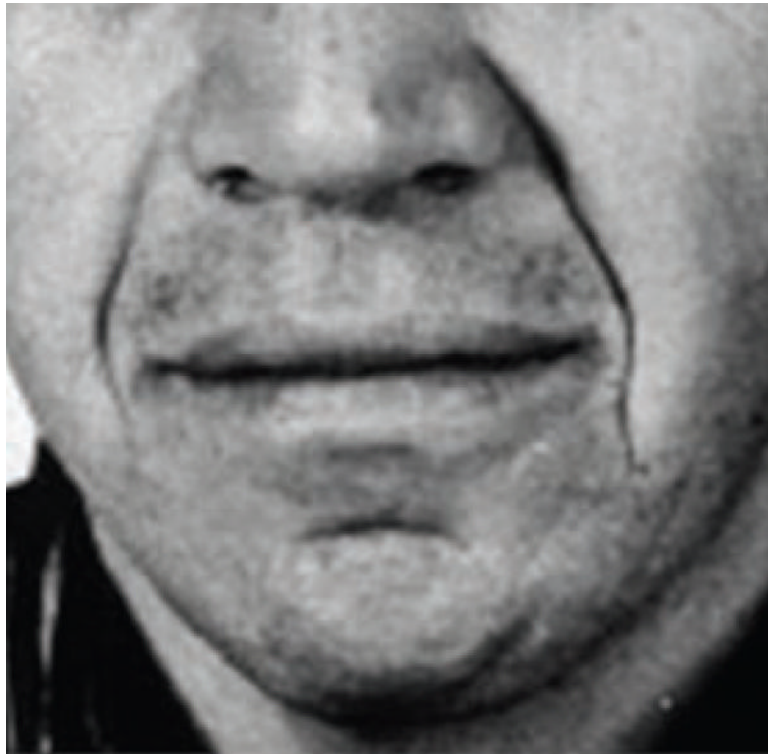

FIG. 65. Chin, horizontal crease

Note the horizontal crease or fold situated below the vermilion border of the lower lip and above the fatty pad of the chin.

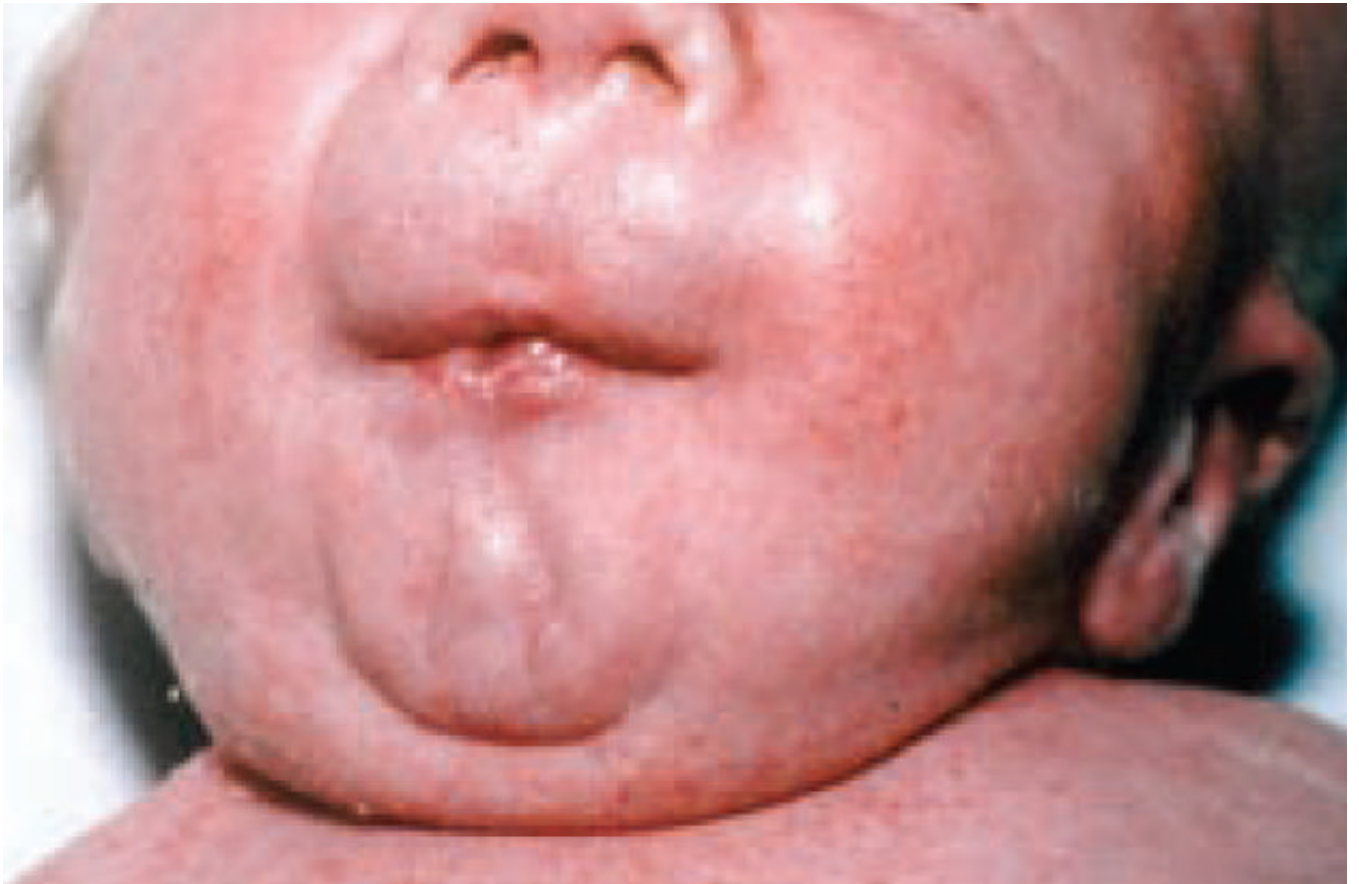

FIG. 66. Chin, H-shaped crease
Note the H-shaped crease in the fat pad of the chin.

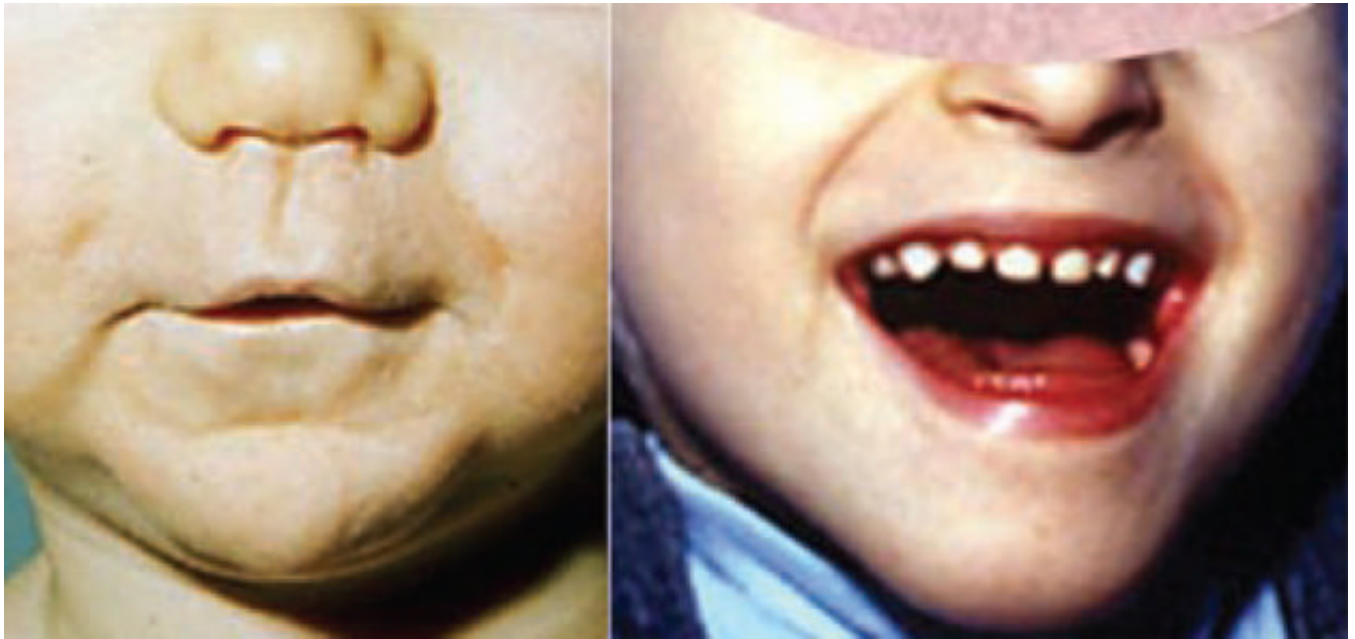

FIG. 67. Chin, pointed

Note the marked tapering of the lower face to the chin with the two sides of the mandible meeting at an acute angle.

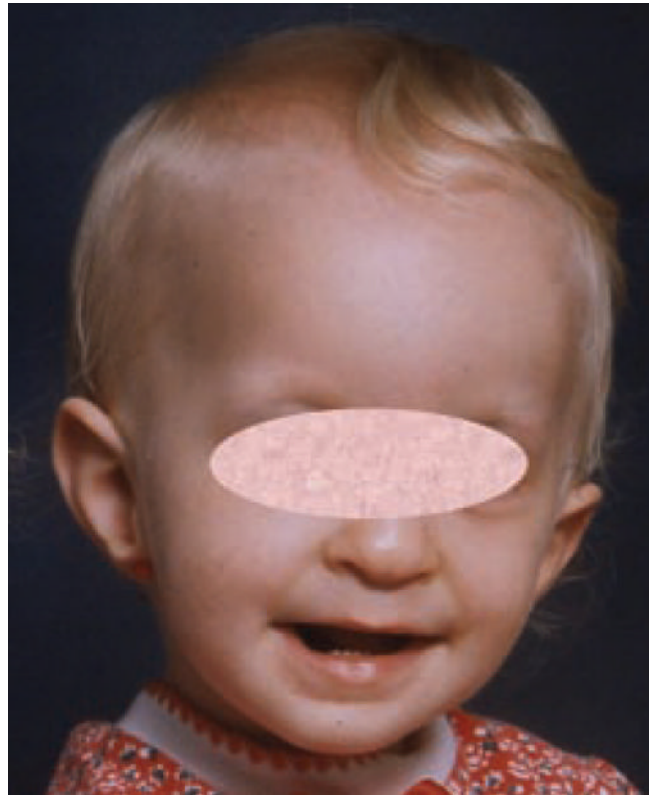

FIG. 68. Chin, short

Note the reduced vertical distance from the vermilion border of the lower lip to the inferior-most point of the chin.

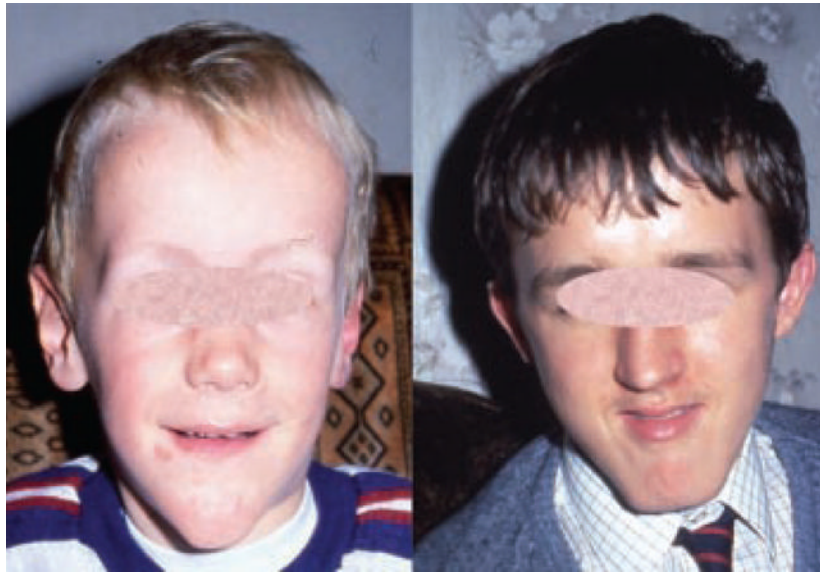

FIG. 69. Chin, tall

Note the increased vertical distance from the vermillion border of the lower lip to the inferior-most point of the chin.

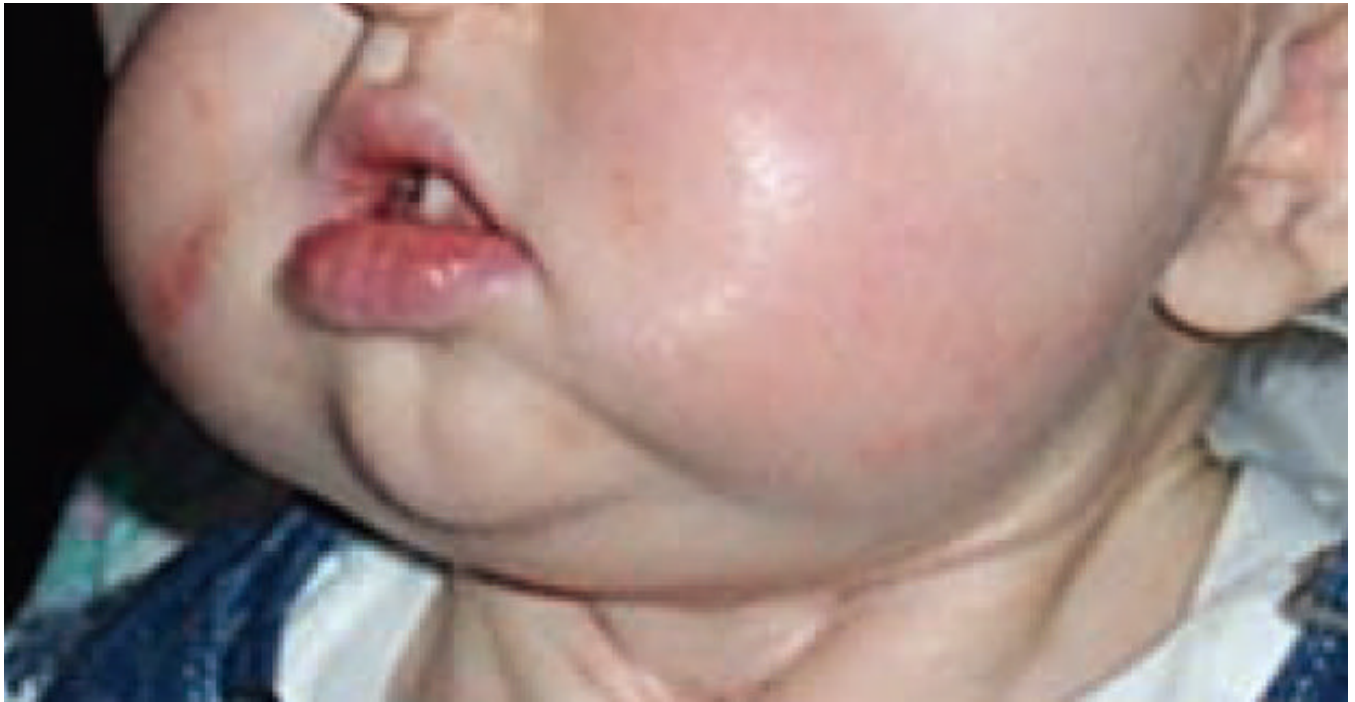

FIG. 70. Chin, vertical crease
Note the vertical crease in the fat pad of the chin.

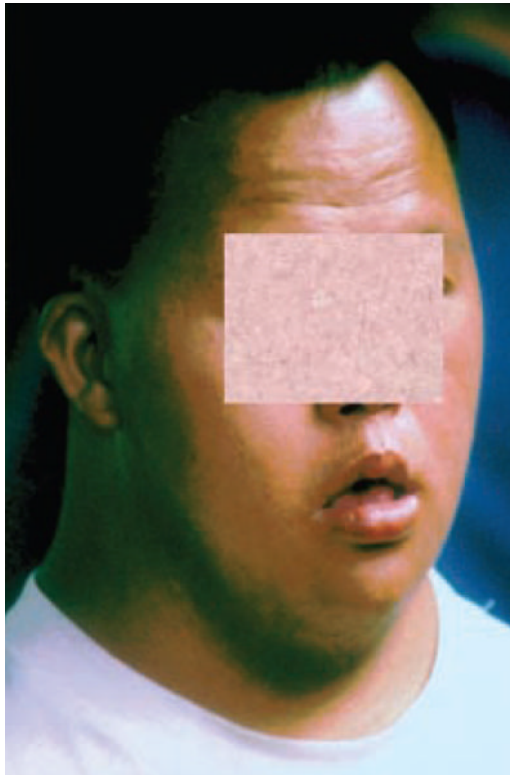

FIG. 71. Neck, broad
Note the increased width of the neck.

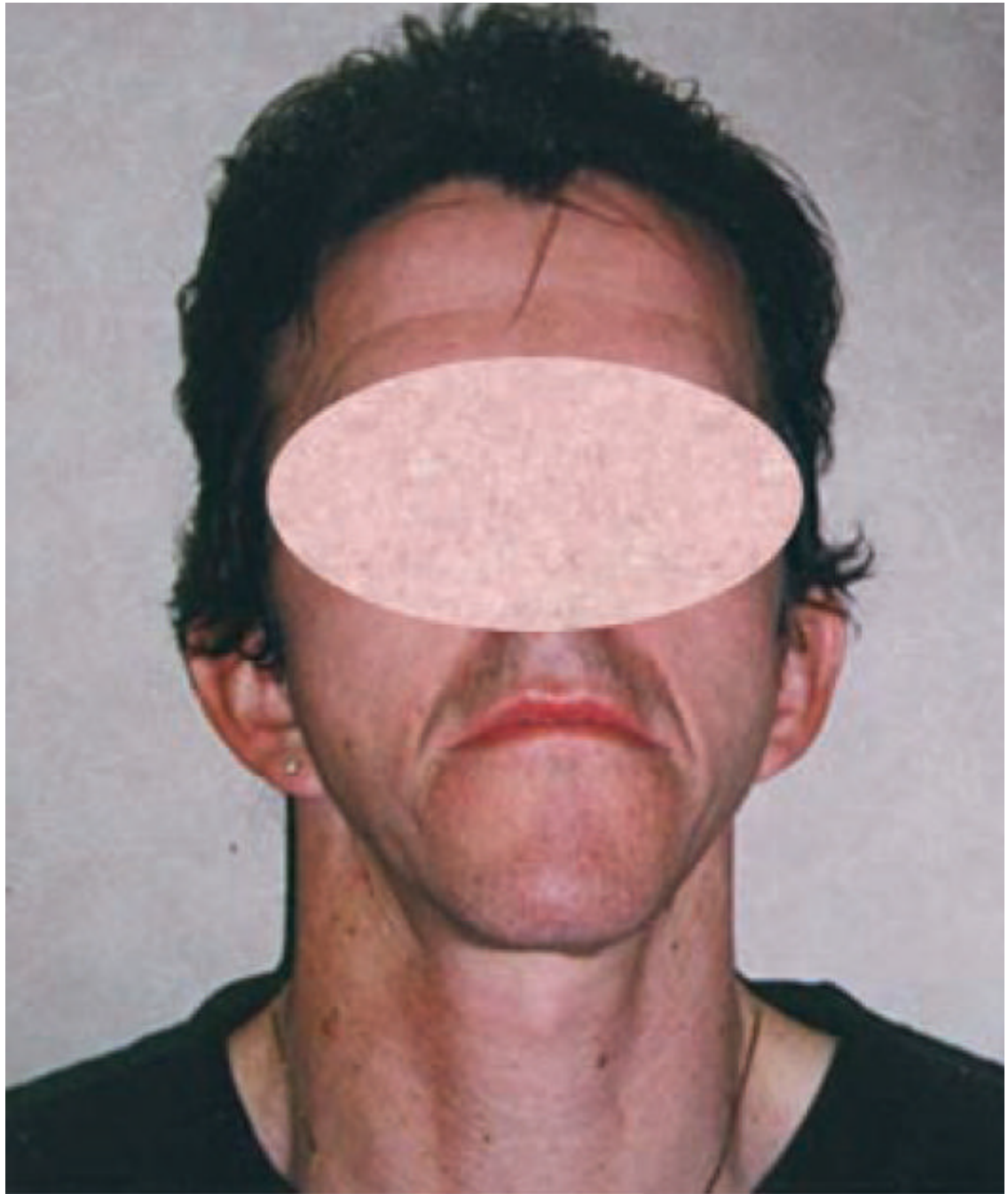


FIG. 72. Neck, long

Note the increased distance from the point where neck and shoulders meet to the inferior margin of the occipital bone.

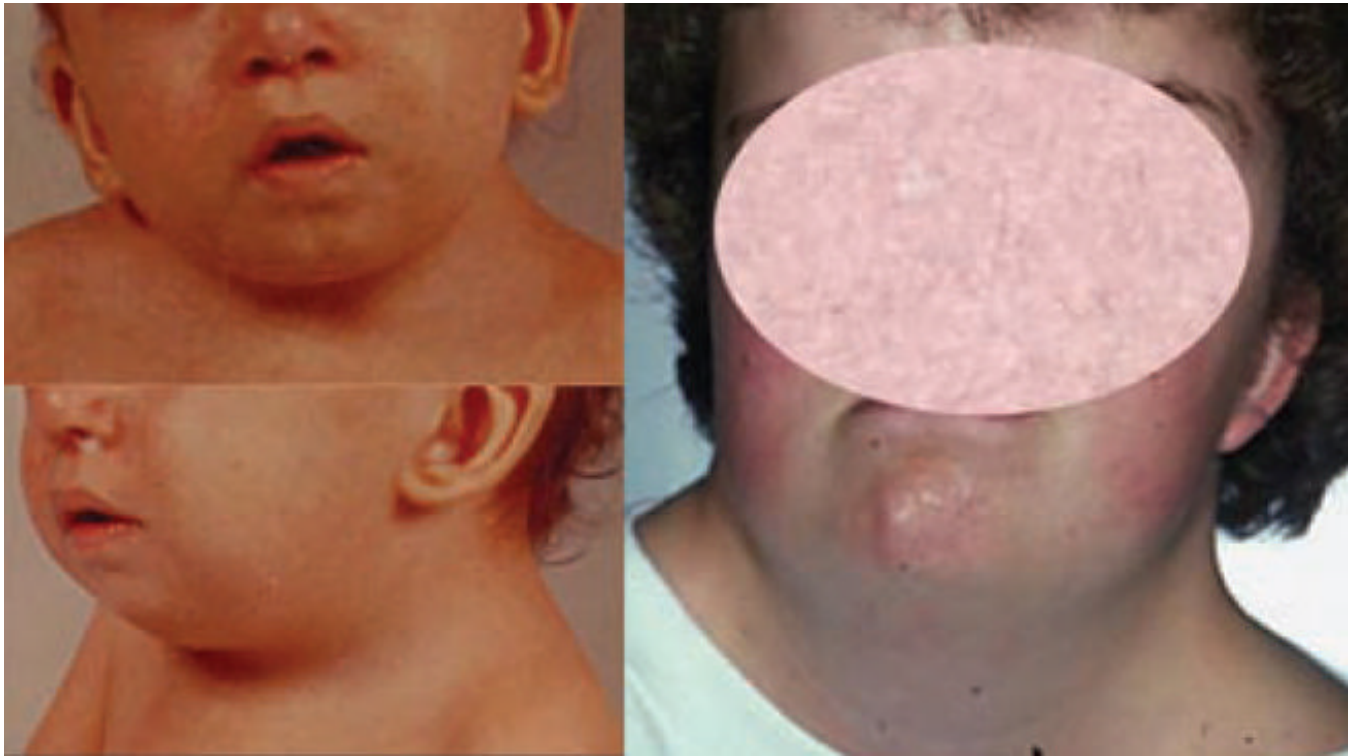

FIG. 73. Neck, short

Note the decreased distance from the point where neck and shoulders meet to the inferior margin of the occipital bone.

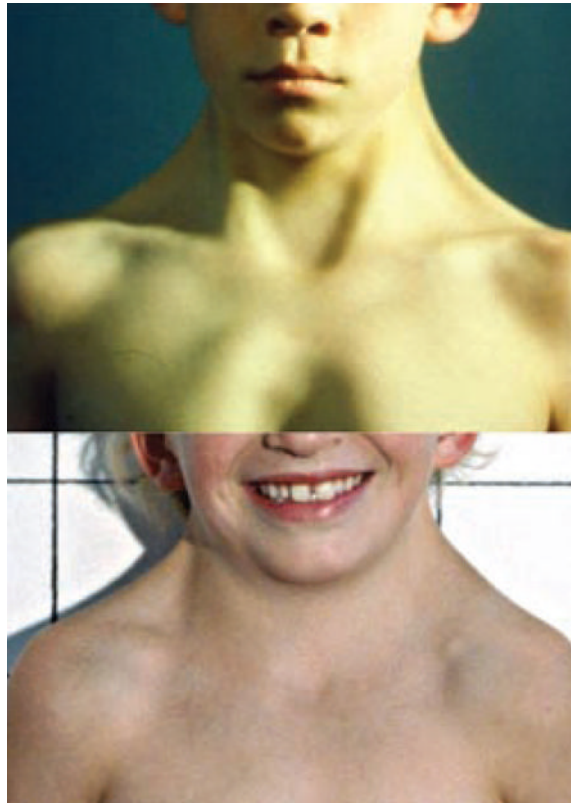


FIG. 74. Neck webbing
Note the bilateral folds of skin on the posterolateral aspect of the neck.

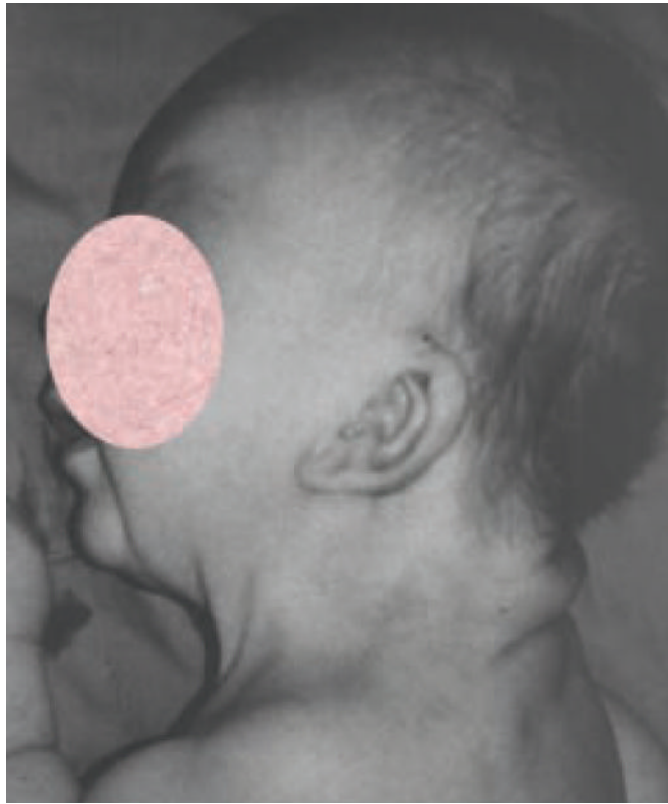

FIG. 75. Nuchal skin, redundant
Note the excess skin around the neck.