

Correspondence: Mineo Kurokawa, Department of Hematology and Oncology, Graduate School of Medicine, University of Tokyo, 7-3-1, Hongo, Bunkyo-ku, Tokyo 1138655, Japan. Phone: international +81.3.5800.9092. Fax: international +81.3.5840-8667. E-mail: kurokawa-tky@umin.ac.jp

Citation: Nagai S, Nannya Y, Arai S, Yoshiki Y, Takahashi T, and Kurokawa M. Molecular or cytogenetic monitoring and pre-emptive therapy for central nervous system relapse of acute promyelocytic leukemia. *Haematologica*. 2010; 95:169-171. doi: 10.3324/haematol.2009.015545

## References

- Montesinos P, Diaz-Mediavilla J, Deben G, Prates V, Tormo M, Rubio V, et al. Central nervous system involvement at first relapse in patients with acute promyelocytic leukemia treated with all-trans retinoic acid and anthracycline monochemotherapy without intrathecal orophylaxis. *Haematologica*. 2009;94(9):1242-9.
- Nagai S, Takahashi T, Kurokawa M. Beneficial and adverse effects of molecularly targeted therapies for acute promyelocytic leukemia in central nervous system. *CNS Neurol Disord Drug Targets*. 2009 [Epub ahead of print].
- Gleissner B, Siehl J, Korfel A, Reinhardt R, Thiel E. CSF evaluation in primary CNS lymphoma patients by PCR of the CDR III IgH genes. *Neurology*. 2002;58(3):390-6.
- de Haas V, Vet RJ, Verhagen OJ, Kroes W, van den Berg H, van der Schoot CE. Early detection of central nervous system relapse by polymerase chain reaction in children with B-precursor acute lymphoblastic leukemia. *Ann Hematol*. 2002;81(1):59-61.
- van Oostenbrugge RJ, Hopman AH, Arends JW, Ramaekers FC, Twijnstra A. Treatment of leptomeningeal metastases evaluated by interphase cytogenetics. *J Clin Oncol*. 2000;18(10):2053-8.
- Breccia M, Carmosino I, Diverio D, De Santis S, De Propriis MS, Romano A, et al. Early detection of meningeal localization in acute promyelocytic leukaemia patients with high presenting leucocyte count. *Br J Haematol*. 2003;120(2):266-70.
- Sanz MA, Lo Coco F, Martin G, Avvisati G, Rayon C, Barbui T, et al. Definition of relapse risk and role of nonanthracycline drugs for consolidation in patients with acute promyelocytic leukemia: a joint study of the PETHEMA and GIMEMA cooperative groups. *Blood*. 2000;96(4):1247-53.
- Nagai S, Asai T, Watanabe T, Oshima K, Hangaishi A, Kanda Y, et al. Simultaneous appearance of central nervous system relapse and subarachnoid hemorrhage during the treatment for acute promyelocytic leukemia. *Ann Hematol*. 2003;87(7):593-5.
- DeAngelis LM, Cairncross JG. A better way to find tumor in the CSF? *Neurology*. 2002; 58(3):339-40.

## Mobilization of *PML/RAR $\alpha$* negative peripheral blood stem cells with a combination of G-CSF and CXCR4 blockade in relapsed acute promyelocytic leukemia pre-treated with arsenic trioxide

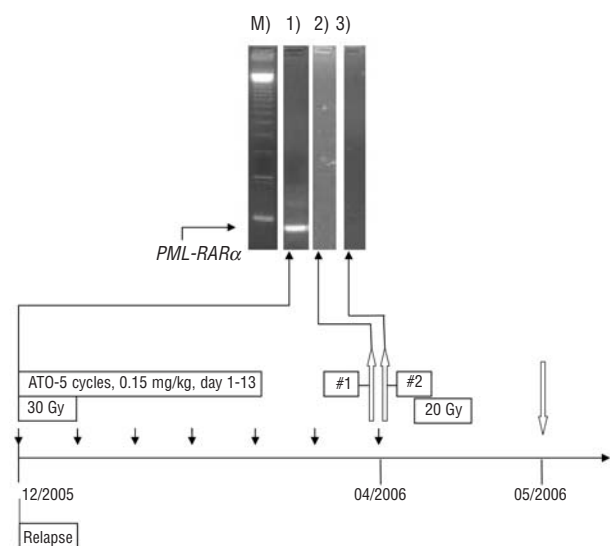
Very recently Montesinos *et al.* reported on the incidence of central nervous system (CNS) involvement at first relapse in patients with acute promyelocytic leukemia (APL) who had been treated with all-*trans* retinoic acid (ATRA) and anthracycline monochemotherapy without intrathecal prophylaxis.<sup>1</sup> Although this study showed a relatively low incidence of CNS involvement at first relapse, controversy over treatment options remains. The introduction of ATRA and more recently arsenic trioxide (ATO) has changed treatment options and outcome for APL.<sup>2,3</sup> In the setting of relapsed APL, ATO is currently regarded as the preferential remission induction therapy. However, for patients achieving complete remission (CR) thereafter, appropriate consolidation strategies have not yet been defined.<sup>4</sup> Autologous hematopoietic stem cell transplantation (HSCT) is one treatment option in relapsed APL.

Here, we report a patient who had been diagnosed with relapsed APL involving the CNS and who achieved a second CR after ATO salvage therapy. Mobilization of peripheral blood stem cells (PBSC) was accomplished using a combination of granulocyte-colony stimulating factor (G-CSF) and CXCR4 blockade.

A 40-year old woman experienced extramedullary relapse of APL while on maintenance therapy after having achieved CR with ATRA containing induction chemotherapy. Due to multilocal CNS manifestation as well as molecular bone marrow involvement, ATO was started (5 cycles, 0.15 mg/kg, day 1-13) in parallel with local irradiation. Liposomal cytarabine (7 applications, 50 mg absolute/week) was applied intrathecally in order to treat meningeosis. After a molecular analysis of the bone marrow had shown negativity for *PML-RAR $\alpha$*  transcripts after ATO and intrathecal therapy, G-CSF mobilization was started out of steady state in order to collect PBSC for autologous HSCT. While the WBC peaked at 31 Gpt/L, only 6/ $\mu$ L CD34<sup>+</sup> cells could be measured in the peripheral blood. The corresponding apheresis yield was only 0.9 $\times$ 10<sup>6</sup>/kg CD34<sup>+</sup> PBSC. In order to achieve a target of >2 $\times$ 10<sup>6</sup>/kg CD34<sup>+</sup> PBSC, the patient received the CXCR4 antagonist AMD3100 subcutaneously at a dose of 240  $\mu$ g/kg ten hours prior to the next apheresis in addition to G-CSF within a compassionate use program. CXCR4 blockade led to an increase in WBC (44 Gpt/L) and CD34<sup>+</sup> count (9/ $\mu$ L) with a subsequent harvest of 1.2 $\times$ 10<sup>6</sup>/kg CD34<sup>+</sup> PBSC. Interestingly, both apheresis products were found to be *PML-RAR $\alpha$* -PCR negative (Figure 1). Sensitivity of nested PCR for *PML-RAR $\alpha$*  was achieved according to the minimal target sensitivity of 10<sup>-4.5</sup>. Three weeks later, myeloablative conditioning containing 12 Gy total body irradiation (day -6 to -4) and 120 mg/kg of intravenous cyclophosphamide (day -3 to -2) was performed and followed by reinfusion of PBSC on day 0. Fast and stable trilineage engraftment was documented with neutrophils >0.5 Gpt/L and platelets > 50 Gpt/L on day +14 and +16, respectively. Three years later (day +1,144 after autologous HSCT) the patient remains in complete hematologic remission without clinical signs of extramedullary disease.

Arsenic trioxide has recently been shown to play an emerging role in relapsed and refractory APL with the majority of patients achieving a complete molecular remission.<sup>3,6</sup> Following molecular CR after ATO treatment, subsequent collection of PBSC and autologous HSCT after myeloablative chemotherapy is recommended but discussed controversially with regard to the best consolidation strategy.<sup>4,7</sup> Harvesting a satisfactory amount of CD34<sup>+</sup> PBSC after repetitive chemotherapy regimens might be challenging. Sequential therapy with ATO might even decrease the hematopoietic capacity. Application of AMD3100 in addition to G-CSF displays a possible option to compensate for poor HSC mobilization. Albeit, leukemic blasts are known to express CXCR4 and could, therefore, become potential targets of AMD3100.<sup>8</sup> Data in a murine model suggest that AMD3100 administration leads to an increased time-dependent mobilization of APL blasts by interrupting the CXCR4-SDF-1 axis.<sup>9</sup> But for AML in general no clinical trials exist in order to confirm or disprove whether mobilizing leukemic stem cells reflect a relevant problem in this setting. DiPersio *et al.* advised caution and stated that AMD3100 might not be intended for mobilization and harvest in patients with leukemia.<sup>10</sup>

Our limited experience in this patient suggests at least that in case of molecular remission, no apparent mobilization of *PML-RAR $\alpha$*  positive cells occurred. Whether differ-



**Figure 1.** *PML-RAR $\alpha$*  specific PCR-M) marker, lane 1) before ATO treatment, lane 2) G-CSF mobilized stem cells, lane 3) G-CSF + AMD3100 mobilized stem cells. Lanes were processed to secure clearness since other patient samples were performed routinely in parallel. Graph: treatment course after relapse. Local irradiation with 30 Gy starting December 2005 and 20 Gy starting in April 2006. Black arrows indicate intrathecal application of liposomal cytarabine. White arrows pointing upward indicate apheresis #1 with G-CSF and apheresis #2 with G-CSF and AMD3100. White arrow pointing downward indicates autologous SCT after myeloablative conditioning with 12 Gy TBI and intravenous cyclophosphamide.

ent subsets of leukemic stem and progenitor cells might be differentially targeted by CXCR4 is unknown. Next leukemic blast mobilization *in vitro* was strictly time-dependent in the murine model with a peak of circulating APL blasts after three hours and return to baseline after 12 h. Furthermore, APL blast mobilization in an *in vivo* model seems to be influenced by the respective microenvironment since extramedullary blasts with exclusive intraperitoneal expansion were not shown to be circulating after AMD3100 administration.<sup>9</sup> Our case shows that even after intensified ATO treatment due to relapsed APL, *PML-RAR $\alpha$*  negative PBSC can be obtained by using the competitive CXCR4 antagonist AMD3100 to increase the number of harvested cells. These cells proved not to be contaminated by clonogenic APL cells allowing successful autologous HSCT which induced prolonged remission without further maintenance therapy.

Friedrich Stölzel, Martin Wermke, Christoph Röllig, Christian Thiede, Uwe Platzbecker, and Martin Bornhäuser  
Medizinische Klinik und Poliklinik I, Universitätsklinikum Carl Gustav Carus Dresden, Germany

**Key words:** extramedullary blasts, *PML-RAR $\alpha$* , all-trans retinoic acid.

**Correspondence:** Friedrich Stölzel, Medizinische Klinik und Poliklinik I, Universitätsklinikum Carl Gustav Carus Dresden Fetscherstr.74, 01307 Dresden, Germany. Phone: international +49.351.4582321. Fax: international +49.351.4585344. E-mail: friedrich.stoelzel@uniklinikum-dresden.de

**Citation:** Stölzel F, Wermke M, Röllig C, Thiede C, Platzbecker U, and Bornhäuser M. Mobilization of *PML/RAR $\alpha$*  negative peripheral blood stem cells with a combination of G-CSF and CXCR4 blockade in relapsed acute promyelocytic leukemia pre-treated with arsenic trioxide. *Haematologica*. 2010; 95:171-172. doi: 10.3324/haematol.2009.016568

## References

- Montesinos P, Diaz-Mediavilla J, Deben G, Prates V, Tormo M, Rubio V, et al. Central nervous system involvement at first relapse in patients with acute promyelocytic leukemia treated with all-trans retinoic acid and anthracycline monochemotherapy without intrathecal orophylaxis. *Haematologica*. 2009;94(9): 1242-9.
- Tallman MS, Andersen JW, Schiffer CA, Appelbaum FR, Feusner JH, Ogden A, et al. All-trans-retinoic acid in acute promyelocytic leukemia. *N Engl J Med* 1997;337(15):1021-8.
- Niu C, Yan H, Yu T, Sun HP, Liu JX, Li XS, et al. Studies on treatment of acute promyelocytic leukemia with arsenic trioxide: remission induction, follow-up, and molecular monitoring in 11 newly diagnosed and 47 relapsed acute promyelocytic leukemia patients. *Blood* 1999;94(10):3315-24.
- Sanz MA, Grimwade D, Tallman MS, Lowenberg B, Fenaux P, Estey EH, et al. Management of acute promyelocytic leukemia: recommendations from an expert panel on behalf of the European LeukemiaNet. *Blood* 2009;113(9):1875-91.
- van Dongen JJ, Macintyre EA, Gabert JA, Delabesse E, Rossi V, Saglio G, et al. Standardized RT-PCR analysis of fusion gene transcripts from chromosome aberrations in acute leukemia for detection of minimal residual disease. Report of the BIOMED-1 Concerted Action: investigation of minimal residual disease in acute leukemia. *Leukemia* 1999;13(12):1901-28.
- Soignet SL, Frankel SR, Douer D, Tallman MS, Kantarjian H, Calleja E, et al. United States multicenter study of arsenic trioxide in relapsed acute promyelocytic leukemia. *J Clin Oncol* 2001;19(18):3852-60.
- Tallman MS, Altman JK. Curative strategies in acute promyelocytic leukemia. *Hematology Am Soc Hematol Educ Program* 2008:391-9.
- Burger JA, Peled A. CXCR4 antagonists: targeting the microenvironment in leukemia and other cancers. *Leukemia* 2009;23(1):43-52.
- Nervi B, Ramirez P, Rettig MP, Uy GL, Holt MS, Ritchey JK, et al. Chemosensitization of acute myeloid leukemia (AML) following mobilization by the CXCR4 antagonist AMD3100. *Blood* 2009;113(24):6206-14.
- DiPersio JF, Stadtmayer EA, Nademanee A, Micallef IN, Stiff PJ, Kaufman JL, et al. Plerixafor and G-CSF versus placebo and G-CSF to mobilize hematopoietic stem cells for autologous stem cell transplantation in patients with multiple myeloma. *Blood* 2009;113(23):5720-6.

## Premature termination codon mutations in the von Willebrand factor gene are associated with allele-specific and position-dependent mRNA decay

Nonsense-mediated mRNA decay (NMD) is an intron-dependent RNA-degradation pathway responsible for depleting transcripts containing premature termination codons (PTCs), presumably to control the synthesis of truncated proteins, potentially deleterious to cells. PTC-bearing (PTC<sup>+</sup>) mRNAs are unstable only when the PTC is located more than 50-55 nucleotides upstream of the last intron.<sup>1</sup> However, not all genes undergo NMD. Among coagulation genes, NMD was demonstrated for factors V, XI, and XIII, whereas it was shown to be inactive for fibrinogen (*FGA*, *FGG*) and factor VIII (*FVIII*) genes (*Online Supplementary Table S1*).

Von Willebrand factor (VWF) is a multimeric glycoprotein, synthesized by endothelial cells and megakaryocytes, promoting both platelet adhesion to the subendothelium at sites of vascular injury, and platelet-platelet interactions in high shear-rate conditions. It also binds and stabilizes *FVIII*.<sup>2</sup>

Quantitative VWF deficiency can be classified as partial (VWD1) or complete (VWD3), whereas qualitative defects (VWD2) are subdivided into four main types: VWD2A, VWD2B, VWD2M, VWD2N.<sup>2</sup>

The aim of this study was to investigate whether PTC-