

## REVIEW

# Facial reconstruction – anatomical art or artistic anatomy?

Caroline Wilkinson

Centre for Anatomy &amp; Human Identification, University of Dundee, UK

---

**Abstract**

Facial reconstruction is employed in the context of forensic investigation and for creating three-dimensional portraits of people from the past, from ancient Egyptian mummies and bog bodies to digital animations of J. S. Bach. This paper considers a facial reconstruction method (commonly known as the Manchester method) associated with the depiction and identification of the deceased from skeletal remains. Issues of artistic licence and scientific rigour, in relation to soft tissue reconstruction, anatomical variation and skeletal assessment, are discussed. The need for artistic interpretation is greatest where only skeletal material is available, particularly for the morphology of the ears and mouth, and with the skin for an ageing adult. The greatest accuracy is possible when information is available from preserved soft tissue, from a portrait, or from a pathological condition or healed injury.

**Key words** anatomy; art; facial reconstruction.

**Introduction**

Facial reconstruction is currently used in two principal contexts: forensic science and archaeology. In the forensic context it plays an important role in identification of the dead where post-mortem deterioration has made this problematic. In archaeology, it is used to create three-dimensional visual images of people from the past, from skeletal remains, mummified bodies, or bodies preserved in bogs.

Forensic facial anthropology is the interpretation of human remains to attempt to depict the face of the individual (Gerasimov, 1971; Prag & Neave, 1997; Taylor, 2001; Wilkinson, 2004). It is a powerful tool that significantly enhances the chances of identification of the deceased. Following major natural disasters, such as the Tsunami of 26 December 2004 and Hurricane Katrina of August 2005, human remains may be extremely difficult to recognize due to decomposition or environmental effects; clothing and personal items may be lost and dental records unavailable (Black & Thompson, 2006). Skin colour is altered by early pallor or later *livor mortis*, putrefaction and epidermal sloughing; eye colour quickly becomes indistinguishable as decomposition of the eye-

balls begins immediately after death, and hair pattern may be uninformative due to hair loss at the roots or tissue shrinkage (Gordon & Shapiro, 1975). In addition, water movement, body movement, rigor mortis, environmental pressure and animal activity can cause feature distortion or surface marks (Freedman, 1996). The jaw of the cadaver may become slack due to the relaxation of the muscles of mastication, and the outer canthal angle of the eye may appear upturned due to a combination of the effects of gravity and *rigor mortis* of the lateral palpebral ligaments (Taylor, 2001). Gas production from putrefaction will bloat the body and the eyelids and lips become closed and swollen; the cheeks puff out, and the distended tongue may protrude between the lips (Polson et al. 1985). Even where facial preservation is sufficient for recognition by a family member to be attempted, the emotional circumstances result in many examples of false recognition (Hill, 2006).

Ten percent of victims of the Tsunami and fifty percent of victims of the Bali bombing of 12 October 2002 were wrongly identified by facial recognition (Lain et al. 2003). The social, legal and religious implications of misidentification are enormous. International investigative authorities advocate that it is vital to identify the deceased to allow remains to be returned to their families for proper recognition and religious observance, for grieving and acceptance of death and for judicial matters of estate (Lain et al. 2003). With mass disasters such as these, the usual accepted methods of identification are often inappropriate and the importance of unusual and less definitive methods of iden-

---

**Correspondence**

Caroline Wilkinson, Centre for Anatomy & Human Identification, MSI Building, Dow Street, University of Dundee, Dundee DD1 5EH, UK.  
E: c.m.wilkinson@dundee.ac.uk

Accepted for publication 30 October 2009

tification has been recognized. The technique of facial reconstruction can help resolve many stalemates within identification investigations (Wilkinson, 2006).

The ultimate aim of facial reconstruction is to recreate an *in vivo* countenance of an individual that sufficiently resembles the deceased person to allow recognition (Prag & Neave, 1997). In forensic situations it may contribute to their recognition and lead to positive identification. It must also be noted that facial reconstruction is not a method of identification, rather a tool for recognition; to produce a list of names from which the individual may be identified by DNA assessment, dental record analysis or other accepted methods of identification (Wilkinson, 2006). It is a last option in a forensic investigation, when the routine channels of enquiry, such as crime scene clues, missing person files and dental record assessment, may have already been pursued with limited success (Clement & Ranson, 1997). When combined with a publicity campaign, facial reconstruction from skeletal remains may lead to recognition by a member of the public, and hence lead to the identification of that individual.

The skull is made up of 22 bones, 14 facial and eight cranial bones; it is a complex structure, and small variations during development and growth, together with soft tissue differences, create the enormous facial variation seen in the human population (Landau, 1989; Bruce & Young, 1998). Artists have long been interested in the direct anatomical relationship between the skull and facial appearance. Gaetano Guilio Zumbo (1656-1701), whose work can be found in the Wax Anatomical Collection at La Specola Museum, Florence, became famous for his macabre scenes depicting various stages of decomposition of the human body (De Ceglia, 2005; Ballestriero, 2010, this issue). One of his most famous pieces is the head of a dead man, with facial muscles recreated in wax over a real skull (see Ballestriero, 2010, this issue; Fig. 1). This is the earliest surviving anatomical wax model created for didactic purposes and exhibits extraordinary anatomical precision alongside an artistic sense of horror and decay. Although we assume that Zumbo was less concerned with facial appearance than anatomical detail, he pioneered the development of scientific art and this work ranks as one of the finest examples of three-dimensional facial reconstruction. Today, many forensic facial reconstruction techniques are in use (Fig. 1), including two-dimensional (Taylor, 2001), three-dimensional manual (Gatliff & Snow, 1979; Gerasimov, 1971) and three-dimensional computer-based (Moss et al. 1987; Kahler et al. 2003; Wilkinson, 2003a).

Although facial reconstruction is used extensively in human identification investigations with a good level of success, and is frequently applied to archaeological investigations to depict the faces of people from the more distant past, the technique receives a great deal of criticism from both science and art perspectives. Criticism from scientists includes the contention that the technique is too subjective and heavily reliant on the artistic skill of the individual

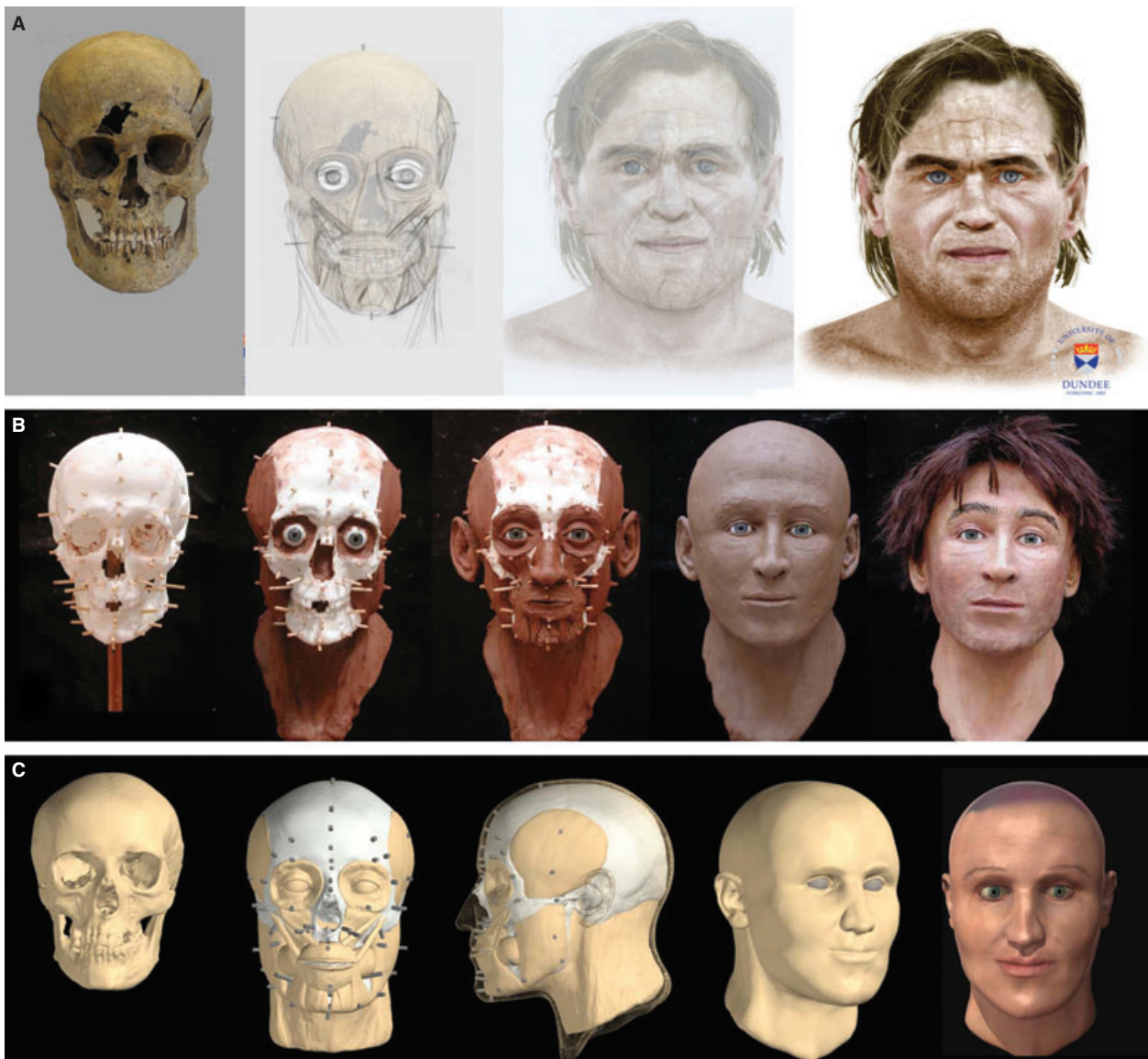practitioner (Suk, 1935; Vanezis et al. 1989; Stephan, 2005). Attempts to automate the process have been poorly received and have not been as successful in forensic investigation, whilst accuracy studies have reported extremely variable results (Snow et al. 1970; Helmer et al. 1989; Haglund & Raey, 1991, Stephan & Henneberg, 2001; Wilkinson & Whitaker, 2002; Wilkinson et al. 2006), and this has led to claims of unreliability and lack of reproducibility (Stephan & Henneberg, 2001; Stephan, 2005). This has been exacerbated by the claims of the media and some practitioners, who state that success is dependent on uncanny intuition or psychic ability (Maxwell, 2001; Vaughan, 2004). On the other hand, some researchers suggest that facial reconstruction techniques are too reliant on average data and inflexible standards (Brues, 1958) and therefore will only produce a facial type rather than a characteristic likeness (Wilkinson, 2008).

This paper will discuss the facial reconstruction technique employed by the author, commonly known as the Manchester method – a combination method developed and taught primarily by Richard Neave (Prag & Neave, 1997) and Wilkinson (2004). There is a great deal of disagreement between practitioners regarding techniques, accuracy levels and reliability. Whilst acknowledging this controversy, I will attempt to assess the procedure employed for facial reconstruction at my institution in relation to the degree of scientific process and artistic interpretation that are involved in each stage. This will enable us to establish whether the process is an artistic interpretation of anatomical structures or a depiction of anatomy using artistic skills. The conclusions are not applicable to all other facial reconstruction methods employed by forensic practitioners and it must be noted that some practitioners apply a different level of artistic interpretation.

### Accuracy of facial reconstruction

The three-dimensional facial reconstruction technique discussed in this paper involves the production of facial sculptures onto the skull or skull replica (see Fig. 1). This approach involves modelling the facial musculature before applying a skin layer to depict the living facial appearance (Prag & Neave, 1997; Wilkinson, 2004).

Before dissecting the facial reconstruction process in detail the accuracy of this technique should be discussed. The level of accuracy is of great importance to practitioners and law enforcement agencies. Without question, facial reconstruction has been a valuable tool for forensic investigation and many individuals have been successfully identified as a direct result of a publicity campaign employing a facial reconstruction (Van den Eerenbeemt, 2001; Policing Cardiff, 2005, Algemeen, 2009). Practitioners report varying success rates (Caldwell, 1981; Haglund & Raey, 1991; Wilkinson, 2006), but it is unclear from the success rates to what extent the facial reconstructions were directly responsible for recognition and thus identification.



**Fig. 1** Facial reconstruction methods: (A) two-dimensional manual, (B) three-dimensional manual, (C) three-dimensional computerized.

Typically, practitioners will show an image of the reconstruction next to an ante-mortem photograph of the identified individual to illustrate the accuracy of the technique (Suzuki, 1975; Haglund & Raey, 1991; Phillips et al. 1996). As only the successful cases are shown in this way, this is not an impartial assessment, and blind studies must be utilized to rigorously analyse the reliability of the techniques. However, the inherent flaw in the majority of blind studies is that it is practically and ethically difficult to represent a forensic scenario based on familiar face recognition (as access to skulls of known identity along with access to relatives of the deceased is almost impossible to achieve), so these blind studies often rely on unfamiliar face recognition and evaluation. The problems associated with the recognition of unfamiliar faces were highlighted by Kemp et al. (1997) who recorded extremely high error rates in the verifi-

cation of identity from photo-ID cards. This was further demonstrated by Bruce et al. (1999), who investigated matching of unfamiliar target faces from high quality video stills against photographic arrays. The recognition rate was only 70% (where the rate by chance was 10%), despite the fact that the target still was taken on the same day as the array photograph. The recognition rates decreased further when unmatched views or expressions were employed. This research suggests that we are not as accomplished at unfamiliar face recognition as familiar face recognition, where the recognition rates are closer to 90% (Burton et al. 1999), and that different neural mechanisms may be utilized (Bruce & Young, 1986).

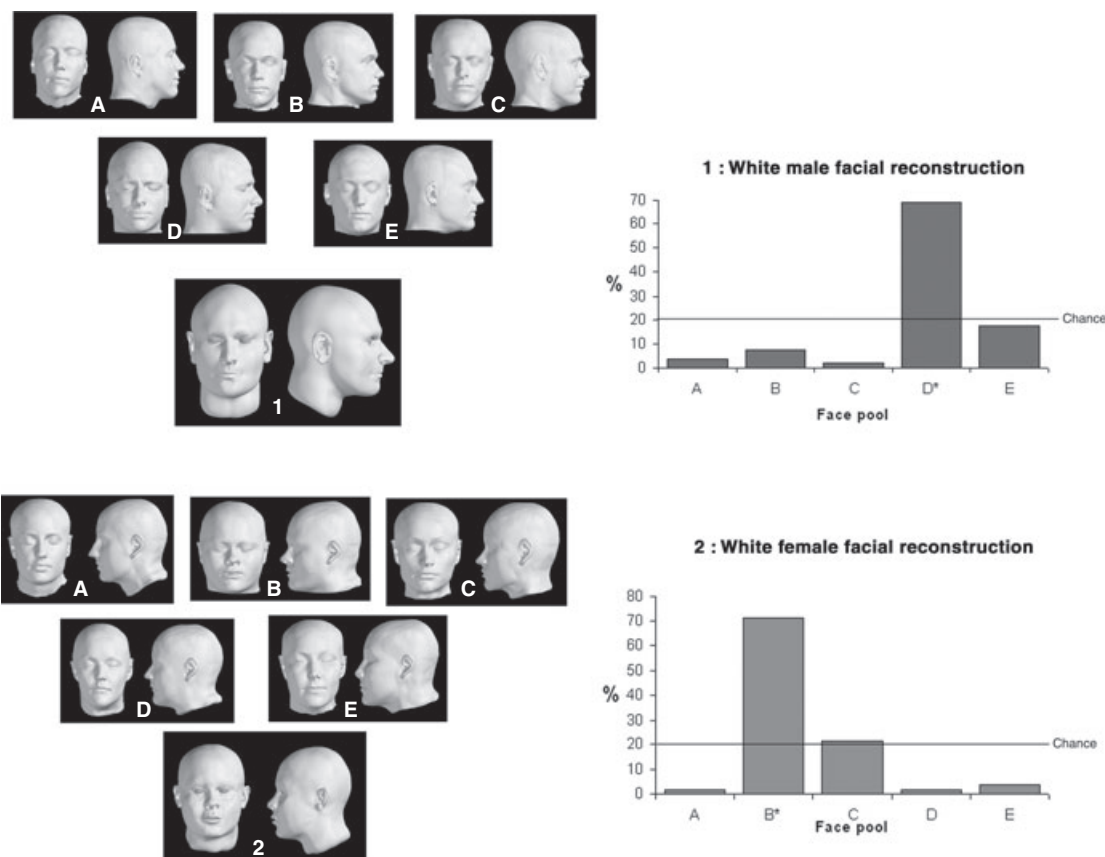
A number of different methods have been employed to assess accuracy and reliability, including face pool assessment, resemblance ratings and morphometric comparison.

The use of resemblance rating assessment has been criticized as misleading and insensitive (Stephan & Arthur, 2006), and face pool assessment and anthropometry are currently encouraged as more meaningful measures of the accuracy of facial reconstruction. Face pool assessment (Snow et al. 1970; Stephan & Henneberg, 2001) involves the comparison of an image of the reconstruction with a pool of face photographs that includes the target alongside a number of other faces of similar age, sex and ethnic group (Fig. 2). Volunteers are then asked to choose the face from the pool that most resembles the reconstruction, to determine the correct recognition rate. The level above that recorded by chance suggests the accuracy of the facial reconstruction. For the Manchester method, a blind study by Wilkinson & Whittaker (2002) analysed five female juvenile reconstructions using face pool assessment and recorded an overall recognition rate of 44% (where the level by chance was 10%). A further blind study (Wilkinson et al. 2006) analysed two adult computerized reconstructions (Fig. 2) and recorded an overall recognition rate of 71% (where the level by chance was 20%). This study employed images of facial surface scan data in the face pool rather than photographs. These results compare favourably

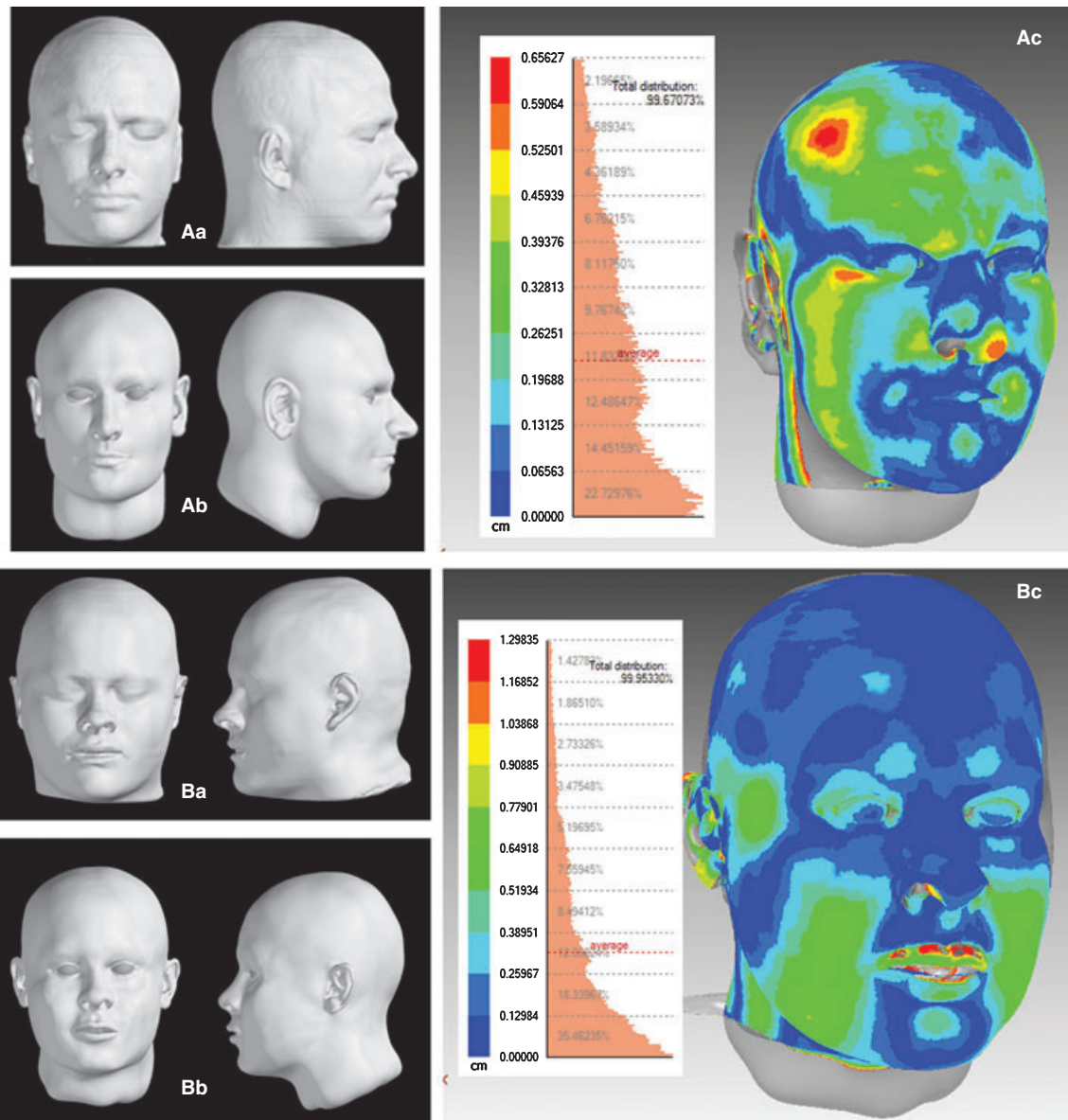
with previous reconstruction studies, where results range from 8% correct identification rate (where the level by chance was 5%; Stephan & Henneberg, 2001) to 46.5% (where the level by chance was 14.3%; Snow et al. 1970), and with the psychology study by Bruce et al. (1999), where recognition even from photographic *in vivo* images was only 70% (where the level by chance was 10%).

It may be possible to assess accuracy by morphometric comparison between the reconstruction and the target face. With the development of CT imaging and computerized facial reconstruction it is possible to compare the surfaces of the reconstruction and the target face using 3D modelling software (RAPIDFORM). The Manchester method was evaluated in this way (Wilkinson et al. 2006) using CT data from two adults, one male and one female. The results suggested that 67% of the facial reconstruction surface had less than 2 mm error, even with the cheek distortion exhibited on the target face due to the position in the CT scanner (Fig. 3). The study suggested that the nose, eyes, jaw line, forehead and chin could be reconstructed reliably (< 2 mm error), with the mouth and ears showing the most errors.

In conclusion, the laboratory studies of the Manchester method suggest that facial reconstruction can reproduce a



**Fig. 2** Face pool assessments of facial reconstruction accuracy. Top row: reconstruction of a white male skull (1) and a face pool (A–D). Bottom row: reconstruction of a white female skull (2) and a face pool (A–D). Graphs show the results of face pool assessment for 1 and 2 with target faces (\*) recording correct recognition rates of > 70% (where the level by chance is 20%) (Wilkinson et al. 2006).



**Fig. 3** Morphometric assessment of facial reconstruction accuracy. The target white male (Aa), the facial reconstruction (Ab) and the contour map (Ac) showing the differences between the surfaces of the two faces in mm. The target white female (Ba), the facial reconstruction (Bb) and the contour map (Bc) showing the differences between the surfaces of the two faces in mm. The blue areas show the least error and the red/orange areas the most error for each reconstruction (Wilkinson et al. 2006).

sufficient likeness to allow recognition by a close friend or family member. It is not possible to produce a portrait and there are many details of the face that cannot be determined from the skull, but it should be possible to estimate the majority of facial feature morphology from skeletal detail.

**Artistic anatomy or anatomical art?**

The facial reconstruction technique involves three elements: the anatomical modelling, the morphology determination, and the depiction of the resulting face to the public.

**Stage 1: anatomical modelling**

Faces have, with some minor variation, a similar number of muscles with the same origins and attachments; indeed this is the very basis of anatomy education (Warwick & Williams, 1973; Paff, 1973; McMinn et al. 1994). However, the shape, size and relative position of these muscles will vary between individuals in relation to the bony matrix and some muscles of facial expression may be absent, duplicated or bifurcated (Pessa et al. 1998a,b; Hu et al. 2008). A routine visit to a dissecting room will show that there is considerable variation in anatomical structures and this human variation has long

been recognized. Whilst some of these variations cannot easily be predicted (e.g. absence or bifurcation of a muscle of facial expression), skeletal assessment may indicate variation in muscle origins and/or attachments.

It is commonly reported in anatomical publications that some muscle attachments are associated with well defined areas on bone surfaces (Warwick & Williams, 1973; Evans & Copp, 1986), and research has established that muscle size and activity have a direct influence on craniofacial morphology (Goldstein, 1992; Inoue, 1993; Ito, 1993; Kiliaridis & Kalebo, 1991). The temporalis muscle attachment can often be seen on the surface of the temporal bone, the inferior border of the masseter muscle is frequently visible on the mandible and the zygomatic muscle origins may be visible at the zygomatic bones (Warwick & Williams, 1973; and Fig. 4). Gerasimov (1955) noted that where the cheek bones are wide and heavy, the zygomaticus major and minor muscle origins will be positioned on the anterior surface of the zygomatic bone; in contrast, where the cheek bones are narrow and gracile, the origins of these two muscles will be positioned more laterally on the surface of the zygomatic

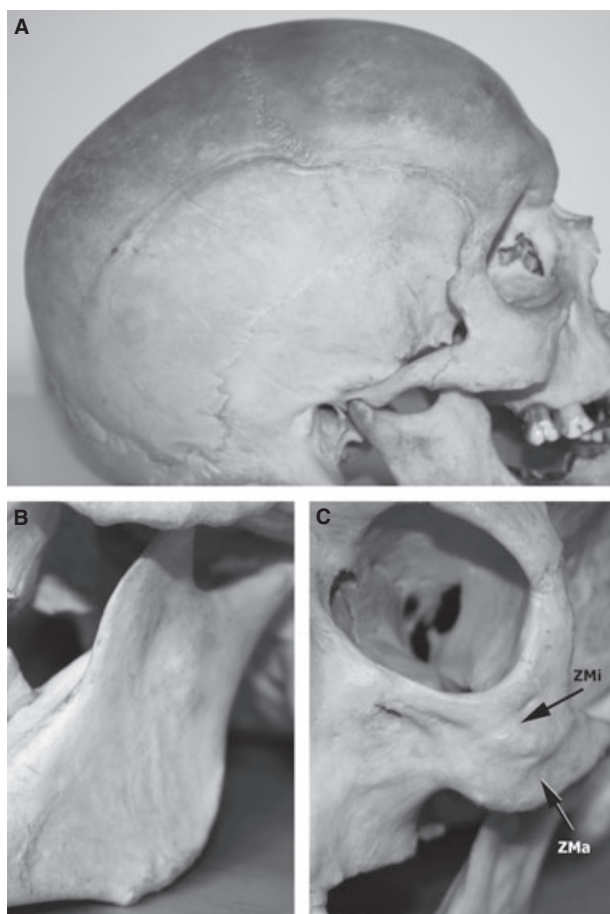
bone. Awareness of these subtle differences means that sculpture of the facial musculature onto different skulls will produce different face shapes, with different proportions and different contours (Fig. 5).

In conclusion, whilst sculptural skill is clearly useful, this stage of the reconstruction process should involve no artistic interpretation and, providing the muscles and other relevant structures (e.g. the parotid gland) are modelled following anatomical guidelines, the procedure will be both reproducible and reliable. Errors in muscle structure determination will occur at this stage of the reconstruction process, as the absence, duplication or bifurcation of facial expression muscles cannot be predicted from skeletal assessment, but the same errors should be produced by all practitioners. From teaching experience it is clear that this is the easiest stage of the reconstruction technique to learn, even with low levels of sculptural expertise.

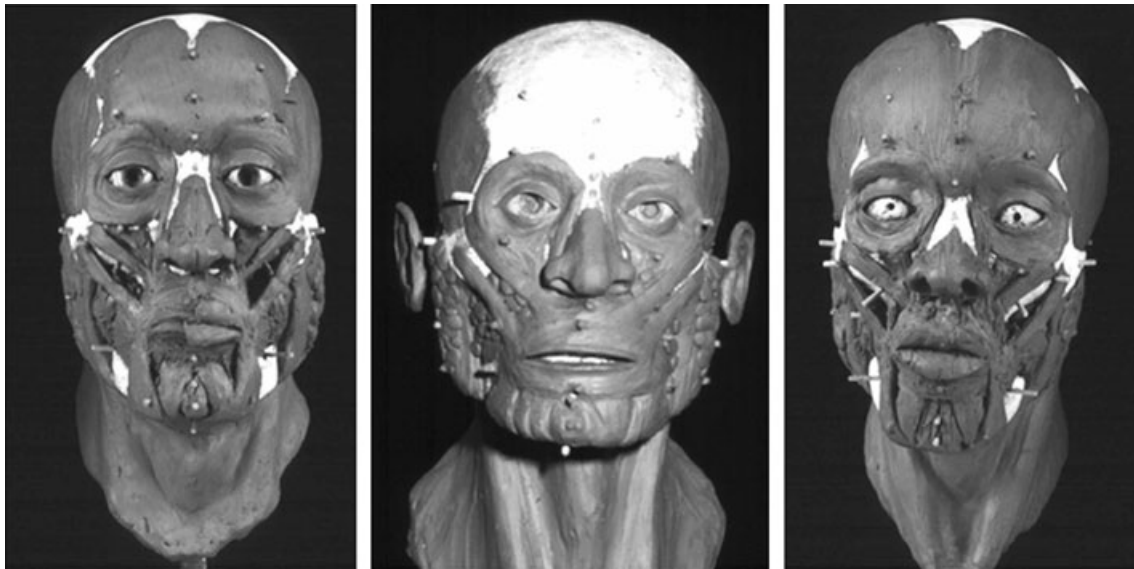
## Stage 2: morphology determination

The determination of facial features is carried out by assessing related bony detail. A number of standards are employed for each feature during this analysis, and many of the standards are related to anatomical principles.

The determination of eye morphology is related to the position of the inner and outer canthi and the position of the eyeball in the orbit. Whitnall (1921) described the orbit in detail and many of our current standards rely on his extensive dissection study. The curves of the eyelid margins are not symmetrical and the upper lid is more pronounced than the lower, its height being greatest nearer the medial angle, whereas that of the lower lid is nearer the lateral angle (Whitnall, 1921). The lateral canthal angle is more acute than the medial and lies in close contact with the globe, whereas the medial canthus extends towards the nose 5–7 mm away from the globe, being separated by the caruncula and the plica semilunaris. Merkel (1887) further described the radius of the upper curve as 16.5 mm and that of the lower as 22 mm. Whitnall (1912) described the position of the two canthi as being 'almost precisely determined, the inner by the naso-lacrimal duct (lacrimal fossa) and the outer by the slightly but definitely indicated malar tubercle'. Angel (1978) confirmed this and stated that the inner canthus can be placed 2 mm lateral to the lacrimal crest at its middle, and the outer canthus can be placed 3–4 mm medial to the malar tubercle. Where the malar tubercle is absent, the outer canthus can be positioned 10 mm below the line of the zygomatico-frontal suture and 5–7 mm from the orbital margin. The centre point of the eyeball is determined as 2 mm below mid-orbit with the iris touching a tangent across the mid-supraorbital to mid-infraorbital bone (Whitnall, 1921). Whilst there has been disagreement in the past between practitioners regarding eyeball placement (Stephan & Davidson, 2008), current research results (Stephan, 2002; Wilkinson & Mautner, 2003)



**Fig. 4** Muscle attachment markings for temporalis (A), masseter (B) and zygomatic (C) muscles. ZMi, zygomaticus minor; ZMa, zygomaticus major.



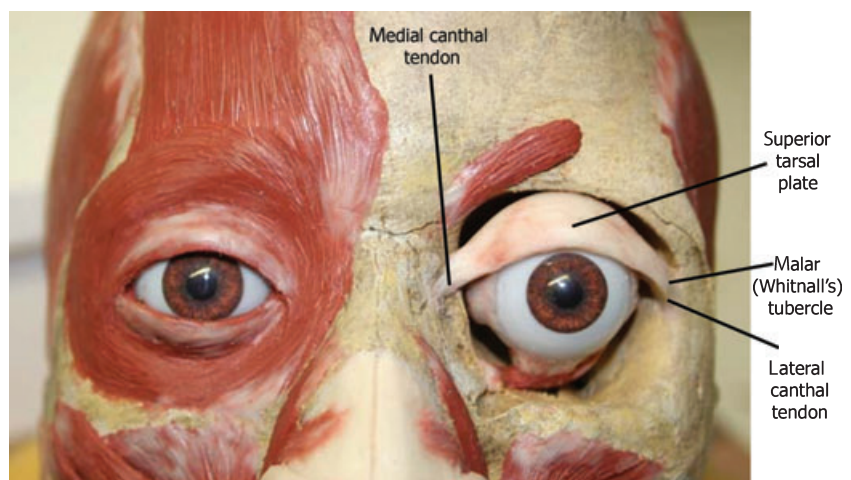
**Fig. 5** Three skulls with the addition of the muscle structure in modeling clay. Where the same muscles, with the same origins and insertions, are modeled onto three different skulls, clear differences can be observed in facial shape and proportions.

are in agreement with Whitnall and Wolff (summarized in Bron et al. 1997).

With these details determined and sculpture of the correct anatomical structures of the eye as described by Whitnall (1921) (a 24-mm diameter eyeball, a 12-mm diameter iris and the eyelids hugging the eyeball closely whilst clipping the edge of the iris as they cross the eyeball) there is little room for artistic interpretation (Fig. 6).

Traditionally the nose has been considered a feature with poor levels of reconstruction accuracy and there have been many studies assessing the relationship between the configuration of the nasal tissue with the bones surrounding the nasal aperture (Tandler, 1909; Virchow, 1912; Schultz, 1918; Gerasimov, 1955; Glanville, 1969; Macho, 1986; McClintock Robinson et al. 1986, George, 1993, Prokopec & Ubelaker, 2002; Stephan et al. 2003). It is anatomically predictable

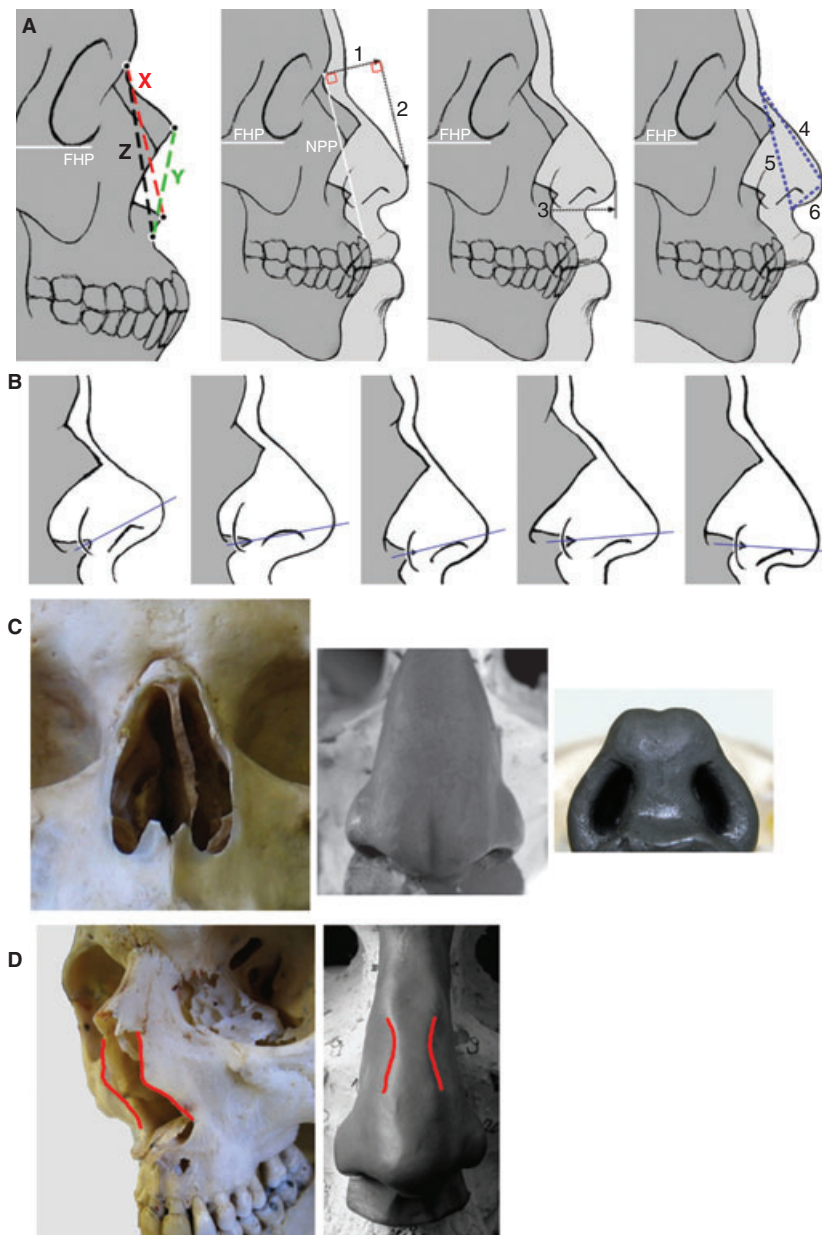
that the soft nose will be wider than the bony aperture, as a narrower soft nose would have no supporting structure. It also makes anatomical sense that the soft nose will not be very much wider than the bony aperture, as this would create a partial obstruction to the movement of air into the nostrils, forcing the air to change direction as it entered the nostrils, creating inefficient air passage. Gerasimov (1955) suggested that the bony nasal aperture at its widest point will be three-fifths of the overall width of the soft nose, and this has been confirmed in a CT study of living subjects regardless of ethnic group (Rynn, 2006). Nasal base angle (angle between the upper lip and the columella) is determined by the direction of the nasal spine. He stated that the axis of the nasal spine serves as a base for the soft nose and determination of nasal spine direction follows the point of the spine, as if it were an arrowhead. He also



**Fig. 6** Anatomical reconstruction of the eye. Image courtesy of Caroline Needham, University of Dundee.

suggested that the end of the soft nose could be predicted as the point where a line following the projection of the last part of the nasal bones (at the rhinion) crosses a line following the direction of the nasal spine, and confirmed these standards with a blind study of 50 cadaver heads. Gerasimov (1955) also claimed that the height of the upper border of the alae can be determined by the position of the crista conchalis and the profile of the nose is a mirror of the nasal aperture in profile. These standards have been confirmed using CT data of living subjects (Rynn, 2006); this study additionally confirmed previous papers suggesting that deviation of the nasal tip from the midline is associated

with opposing nasal septum deviation (Selzter, 1944, Gray, 1965) and that nasal tip bifurcation is associated with a bifid nasal spine (Weaver & Bellinger, 1946). Rynn's research also produced guidelines for nasal shape prediction, utilizing three cranial measurements that can be used to predict six soft nose measurements. When all these standards are applied to nasal morphology sculpture, there is little room for artistic interpretation, as illustrated by a blind study (Rynn, 2006; Rynn et al. 2008) using a sample of six skulls, where the predicted noses were compared with ante-mortem images of the faces, showing a high level of accuracy (Fig. 7).



**Fig. 7** Anatomical sculpture of the nose (Rynn, 2006). Row A indicates the skeletal measurements (x,y,z) that provide soft tissue measurements 1–6. Row B demonstrates how the shape of the aperture in profile reflects the profile of the nose, and how the anterior nasal spine points to the nasal tip. Row C shows a bifurcated ANS and related bifid nose. Row D indicates how the undulating lateral borders of the nasal aperture are related to nasal shape.



The morphology of the mouth is an area of the face where there is more reliance on artistic interpretation. Orthodontic and anatomic literature suggests that the form of the mouth is related to the occlusion of the teeth (Rudee, 1964; Roos, 1977; Koch et al. 1979; Waldman, 1982; Holdaway, 1983; Denis & Speidel, 1987; Talass et al. 1987), the dental pattern (Subtelny, 1959) and the facial profile (Gerasimov, 1955). Where the upper teeth are more prominent than the lower teeth, the upper lip will be more prominent than the lower lip and vice versa, and different occlusion patterns will suggest different lip patterns (Gerasimov, 1955). There are some standards for determination of mouth shape, such as placement of the fissure at the mid-line of the maxillary incisor crowns (Angel, 1978) and the mouth corners on radiating lines from the first premolar-canine junction (Krogman & İscan, 1986), or with intercanine distance as 75% of overall mouth width (Stephan & Henneberg, 2003), or the mouth corners positioned below the infraorbital foramina (Stephan & Murphy, 2008). There is also a positive correlation between upper lip thickness and maxillary enamel height, and between lower lip thickness and mandibular enamel height; sets of regression formulae can be utilized for White European and Indian subcontinent populations (Wilkinson et al. 2003). However, the exact shape of the vermillion line is difficult to predict with any degree of accuracy, as illustrated by the results of a metrical evaluation in which lip shape was found to be one of the most error-prone areas of reconstruction (Wilkinson et al. 2006). Successful forensic reconstructions have been demonstrated where the practitioner has modeled the lips 'in sympathy' with the rest of the face (Prag & Neave, 1997), although this may be more luck than judgment.

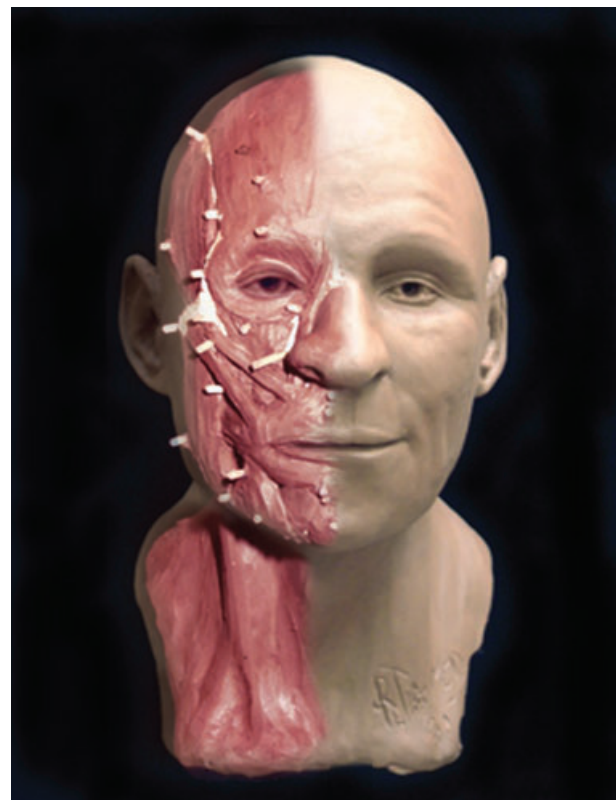Ear shape is also very difficult to determine. Gerasimov (1955) considered the angle of ear to be parallel to the jaw line and stated that where the mastoid processes are directed downward, the earlobe will be attached (adherent), whereas where the mastoid processes point forward, the earlobe will be free. As yet very little information regarding ear shape, size and prominence can be determined reliably and typically standard ear casts will be attached to the reconstruction, which vary in relation to size and lobe pattern only (Wilkinson, 2004).

The final stage of the facial reconstruction process is the addition of a skin layer (with subdermal connective and adipose tissue) over the muscle structure to fill the face out to the level of the tissue depth pegs. The tissue depth pegs represent the mean tissue at an anatomical point related to the ethnic group, sex and age of the individual. There are a large number of international datasets including White European (Helmer, 1984), Indian (Sahni, 2002), North American Black, White and Hispanic (Manhein et al. 2000), South African Mixed Race (Phillips & Smuts, 1996), Japanese (Suzuki, 1948), Egyptian (El-Mehallawi & Soliman, 2001), Zulu (Auslebrook et al. 1996), Korean, Buryat, Kazakh, Bashhir, Uzbek, Armenian, Abkhazian, Russian and Lithuanian

(Lebedinskaya et al. 1993) for adults, and White European (Wilkinson, 2002) and North American White, Black and Hispanic (Manhein et al. 2000) for juveniles. These datasets were measured on living individuals using ultrasound, MR or CT images.

There is an assumption with the use of these datasets that the individual has an average amount of fat over the surface of the face. This may or may not be true, but since it is currently impossible to determine facial fatness from the skeletal structure, this assumption is necessary and based on the hope that a familiar face will be recognizable even where the reconstruction involves a reduction or gain of weight. The skin layer follows the structure of the underlying muscles, so the main determinant of facial morphology is anatomical. Where the anatomical structures disagree with the tissue pegs, the tissue pegs will be removed, as the pegs only represent averages and will not be wholly appropriate for all skulls (Prag & Neave, 1997; Wilkinson, 2004). The addition of a skin layer does not in itself involve any degree of artistic interpretation, but the surface morphological detail is very important for both realistic depiction and artistic interpretation, and this will be related to the age of the individual (Fig. 8).

Age-related changes to the face have been well documented and follow a predictable pattern (Gonzalez-Ulloa &



**Fig. 8** Composite image showing the skin layer placement in relation to the sculpted musculature and tissue depth pegs for facial reconstruction.

Flores, 1965; Takema et al. 1994; Khalil et al. 1996): the skin loses elasticity due to biochemical changes in the underlying connective tissue that cause it to become less firmly attached to the underlying bone or muscles; wrinkles form due to changes in the distribution and formation of collagenous material in the skin, a decrease in the resilience of the fibres, and a decline in the number of fibroblasts leading to dehydration, sagging of flesh, loss of adipose tissue, blurring of iris detail, increased prominence of facial lines and hair loss. An old person may appear to have sunken eyes due to resorption of adipose tissue at the orbits and more visible veins beneath the thinner orbital skin, producing dark circles below the eyes (Gonzalez-Ulloa & Flores, 1965). The suborbital region may also begin to sag, producing 'bags'. Nasolabial and mental creases will become more marked and deeper with increased age (Neave, 1998). Bone resorption at the alveolar processes with loss of teeth in later life will alter the jaw line and mouth significantly (Bodic et al. 2005). The nose and chin will appear more prominent and the distance between the nose and the chin will decrease, with the mouth appearing to sink into the face, and there is some growth of the cartilaginous portions of the nose and the ears throughout adulthood (Neave, 1998).

Although age-related changes to the skin surface follow a predictable pattern, the timing of this pattern is not predictable (Loth & Iscan, 1994; Novick, 1988; Orentreich, 1995). Age-related skin changes accrue more slowly in some people than others so there is a great deal of variation between individuals of the same age. Facial ageing is influenced by lifestyle and may be accelerated by external factors such as cigarette smoking, sleeping position, chronic alcohol consumption, sun damage, medication or loss of weight (Taister et al. 2000). These changes are also related to genetic factors, skin type, face shape and subcutaneous fat levels. Even if the accurate age of the individual is known, it is impossible to predict the surface texture of the face with any degree of reliability. This makes the reconstruction of the facial surface very difficult, with increased error related to increased age.

In conclusion, the majority of facial feature morphology (at least 67% according to the study by Wilkinson et al. 2006) can be determined following scientific procedure, with lip and ear shapes the most difficult features to determine reliably. The skin layer in a child or young adult may be determined reliably, but as the adult age increases, the degree of artistic interpretation increases with respect to surface texture. From teaching experience it is clear that this is the most difficult stage of the reconstruction process to learn, and success is related to sculptural experience.

### **Stage 3: depiction of the face for presentation to the public**

Forensic facial reconstructions may be presented to the general public using a variety of skin textures, colours, hairstyles

and personal effects. Research suggests that different surface detail, such as hairstyle (Wright & Sladden, 2003), glasses and facial hair (Lewis & Johnson, 1997), can have an alarmingly strong effect upon recognition levels. It has also been shown that we find faces more difficult to recognize without surface detail and colour (Bruce et al. 1991).

However, the amount of known surface detail regarding the identity of the individual will be different for each investigation. Although most forensic cases that involve facial reconstruction start with little information other than skeletal material, some scenes will reveal extra details regarding the appearance of the deceased, such as facial hair, skin colour, eye colour, hair or clothing. Even where some details are known, the exact appearance of the individual feature will still be uncertain. For example, it may be known that the individual has white skin, but the range of white skin is wide, from milky-white and freckled to olive-toned. Similarly, the person may have dark brown, shoulder-length, straight hair, but the exact style or way that this was worn will be uncertain. These variations may have a great effect upon resemblance and recognition. In addition, characteristic facial appearance is often related to facial expression (Landau, 1989), which cannot be determined from the skeletal structure. Facial expression may also be inappropriate in forensic investigations or certain archaeological cases.

### **Archaeological investigations**

Archaeological investigations provide challenging facial analysis opportunities to depict faces from the past, to show the public how these ancient people looked and to enable comparison with contemporary faces (Prag & Neave, 1997). They may also provide different types of material compared to forensic investigations and the amount of artistic interpretation may be greater, depending on the level of preservation. In forensic cases it is preferable to include only appearance details that have been ascertained directly from scene evidence, and not to estimate any unknowns, as incorrectly estimated details may confuse and discourage recognition and identification (Wilkinson, 2004). However, in archaeological investigations recognition of the face is rarely the primary objective and producing the most likely depiction may be more important than individual identity. In these cases the archaeologist will suggest the most probable hairstyle, hair colour, skin colour and eye colour from historical textual and pictorial evidence.

### **The depiction of preserved bodies**

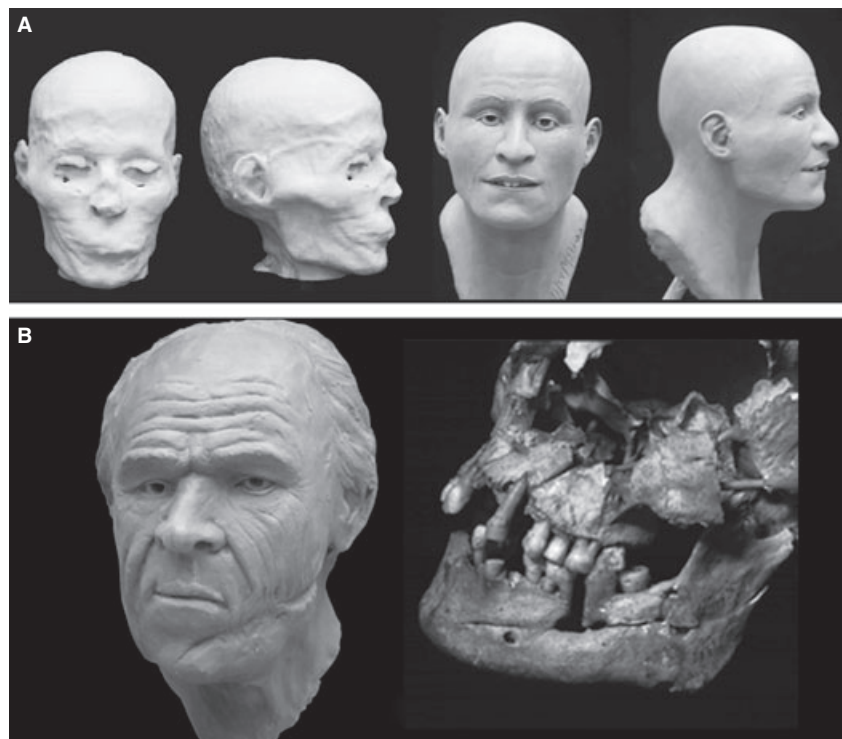
Ancient Egyptians have provided a rich source for analysis, as the mummification process preserves (with some modification) the soft tissues of the face as well as the skeletal material. The development of clinical imaging has allowed the non-invasive analysis of the soft and hard tissues of

the faces of Ancient Egyptians. Cross-sectional data created by computed tomography (CT) can be employed to produce a three-dimensional digital model of the skull (Spoor et al. 2000) and replica skulls may be produced from digital data using stereolithography (Hjalgrim et al. 1995) or another form of three-dimensional model manufacture (Seitz et al. 2005). Digital 3D models of the skull can also be imported into computer-based facial reconstruction systems. Examples of such work include the facial reconstruction of Tut Ankh Amun (Gatliff, 2001; Handwerk, 2005), Nesperrenub (Taylor, 2004) and Janus (Tukker & Dassen, 1999).

Often the assessment of mummified soft tissues will reveal details of facial morphology that cannot be determined from the skeleton alone (Fig. 9A), increasing the reliability and reducing the artistic interpretation of the facial reconstruction. Frequently, the ears will be preserved and it may be possible to determine ear shape, size and detail directly from the mummy (Taylor, 2004). Similarly the hair line and lip pattern may be visible, details that require artistic interpretation in many facial reconstructions. Shrinkage, distortion and the effects of the mummification procedure must be considered, as these may affect the soft tissue appearance: many facial features will be distorted by the bandages, the nose may be distorted by brain removal and the eyes sunken due to post-mortem changes (Aufderheide, 2003). For example, the large majority of Egyptian mummies appear to exhibit hooked noses in profile, yet this is typically a bandage distortion rather than the actual profile

of the nose, and experienced practitioners will recognize this phenomenon (Cesarani et al. 2004).

The facial appearance of bog bodies has been of great interest since the earliest discoveries, as the soft tissues are preserved by the acidity of the peat bog environment (Asingh & Lynnerup, 2007). This can lead to the incredible preservation of the faces of bog bodies, although there may be severe distortion due to the pressure of the burial environment. Where there is distortion of the soft tissues it can be difficult to visualize facial features and proportions, and in these circumstances facial reconstruction has been utilized (Prag & Neave, 1997, Chap. 8, Bergen et al. 2002). CT imaging allows visualization of the skull but the acidic conditions of the peat bog cause deterioration of the bone surface and this, in combination with any distortion, makes skeletal assessment for facial reconstruction difficult. However, the lack of skeletal detail is more than compensated by the enormous amount of preserved facial morphology, and the facial reconstruction of bog bodies will be carried out primarily from the information provided by the soft tissue material (Wilkinson, 2007). As with mummies the ears will often be preserved and it may be possible to determine ear shape, size, protrusion and detail directly. Similarly, the vermilion line, hair line and facial wrinkle patterns may be visible, details that require artistic interpretation in many facial reconstructions (Wilkinson, 2009). Grauballe Man and Clonycavan Man are examples of such work (Wilkinson, 2007, 2009). Along with facial morphology detail, bog bodies often exhibit additional information regarding the



**Fig. 9** Facial reconstruction of an Egyptian mummy (A) and depicting trauma (B). 12th Dynasty Ancient Egyptian Priest (A) – the 3D replica of the soft tissues of an Egyptian mummy (left) produced by stereolithography from the CT scan data and the resulting facial reconstruction (right) – courtesy of the National Museum of Scotland. The facial reconstruction of a soldier from the 1996 Towton Battle collection (B) at the University of Bradford showing a healed sword wound to his lower jaw (left). The healed skeletal trauma can be seen on the right – courtesy of the University of Bradford.

hairstyle, hair colour and facial hair (Wilkinson, 2009), decreasing the artistic interpretation of the reconstruction further and increasing its reliability.

### The depiction of disease and trauma

Archaeological cases can be challenging as the skeletal remains may exhibit certain pathological conditions, facial deformity or facial wounds. Where this is evident, the technique of facial reconstruction can be a valuable tool to help establish facial appearance relating to medical treatment, ancient disease processes and hereditary conditions. Where facial trauma was peri-mortem, it is usually inappropriate for the reconstruction to demonstrate any resulting wounds. Where the wounds show signs of healing it may be appropriate to demonstrate the soft tissue scarring as part of the reconstruction. The first facial reconstruction case that involved facial trauma was of Philip II Macedon from 250 BC ancient Greece (Prag & Neave, 1997), showing a well-healed wound to the right eye.

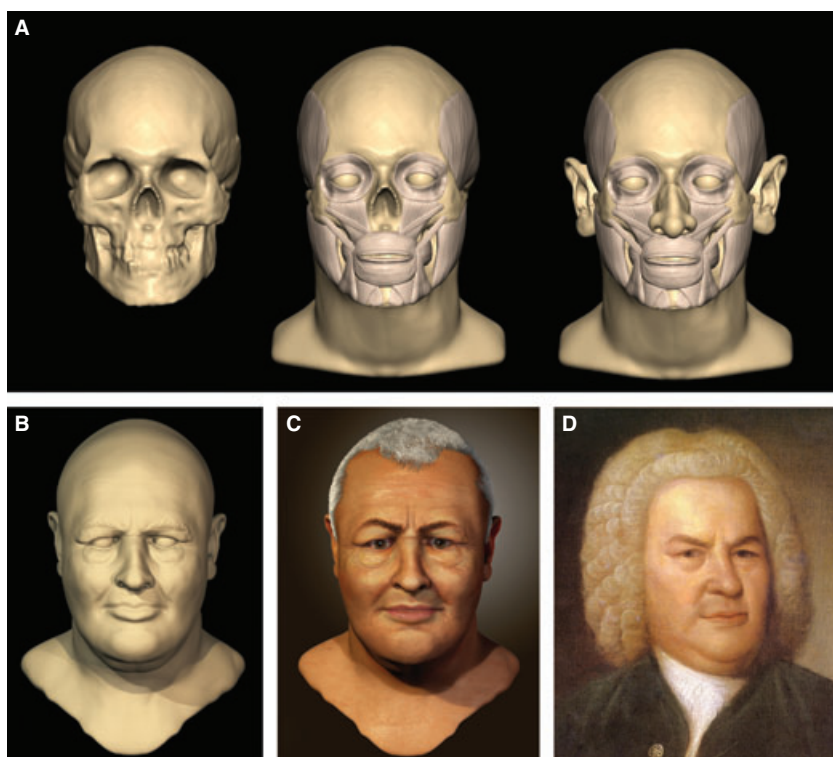A more recent example can be seen in the case of a soldier (number 16) from the Battle of Towton (Fig. 9B). His remains are part of the 1996 Towton Battle collection of 37 skeletons from the University of Bradford (Fiorato et al. 2000). The skull exhibited a well-healed blade injury to the left mandibular corpus. The blade wound had penetrated the lingual surface of the corpus, removing the apex of the first molar and impacting the internal surface of the right mandibular corpus. A gaping hole remained between the

left first and second molars where the bone had been removed. All margins of the wound were well healed and exhibited no evidence of infection. The reconstruction was produced demonstrating this healed wound, as it would have greatly altered the soldier's living facial appearance, with the resulting scar tissue distorting the left side of the face to a significant degree. In addition, he may have suffered eating and talking difficulties and some problems with mouth closure on the left side, leading to dribbling and a drooping of the left mouth corner (Wilkinson & Neave, 2003).

Reconstructions depicting pathological conditions can provide useful information for comparison with contemporary populations and reconstructions have been produced of individuals with meningioma hyperostosis and a haemangioma (Wilkinson, 2008). These reconstructions provide more detail regarding the surface detail of the face, and in this way can be considered to involve increased scientific evaluation. However, the interpretation of trauma and disease, although based on science, may still be considered to include an element of artistic estimation.

### The use of portraits for surface detail

Occasionally portraits may be available for use as reference material for the addition of surface detail, such as fatness, age-related changes, skin colour, eye colour, hairstyle and colour and facial hair. In these circumstances the resulting facial reconstructions can be considered more reliable in



**Fig. 10** The facial reconstruction of Johann Sebastian Bach. The computerized facial reconstruction (A) utilized a 3D model of the skull from laser scan data. Texture was added to the resulting face (B) using the Haussmann 1746 portrait (D) as reference material regarding the degree of fatness, eye condition, skin colour, eye colour and skin textures (C). Courtesy of the Bachhaus, Eisenach, and Dr Caroline Wilkinson & Janice Aitken, University of Dundee.

terms of resemblance. Usually the facial reconstruction process from skull to face is carried out blind to the portrait and then the surface detail is added to depict the face from the past more reliably.

Examples of the use of portraiture for surface detail are the facial reconstructions of Ancient Egyptian mummies with related portraits. The portraits (Fayuun portraits) all date from the 1st to 2nd centuries AD and were produced using an encaustic technique (Walker, 1997). These portraits have been analysed by Egyptologists to determine hairstyles, jewelry, fashion and social status. It has been estimated that there are more than 1000 mummy portraits, but fewer than 100 are still bound into their mummies. Several mummies with portraits have been studied (Wilkinson, 2003b; Prag, 2002; Brier & Wilkinson, 2005) and, in all cases, following a resemblance assessment, the portraits were used to apply additional surface detail to the reconstructions.

A recent study of the skull of Johann Sebastian Bach (1685–1750), the famous German composer and organist, included the assessment of a known portrait of Bach for additional surface information (Hansen, 2008). Bach was known to have sat for the painter Elias Gottlob Haussmann in 1746, a few years before his death (Müller, 1935). Haussmann (1695–1774) served as court painter at Dresden, and from 1720 as the official portraitist at Leipzig. The facial reconstruction was produced as a 3D computerized model using a laser scan of the bronze copy of the skull of Bach provided by the Bachhaus, Eisenach (Fig. 10). The skull suggested a middle-aged man with a large nose, strong chin and under-bite. Tissue depth data from contemporary German men in their 60s were employed for the reconstruction (Helmer, 1984), but the degree of fatness to the face was directly influenced by the Haussmann portrait. Records of Bach's life suggest that he had eye problems that left him with swollen, sore lids and the portrait depicted this affliction (David & Mendel, 1945; Zegers, 2005). The eye detail, eye colour, skin colour and facial ageing details were determined from the portrait (Fig. 10). The combination of skeletal assessment and portrait evaluation presents a facial depiction of Bach that can be considered as accurate as is possible with the material available (Hansen, 2008).

## Conclusions

Sculptural skills are clearly useful when reconstructing the musculature of the face, but where anatomical accuracy is achieved the reconstruction process should involve no artistic interpretation and the procedure is reproducible. Determination of facial feature morphology should follow scientific procedure, except for the lips and ears, which require a degree of artistic interpretation. The skin layer in a child or young adult can be determined relatively reliably, but the degree of artistic interpretation of surface texture increases with increasing adult age. More artistic licence

may be appropriate in archaeological reconstructions than in a forensic investigation, as recognition of the face is rarely the primary objective and producing the most likely depiction may be more important than individual identity. Some archaeological investigations may provide additional facial appearance information from preserved soft tissues, portraits or pathological conditions.

## Acknowledgements

Thanks to the National Museum of Scotland, Jörg Hansen at the Bachhaus, the University of Bradford, Prof. Stephen Richmond at Cardiff Dental School and the FBI Academy, USA. Special thanks to Dr Chris Rynn, Janice Aitken and Caroline Needham.

## References

- Algemeen** (2009) *Vader Maasmeisje overleden in gevangenis*. Published 12 May 2009. Available at: <http://translate.google.co.uk/translate?hl=en&sl=nlandu=http://www.nu.nl/algemeen/1962980/vader-maasmeisje-overleden-in-gevangenis.html&ei=Ga6fSsemJNrTjAeRyfmXDgandsa=Xandoi=translate&resnum=7&act=result&prev=/search%3Fq%3Dmaasmeisje%26hl%3Den%26sa%3DX>.
- Angel JL** (1978) Restoration of head and face for identification. *Proceedings of Meetings of American Academy of Forensic Science*, St. Louis, MO.
- Asingh P, Lynnerup N** (2007) *Grauballe Man – An Iron Age Bog Body Revisited*. Moesgaard: Jutland Archaeological Society.
- Aufderheide AC** (2003) *The Scientific Study of Mummies*. Cambridge: Cambridge University Press.
- Auslebrook WA, Becker PJ, Iscan MY** (1996) Facial soft tissue thicknesses in the adult male Zulu. *Forensic Sci Int* **79**, 83–102.
- Ballestriero R** (2010) Anatomical models and wax Venuses: art masterpieces or scientific craft works? *J Anat* **216**, 223–234.
- Bergen C, Niekus MJLT, van Vilsteren VT** (2002) *The Mysterious Bog People*. Zwolle: Waanders Publishers.
- Black S, Thompson T** (2006) *Forensic Human Identification – An Introduction*. Boca Raton: CRC Press.
- Bodic F, Hamel L, Lerouxel E, et al.** (2005) Bone loss and teeth. *Joint Bone Spine* **72**, 215–221.
- Brier B, Wilkinson CM** (2005) A preliminary study on the accuracy of mummy portraits: Hierzu Tafel XXIII–XXIX. *Z Aegypt Sprach Altertumskd* **132**, 107–111.
- Bron AJ, Tripathi R, Warwick R, et al. (eds) (1997) *Wolff's Anatomy of the Eye and Orbit: Comparative Anatomy of the Visual Apparatus*. London: Hodder Arnold Publishers.
- Bruce V, Young A** (1986) Understanding face recognition. *Br J Psychol* **77**, 305–327.
- Bruce V, Young A** (1998) *In the Eye of the Beholder – The Science of Face Perception*. Oxford: Oxford University Press.
- Bruce V, Healey P, Burton M, et al.** (1991) Recognising facial surfaces. *Perception* **20**, 755–769.
- Bruce V, Henderson Z, Greenwood K, et al.** (1999) Verification of face identities from images captured on video. *J Exp Psychol Appl* **5**, 339–360.
- Brues AM** (1958) Identification of skeletal remains. *J Crim Law Crim Pol Sci* **58**, 551–563.
- Burton AM, Wilson S, Cowan M, et al.** (1999) Face recognition in poor quality video. *Psychol Sci* **10**, 243–248.

- Caldwell MC** (1981) *The relationship of details of the human face to the skull and its application in forensic anthropology*. Masters Thesis, Arizona State University.
- Cesarani F, Martina MC, Grilletto R, et al.** (2004) Facial reconstruction of a wrapped Egyptian mummy using MDCT. *Am J Roentgenol* **183**, 755–758.
- Clement JG, Ranson DL** (1997) *Craniofacial Identification in Forensic Medicine*. Sydney: Arnold Publishers.
- David HT, Mendel A** (1945) *The Bach Reader: A Life of Johann Sebastian Bach in Letters and Documents*. New York: WW Norton and Co. Inc.
- De Ceglia FP** (2005) The rotten, the disemboweled woman, the skinned man. *J Sci Commun* **4**, 1–7.
- Denis LK, Speidel TM** (1987) Comparison of three methods of profile change prediction in the adult orthodontic patient. *Am J Orthod Dentofacial Orthop* **92**, 396–402.
- El-Mehallawi IH, Soliman EM** (2001) Ultrasonic assessment of facial soft tissue thicknesses in adult Egyptians. *Forensic Sci Int* **117**, 99–107.
- Evans MBEJ, Copp L** (1986) The histology of tendon attachments to bone in man. *J Anat* **149**, 89–100.
- Fiorato V, Boylston A, Knusel C** (2000) *Blood Red Roses*. Oxford: Oxbow Books Publishers.
- Freedman AD** (1996) *Death and Dying*. The 1996 Grolier Multimedia Encyclopaedia.
- Gatliff BP** (2001) Facial reconstruction of Tut Ankh Amun. In *Forensic Art and Illustration* (ed. Taylor KT), pp. 466–467, Boca Raton: CRC Press.
- Gatliff BP, Snow CC** (1979) From skull to visage. *J Biocommun* **6**, 27–30.
- George RM** (1993) Anatomical and artistic guidelines for forensic facial reconstruction. In *Forensic Analysis of the Skull* (eds Iscan MY, Helmer RP), pp. 215–227, New York: Wiley Liss Inc.
- Gerasimov MM** (1955) *The Reconstruction of the Face from the Basic Structure of the Skull*, translator W. Tshernezky, Russia: Publishers unknown.
- Gerasimov MM** (1971) *The Face Finder*. New York: Lippincott.
- Glanville EV** (1969) Nasal shape, prognathism and adaptation in man. *Am J Phys Anthropol* **30**, 29–38.
- Goldstein SA** (1992) Clinical applications of bone remodelling dynamics. In: *Bone Biodynamics in Orthodontic and Orthopaedic Treatment* (eds Carson DS, Goldstein DS), Monograph No 27, Craniofacial Growth Series Centre for Human Growth and Development, pp. 51–73, Ann Arbor: University of Michigan.
- Gonzalez-Ulloa M, Flores ES** (1965) Senility of the face – basic study to understand its causes and effects. *Plast Reconstr Surg* **36**, 239–246.
- Gordon I, Shapiro HA** (1975) *Forensic Medicine: A Guide to the Principles*. Edinburgh: Churchill Livingstone.
- Gray L** (1965) The deviated septum – aetiology. *J Laryngol Otol* **79**, 567–575.
- Haglund WD, Raey DT** (1991) Use of facial approximation in identification of Green River serial murder victims. *Am J Forensic Med Pathol* **12**, 132–142.
- Handwerk B** (2005) King Tut's new face: behind the forensic reconstruction. *National Geographic* May 11.
- Hansen J** (2008) *Bach through the Mirror of Medicine*. Exhibition catalogue. Eisenach: Bachhaus.
- Helmer R** (1984) *Schädelidentifizierung durch elektronische Bildmischung*. Heidelberg: Kriminalistik-Verlag.
- Helmer R, Rohricht S, Petersen D, et al.** (1989) Plastische Gesichtsrekonstruktion als Möglichkeit der Identifizierung unbekannter Schädel (II). *Arch Kriminol* **184**, 142–160.
- Hill I** (2006) Physical appearance. In *Forensic Human Identification – An Introduction* (eds Black S, Thompson T), Chapter 5, pp. 365–378, Boca Raton: CRC Press.
- Hjalgrim H, Lynnerup N, Liversage M, et al.** (1995) Stereolithography: potential applications in anthropological studies. *Am J Phys Anthropol* **97**, 329–333.
- Holdaway RA** (1983) A soft tissue cephalometric analysis and its use in orthodontic treatment planning. Part I. *Am J Orthod* **84**, 1–28.
- Hu KS, Jin GC, Youn KH, et al.** (2008) An anatomic study of the bifid zygomaticus major muscle. *J Craniofac Surg* **19**, 534–536.
- Inoue N** (1993) Collapse of dentition in Japan. In: *Culture of Food and Oral Health in Maori* (ed. Inoue N), pp. 67–77, Tokyo: Therapeia Publishing Co.
- Ito G** (1993) Basic and clinical considerations on the development of masticatory function and occlusion. *J Tohoku Orthodont Soc* **1**, 1–17.
- Kahler K, Haber J, Seidel HP** (2003) Reanimating the dead: reconstruction of expressive faces from skull data. *ACM/SIGGRAPH Computer Graphics Proceedings* **22**, 554–567.
- Kemp R, Towell N, Pike G** (1997) When seeing should not be believing: photographs, credit cards and fraud. *Appl Cogn Psychol* **11**, 211–222.
- Khalil AK, Kubota T, Tawara A, et al.** (1996) Ultrastructural age-related changes on the posterior iris surface. A possible relationship to the pathogenesis of exfoliation. *Arch Ophthalmol* **114**, 721–725.
- Kiliaridis S, Kalebo P** (1991) Masseter muscle thickness by ultrasonography and its relation to facial morphology. *J Dent Res* **70**, 1262–1265.
- Koch R, Gonzales A, Witt E** (1979) Profile and soft tissue changes during and after orthodontic treatment. *Eur J Orthod* **1**, 193–199.
- Krogman WM, İscan MY** (1986) *The Human Skeleton in Forensic Medicine*. Springfield, IL: Charles C Thomas.
- Lain R, Griffiths C, Hilton JMN** (2003) Forensic dental and medical response to the Bali bombing – a personal perspective. *Med J Aust* **179**, 362–365.
- Landau T** (1989) *About Faces – The Evolution of the Human Face*. New York: Bantam Doubleday Dell Publishing Group Inc.
- Lebedinskaya GU, Balueva TS, Veselovskaya EB** (1993) Development of methodological principles for reconstruction of the face on the basis of skull material. In: *Forensic Analysis of the Skull* (eds Iscan MY, Helmer RP), pp. 183–198, New York: Wiley-Liss Inc.
- Lewis MB, Johnson RA** (1997) Familiarity and false positives in face recognition. *Eur J Cogn Psychol* **9**, 437–459.
- Loth S, Iscan MY** (1994) Morphological indicators of skeletal aging: Implications for paleodemography and paleoerontology. In: *Biological Anthropology and Aging: Perspectives on Human Variation over the Life Span*, Chapter 15 (eds Crews DE, Garruto RM) New York: Oxford University Press.
- Macho GA** (1986) An appraisal of plastic reconstruction of the external nose. *J Forensic Sci* **31**, 1391–1403.

- Manhein MH, Barsley RE, Listi GA, et al.** (2000) In vivo facial tissue depth measurements for children and adults. *J Forensic Sci* **45**, 48–60.
- Maxwell A** (2001) Forensic sculptor brings the dead to life. USATODAY.com, PHILADELPHIA — No. 5233, <http://www.usatoday.com/careers/dream/2001-March-forensic-sculptor.htm>.
- McClintock Robinson J, Rinchosa DJ, Zullo TG** (1986) Relationship of skeletal pattern and nasal form. *Am J Orthod* **89**, 499–506.
- McMinn RMH, Hutchings RT, Logan BM** (1994) *Colour Atlas of Head and Neck Anatomy*, 2nd edn. London: Mosby-Wolfe Publishers.
- Merkel FB** (1887) Der musculus superciliaris. *Anat Anz* **11**, 17.
- Moss JP, Linney AD, Grindrod SR, et al.** (1987) 3-Dimensional visualisation of the face and skull using computerised tomography and laser scanning techniques. *Eur J Orthod* **9**, 247–253.
- Müller G** (1935) *Bach portraits*. The Musical Quarterly, Oxford: Oxford University Press.
- Neave RAH** (1998) Age changes in the face in adulthood. In *Craniofacial Identification in Forensic Medicine* (eds Clement JG, Ranson DL), pp. 215–231, Sydney: Arnold Publications.
- Novick NL** (1988) *Super Skin*. New York: Clarkson Potter.
- Orentreich DS** (1995) Skin. In *The Encyclopedia of Aging*, 2nd edn (ed. Maddox GL), pp. 611–612, New York: Springer.
- Paff GH** (1973) *Anatomy of the Head and Neck*. Philadelphia: W.B. Saunders Co.
- Pessa JE, Zadoo VP, Adrian EK, et al.** (1998a) Variability of the midfacial muscles: analysis of 50 hemifacial cadaver dissections. *Plast Reconstr Surg* **102**, 1888–1893.
- Pessa JE, Zadoo VP, Adrian EK, et al.** (1998b) Double or bifid zygomaticus major muscle: anatomy, incidence, and clinical correlation. *Clin Anat* **11**, 310–313.
- Phillips VM, Smuts NA** (1996) Facial reconstruction; utilisation of computerised tomography to measure facial tissue thickness in a mixed population. *Forensic Sci Int* **83**, 51–59.
- Phillips VM, Rosendorff S, Scoltz HJ** (1996) Identification of a suicide victim by facial reconstruction. *J Forensic Odontostomatol* **14**, 34–38.
- Policing Cardiff** (2005) A chronology of 50 years of policing Cardiff's Capital. Available at: <http://www.south-wales.police.uk/fe/master.asp?n1=8andn2=253andn3=1082> [accessed on 4 June 2009].
- Polson CJ, Gee DJ, Knight B** (1985) *The Essentials of Forensic Medicine*, 4th edn. Oxford: Pergamon Press.
- Prag AJNW** (2002) Proportion and personality in the Fayum Portraits. *BMSAES* **3**, 55–63 <http://www.thebritishmuseum.ac.uk/bmsaes/issue3/prag.html>.
- Prag J, Neave RAH** (1997) *Making Faces*. London: British Museum Press.
- Prokopec M, Ubelaker DH** (2002) Reconstructing the shape of the nose according to the skull. *Forensic Sci Commun* **4**, 1.
- Roos N** (1977) Soft tissue profile changes in Class II treatment. *Am J Orthod* **72**, 165–175.
- Rudee DA** (1964) Proportional profile changes concurrent with orthodontic therapy. *Am J Orthod* **50**, 421–434.
- Rynn C** (2006) *Craniofacial approximation and reconstruction: tissue depth patterning and the prediction of the nose*. PhD dissertation, University of Dundee.
- Rynn C, Wilkinson CM, Peters H** (2008) *Prediction of nasal morphology from the skull*. Presentation at the 13<sup>th</sup> Conference of the International Association of Craniofacial Identification (IACI), Dundee.
- Sahni D** (2002) Preliminary study on facial soft tissue thickness by magnetic resonance imaging in Northwest Indians. *Forensic Sci Commun* **4**, 1.
- Schultz AH** (1918) Relation of the external nose to the bony nose and nasal cartilages in whites and negroes. *Am J Phys Anthropol* **1**, 329–338.
- Seitz H, Tille C, Rieder W, et al.** (2005) *Rapid Prototyping Models for Facial Reconstruction*. Presented at the 2nd International Conference on Reconstruction of Soft Facial Parts (RSFP), Remageny.
- Selzter AP** (1944) The nasal septum: plastic repair of the deviated septum associated with a deflected tip. *Arch Otolaryngol* **40**, 433–444.
- Snow CC, Gatliff BP, McWilliams KR** (1970) Reconstruction of facial features from the skull: an evaluation of its usefulness in forensic anthropology. *Am J Phys Anthropol* **33**, 221–228.
- Spoor F, Jeffery N, Zonneveld F** (2000) Imaging skeletal growth and evolution. In *Development, Growth and Evolution: Implications for the Study of the Hominid Skeleton* (eds O'Higgins P, Cohn M), pp. 123–161, London: Academic Press.
- Stephan CN** (2002) Facial approximation: falsification of globe projection guideline by exophthalmometry literature. *J Forensic Sci* **47**, 1–6.
- Stephan CN** (2005) Anthropological facial reconstruction – recognizing the fallacies, unembracing the errors and realizing method limits. *Sci Justice* **43**, 193–200.
- Stephan CN, Arthur RS** (2006) Assessing facial approximation accuracy: How do resemblance ratings of disparate faces compare to recognition tests? *Forensic Sci Int* **159** (Suppl), 159–163.
- Stephan CN, Davidson PL** (2008) The placement of the human eyeball and canthi in craniofacial identification. *J Forensic Sci* **53**, 612–619.
- Stephan C, Henneberg M** (2001) Building faces from dry skulls: are they recognised above chance rates? *J Forensic Sci* **46**, 432–440.
- Stephan CN, Henneberg M** (2003) Predicting mouth width from inter-canine width – a 75% rule. *J Forensic Sci* **48**, 725–727.
- Stephan CN, Murphy SJ** (2008) Mouth width prediction in craniofacial identification: cadaver tests of four recent methods, including two techniques for edentulous skulls. *J Forensic Odontostomatol* **27**, 1.
- Stephan CN, Henneberg M, Sampson W** (2003) Predicting nose projection and pronasale position in facial approximation: a test of published methods and proposal of new guidelines. *Am J Phys Anthropol* **122**, 240–250.
- Subtelny JD** (1959) A longitudinal study of soft tissue facial structures and their profile characteristics, defined in relation to underlying skeletal structures. *Am J Orthod Dentofacial Orthop* **45**, 481–507.
- Suk V** (1935) Fallacies of anthropological identifications and reconstructions. *Publications de al Facultae des Sciences de l'Universitae Masaryk Brno* **201**, 3–18.
- Suzuki K** (1948) On the thickness of the soft parts of the Japanese face. *J Anthropol Soc Nippon* **60**, 7–11.
- Suzuki T** (1975) Reconstitution of a skull. *Int Crim Police Rev* **28**, 76–80.

- Taister MA, Holliday SD, Borrmann HIM** (2000) Comments on facial aging in law enforcement investigation. *Forensic Sci Comm* **2**, no. 2.
- Takema Y, Yorimoto Y, Kawai M, et al.** (1994) Age-related changes in the elastic properties and thickness of human facial skin. *Br J Dermatol* **131**, 641–648.
- Talass MF, Talass L, Baker RC** (1987) Soft-tissue profile changes resulting from retraction of maxillary incisors. *Am J Orthod Dentofacial Orthop* **5**, 385–394.
- Tandler J** (1909) Über den Schädel Haydns. *Mitteilungen der Anthropologie Gesellschaft Wien* **39**, 260–280.
- Taylor K** (2001) *Forensic Art and Illustration*. Boca Raton: CRC Press.
- Taylor JH** (2004) *Mummy: The Inside Story*. London: British Museum Press.
- Tukker W, Dassen H** (1999) Mummie – scannen door de eeuwen heen. *Triakel*, **17 Dec**, 14–17.
- Van den Eerenbeemt M** (2001) 'Van Nulde' krijgt gezicht. De Volkskrant, Published on October 16, 2001, updated on 20 January 2009; [http://www.volkskrant.nl/archief\\_gratis/article\\_907549.ece/Meisje\\_van\\_Nulde\\_krijgt\\_gezicht](http://www.volkskrant.nl/archief_gratis/article_907549.ece/Meisje_van_Nulde_krijgt_gezicht).
- Vanezis P, Blowes RW, Linney AD, et al.** (1989) Application of 3D computer graphics for facial reconstruction and comparison with sculpting techniques. *Forensic Sci Int* **42**, 69–84.
- Vaughan B** (2004) Man of the month: Frank Bender. *Esquire* magazine, April 1.
- Virchow H** (1912) *Die anthropologische Untersuchung der Nase*. *Z Ethnol* **44**, 289–337.
- Waldman BH** (1982) Change in lip contour with maxillary incisor retraction. *Angle Orthod* **52**, 129–134.
- Walker S** (1997) *Ancient Faces – Mummy Portraits from Roman Egypt*. Metropolitan Museum of Art Publications. New York: Routledge.
- Warwick R, Williams PI (eds) (1973) *Gray's Anatomy*, 35th edn. London: Longman Publishers.
- Weaver DF, Bellinger DH** (1946) Bifid nose associated with midline cleft of the upper lip. *Arch Otolaryngol* **44**, 480–482.
- Whitnall SE** (1912) The naso-lacrimal canal: the extent to which it is formed by the maxilla, and the influence of this upon its calibre. *Ophthalmoscope* **10**, 557–558.
- Whitnall SE** (1921) *The Anatomy of the Human Orbit and Accessory Organs of Vision*. Oxford Medical Publications. London: Henry Frowde.
- Wilkinson CM** (2002) In vivo facial tissue depth measurements for White British children. *J Forensic Sci* **47**, 459–465.
- Wilkinson CM** (2003a) 'Virtual' sculpture as a method of computerised facial reconstruction. *Proceedings of the 1st International Conference on Reconstruction of Soft Facial Parts (RSFP)*, Potsdam, 59–63.
- Wilkinson CM** (2003b) *The Facial Reconstruction of the Marina El-Alamein Mummy*. *Polish Archaeology in the Mediterranean XIV Reports 2002*. Warsaw University, 66–71.
- Wilkinson CM** (2004) *Forensic Facial Reconstruction*. Cambridge: Cambridge University Press.
- Wilkinson CM** (2006) Facial anthropology and reconstruction. In *Forensic Human Identification* (eds Thompson TJK, Black S), Chapter 7, pp. 231–256, Boca Raton: CRC Press.
- Wilkinson CM** (2007) The facial reconstruction of Grauballe man. In *Grauballe Man – An Iron Age Bog Body Revisited* (eds Asingh P, Lynnerup N), Chapter 19, pp. 260–273, Moesgaard: Jutland Archaeological Society.
- Wilkinson CM** (2008) The facial reconstruction of ancient Egyptians. In *Egyptian Mummies and Modern Science* (ed David R), Chapter 11, pp. 162–180, Cambridge: Cambridge University Press.
- Wilkinson CM** (2009) The facial analysis of Clonycavan man. In *Bog Bodies Research project, Monograph Publication*, Chapter 14. Dublin: National Museum of Ireland. In Press.
- Wilkinson CM, Mautner SA** (2003) Measurement of eyeball protrusion and its application in facial reconstruction. *J Forensic Sci* **48**, 4.
- Wilkinson CM, Neave RAH** (2003) The reconstruction of faces showing healed wounds. *J Archaeol Sci* **30**, 1343–1348.
- Wilkinson CM, Whittaker DK** (2002) Juvenile forensic facial reconstruction – a detailed accuracy study. *Proceedings of the 10<sup>th</sup> Meeting of the International Association of Craniofacial Identification*, Bari, 98–110.
- Wilkinson CM, Motwani M, Chiang E** (2003) The relationship between the soft tissues and the skeletal detail of the mouth. *J Forensic Sci* **48**, 1–5.
- Wilkinson CM, Rynn C, Peters H, et al.** (2006) A blind accuracy assessment of computer-modelled forensic facial reconstruction using Computed Tomography data from live subjects. *J Forensic Sci Med Pathol* **2**, 179–187.
- Wright DB, Sladden B** (2003) An own gender bias and the importance of hair in face recognition. *Acta Psychol* **114**, 101–114.
- Zegers RHC** (2005) The eyes of Johann Sebastian Bach. *Arch Ophthalmol* **123**, 1427–1430.