



**Research Paper**

*Afr. J. Traditional,  
Complementary and  
Alternative Medicines*  
[www.africanethnomedicines.net](http://www.africanethnomedicines.net)

**ISSN 0189-6016©2007**

ACUTE AND SUBCHRONIC TOXICITY OF *ANACARDIUM OCCIDENTALE* LINN (ANACARDIACEAE) LEAVES HEXANE EXTRACT IN MICE.

**Léonard Tédong<sup>a,\*</sup>, Paul Désiré Djomeni Dzeufiet<sup>a</sup>, Théophile Dimo<sup>a</sup>, Emmanuel Acha Asonalem<sup>d</sup>, Selestin Ndogmo Sokeng<sup>c</sup>, Jean-François Flejou<sup>b</sup>, Patrice Callard<sup>c</sup>, Pierre Kamtchouing<sup>a</sup>**

<sup>a</sup>Department of Animal Biology and Physiology, Faculty of Science, University of Yaounde I. P.O. Box 812 Yaounde, Cameroon, <sup>b</sup>Laboratoire d'Anatomie et Cytologie Pathologiques, Hôpital Saint-Antoine Université Pierre et Marie Curie, France., <sup>c</sup>Department of Biological Science, Faculty of Science, University of Ngaoundere, Ngaoundere- Cameroon., <sup>d</sup>Department of Physiology, Faculty of Medicine and Biomedical Sciences, University of Yaounde I, Cameroon., <sup>e</sup>Laboratoire d'Anatomie et Cytologie Pathologiques, Hôpital de Tenon, Université Pierre et Marie Curie, France  
E-mail: [ltedong@yahoo.fr](mailto:ltedong@yahoo.fr)

## Abstract

These studies focus on the toxicity leaf hexane extract of *A. occidentale* L (*Anacardiaceae*) used in Cameroon traditional medicine for the treatment of diabetes and hypertension. Previous findings on antidiabetic and anti-inflammatory have given support to the ethnopharmacological applications of the plant. After acute oral administration, it was found that doses of the extract less than 6 g/kg are not toxic. Signs of toxicity at high doses were asthenia, anorexia, diarrhoea, and syncope. The LD<sub>50</sub> of the extract, determined in mice of both sexes after oral administration was 16 g/kg. In the subchronic study, mice received *A. occidentale* at doses of 6, 10 and 14 g/kg (by oral route) for 56 days. At doses of 2, 6 and 10 g/kg of extract, repeated oral administration to mice produced a reduction in food intake, weight gain, and behavioural effects. Liver or the kidney function tests were assessed by determining serum parameters like, creatinine, transaminases, and urea. All these parameters were significantly ( $p < 0.01$ ) abnormal. Histopathological studies revealed evidence of microscopic lesions either in the liver or in the kidney which may be correlated with biochemical disturbances. We conclude that toxic effects of *A. occidentale* L hexane leaf extract occurred at higher doses than those used in Cameroon folk medicine.

**Keys words:** Toxicity, *Anacardum occidentale*, Hexane extract, mice.

## Introduction

In recent years, an increasing percentage of people from industrialized countries have been using complementary and alternative medicines (CAM). This, combined with numerous warnings regarding the potential toxicity of these therapies, suggests the need for practitioners to keep abreast of the reported incidence of renal and hepatic toxicity caused by the ingestion of medicinal herbs. Although, poisonous plants are ubiquitous (Jaouad et al., 2004), herbal medicine is used by up to 80% of the population in the developing countries. Extracts from roots, stems and fruits of *Anacardium occidentale* L., (Sokeng et al., 2001) have been used by the Cameroonian and other countries' folk medicine. *A. occidentale* is one of the over 700 plants described to be beneficial in the treatment of diabetes mellitus (Day, 1995). In the traditional Nigerian and Brazilian pharmacopoeia, stem-bark of *A. occidentale* L. is known for its inflammatory effects (Mota et al., 1985; Ojewole, 2004). Importantly, *A. occidentale* L., have been shown to display a wide spectrum of biological activities, with experimental support for the empiric ethnopharmacological use of this plant in folk medicine. Mendes et al. (1990) reported that hexane extract of *A. occidentale* (cashew) nut shells in Brazil as a molluscicide. Recently, we have demonstrated renal protective effects of hexane leaf extract of *A. occidentale*

in diabetic rats (Tedong *et al.* 2006). However the toxicity of *A. occidentale* L. has not been extensively studied. Paris *et al.*, (1977) observed no toxic effects in mice treated with aqueous extracts of *A. occidentale* at doses of up to 2g/kg by oral route while the same extract taken by i.p. route showed that LD<sub>50</sub> is 0.250 g/kg.

Taking into account these data, we have conducted our research on acute and sub-acute toxicity after oral administration of hexane leaf extract of *Anacardium occidentale* L. in mice. Such extracts has been shown to exhibit antibiotic and antidiabetic activities.

## Material and Methods

### Plant material

Leaves of *A. occidentale* were collected in January 2003 and were authenticated at the national herbarium (Yaounde-Cameroon), voucher specimen (N° 41935 /HNC). The plant leaves were dried in the laboratory at room temperature and powdered in a mixer grinder. 3 kg of powder-dried plant was macerated in 8 L of methanol at room temperature. After filtration, the solution was concentrated under reduced pressure. The resulting extract (262 g) was eluted in hexane (1 L) and concentrated to dryness to obtain a mass of hexane extract (55 g) with the extraction yield of 1.83%. 25 g of this extract was dissolved in 5 mL of dimethyl sulfoxide (DMSO) and solution adjusted to 45 mL with distilled water to obtain a solution of 50 mL (25 g/50 mL). This was the stock solution for the tests. For a dose of 6 g/kg, the hexane extract of leaves of *A. occidentale* was administered as a constant volume of 0.24 mL. For each other dose used, we calculated the volume to be administered as follows:

$$V \text{ (mL)} = \frac{D \times P}{C}$$

D: Dose used (g/kg body weight)  
P: Body weight (g)  
C: Concentration (g/mL)  
V: Volume

### Animals

The experimental animals used in this study were Swiss albino mice of both sexes each weighing 20-30g and aged 8-10 weeks. The animals were randomly distributed into group of 10 animals per dose per cage with free access to water and food except for the short fasting period before oral administration of doses of extract. All animals (mice) were maintained on a 12 h light/dark cycle, at constant temperature and humidity. The study was approved by the institution's animal Ethical Committee.

### Acute toxicity

In order to study any possible toxic effect or changes in normal behaviour, seven groups of 10 rats (5 males and 5 females) were used in this experiment. The acute toxicity of the plant was studied by preparing seven different concentrations of the extract (2, 6, 10, 14, 18, 22, and 26 g/ b.w), and administered orally to seven groups of animals. The eight group was taken as a control and given diluted solution (DMSO in water). The symptoms of toxicity such as asthenia, hypoactivity (motor activity), anorexia, diarrhoea and syncope were checked. Survival animals were kept under observation for 7 days.

### Chronic toxicity

Four groups of 10 mice (5 males and 5 females) were kept under the same conditions as above. The first group was given diluted solution and taken as the control. The second group was given 6, 10 and 14 g/kg b.w. of the *A. occidentale* hexane extract daily for 8 weeks (56 days) by oral route. At the end of the experimental period, the animals were killed by decapitation and blood samples were collected. The plasma was used for biochemical plasma analysis. Total protein (Gornal *et al.*, 1949), serum creatinine (Bartels H. and Bohmer, 1972), aspartate amino tranferase, (IFCC, 1975) alanine aminotransferase (ALT) (IFCC,1980), and urea (Bolleter *et al.*, 1961) were determined using specific kits and measurement of optical density with spectrophotometer (Perkin-Elmer, Lambda 1).

For histological studies, liver and kidneys were dissected out, freed from adjoining fatty and mesenteric tissues. Portions of each organ were removed and weighed for histological study using haematoxylin-eosin, PAS and Mason's trichrome techniques.

### Statistical analysis

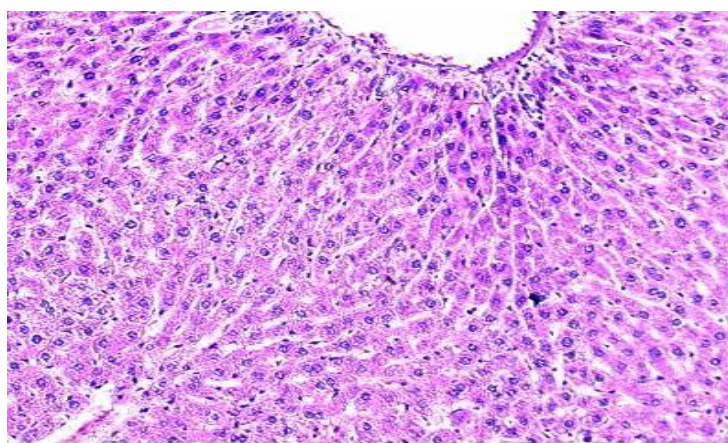
The results are reported as mean  $\pm$  SEM. Statistical analysis was carried out using analysis of variance

(ANOVA). The difference of the means was calculated using Kruskal-Willis test. P values of less than 5% was considered statistically significant ( $P < 0.05$ ).

## Results

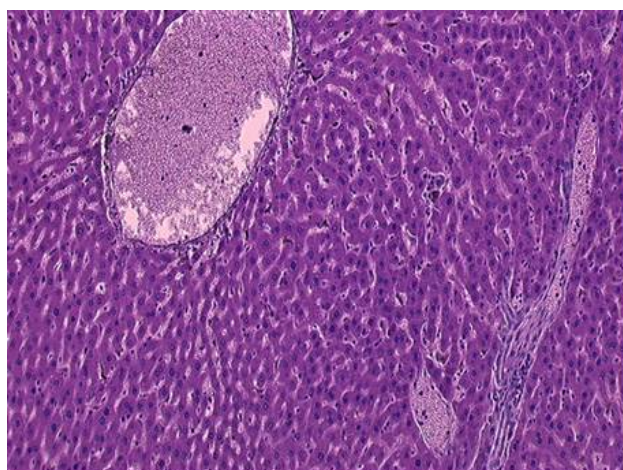
### Acute toxicity

There were no deaths or any signs of toxicity observed after oral administration of single doses of *A. occidentale* hexane extract up to 14 g/kg. However, the mortality rate increased progressively with increasing dose (Table 1). The mortality rate of 0% at 2 g/kg up to a dose of 14 g/kg gradually rose to 100% at 26 g/kg. Some adverse effects, such as hypoactivity (reduction of motor activity), asthenia, and anorexia were seen after the dose of 18 g/kg immediately after oral administration, while others (diarrhoea, sedation and syncope) were observed later and were more pronounced at higher doses (22 and 26 g/kg) and persisted until death (1 h after treatment). The LD50 of *A. occidentale* hexane leaf extract determined in mice of both sexes after acute oral administration was 16 g/kg, p.o. 48 hours.



**A:** Liver section from control mice (PAS x 100).

Typical normal portal area (P) with portal vein (PV) and hepatic artery (HA). Hepatic lobule with central vein (C). Les hépatocytes sont bordés par des capillaires sinusoides (Cs).



**B:** Liver section from a mouse treated with 14 g/kg/j body weight (B) of hexane extract of *A. occidentale* for 56 days (H&E x 200)

Vascular congestion (VC) is noted. Cell necrosis (N) and degeneration (D)

**Figure 1:** Liver section from a control mouse (A) and a mouse treated with 14 g/kg/ body weight (B) of hexane extract of *A. occidentale* for 56 days.

**Sub-acute toxicity****Effect of chronic oral administration of *A. occidentale*-extract on body weight and mortality**

As shown in Table 2, weights of animals that received repeated dose of *A. occidentale* hexane extract at a dose of 10 and 14 g/kg by oral route decreased significantly ( $P < 0.05$  and  $P < 0.01$  respectively) relative to that of controls from 35<sup>th</sup> day until the end of the 56 days study. On the other hand, administration at a dose of 10 and 14 g/kg for 56 days resulted in mortality rate of 23 and 25 % respectively.

**Effect of chronic oral administration of *A. occidentale*-extract on food intakes**

Mean weights of food consumed by animals in the treated groups and in the control group are shown in Table 3. There is no statistically significant difference between any groups. No lethality was recorded for the dose of 6 g/kg during 8 weeks (56 days) of treatment.

**Effect of chronic oral administration of *A. occidentale*-extract on biochemical parameters of mice**

Administrations of *A. occidentale* hexane extract result in significant changes in biochemical parameters (Table 4). Statistically significant increase ( $P < 0.01$ ) in serum creatinine and urea were observed in animals in groups II and III. Chronic administration of *A. occidentale* hexane extract caused significant decrease ( $P < 0.01$ ) in the activity of marker enzymes (ALT, AST). However, serum total protein was significantly ( $P < 0.01$ ) decreased in treated animals (II-III) as compared to controls up to 56 days of treatment.

**Histological assessment**

In histopathological studies of animals in the control group and in the groups treated with *A. occidentale* extract, alterations were noted in relation to some organs (liver and kidney). Histopathological examination of the liver revealed marked centrolobular degeneration of hepatocytes (Figure 1). The lesion then resolved as a predominantly necrosis of hepatocytes (apoptotic bodies). There was slight congestion of the liver. Histopathological examination of kidney section of treated animal is presented in Figure 2. Microscopically, there was slight degeneration of tubular epithelium. Glomeruli were congested and had increased cellularity. Tubular dilation with some vesicular nuclei was noted.

**Discussion**

Despite the widespread use, few scientific studies have been undertaken to ascertain the safety and efficacy of traditional remedies. The present investigation shows that the hexane extract leaves of *A. occidentale* is non toxic via the oral route in mice, at least up to a maximum dose of 14 g/kg. Since the *A. occidentale* hexane extract has previously been shown to be pharmacologically active (antidiabetic, anti-inflammatory) when given by oral route to rats (De Souza *et al.*, 1992; Ojewole, 2003) at the minimum active dose of 100 mg/kg, one may conclude that active compound (s) present in the *A. occidentale* hexane extract exhibit a rather low acute oral toxicity profile. In this study, mortality and symptoms of pronounced behaviour were noted only after oral administration of relatively high doses of *A. occidentale* hexane extract in mice ( $LD_{50}=16$  g/kg). In agreement with these findings, and literature reports several antidiabetic plants with no acute toxicity at a dose higher than 10 g/kg (Erenmeniosoglu *et al.*, 1995; Peungvicha *et al.*, 1996).

Sub-acute treatment of the mice with *A. occidentale* hexane extract at doses of 6 g/kg for 8 weeks did not affect body weight and biochemical parameters. Since the changes in body weight have been used as an indicator of adverse effects of drugs and chemicals (Theo *et al.*, 2002), the present results suggest that at the oral dose of 6g/kg administered, the *A. occidentale* hexane extract for 56 days is not toxic. On the other hand, administration of *A. occidentale* hexane extract at doses of 10 and 14 g/kg during 56 days resulted in significant decrease in body weight compared to the controls. Since there were significant changes in the levels of transaminases (ALT, AST), creatinine and urea at a dose of 14 g/kg which are good indicators of liver and kidney functions, it is reasonable to deduce that the *A. occidentale* hexane extract induce damage to liver and the kidneys. This is further confirmed by histological assessment of these organs. Weight of liver and kidneys were slightly altered by the drug administration at a dose of 14 g/kg. Histopathological examination of selected organs showed liver infiltration and congestion, kidneys' mesangial expansion and nucleus pycnosis (Figure 1).

**Table 1:** Acute toxicity of hexane extract of *A. occidentale* administered by oral route to mice.

| Dose (g/kg) | N  | Toxic symptoms                         | Dead mice | D/T   | % of mortality |
|-------------|----|--|-----------|-------|----------------|
| 2           | 10 | None                                   | 0         | 0/10  | 0              |
| 6           | 10 | None                                   | 0         | 0/10  | 0              |
| 10          | 10 | Asthenia, hypoactivity                 | 0         | 0/10  | 0              |
| 14          | 10 | Asthenia, anorexia, hypoactivity       | 0         | 0/10  | 0              |
| 18          | 10 | Asthenia, anorexia, diarrhoea, syncope | 3         | 3/10  | 30             |
| 22          | 10 | Asthenia, anorexia, diarrhoea, syncope | 7         | 7/10  | 70             |
| 26          | 10 | Asthenia, anorexia, diarrhoea, syncope | 10        | 10/10 | 100            |
| Total       | 80 |  | 20        | 20/70 | 28,57          |

**Table 2:** Changes in body weight of mice in control groups and groups receiving hexane extract of *A. occidentale* administered by oral route for 56 days.

| Group   | Days of treatment |           |          |          |          |          |            |            |
|---------|-------------------|-----------|----------|----------|----------|----------|------------|------------|
|         | 7                 | 14        | 21       | 28       | 35       | 42       | 49         | 56         |
| Control | 21,9±0,1          | 23,44±0,2 | 23,6±0,1 | 25,0±0,2 | 25,0±0,2 | 26,3±0,0 | 26,5±0,2   | 27,1±0,1   |
| I       | 21,3±0,2          | 23,0±0,3  | 24,7±0,2 | 25,8±0,2 | 24,6±0,1 | 24,6±0,1 | 24,4±0,2   | 25±0,1     |
| II      | 21,6±0,0          | 23,2±0,2  | 23,8±0,2 | 25,3±0,3 | 21,2±0,1 | 19,8±0,3 | 18,6±0,2*  | 17,6±0,2*  |
| III     | 20,0±0,1          | 22,0±     | 23,3±0,1 | 23,6±0,2 | 20,6±0,2 | 17,6±0,1 | 15,9±0,1** | 15,5±0,0** |

The hexane extract of *A. occidentale* was given daily by oral route to groups of mice (n=10) at the doses: I (6g/kg), II (10 g/kg) and III (14 g/kg) for 56 days. The rats were weighted every 7 days. The data are expressed as mean ±S.E.M. Significances differences for each group at each time period vs control values: \*P<0.05; \*\*P<0.01.

**Table 3:**

Food intakes (gram per animal per day) of mice (Control group and group I-III) treated with hexane extract of *A. occidentale* during 56 days of treatment.

|           | Days of treatment |           |           |           |           |           |           |           |
|-----------|-------------------|-----------|-----------|-----------|-----------|-----------|-----------|-----------|
|           | 7                 | 14        | 21        | 28        | 35        | 42        | 49        | 56        |
| Control   | 4,50 (10)         | 4,22 (10) | 4,42 (10) | 4,5 (10)  | 4,06 (10) | 4,21 (10) | 3,81 (10) | 3,94 (10) |
| Group I   | 4,90 (10)         | 3,95 (10) | 4,32(9)   | 4,35 (10) | 4,22(9)   | 4,18 (9)  | 4,28 (9)  | 4,25 (9)  |
| Group II  | 4,79 (10)         | 4,56 (10) | 4,33 (9)  | 4,21 (8)  | 4,13 (8)  | 4,16 (8)  | 4,10 (8)  | 3,97 (8)  |
| Group III | 4,72 (10)         | 4,23 (10) | 3,88 (8)  | 3,90 (7)  | 3,88(5)   | 3,74 (5)  | 3,61 (4)  | 3,55 (4)  |

**Table 4:**

Biochemical parameters relating to blood of mice (control and groups I-III) after daily administration of 0, 6 10 and 14 g/kg of hexane extract of *A. occidentale* for 56 days.

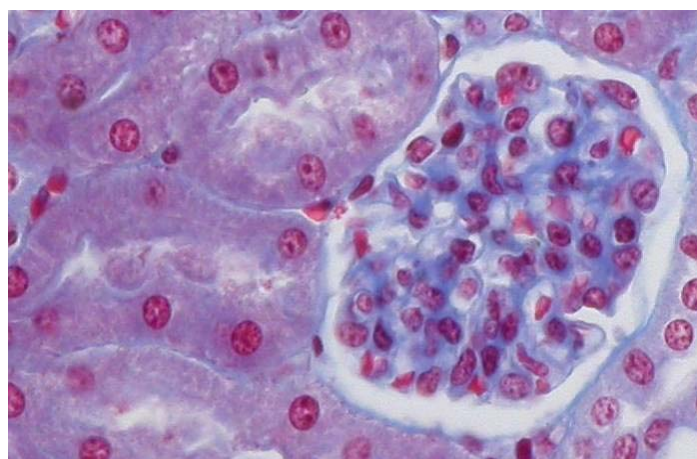
| Parameter           | Control group | Group I  | Group II | Group III  |
|---------------------|---------------|----------|----------|------------|
| ASAT (U/L)          | 51,3±0,2      | 42,5±0,1 | 37,7±0,2 | 29,3±0,2** |
| ALAT (U/L)          | 45,0±0,2      | 38,3±0,1 | 35,3±0,2 | 28,4±0,2*  |
| Creatinine (mmol/L) | 15,5±0,2      | 21,0±0,1 | 26,6±0,3 | 45,0±0,1** |
| Urea (mmol/L)       | 35,5±0,1      | 32,5±0,1 | 44,0±0,2 | 49±0,3**   |
| Total protein (g/L) | 45,5±0,2      | 44,0±0,1 | 32,0±0,2 | 28±0,2**   |

The hexane extract of *A. occidentale* was given daily by oral route to groups of mice (n=10) at the doses: I (6g/kg), II (10 g/kg) and III (14 g/kg) for 56 days. Biochemical parameters were measured after the last day of treatment. The data are expressed as mean ±S.E.M. Significances differences for each group at each time period vs control values: \*P<0.05; \*\*P<0.01.

**Tableau 5:** Weights of organs from mice in control groups and groups receiving hexane extract of *A. occidentale* administered by oral route for 56 days

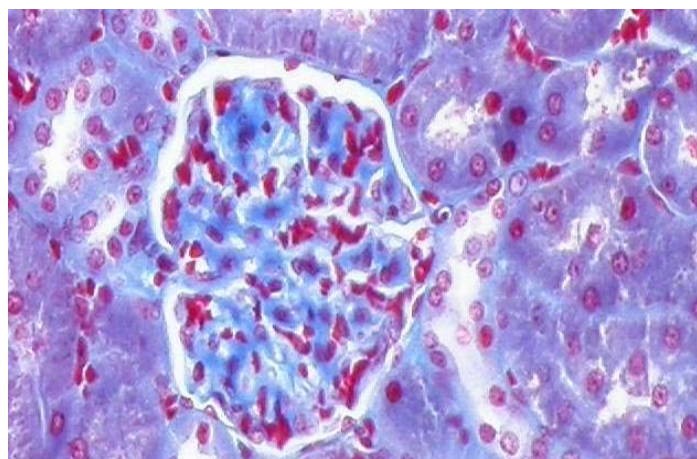
| Doses (g/kg) | Liver         |               | Kidney        |                |
|--------------|---------------|---------------|---------------|----------------|
|              | Mâles         | Femelles      | Mâles         | Femelles       |
| Control      | 3,1±0,1 (5)   | 3,6±0,4 (5)   | 1,45±0,2 (5)  | 1,35±0,3 (5)   |
| Group I      | 3,33±0,2 (5)  | 3,7±0,1 (4)   | 1,52±0,1 (5)  | 1,45±0,1 (4)   |
| Group II     | 4,02±0* (4)   | 4,33±0,1* (4) | 1,6±0,0 (4)   | 1,65±0,1 (4)   |
| Group III    | 4,42±0,1* (4) | 4,80** (4)    | 1,85±0,2* (4) | 1,9±0,12** (4) |

Each value represents a mean relating to number of animals in bracket. Significances differences for each group at each time period vs control values: \*P<0.05; \*\*P<0.01.



**A:** Kidney section from control mice (Mason's trichrome x 200)

Glomerulus (G). Bowman's Capsule (BC). Numerous of tubules, Proximal Convoluted tubules (PCT) and Distal Convoluted tubules lie in the area adjacent to Glomerulus. Brush border (BB); Urinary Tract (UT)



**B:** Kidney section from mice treated with 14 g/kg/j body weight (B) of hexane extract of *A. occidentale* for 56 days. (Mason's trichrome x100)

Mesangial expansion (ME).

Tubular clarification (TC)  
Vesicular nuclei (Vn)

**Figure 2:** Kidney section from control mice (A) and mice treated with 14 g/kg/j body weight (B) of hexane extract of *A. occidentale* for 56 days.

To confirm the toxic nature of any plant product, one has to consider several factors that can alter its toxicity profile, including the growth stage, and the maturity of the plant, the specific part (s) of the plants (such as leaves, roots, bark, flowers, seeds etc..) used, the storage conditions of the product (freshly collected or stored for long time) the seasonal variation in the relative abundance of phytochemicals (Jaouad *et al.*, 2004). Qualitative tests of *A. occidentale* hexane extract revealed the presence of alkaloids, lipids saponins and polyphenols. The toxic activity of *A. occidentale* leaf extract may be related to its alkaloid content. Importantly, more than 350 species which contain alkaloids have been shown to display a wide spectrum of toxicological activities (Schuppan *et al.*, 1999; Stedman, 2002; Pageaux and Larrey, 2003). Larrey (1997) have also reported that some galenic preparations are hepatotoxic because of their alkaloid content. Some parts of plants such as bark and fruits of *A. occidentale* have been shown to contain alkaloids, tannins (Paris *et al.*, 1977) or other compounds that have toxic effects (França *et al.*, 1993). Concerning lipids, lesions observed on liver and kidney may not be attributable to these compounds. Malini and Vanithakumari (1990) indicated that chronic administration of  $\beta$ -sitosterol (lipids isolated from *A. occidentale* leaf extract) subcutaneously to rats for 60 days was well tolerated and there was no clear evidence of any lesions either in the liver or in the kidney. Although the fruits of *A. occidentale* are commonly eaten, leaves and barks have been shown to display a wide spectrum of biological and pharmacological activities, which provide experimental support for empiric ethnopharmacological use of this plant in folk medicine. *Anacardium* has been reported to have anti-inflammatory actions (Mota *et al.*, 1985; Ojewole, 20004), antimicrobial (Laurens *et al.*, 1982), hypoglycaemic and antidiabetic (Kamtchouing *et al.*, 1998; Ojewole, 2004; Tedong, 2006) and molluscicide (Mendes *et al.*, 1990; Juberg *et al.*, 1995) activity. The folkloric used of *A. occidentale* may be validated by this study since the therapeutic dose often used is usually lower than the dose exhibiting toxicity in this study.

## Conclusion

The investigations described here were intended to reveal possible toxic effects of *A. occidentale* hexane extract in view of their antidiabetic and antimicrobial-activity. It was shown that toxic effects of *A. occidentale* hexane extract occurred at higher doses than those employed in the models of antidiabetic activities studied. Previous study in our laboratory have shown long term efficacy of *A. occidentale* hexane extract as hypoglycaemic agent in diabetic rats. Studies of this kind are always needed before a phytotherapeutic agent can be generally introduced.

## References

1. Bartels H. and Bohmer (1972). Estimation of creatinine clearance in patients with unstable renal function. *Clin. Chim. Acta*, 37:173.
2. Day C. (1995). Hypoglycemic plant compounds. *Practical Diabetes Int.*, 12(6):245-296.
3. De Souza C.P., Mendes N.M., Janotti-Passos L.K., Pereira J.P. (1992). The used of the shell of cashew nut, *Anacardium occidentale*, as an alternative molluscicide. *Rev. Inst. Med. Trop. So Paulo.*, **34** (5): 459-466.
4. Erenmemisoglu A., Kelestimur F., Koker A.M., Ustun H., Tekol Y. and Ustdal M. (1995). Hypoglycaemic effect of Zizuphus jujube leaves. *J.Pharm. Pharmacol.* **47** (1):72-74.
5. Franca F., Cuba C.A., Moreira E.A., Miguel O., Almeida M., Das irgens M and Marsden P.D. (1993). An evaluation of a bark extracts from the cashew (*Anacardium occidentale* L.) on infection by Leishmania (Viannia) braziliensis. Paris R. ; Phat M. ; Giono-Barber, Linhard J. et Laureus J. (1977).
6. Gornal A.G., Bardwil G.S., David M.M. (1949). Determination of serum proteins by the means of Biuret reactions. *J. Biol. Chem.*, **177**: 751-766.
7. IFCC (International Federation of Clinical Chemistry). (1975). Committee on standards. Part 2. Method for Aspartate Aminotransferase. Elsevier publishing company. Amsterdam.
8. IFCC (International Federation of Clinical Chemistry). (1980).IFCC methods for the measurement of catalytic concentration of enzymes. Part 3. IFCC method for Alanine Amino Transferase (L-alanine: 2-oxoglutarate aminotransferase. EC 2.6.1.2). *Clinica Chimica Acta.* **105**: 147-154.
9. Jaouad E.H., Israili Z.H., Lyoussi B. (2004). Acute toxicity and chronic toxicological studies of *Ajuja iva* in experimental animals. *J. Ethnopharm.* **91**: 43-50.

10. Kamtchouing P., Sokeng D.S., Moundipa P.F., Watcho P., Jatsa B.J., Lontsi D. (1998). Protective role of *A. occidentale* extract against streptozotocin-induced diabetes in rats. *J. Ethnopharmacol.*, 65: 95-99.
11. Larrey D. (1997). Hepatotoxicity of herbal remedies. *J. Hepatol* ; 26 [suppl. 1] : 47-51.
12. Mendes N.M., de Oliveira A.B., Guimareas J.E., Pereira J.P., Katz N. (1990). Molluscicide activity of mixture of 6-n-alkyl salicylic acids (anacardic acid) and 2 of its complexes with copper (II) and lead (II). *Rev. Soc. Bras. Med. Trop.*, **23** (3): 217-24.
13. Malini T. and Vanithakoumari G. (1990). Rat toxicity studies with  $\beta$ -sitosterol. *J. Ethnopharm.* **28**: 221-234.
14. Mota M.L. Thomas G., Barbosa Filho J.M. (1985). Anti-inflammatory actions of tannins isolated from the bark of *Anacardium occidentale* L. *J. Ethnopharm.*, 13 (3): 289-300.
15. Ojewole J.A. (2003). Laboratory evaluation of hypoglycemic effect of *Anacardium occidentale* Linn (Anacardiaceae) stem-bark extracts in rats. *Methods .Find. Exp. Clin. Pharmacol.*, 25 (3): 199-204
16. Ojewole J.A. (2004). Potentiation of the anti-inflammatory effect of *Anacardium occidentale* (Linn) stem-bark extract by grapefruit juice. *Methods Find Exp Clin. Pharmacol.*, **26**: 183-188.
17. Pageaux G, Larrey D. (2003) Alternative medicine, vitamins and natural hepatotoxins. In Drug-Induced liver disease. KAPLOWITZ N and DELEVE LD, Eds. Marcel Dekker, New York, Basel,.
18. Paris R. ; Phat M. ; Giono-Barber, Linhard J. et Laureus J. (1977). Recherche chimique et pharmacologique sur les feuilles d'*Anacardium occidentale* L. (Anacardiacées). *Bull soc. Med. Afr. Noire*, **22** (3), 275-281.
19. Peungvicha P., Thirwapan S.S., and Watanabe H. (1996). Hypoglycaemic water extract of root of *Pandanus odoratus* RIDL. *Bil. Pharm. Bull.* **19** (3): 364-366.
20. Schuppan D, Jia JD, Brinkhaus B, Hahn EG (1999). Herbal products for liver diseases: a therapeutic challenge for the new millennium. *Hepatology*; 30: 1099-1104
21. Sokeng D.S., Kamtchouing P., Watcho P., Jatsa H.B., Moundipa P.F., Ngounou F.N., Lontsi D., Bopelet M. (2001). Hypoglycemic activity of *Anacardium occidentale* L. Aqueous extract in normal and streptozotocin-induced diabetic rats. *Diab. Res.*, **36**: 001-009.
22. Stedman C. (2002) .Herbal hepatotoxicity. *Sem Liv Dis*; 22: 195-206.
23. Tedong L. Dimo T., Dzeufiet P. D. D., Asongalem A. E., Sokeng D. S., Callard P., Flejou J.F. and Kamtchouing P. (2006). Antihyperglycemic and renal protective activities of *Anacardium occidentale* (Anacardiaceae) leaves in streptozotocin induced diabetic rats. *Afr. J. Trad. CAM* 3 (1): 23 – 35.
24. Theo S., Stirling D., Thomas S., Hoberman A., Kiorpes A., Khetani V.(2002). A 90-day oral gavage toxicity study of D-methylphenidate and D,L-methylphenidate in sprague-Dawley rats. *Toxicology*, 179:183-196.
25. De Souza C.P., Mendes N.M., Janotti-Passos L.K., Pereira J.P. (1992). The use of the shell of cashew nut, *Anacardium occidentale*, as an alternative molluscicide. *Rev. Inst. Med. Trop. So Paulo.*, **34** (5): 459-466.