

Soft tissue sarcomas in dogs

Monique N. Mayer, Susan M. LaRue

Canine soft tissue sarcomas arise from non-bone connective tissues and include several different tumor types that are grouped together due to their similar biological behavior. These tumour types include fibrosarcoma, hemangiopericytoma, myxosarcoma, undifferentiated sarcoma, liposarcoma, malignant fibrous histiocytoma, schwannoma, rhabdomyosarcoma, and neurofibrosarcoma (1). These tumors infiltrate along fascial planes, recur locally after conservative surgical excision, metastasize via hematogenous routes, and are surrounded by a pseudocapsule (2). The pseudocapsule may appear to separate the tumor from surrounding normal tissue, but tumors that are marginally resected at the level of this capsule have a high rate of local recurrence (1).

Canine soft tissue sarcomas generally present as a firm mass arising from the body wall, oral cavity, or extremity (1). If a soft tissue sarcoma is suspected based on clinical presentation or aspirate cytology, a pretreatment biopsy is indicated. Pretreatment biopsy techniques include needle core biopsies, punch biopsies, and incisional biopsies (3). An incisional biopsy will generally provide an adequate amount of tissue for a definitive histopathologic diagnosis and tumor grade. In contrast to lumpectomy, an incisional biopsy will not interfere with pretreatment imaging of the gross tumor or affect the size of radiation treatment fields. The biopsy incision should be kept as short as possible, and placed so that the entire biopsy tract can be removed at the time of surgery (3). Minimal dissection will help to prevent contamination of surrounding tissues with cancer cells. If the mass is on an extremity, the biopsy incision should be made along the long axis of the leg to facilitate removal of the entire biopsy tract (3).

Grading of canine soft tissue sarcomas provides important prognostic information and directs the management approach. Histological features of higher grade tumors have been associated with a shorter survival and increased risk of metastases (4). Adjunctive chemotherapy may be part of the recommended therapy for dogs with high grade soft tissue sarcomas.

Once a histological diagnosis of soft tissue sarcoma has been made, complete staging of the patient is critical to determining the optimal treatment plan. The TNM

staging system described for animals is based on extent of the primary tumor (T), condition of the regional lymph nodes (N), and the absence or presence of distant metastases (M) (5). The extent of body wall, oral, or proximal extremity tumors can be determined by using computed tomography or magnetic resonance imaging. Although soft tissue sarcomas usually spread via a hematogenous route, lymphatogenous spread has been reported (2,4). Lymph nodes draining the tumor region should be assessed by palpation and aspirated for cytology if abnormal. If draining lymph nodes are not accessible for palpation, they can be assessed by imaging modalities, such as ultrasonography, radiography, or computed tomography. Thoracic radiographs assess the presence of clinically detectable lung metastases.

The optimal time to determine the best combination and sequencing of radiation, surgery, and chemotherapy for canine soft tissue sarcomas is after a pretreatment biopsy and a full staging workup. Consultation with a radiation oncologist is indicated when it is probable that cancer cells will be left behind after surgery. Cancer cells may be left behind if radical surgical resection is not possible due to the location of a tumor, or if the decision is made to perform a less radical surgery to preserve function or for cosmetic reasons.

The sequencing of radiation and surgery is based on multiple factors and is determined on an individual basis, after patient examination by a radiation oncologist and surgeon. There are several advantages and disadvantages to both preoperative and postoperative radiation therapy (6). One advantage of radiation prior to surgery is that preoperative radiation fields are generally smaller than postoperative fields, which must include all surgical margins. Smaller fields are preferable to decrease dose to normal tissues surrounding a tumor, as the probability of late normal tissue damage decreases as the volume of tissue irradiated decreases (6). As well, the patient will have a smaller area affected by acute side effects of radiation treatment. The ability to image the gross tumor and determine its precise location in relation to surrounding structures facilitates the selection of the target volumes by the radiation oncologist during the radiation treatment planning process. Also, preoperative irradiation avoids surgical disruption of the tissues surrounding a tumor prior to irradiation, which can lead to hypoxia (6). A low oxygen environment protects tumor cells from radiation and may lead to treatment failure (7). Preoperative irradiation may be elected for a large, nonresectable soft tissue sarcoma, as shrinkage of the tumor after irradiation may facilitate surgical removal (Figure 1). A disadvantage of preoperative irradiation is an increased risk of surgical complications related to

Department of Small Animal Clinical Sciences, University of Saskatchewan, 52 Campus Drive, Saskatoon, Saskatchewan S7N 5B4 (Mayer); Department of Radiological and Environmental Health Sciences, Colorado State University, Fort Collins, Colorado 80523-1618, USA (LaRue).

Address all correspondence to Dr. Monique N. Mayer; e-mail: monique.mayer@usask.ca

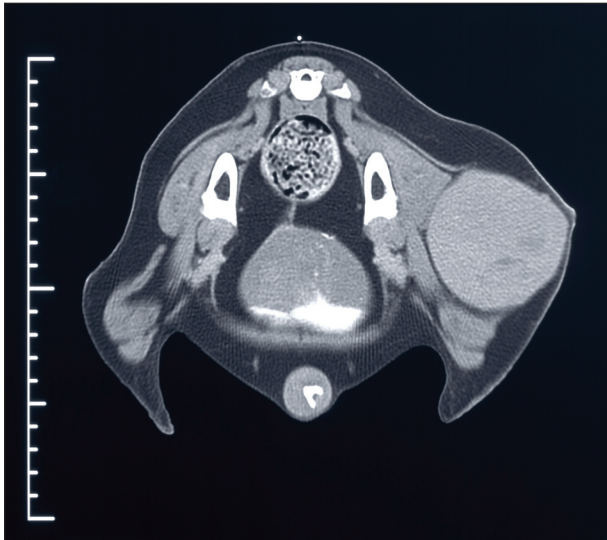


Figure 1. Computed tomographic image of a grade 1 soft tissue sarcoma in a dog. Preoperative radiation therapy was elected for this patient.

impairment of wound healing by radiation (6). The risk of wound complications may be minimized by selection of appropriate radiation dose protocols when surgery is part of the therapy plan (8).

An advantage to radiation therapy after surgery is that wound complications are rare in tissues that are irradiated after the first inflammatory phase of wound healing (9). As well, if a patient has a large tumor with necrotic regions or infection, removal of the mass may make the patient, and the patient's family, more comfortable. Postoperative treatment planning may be simpler than preoperative planning in patients in which the size or shape of a tumor creates difficulty in achieving a uniform dose distribution. Disadvantages to postoperative radiation therapy include increased radiation field sizes; damage to vasculature, which may lead to hypoxia; and potential delays in the start of radiation therapy, if there are post-surgical wound complications (10).

The length of time between surgery and radiation therapy is different for preoperative and postoperative irradiation. Surgery is generally scheduled 3 to 4 wk or longer after completion of a radiation protocol, to allow time for acute side effects to heal and shrinkage of the tumor to occur (6). In contrast, postoperative irradiation is generally started within 1 to 14 d of surgery (6). Surgery may promote accelerated growth of the residual cancer cells, reducing the probability of tumor control if the start of radiation is delayed (6).

A retrospective study by Forrest et al (11) of 35 dogs with marginally excised soft tissue sarcomas evaluated the effectiveness of postoperative radiation therapy. All patients had microscopic disease present on histological examination, but no remaining gross disease. Of the 25 tumors available for review, 23 were grade 1 or 2. Patients were treated daily Monday through Friday. The overall median survival of the 35 dogs was 5.1 y. Dogs with tumors in the oral cavity had a significantly shorter median survival (1.5 y) than dogs with tumors at non-oral sites (6.2 y). Fourteen percent of the dogs developed pulmonary metastases. The authors concluded that radi-

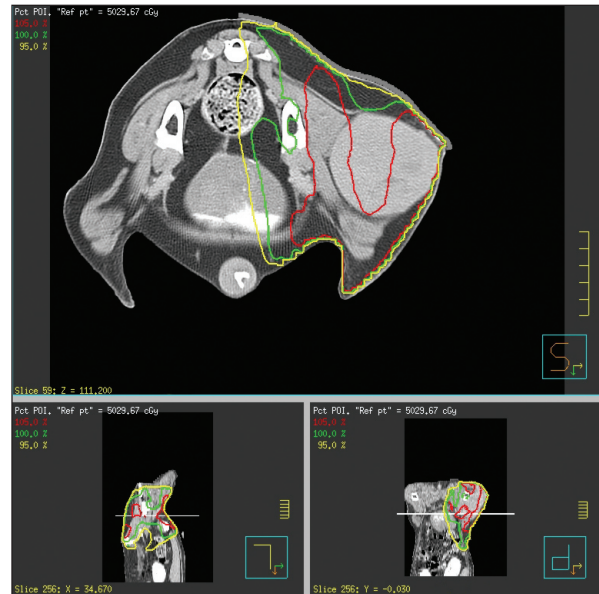


Figure 2. Isodose lines showing distribution of 95% (yellow), 100% (green), and 105% (red) of the prescribed dose for the patient in Figure 1. Dose is prescribed to the gross tumor and surrounding tissues that may contain microscopic or subclinical disease.

ation therapy has a role as an adjuvant therapy when soft tissue sarcomas are incompletely excised.

The effectiveness of radiation therapy for incompletely resected soft tissue sarcomas was evaluated in a prospective study by McKnight et al (12). Forty-eight dogs received postoperative radiation therapy starting 2 to 3 wk after their tumors had been surgically reduced to less than 3 cm³. The authors excluded dogs with tumors in the oral cavity. The median disease-free interval for the 48 dogs was 3 y. Eighty-seven percent of dogs were alive at 1 and 2 y, 81% at 3 and 4 y, and 76% at 5 y. Eight percent of dogs developed lung metastases. The authors concluded that conservative surgery with adjunctive radiation therapy is as effective as radical surgery alone, and that amputation is not needed to provide long-term control of extremity soft tissue sarcomas.

Literature on the effectiveness of radiation therapy prior to surgery for canine soft tissue sarcomas is limited. However, survival of cats treated with preoperative radiation therapy for soft tissue sarcomas is similar to that of cats irradiated after surgery (13–15). As well, overall survival and duration of local control was not different between human patients irradiated for soft tissue sarcomas preoperatively and those treated postoperatively (16).

Radiation therapy is indicated for dogs with soft tissue sarcomas that are not curable with surgery alone. It may not be possible to remove all cancer cells with surgery due to either the location of a tumor or the desire to preserve function or cosmesis. Radiation therapy alone or in combination with chemotherapy also has a role for soft tissue sarcomas for which surgical options do not exist. It is critical to plan the optimal combination and timing of radiation, surgery, and chemotherapy for canine soft tissue sarcomas before any treatment is undertaken. A pretreatment biopsy, as opposed to an excisional

biopsy or lumpectomy, is preferred, as it will not limit advanced imaging of the tumor and will allow preoperative radiation to be considered as an option. Dogs referred to the Western College of Veterinary Medicine for radiation therapy of soft tissue sarcomas are treated daily Monday through Friday for 3½ to 4 wk, on an outpatient basis. The treatment planning process is dependent on the location of the tumor. Computerized 3-dimensional treatment plans are indicated for most patients with tumors of the oral cavity, body wall, or proximal region of an extremity, and are created from a computed tomographic scan (Figure 2). Computerized treatment planning is a complex process involving a radiation oncologist, radiation therapist, dosimetrist, and physicist. Time is required for plan development and evaluation, as well as for construction of custom shielding designed to protect normal tissue. As a result, dogs generally start treatment 7 to 10 d after their computed tomographic scan. Dogs with tumors of the distal region of an extremity are generally planned by using simpler 2-dimensional calculations, and treatment is started within 1 to 2 d of referral.

References

1. Thrall DE, Gillette EL. Soft-tissue sarcomas. *Semin Vet Med Surg (Small Anim)* 1995;10:173–179.
2. MacEwen EG, Powers BE, Macy DW, Withrow SJ. Soft tissue sarcomas. In: Withrow SJ, MacEwen EG, eds. *Small Animal Clinical Oncology*. Philadelphia: WB Saunders, 2001:283–304.
3. MacEwen EG, Powers BE, Macy DW, Withrow SJ. Biopsy principles. In: Withrow SJ, MacEwen EG, eds. *Small Animal Clinical Oncology* Philadelphia: WB Saunders 2001:63–69.
4. Kuntz CA, Dernel WS, Powers BE, Devitt C, Straw RC, Withrow SJ. Prognostic factors for surgical treatment of soft-tissue sarcomas in dogs: 75 cases (1986–1996). *J Am Vet Med Assoc* 1997;211:1147–1151.
5. TNM Classification of Tumours in Domestic Animals. Geneva: World Health Organization, 1980:46–47.
6. McLeod DA, Thrall DE. The combination of surgery and radiation in the treatment of cancer. A review. *Vet Surg* 1989;18:1–6.
7. Hall EJ. The Oxygen Effect and Reoxygenation. In: *Radiobiology for the Radiologist*. Philadelphia: Lippincott Williams & Wilkins 2000:91–111.
8. Seguin B, McDonald DE, Kent MS, Walsh PJ, Theon AP. Tolerance of cutaneous or mucosal flaps placed into a radiation therapy field in dogs. *Vet Surg* 2005;34:214–222.
9. Tibbs MK. Wound healing following radiation therapy: a review. *Radiother Oncol* 1997;42:99–106.
10. McNiel EA, LaRue SM. Principles of adjunctive radiation therapy. *Clin Tech Small Anim Pract* 1998;13:33–37.
11. Forrest LJ, Chun R, Adams WM, Cooley AJ, Vail DM. Postoperative radiotherapy for canine soft tissue sarcoma. *J Vet Intern Med* 2000;14:578–582.
12. McKnight JA, Mauldin GN, McEntee MC, Meleo KA, Patnaik AK. Radiation treatment for incompletely resected soft-tissue sarcomas in dogs. *J Am Vet Med Assoc* 2000;217:205–210.
13. Bregazzi VS, LaRue SM, McNiel E, et al. Treatment with a combination of doxorubicin, surgery, and radiation versus surgery and radiation alone for cats with vaccine-associated sarcomas: 25 cases (1995–2000). *J Am Vet Med Assoc* 2001;218:547–550.
14. Cronin K, Page RL, Spodnick G, et al. Radiation therapy and surgery for fibrosarcoma in 33 cats. *Vet Radiol Ultrasound* 1998;39:51–56.
15. Kobayashi T, Hauck ML, Dodge R, et al. Preoperative radiotherapy for vaccine associated sarcoma in 92 cats. *Vet Radiol Ultrasound* 2002;43:473–479.
16. Cheng EY, Dusenbery KE, Winters MR, Thompson RC. Soft tissue sarcomas: preoperative versus postoperative radiotherapy. *J Surg Oncol* 1996;61:90–99.