

Review Article

The Evolution of Surgical Treatment for Female Stress Urinary Incontinence: Era of Mid-Urethral Slings

Young-Suk Lee, Ha Na Lee¹, Kyu-Sung Lee¹

Department of Urology, Masan Samsung Medical Center, Masan, ¹Samsung Medical Center, Seoul, Sungkyunkwan University School of Medicine, Korea

Based on the integral theory, tension-free placement of a mid-urethral sling (MUS) for female stress urinary incontinence (SUI) has gained substantial popularity owing to the ease of the procedure and its effectiveness. Published series with long-term follow-up show continence rates after the MUS procedure ranging from 70% to 80%. Complication rates after MUS procedures are usually low. This review aimed to describe the historical change and the current use of the MUS. We discuss the efficacy and complications of various MUS procedures and the current strategies for managing failed slings.

Key Words: *Stress urinary incontinence; Tension-free vaginal tape; Trans-obturator tape*

Article History:

received 28 March, 2010

accepted 7 April, 2010

Corresponding Author:

Kyu-Sung Lee
Department of Urology, Samsung Medical Center, Sungkyunkwan University School of Medicine, 50, Irwon-dong, Gangnam-gu, Seoul 135-710, Korea
TEL: +82-2-3410-3554
FAX: +82-2-3410-3027
E-mail: ksleedr@skku.edu

INTRODUCTION

After the introduction of the integral theory and the development of the mid-urethral sling (MUS), MUS is now considered a standard surgical option for the management of female stress urinary incontinence (SUI). As the materials and surgical techniques of SUI surgery evolve, surgeons are faced with the concern of choosing the optimal management option. This review aimed to describe the historical change and the current use of the MUS. We discuss the efficacy and complications of various MUS procedures and the current strategies for managing failed slings.

MECHANISM OF ACTION: THE INTEGRAL THEORY

In 1990, Petros and Ulmsten described the integral theory of female urinary continence, a concept that would define the modern approach of anti-incontinence surgery [1]. The theory proposes that a physiologic backboard is created through fixation of the middle region of the urethra to the pubic bone, via the pubourethral ligaments [2]. Loss of this backboard, which is critical to the continence mechanism, inhibits normal urethral coaptation when the intra-abdominal pressure is increased and results in urinary incontinence. The three pelvic organs, bladder, vagina, and

rectum, are suspended from the pelvic brim by three suspensory ligaments, pubourethral, cardinal/uterosacral, and arcus tendineus fascia pelvis. The vaginal fascia is closely linked to the suspensory ligaments and the perineal body. Three directional muscles transmit tension to the organs to give them position, shape, and strength. The clinical application of this concept was evident in subsequent repositioning of the sling to a more distal location beneath the urethra, appropriately described as the MUS. "Tension-free" polypropylene tapes have been applied at the mid-urethra to cure stress incontinence. Reinforcement of the muscle insertion points, the ligaments, restores opening and closing muscle forces and, therefore, function.

EVOLUTION OF THE ROUTE: MID-URETHRAL SLING TYPES

Since the introduction of the MUS technique, significant global experience with this procedure has proven it to be an effective treatment for SUI. Following initial reports by Ulmsten on a new surgical procedure to treat SUI, the tension-free vaginal tape (TVT) procedure has been used globally owing to its reduced invasiveness and high success rates [3]. Subsequently, other retro pubically implanted devices, such as the SPARC (American Medical Systems Research Corp., Minnetonka, MN, USA) and intravaginal sling-

plasty (IVS) (US Surgical, Norwalk, CT, USA) slings, make sling procedures even less invasive, more cost-effective, and sometimes only used for patent issues (Table 1). As the result of efforts to develop safer and less invasive procedures to avoid blind passage of a needle through the retro-pubic region, the trans-obturator tape (TOT) procedure was introduced by Delorme [4]. New products continue to be developed and introduced as safe and effective alternatives to retro pubic or trans-obturator slings. Single-in-

cision MUS, the TVT-SECUR (Gynecare, Menlo Park, CA, USA), the MiniArc (American Medical Systems, Minnetonka, MN, USA), the Mini-Sling (ProSurg, San Jose, CA, USA), and the Prefyx PPS System (Boston Scientific, Natick, Massachusetts) were developed to minimize the risks by the short course of the devices. The TVT-SECUR consists of prolene mesh, 8 cm in length, that is advanced into the endopelvic fascia through a small vaginal incision. For the U-type method, the inserters are introduced into the paraurethral space oriented to 45° from the sagittal midline and are advanced upward until the back edge of the pubic bone is reached, creating a U-shaped sling. For the H-type method, the inserters are introduced into the obturator internus muscle parallel to the floor, thus creating a hammock(H)-shaped sling (Fig. 1).

TABLE 1. Commercial kits available for midurethral sling placement

Name	Manufacturer	Approach
Retropubic		
Transvaginal tape	Gynecare ^a	Bottom-to-top
Suprapubic arc (SPARC [®])	AMS ^b	Top-to-bottom
IVS Tunneler	US surgical ^c	Bottom-to-top
Transobturator		
Monarc	AMS	Outside-in
TVT-O	Ethicon ^d	Inside-out
ObTape	Mentor ^e	Outside-in
ObTryx	Boston scientific ^f	Outside-in
Obturator IVS Tunneler	US surgical	Outside-in
UraTape [®]	Porgès-mentor ^g	Inside-out
Aris [®]	Coloplast ^h	Outside-in
TOT [®]	Dow ⁱ	Outside-in
Other		
MiniArc [®]	AMS	NA
Secur [®]	Gynecare	NA

NA: not applicable, TVT-O: transobturator vaginal tape, IVS: intravaginal slingplasty, All these kits use a polypropylene mesh sling. ^a: Gynecare[®] Inc., Menlo Park, CA. ^b: American Medical Systems Research Corp., Minnetonka, MN. ^c: US Surgical, Norwalk, CT. ^d: Ethicon Inc., Somerville, NJ. ^e: Mentor Corp., Santa Barbara CA. ^f: Boston Scientific Scimed Inc., Maple Grove, MN. ^g: Le Plessis, Robinson, France. ^h: Coloplast A/S, Copenhagen, Denmark, ⁱ: Dow Medics, Korea

EFFICACY OF THE MID-URETHRAL SLINGS

According to the 5-year outcomes of the TVT procedure published by Doo et al, the overall success rate was 94.9%, with an 86.6% patient satisfaction rate [5]. The cure rates of the TOT procedure were noted to range from 51% to 95%, depending on the definition used for success, the study instruments, and the study population [6,7]. To date, many randomized controlled trials (RCTs) comparing different types of MUS have been performed.

1. TVT vs. pubovaginal sling

Several RCTs have been conducted to compare the TVT and pubovaginal sling as treatments for SUI. Bai et al showed that the rectal fascia pubovaginal sling outperformed both TVT and Burch colposuspension, with 92.8% of the patients experiencing cure at the 12-month follow-up, compared with 87.8% of the Burch colposuspension group and 87% of TVT patients [8]. Wadie et al reported similar continence rates between TVT (92%) and the pubovaginal sling (92%) [9]. According to meta-analyses, TVT and pubovaginal slings showed similar continence rates [odds ratio

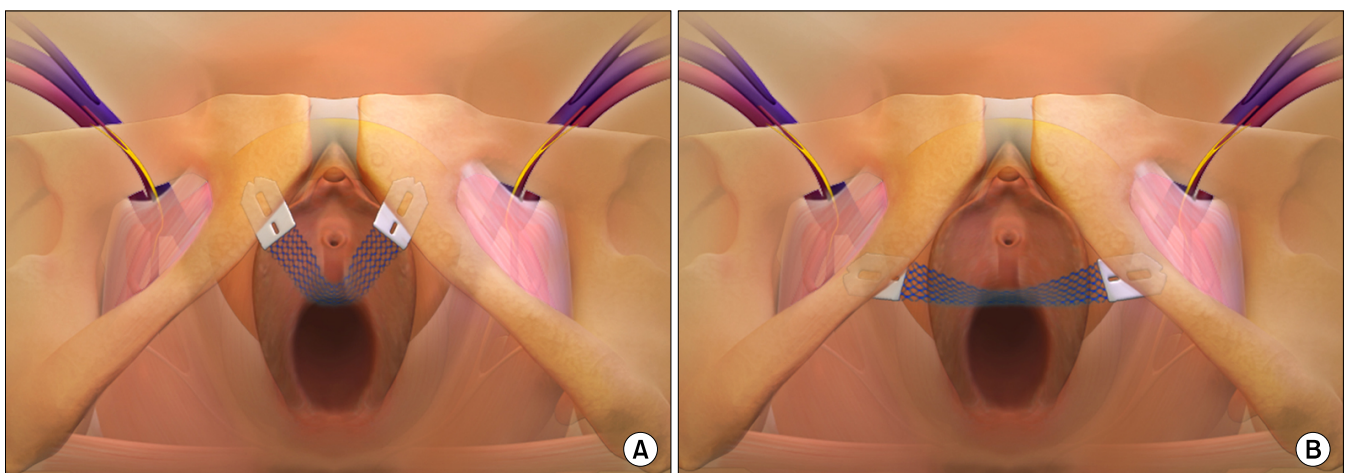


FIG. 1. TVT-Secur device after insertion. (A) TVT-Secur “U” type. (B) TVT-Secur “H” type (Figures printed with permission from TVT-S; TVT-Secur, Gynecare, Menlo Park, CA, USA).

TABLE 2. Randomized controlled trials comparing TVT with other mid-urethral sling procedures as the primary treatment for stress urinary incontinence: subjective and objective cure rates

Reference	Cases	Follow-up (months)	Cure rate	
			Objective (%)	Subjective (%)
Bai 2005 [8]				
TVT	31	12	87	NR
Puvovaginal sling	28		92.8	
Wadie 2005 [9]				
TVT	25	6	92	NR
Rectus fascia sling	28		92.9	
Rechberger 2003 [11]				
TVT	50	13.5	88	NR
IVS	50		80	
Meschia 2006 [12]				
TVT	95	24	85/86	87
IVS	95		72/75	78
Tseng 2005 [13]				
TVT	31	25	80.7	NR
SPARC	31		87.1	
Gandhi 2005 [14]				
TVT	73	4.25	95	86
SPARC	49		70	60
Enzelsberger 2005 [15]				
TVT	52	15	86	NR
Monarc	53		84	
Laurikainen 2006 [16]				
TVT	136	2.1	98.5	Non-significant difference
TVT-O	131		95.4	
Lee 2007 [17]				
TVT	60	13	86.8	NR
TVT-O	60		86.8	

TVT: tension-free vaginal tape, IVS: intravaginal slingplasty, NR: not reported

(OR): 0.82; 95% confidence interval (CI): 0.42-1.59; $p=0.55$ [10]. RCTs comparing TVT with other MUS procedure are listed in Table 2.

2. TVT vs. other retropubic tension-free mid-urethral slings

The largest trial was recently published by Meschia et al, who reported outcomes on 190 patients randomly assigned 1:1 to TVT or IVS [12]. The study showed significantly higher continence rates for patients treated with TVT, regardless of the applied definition of continence. TVT outperformed IVS, considering the success rates evaluated according to any definition of continence (OR: 0.51; 95% CI: 0.31-0.83; $p=0.007$) and the presence of a negative stress test (OR: 0.47; 95% CI: 0.28-0.82; $p=0.007$). The subjective cure rates were not different (OR: 0.63; 95% CI: 0.37-1.09; $p=0.10$) [10]. A comparative study between TVT and SPARC reported similar continence rates in the two arms (87.1% vs. 80.7%) and similar complication rates across all the assessable parameters [13].

3. Retropubic vs. trans-obturator tension-free mid-urethral slings

When comparing the TVT procedure to the TVT-O procedure, Laurikainen et al reported that the objective cure

rates, defined as negative cough stress test at 2 months postoperatively, were 98.5% for the TVT group and 95.4% for the TVT-O group [16]. Subjective cure rates as demonstrated by improvement on questionnaire scores were similarly high in both groups.

Lee et al randomly assigned 120 women to the TVT or TVT-O procedures [17]. The only significant differences between the groups were the mean operative time (TVT, 15.2 min; TVT-O, 11.5 min) and sling length used (TVT, 23.1 cm; TVT-O, 16.1 cm). The rates of cure (TVT, 86.8%; TVT-O, 86.8%), improvement (TVT, 6.6%; TVT-O, 8.2%) and failure (TVT, 6.6%; TVT-O, 5.0%) were similar.

A meta analysis by Latthe et al that compiled data from all available RCTs between retro pubic and trans-obturator slings showed similar subjective cure rates between the groups [18]. These data indicate little clinical difference between the retro pubic and trans-obturator approaches (Table 2).

4. Trans-obturator vaginal tape 'inside-out' vs. 'outside-in'

A prospective study to compare the efficacy and safety of the 'inside-out' (TVT-O) and 'outside-in' (TOT) trans-obturator tape procedures reported that TVT-O and TOT showed similar cure rates (86% vs. 92%) [19]. Approxi-

mately 1 year after surgery, parameters in the incontinence quality of life (I-QoL) questionnaire improved significantly in both groups, but there was no statistical difference between the groups. Patients satisfaction rates with TVT-O and TOT (96% vs. 98%) were similar (Table 3).

TABLE 3. Surgical results of patients who underwent inside-out TVT-O and outside-in TOT procedures

	TVT-O (n=50)	TOT (n=50)	p-value
Stress urinary incontinence			
Cured	43 (86%)	46 (92%)	0.262 ^a
Improved	5 (10%)	2 (4%)	0.134 ^b
Failed	2 (4%)	2 (4%)	0.691 ^b
Subjective satisfaction			
Very satisfied	31 (62%)	34 (68%)	0.338 ^a
Satisfied	17 (34%)	15 (30%)	0.415 ^a
Not satisfied	2 (4%)	1 (2%)	0.500 ^b
Patient would undergo repeat operation if symptoms recur			
Yes	48 (96%)	47 (94%)	0.500 ^a
No	2 (4%)	3 (6%)	0.500 ^b
Recommend to other patients			
Yes	48 (96%)	45 (90%)	0.218 ^a
No	2 (4%)	5 (10%)	0.218 ^b

TVT-O: transobturator vaginal tape, TOT: trans-obturator tape, Values are given as n (%), NS: not significant ($p > 0.05$), ^a: chi-square test, ^b: Fisher's exact test

Debodinance conducted a prospective comparative study of 100 SUI patients: 50 TVT-O vs. 50 Monarc [20]. The cure rate at 1 year was 94% in the TVT-O group vs. 90% in the Monarc group.

5. TVT-SECUR U-type vs. H-type

Lee et al performed a prospective, multicenter randomized comparative study between the U-type and H-type TVT-SECUR procedures (Table 4) [21]. The overall objective cure rate was 83.9% (239 of 285): 87.5% (126 of 144) for the U-type vs. 80.1% (113 of 141) for the H-type ($p=0.091$). The overall subjective cure rate was 76.4% (217 of 284): 77.1% (111 of 144) for the U-type vs. 75.7% (106 of 140) for the H-type ($p=0.786$). Improvement in the I-QoL and domain scores of the International Consultation on Incontinence Questionnaire-Female Lower Urinary Tract Symptoms (filling and incontinence sum, QoL score) questionnaires and patients satisfaction favored the U-type method.

Meschia et al reported that the TVT-SECUR procedure was effective for the treatment of primary SUI with 78% and 81% subjective and objective cure rates, respectively. No significant differences were seen in success rates when the tape was inserted by either the U- or H-type method [22]. The TVT-SECUR procedure appears to be an effective treatment for women with primary SUI, with an overall success rate of 80%.

TABLE 4. Comparisons of the changes in outcome measures between the U- and H-type methods

Variables	Total		U-type method		H-type method		p-value U vs. H ^a
	Preop.	Postop.	Preop.	Postop.	Preop.	Postop.	
I-QoL							
Avo/Lim	41.8	71.3 ^b	41.8	75.3 ^b	41.8	67.2 ^b	0.022
Psychosocial impacts	43.3	71.9 ^b	43.4	76.0 ^b	43.2	67.7 ^b	0.021
Social embarrassment	34.7	74.9 ^b	33.9	79.6 ^b	35.5	70.0 ^b	0.015
ICIQ-FLUTS							
Filling sum	6.18	3.60 ^b	6.20	3.18 ^b	6.15	4.04 ^b	0.022
Voiding sum	2.58	1.74 ^b	2.91	1.86 ^b	2.23	1.61 ^b	0.276
Incontinence sum	8.55	3.46 ^b	8.76	2.82 ^b	8.33	4.12 ^b	0.006
Sexual function score	1.74	0.87 ^b	1.81	0.81 ^b	1.66	0.94 ^b	0.421
QoL score	7.77	3.46 ^b	7.90	2.80 ^b	7.64	4.15 ^b	0.007
I-VAS	6.82	1.36 ^b	6.90	1.03 ^b	6.75	1.69 ^b	0.056
Voiding diary parameters							
Micturition/24 hours	9.03	7.97 ^b	8.99	8.02 ^b	9.07	7.92 ^b	0.218
Nocturia	1.25	0.68 ^b	1.28	0.68 ^b	1.23	0.69 ^b	0.615
Urgency episode/24 hours	2.37	1.22 ^b	2.88	1.40 ^b	1.86	1.04 ^b	0.329
Uroflowmetry parameters							
Qmax	25.7	24.3	24.8	23.7	26.6	25.0	0.576
PVR	18.0	20.1	18.2	20.6	17.8	19.6	0.306

Preop: preoperative, Postop: postoperative, Avo/Lim: avoidance and limiting behavior, ICIQ-FLUTS: international consultation on incontinence questionnaire- female lower urinary tract symptoms, I-QoL: incontinence quality of life questionnaire, PVR: postvoid residuals, Qmax: maximum flow rate, QoL: quality of life, I-VAS: incontinence visual analogue scale, ^a: Comparison between U- and H-type methods, Mann-Whitney U test, or t-test, ^b: $p < 0.05$, comparison between pre- and postoperative, Wilcoxon signed rank test, or paired t-test with Bonferroni correction

THE MID-URETHRAL SLING IN SPECIFIC CLINICAL PROBLEMS

1. Detrusor underactivity

If patients show detrusor underactivity during preoperative uroflowmetry or urodynamics, we cannot expect successful surgical outcomes after MUS. There is a delicate balance after MUS implant between continence and obstruction, and it is difficult to estimate the optimal degree of tension to be applied during surgery, especially in case of detrusor underactivity. If the tape is too loose, incontinence may persist. On the other hand, if the tape is too tight, urinary obstruction could result. Between 0% and 13% complete urinary retention occurs following the TOT procedure [23,24], and tape sectioning or tape adjustment are necessary in up to 5% of the cases [6].

The adjustable MUS has been shown to allow adjustment of tension for a number of days after surgical intervention, thus permitting correction of postoperative incontinence or obstruction [25]. Maroto et al performed the trans-obturator adjustable tape procedure in 77 patients [26]. A total of 69 patients (90%) were objectively continent, 5 (6.5%) had considerable improvement, and in 3 patients (3.5%), the treatment failed. Additional pelvic floor surgery did not have any significant influence ($p=0.519$), neither did the need for adjustment ($p=0.323$).

2. Mixed incontinence

While surgical correction of SUI is associated with good long-term success rates, urgency urinary incontinence (UUI), as an independent entity and as a co-factor in patients with SUI, remains difficult to treat. Whereas patients with mixed urinary incontinence (MUI) undergo anti-incontinence procedures mainly to control predominantly stress-related symptoms, there are unresolved issues about the effect of pre-existing urgency symptoms on postsurgical outcomes, and what mechanisms may underlie any postoperative symptom changes.

A few studies have suggested that UUI may improve after the TVT procedure. Rezapour and Ulmsten reported that not only SUI but also UUI was cured in 85% of the patients and significantly improved in 4% [27]. Segal et al reported that the improvement rate of the irritative subscales on the Urinary Distress Inventory (UDI) for patients with MUI was 87.8% [28]. Paick et al evaluated the outcome at least 6 months after the TVT, SPARC, and TOT procedures in women with MUI [29]. The cure rates in women with MUI were similar following the TVT, SPARC, and TOT procedures (for SUI: TVT, 95.8%; SPARC, 90.0%; TOT, 94.0%; $p=0.625$, and for UUI: TVT, 81.9%; SPARC, 86.4%; TOT, 82.0%; $p=0.965$). Low maximum urethral closure pressure and the presence of uninhibited detrusor contraction during cystometry were deemed independent risk factors for UUI treatment failure.

COMPLICATIONS ASSOCIATED WITH MID-URETHRAL SLINGS

The complication rates following MUS placement are usually considered low. With regard to intraoperative complications, bladder perforations have been reported to occur in 2.5-11.7% of cases, whereas significant bleeding is less common (0.5-2.5%). Postoperative complications included urinary tract infections (0.4-31.5%), de novo urgency (3.1-29%), transient or persistent voiding dysfunction (2.8-38%), and vaginal and/or bladder erosions (0.6-5.4%) [30]. Despite these encouraging figures, some cases of major complications have been reported, including bowel, vascular, and nerve injuries; necrotizing fasciitis; ischiorectal abscess; sepsis; and death.

1. Bladder, urethral, or vaginal perforation

Although the development of trans-obturator tapes or single-incision slings may limit the rate of bladder perforation, urethral or vaginal perforation is another cause of concern regarding this approach. In a meta-analysis of randomized controlled trials comparing complications after MUS procedures, retro pubic approaches caused up to a 24% risk of bladder perforation [31]. According to the devices, trends were identified in favor of TVT for causing bladder perforations, compared with IVS and SPARC. When compared with the retro pubic and trans-obturator approaches, bladder perforation (OR: 2.33; 95% CI: 1.26-4.32; $p=0.007$) was significantly less common in the patients treated by trans-obturator tapes (Table 5). In a recent study on TVT-SECUR, lateral vaginal wall perforation was found in 2.1% (3/141) of women treated with the hammock approach [21]. Neuman reported a 4% incidence of vaginal perforation in their first 100 cases [35]. The TVT-SECUR system requires a wider tunnel to prevent dragging of the vaginal submucosal connective tissue and perforation of the vaginal mucosa when placing the end of the device into the fibrous tissue of the internal obturator muscle.

2. Mesh erosions

Although the complications of bladder and vaginal erosion are well recognized, these complications are inadequately reported in the literature [31]. In a trial conducted in the United Kingdom and Ireland, 175 patients underwent TVT placement, of whom 6 had a tape-related complication within 5 years (erosion into the vagina, obstructed voiding, suprapubic extrusion, or erosion into the bladder), and some presented between 2 and 5 years postoperatively [36]. A further patient presented with vaginal erosion due to TVT placement after 5 years of follow-up and was not included in the 5-year data. Overall, urethral erosion gives a risk of tape-related complications of 4.6% (8/175). The true value may be higher, however, because the full study population has not been surveyed beyond 5 years postoperatively.

The recently published study by Meschia et al reported

TABLE 5. Randomized controlled trials comparing complication rates among mid-urethral sling procedures

Reference	Cases	Follow-up (months)	Bladder/vaginal perforation (%)	Haematoma (%)	Bladder erosions (%)	Vaginal erosion (%)
Rechberger 2003 [11]						
TVT	50	13.5	4	4	0	0
IVS	50		8	2	0	0
Lim 2005 [32]						
TVT	61	1.5-3	1.6	0	3.3	
IVS	60		3.3	0	1.7	
Meschia 2006 [12]						
TVT	95	24	3.3	1.1	0	0
IVS	95		3.4	3.4	0	9
Andonian 2005 [33]						
TVT	43	12	23	0	0	0
SPARC	41		24	2.4	0	2.4
Lim 2005 [32]						
TVT	61	1.5-3	1.6	0	3.3	
SPARC	61		6.6	0	13.1	
Tseng 2005 [13]						
TVT	31	25	0	16.1	29	
SPARC	31		12.9	9.7	9.6	
Lord 2006 [34]						
TVT	147	2	0.7	4.1	NR	NR
SPARC	154		1.9	2.6	NR	NR
Enzelsberger 2005 [15]						
TVT	52	15	7.6	5.7	1.9	
Monarc	53		0	0	1.8	
Laurikainen 2007 [16]						
TVT	136	2.1	2.2	0.7		
TVT-O	131		2.3	0	NR	NR
Zullo 2007 [23]						
TVT	35	16	11	2.8	0	0
TVT-O	37		0	0	0	0

MUS: mid-urethral sling, IVS: intravaginal slingplasty, NR: not reported

that vaginal erosion was significantly more common after IVS than after TVT (IVS, 9%; TVT, 0%; $p=0.009$) [12]. In a meta-analysis, the rate of tape erosion was lower in patients who underwent TVT, although only a nonsignificant trend was observed (OR: 0.26; 95% CI: 0.06-1.03; $p=0.06$) [31]. The incidence of vaginal erosion following retro pubic and trans-obturator tape insertion was similar.

3. Postoperative voiding dysfunction

A multi-institutional study compared obstructive voiding complications between the retro pubic and trans-obturator procedures [37]. Obstructive complications were significantly higher in the retro pubic group (retro pubic, 18.3%; trans-obturator, 11.0%). Minassian et al compared the incidence of voiding dysfunction, defined as urinary retention or post-void residual (PVR) > 200 ml at discharge, among women after three types of anti-incontinence procedures: 63 TVT, 42 Burch colposuspension, and 33 suburethral sling [38]. The incidences were 50%, 15%, and 24%, respectively.

Previous studies have shown associated voiding dysfunction following TVT (range, 4.3-10%) [39,40], as well as de novo overactivity (range, 6-15%) [41,42]. Voiding dys-

function after MUS can also be related to the pre-existing urgency symptom, de novo urgency. According to a study on postoperative urgency treatment, of the 59 patients with pre-existing urgency, 54.2%, 35.6%, and 39.0% demonstrated symptom persistence at postoperative 1, 6, and 12 months, respectively [43]. Of the 32 patients without preoperative urgency, 3.1% and 18.8% of patients demonstrated de novo urgency at 1 and 6 months, respectively, but symptom persistence to 12 months was observed in 6.2%. Overall, urgency lasting 12 months was observed in 25 (27.5%) of the entire cohort.

4. Other complications

Groin pain following the trans-obturator procedure is a troublesome complication, for both patients and surgeons. Laurikainen et al randomly assigned 267 patients to TVT or TVT-O and reported that postoperative groin pain was significantly more common in the TVT-O group than in the TVT group (16% vs. 1.5%, respectively, $p < 0.001$) [16]. In addition, patients in the TVT-O group had significantly longer hospital stays and needed significantly more postoperative opiate analgesia than did the patients in the TVT

group. They also reported a single case of retro pubic hematoma after TVT and urinary tract infections (TVT, 8%; TVT-O, 13%).

MANAGEMENT OF FAILED MID-URETHRAL SLING FOR FEMALE STRESS URINARY INCONTINENCE

Although the MUS procedure is associated with high success rates, its widespread use has led to greater number of failures, increasing the need for an appropriate salvage procedure. Current options for managing failed sling procedures include shortening of the pre-implanted tape, injecting a bulking agent, repeat MUS procedures, retro pubic suspension, and pubovaginal slings.

1. Repeat mid-urethral slings after failure of the initial sling procedure

Liapis et al reported the outcome of TVT in 32 women with failed MUS, showing an objective cure rate of 77% and a subjective cure rate of 71% with a mean follow-up of 18.6 months [44]. In conclusion, they stated that patients who showed recurrent SUI and who had adequate urethral mobility might be candidates for TVT repair. A retrospective study with 29 women who underwent repeat MUS due to persistent or recurrent SUI found that the cure rate was 75.9%, with a mean follow-up of 18.1 months after repeat MUS [45]. In addition, the study also showed that the approach of repeat surgery can affect the outcomes when choosing MUS to salvage a failed sling. The cure rate was lower in women who received trans-obturator slings (62.5%) than in women who received retro pubic slings (92.3%) after repeat MUS. Although the cohort of the study was too small to make a meaningful comparison, other studies also showed a lower cure rate of the trans-obturator approach as a repeat MUS procedure compared with the retro pubic approach [46,47]. A possible explanation for the difference in the cure rate of repeat retro pubic and trans-obturator procedures is the angle of the tape supporting the mid-urethra. The retro pubic sling has a U shape, which may be more supportive and obstructive than the trans-obturator modifications. Another explanation is that the approach from outside the trans-obturator procedure requires wider dissection of the periurethral area, which may cause migration of the tape.

2. Pubovaginal sling after failed mid-urethral slings

Anti-incontinence procedures may yield a fixed, scarred urethra, which leads to lower success rates, as seen in patients with intrinsic sphincter deficiency (ISD) and those with no urethral hypermobility. Liapis et al showed a lower success rate (30%) among women with a fixed urethra [48]. Although it is difficult to compare the success rates due to differing primary procedures (e.g., pubovaginal sling, collagen, MUS), the critical risk factor for failure that has been suggested in some studies is a fixed urethra [27,49-52]. Several studies have also looked at pubovaginal slings in the treatment of recurrent SUI with success rates of 50%

to 90% [53-55]. Although the use of pubovaginal slings in women who have failed MUS procedures has not been studied, a pubovaginal sling may offer more advantages in women who have a scarred, less mobile urethra and with more severe degrees of ISD.

3. Bulking agent injection after failure of the initial sling procedure

A peri-urethral injection in patients with a failed sling has shown good clinical efficacy when used to salvage failed anti-incontinence procedures [56]. Of the 5 patients with failure in the study, peri-urethral injections resulted in cure in 3 patients and improvement in 1.

EVALUATION AND MANAGEMENT OF VOIDING DYSFUNCTION AFTER MID-URETHRAL SLING PROCEDURES

1. Evaluation of voiding dysfunction after MUS procedures

Voiding dysfunction after a sling procedure may be due to urethral obstruction from hyper-elevation of the bladder neck or an exaggerated kink in the urethra. These symptoms could be obstructive (hesitancy, slow stream, intermittency, feeling of incomplete voiding, need to strain or void in the half-standing position) or irritative (pain, frequency, dysuria, nocturia, urgency, urge incontinence). A detailed clinical history is elemental in the detection of urinary symptoms suggestive of infravesical obstruction. The most important aspect of the history is to ascertain the absence of obstructive symptoms before the sling procedure. Abdominal and vaginal examinations should be performed to evaluate the presence of scars, erosions, residual bladder neck mobility, and associated prolapse. The presence of exaggerated urethral or urethrovesical junction angulation with a high, fixed urethra located in the retro pubic area is suggestive of urethral hypercorrection [57]. Although there is no established cutoff between normal and abnormal PVR, and no evidence of correlation between PVR and symptoms of obstructive voiding, PVR of more than 100 ml is considered abnormal in women [58-60]. Blaivas and Groutz proposed an obstruction nomogram for women on the basis of free maximal flow rate and maximal detrusor pressure during pressure-flow study [61]. The nomogram characterizes patients into four categories: no obstruction, mild obstruction, moderate obstruction, and severe obstruction. Massolt et al compared obstructive symptoms according to a standardized questionnaire with the Blaivas-Groutz nomogram and found no correlation between the severity of symptoms and the degree of obstruction related to the four nomogram categories [62]. Occasionally, cystourethroscopy may be indicated to rule out an eroded tape or tumors in the urethra or bladder [57].

In summary, there is no specific investigation to confirm obstruction in patients. The diagnosis relies on several parameters that must confirm clinical suspicion. The history of initial symptoms following MUS procedure, low peak flow rate, high voiding pressure, significant PVR, and ab-

TABLE 6. Outcome of case series involving surgical treatment of urethral obstruction after the TVT procedure

Reference	Patients, n	Procedure	Time to procedure	Recurrent SUI rate (%)	Follow-up
Glavind and Glavind 2007 [66]	5	Tape pull-down	2.2 weeks	0	NR
	2	Midline sling incision	5 and 7 months	100	NR
Zubke et al. 2004 [67]	3	Midline sling incision and polypropylene mesh prolongation	NR	0	NR
Croak et al. 2003 [68]	5	Midline sling incision	NR	20	NR
Rardin et al. 2002 [69]	23	Midline sling incision	17.3 weeks	13	6 weeks
Klutke et al. 2001 [70]	17	Tape release (incision or loosening)	64 days	5.9	13 months

TVT: tension-free vaginal tape, NR: not reported

normal urethral calibrating must all be considered for a conclusive diagnosis of urethral obstruction.

2. Management of voiding dysfunction after MUS procedures

The initial management of a patient after a MUS procedure should place her in one of the two following categories: acute complete urinary retention or chronic urinary retention with obstructive voiding dysfunction. If the patient is in the first category, a voiding trial should be performed within 48-72 hours following surgery. However, if the patient presents with signs and symptoms of dysfunctional obstructive voiding indicative of chronic urinary retention, the approach may vary. In an Australasian survey that included 74 respondents who had performed 1,549 polypropylene sling procedures (TVT or suprapubic arc sling), 95 cases (6.5%) of urinary retention were reported [63]. Most were managed conservatively by clean intermittent self-catheterization (38%) or indwelling urethral catheterization (35%). Thirty-three women required operative management by sling division (20%), early sling loosening by traction (7%), and urethrolisis with sling removal (7%). A combination of initial conservative management followed by surgery was needed in 7 patients (7%).

A multi-institutional review of 241 women who had undergone the TVT procedure revealed 47 women who developed urinary retention for more than 24 hours. Of these women, 68% experienced resolution of urinary retention in the first 48 hours after surgery and 11% were managed with intermittent catheterization or an indwelling Foley catheter [64]. The remaining patients underwent different treatments: 7 had tape release and 3 had tape incision. There is no consensus on the appropriate surgical revision techniques. Tape release, urethrolisis, and sling incision can be options as surgical treatment for voiding dysfunction after MUS.

The rate of recurrent SUI after surgical treatment of urethral obstruction was reported to be up to 36%, except in a study with 2 patients [65]. Table 6 summarizes case series reporting the surgical management of urinary retention after sling procedures.

Another important issue is the optimal time for further treatment, such as anti-muscarinic agents in cases where

urgency is present postoperatively. A study evaluating the optimal time for overactive bladder symptoms after MUS recommended treatment if urgency is noted at 1 month postoperatively in patients with pre-existing urgency and after 6 months for those without preoperative urgency [39].

CONCLUSIONS

MUS has proven efficacy and is now a mainstay in the surgical management of female SUI. Prospective data indicate little clinical difference between the retro pubic and the trans-obturator approach, or indeed between various devices used within each technique. Surgeons must be prepared to identify and correct postoperative complications and voiding dysfunction. In addition, they should be trained in the diagnosis and treatment of failed MUS procedures.

Conflicts of Interest

The authors have nothing to disclose.

REFERENCES

- Petros PE, Ulmsten UI. An integral theory of female urinary incontinence. Experimental and clinical considerations. *Acta Obstet Gynecol Scand Suppl* 1990;153:7-31.
- Petros PEP, Woodman PJ. The integral theory of continence. *Int Urogynecol J Pelvic Floor Dysfunct* 2008;19:35-40.
- Ulmsten U, Henriksson L, Johnson P, Varhos G. An ambulatory surgical procedure under local anesthesia for treatment of female urinary incontinence. *Int Urogynecol J Pelvic Floor Dysfunct* 1996;7:81-5.
- Delorme E. Transobturator urethral suspension: mini-invasive procedure in the treatment of stress urinary incontinence in women. *Prog Urol* 2001;11:1306-13.
- Doo CK, Hong B, Chung BJ, Kim JY, Jung HC, Lee KS, et al. Five-year outcomes of the tension-free vaginal tape procedure for treatment of female stress urinary incontinence. *Eur Urol* 2006;50:333-8.
- Juang CM, Yu KJ, Chou P, Yen MS, Twu NF, Horng HC, et al. Efficacy analysis of trans-obturator tension-free vaginal tape (TVT-O) plus modified Ingelman-Sundberg procedure versus TVT-O alone in the treatment of mixed urinary incontinence: a randomized study. *Eur Urol* 2007;51:1671-8.
- Davila GW, Johnson JD, Serels S. Multicenter experience with the Monarc transobturator sling system to treat stress urinary

- incontinence. *Int Urogynecol J Pelvic Floor Dysfunct* 2006;17:460-5.
8. Bai SW, Sohn WH, Chung DJ, Park JH, Kim SK. Comparison of the efficacy of Burch colposuspension, pubovaginal sling, and tension-free vaginal tape for stress urinary incontinence. *Int J Gynaecol Obstet* 2005;91:246-51.
 9. Wadie BS, Edwan A, Nabeeh AM. Autologous fascial sling vs polypropylene tape at short-term followup: A prospective randomized study. *J Urol* 2005;174:990-3.
 10. Novara G, Ficarra V, Boscolo-Berto R, Secco S, Cavalleri S, Artibani W. Tension-free midurethral slings in the treatment of female stress urinary incontinence: a systematic review and meta-analysis of Randomized controlled trials of effectiveness. *Eur Urol* 2007;52:663-79.
 11. Rechberger T, Rzezniczuk K, Skorupski P, Adamiak A, Tomaszewski J, Baranowski W, et al. A randomized comparison between monofilament and multifilament tapes for stress incontinence surgery. *Int Urogynecol J Pelvic Floor Dysfunct* 2003;14:432-6.
 12. Meschia M, Pifarotti P, Bernasconi F, Magatti F, Vigano R, Bertozzi R, et al. Tension-free vaginal tape (TVT) and intravaginal slingplasty (IVS) for stress urinary incontinence: a multicenter randomized trial. *Am J Obstet Gynecol* 2006;195:1338-42.
 13. Tseng LH, Wang AC, Lin YH, Li SJ, Ko YJ. Randomized comparison of the suprapubic arc sling procedure vs tension-free vaginal taping for stress incontinent women. *Int Urogynecol J Pelvic Floor Dysfunct* 2005;16:230-5.
 14. Gandhi S, Abramov Y, Kwon C, Beaumont JL, Botros S, Sand PK, et al. TVT versus SPARC: comparison of outcomes for two midurethral tape procedures. *Int Urogynecol J Pelvic Floor Dysfunct* 2006;17:125-30.
 15. Enzelsberger H, Schalupny J, Heider R, Mayer G. TVT versus TOT - A prospective randomized study for the treatment of female stress urinary incontinence at a follow-up of 1 year. *Geburtshilfe Und Frauenheilkunde* 2005;65:506-11.
 16. Laurikainen E, Valpas A, Kivela A, Kalliola T, Rinne K, Takala T, et al. Retropubic compared with transobturator tape placement in treatment of urinary incontinence: a randomized controlled trial. *Obstet Gynecol* 2007;109:4-11.
 17. Lee KS, Han DH, Choi YS, Yum SH, Song SH, Doo CK, et al. A prospective trial comparing tension-free vaginal tape and transobturator vaginal tape inside-out for the surgical treatment of female stress urinary incontinence: 1-year follow up. *J Urol* 2007;177:214-8.
 18. Latthe PM, Foon R, Toozs-Hobson P. Transobturator and retropubic tape procedures in stress urinary incontinence: a systematic review and meta-analysis effectiveness and complications. *BJOG* 2007;114:522-31.
 19. Lee KS, Choo MS, Lee YS, Han JY, Kim JY, Jung BJ, et al. Prospective comparison of the 'inside-out' and 'outside-in' transobturator-tape procedures for the treatment of female stress urinary incontinence. *Int Urogynecol J Pelvic Floor Dysfunct* 2008;19:577-82.
 20. Debodinance P. Trans-obturator urethral sling for the surgical correction of female stress urinary incontinence: outside-in (Monarc) versus inside-out (TVT-O). Are the two ways reassuring? *Eur J Obstet Gynecol Reprod Biol* 2007;133:232-8.
 21. Lee KS, Lee YS, Seo JT, Na YG, Choo MS, Kim JC, et al. A prospective multicenter randomized comparative study between the U- and H-type methods of the TVT Secur procedure for the treatment of female stress urinary incontinence: 1-Year follow-up. *Eur Urol* 2010;Epub ahead of print
 22. Meschia M, Barbacini P, Ambrogi V, Pifarotti P, Ricci L, Spreafico L. TVT-secur: a minimally invasive procedure for the treatment of primary stress urinary incontinence. One year data from a multi-centre prospective trial. *Int Urogynecol J Pelvic Floor Dysfunct* 2009;20:313-7.
 23. Zullo MA, Plotti F, Calcagno M, Marullo E, Palaia I, Bellati F, et al. One-year follow-up of tension-free vaginal tape (TVT) and trans-obturator suburethral tape from inside to outside (TVT-O) for surgical treatment of female stress urinary incontinence: A prospective randomised trial. *Eur Urol* 2007;51:1376-84.
 24. deTayrac R, Deffieux X, Droupy S, Chauveaud-Lambling A, Calvanese-Benamour L, Fernandez H. A prospective randomized trial comparing tension-free vaginal tape and transobturator suburethral tape for surgical treatment of stress urinary incontinence. *Am J Obstet Gynecol* 2004;190:602-8.
 25. Maroto JR, Gorraiz MO, Chaparro LP, Bru JJP, Bueno JJM, Lopez CL. Transvaginal adjustable tape: an adjustable mesh for surgical treatment of female stress urinary incontinence. *Int Urogynecol J Pelvic Floor Dysfunct* 2008;19:1109-16.
 26. Maroto JR, Gorraiz MO, Bueno JJM, Perez LG, Bru JJP, Chaparro LP. Transobturator adjustable tape (TOA) permits to correct postoperatively the tension applied in stress incontinence surgery. *Int Urogynecol J Pelvic Floor Dysfunct* 2009;20:797-805.
 27. Rezapour M, Ulmsten U. Tension-Free vaginal tape (TVT) in women with mixed urinary incontinence-a long-term follow-up. *Int Urogynecol J Pelvic Floor Dysfunct* 2001;12 (Suppl 2):S15-8.
 28. Segal JL, Vassallo B, Kleeman S, Silva WA, Karram MM. Prevalence of persistent and de novo overactive bladder symptoms after the tension-free vaginal tape. *Obstet Gynecol* 2004;104:1263-9.
 29. Paick JS, Oh SJ, Kim SW, Ku JH. Tension-free vaginal tape, suprapubic arc sling, and transobturator tape in the treatment of mixed urinary incontinence in women. *Int Urogynecol J Pelvic Floor Dysfunct* 2008;19:123-9.
 30. Artibani W. Complications of surgery for stress incontinence. In: Cardozo L, Staskin L, editors. *Textbook of female urology and urogynecology*. 2nd ed. Taylor & Francis Ltd; 2007;1345-62.
 31. Novara G, Galfano A, Boscolo-Berto R, Secco S, Cavalleri S, Ficarra V, et al. Complication rates of tension-free midurethral slings in the treatment of female stress urinary incontinence: a systematic review and meta-analysis of randomized controlled trials comparing tension-free midurethral tapes to other surgical procedures and different devices. *Eur Urol* 2008;53:288-308.
 32. Lim YN, Muller R, Corstiaans A, Dietz HP, Barry C, Rane A. Suburethral slingplasty evaluation study in North Queensland, Australia: the SUSPEND trial. *Aust N Z J Obstet Gynaecol* 2005;45:52-9.
 33. Andonian S, Chen T, St-Denis B, Corcos J. Randomized clinical trial comparing suprapubic arch sling (SPARC) and tension-free vaginal tape (TVT): one-year results. *Eur Urol* 2005;47:537-41.
 34. Lord HE, Taylor JD, Finn JC, Tsokos N, Jeffery JT, Atherton MJ, et al. A randomized controlled equivalence trial of short-term complications and efficacy of tension-free vaginal tape and suprapubic urethral support sling for treating stress incontinence. *BJU Int* 2006;98:367-76.
 35. Neuman M. Perioperative complications and early follow-up with 100 TVT-SECUR procedures. *J Minim Invasive Gynecol* 2008;15:480-4.
 36. Ward KL, Hilton P. Tension-free vaginal tape versus colposuspension for primary urodynamic stress incontinence: 5-year follow up. *BJOG* 2008;115:226-33.
 37. Morey AF, Medendorp AR, Noller MW, Mora RV, Shandera KC,

- Foley JP, et al. Transobturator versus transabdominal mid urethral slings: a multi-institutional comparison of obstructive voiding complications. *J Urol* 2006;175:1014-7.
38. Minassian VA, Al-Badr A, Drutz HP, Lovatsis D. Tension-free vaginal tape, Burch, and slings: are there predictors for early post-operative voiding dysfunction? *Int Urogynecol J Pelvic Floor Dysfunct* 2004;15:183-7.
 39. Karram MM, Segal JL, Vassallo BJ, Kleeman SD. Complications and untoward effects of the tension-free vaginal tape procedure. *Obstet Gynecol* 2003;101:929-32.
 40. Dorflinger A, Monga A. Voiding dysfunction. *Curr Opin Obstet Gynecol* 2001;13:507-12.
 41. Haab F, Sananes S, Amarenco G, Ciofu C, Uzan S, Gattegno B, et al. Results of the tension-free vaginal tape procedure for the treatment of type II stress urinary incontinence at a minimum followup of 1 year. *J Urol* 2001;165:159-62.
 42. Moran PA, Ward KL, Johnson D, Smirni WE, Hilton P, Bibby J. Tension-free vaginal tape for primary genuine stress incontinence: a two-centre follow-up study. *BJU Int* 2000;86:39-42.
 43. Song C, Park SH, Han JY, Lee KS, Choo MS. Identification of the optimal time to treat urgency after a midurethral sling procedure for stress urinary incontinence. *Int Urogynecol J Pelvic Floor Dysfunct* 2008;19:573-6.
 44. Liapis A, Bakas P, Creatsas G. Tension-free vaginal tape in the management of recurrent urodynamic stress incontinence after previous failed midurethral tape. *Eur Urol* 2009;55:1450-5.
 45. Lee KS, Doo CK, Han DH, Jung BJ, Han JY, Choo MS. Outcomes following repeat mid urethral synthetic sling after failure of the initial sling procedure: rediscovery of the tension-free vaginal tape procedure. *J Urol* 2007;178:1370-4.
 46. Tsivian A, Neuman M, Yulish E, Shtricker A, Levin S, Cytron S, et al. Redo midurethral synthetic sling for female stress urinary incontinence. *Int Urogynecol J Pelvic Floor Dysfunct* 2007;18:23-6.
 47. Moore RD, Gamble K, Miklos JR. Tension-free vaginal tape sling for recurrent stress incontinence after transobturator tape sling failure. *Int Urogynecol J Pelvic Floor Dysfunct* 2007;18:309-13.
 48. Liapis A, Bakas P, Lazaris D, Creatsas G. Tension-free vaginal tape in the management of recurrent stress incontinence. *Arch Gynecol Obstet* 2004;269:205-7.
 49. Azam U, Frazer MI, Kozman EL, Ward K, Hilton P, Rane A. The tension-free vaginal tape procedure in women with previous failed stress incontinence surgery. *J Urol* 2001;166:554-6.
 50. Rardin CR, Kohli N, Rosenblatt PL, Miklos JR, Moore R, Strohsnitter WC. Tension-free vaginal tape: outcomes among women with primary versus recurrent stress urinary incontinence. *Obstet Gynecol* 2002;100:893-7.
 51. Lo TS, Horng SG, Chang CL, Huang HJ, Tseng LH, Liang CC. Tension-free vaginal tape procedure after previous failure in incontinence surgery. *Urology* 2002;60:57-61.
 52. Kuuva N, Nilsson CG. Tension-free vaginal tape procedure: an effective minimally invasive operation for the treatment of recurrent stress urinary incontinence? *Gynecol Obstet Invest* 2003;56:93-8.
 53. Petrou SP, Frank I. Complications and initial continence rates after a repeat pubovaginal sling procedure for recurrent stress urinary incontinence. *J Urol* 2001;165:1979-81.
 54. Blaivas JG, Jacobs BZ. Pubovaginal fascial sling for the treatment of complicated stress urinary incontinence. *J Urol* 1991;145:1214-8.
 55. Breen JM, Geer BE, May GE. The fascia lata suburethral sling for treating recurrent urinary stress incontinence. *Am J Obstet Gynecol* 1997;177:1363-5.
 56. Lightner D, Calvosa C, Andersen R, Klimberg I, Brito CG, Snyder J, et al. A new injectable bulking agent for treatment of stress urinary incontinence: results of a multicenter, randomized, controlled, double-blind study of Durasphere. *Urology* 2001;58:12-5.
 57. Nguyen JK. Diagnosis and treatment of voiding dysfunction caused by urethral obstruction after anti-incontinence surgery. *Obstet Gynecol Surv* 2002;57:468-75.
 58. Pfisterer MH, Griffiths DJ, Rosenberg L, Schaefer W, Resnick NM. Parameters of bladder function in pre-, peri-, and postmenopausal continent women without detrusor overactivity. *Neurourol Urodyn*. 2007;26:356-61.
 59. Suebnukanwattana T, Lohsiriwat S, Chaikomin R, Tantiwongse A, Soontrapa S. Uroflowmetry in normal Thai subjects. *J Med Assoc Thai* 2003;86:353-60.
 60. Al-Shahrani M, Lovatsis D. Do subjective symptoms of obstructive voiding correlate with post-void residual urine volume in women? *Int Urogynecol J Pelvic Floor Dysfunct* 2005;16:12-4.
 61. Blaivas JG, Groutz A. Bladder outlet obstruction nomogram for women with lower urinary tract symptomatology. *Neurourol Urodyn* 2000;19:553-64.
 62. Massolt ET, Groen J, Vierhout ME. Application of the Blaivas-Groutz bladder outlet obstruction nomogram in women with urinary incontinence. *Neurourol Urodyn* 2005;24:237-42.
 63. Hammad FT, Kennedy-Smith A, Robinson RG. Erosions and urinary retention following polypropylene synthetic sling: Australasian survey. *Eur Urol* 2005;47:641-6.
 64. Abouassaly R, Steinberg JR, Lemieux M, Marois C, Gilchrist LI, Bourque JL, et al. Complications of tension-free vaginal tape surgery: a multi-institutional review. *BJU Int* 2004;94:110-3.
 65. Campeau L, Al-Afraq T, Corcos J. Evaluation and management of urinary retention after a suburethral sling procedure in women. *Curr Urol Rep* 2008;9:412-8.
 66. Glavind K, Glavind E. Treatment of prolonged voiding dysfunction after tension-free vaginal tape procedure. *Acta Obstet Gynecol Scand* 2007;86:357-60.
 67. Zubke W, Becker S, Kramer B, Wallwiener D. Persistent urinary retention after tension-free vaginal tape: a new surgical solution. *Eur J Obstet Gynecol Reprod Biol* 2004;115:95-8.
 68. Croak AJ, Schulte V, Peron S, Klingele C, Gebhart J, Lee R. Transvaginal tape lysis for urinary obstruction after tension-free vaginal tape placement. *J Urol* 2003;169:2238-41.
 69. Rardin CR, Rosenblatt PL, Kohli N, Miklos JR, Heit M, Lucente VR. Release of tension-free vaginal tape for the treatment of refractory postoperative voiding dysfunction. *Obstet Gynecol* 2002;100:898-902.
 70. Klutke C, Siegel S, Carlin B, Paszkiewicz E, Kirkemo A, Klutke J. Urinary retention after tension-free vaginal tape procedure: incidence and treatment. *Urology* 2001;58:697-701.