

CASE REPORT

A Case of Faun Tail Naevus Treated by Intense Pulsed Light

Hye In Lee, M.D., Yong Kwan Rho, M.D., Beom Joon Kim, M.D., Myeung Nam Kim, M.D.

Department of Dermatology, College of Medicine, Chung-Ang University, Seoul, Korea

A faun tail is abnormal lumbar hypertrichosis that is characterized by a wide, often triangular or lozenge-shaped patch of coarse hair, and this hair is usually several inches long. Faun tail is a rare entity. A 36-year-old male presented with a triangular shaped hair tuft with terminal hair on the lumbosacral area, and he'd had this unusual hair since birth. There were no neurologic signs or abnormality on his spine X-ray. The MRI scan showed disc degeneration and loss of lordosis. We report here on a rare case of faun tail, which was a form of localized hypertrichosis on the lumbosacral area, and this was successfully treated with intense pulsed (IPL) light. (**Ann Dermatol 21(2) 147~149, 2009**)

-Keywords-

Faun tail, Hypertrichosis, Intense pulsed light

INTRODUCTION

Hypertrichosis is the excessive growth of hair on the non-androgen dependent areas of the body. Primary hypertrichosis has been classified based on the age of onset as to whether it is congenital or acquired, and the extent of distribution takes on either localized or generalized forms. Primary localized hypertrichosis may occur as hypertrichosis cubiti involving the elbows, anterior cervical hypertrichosis, posterior cervical hypertrichosis or a faun tail deformity¹. A faun tail is a lock of coarse, terminal hair situated on the lumbosacral area. According to the Korean dermatologic articles²⁻⁵, only four cases with faun tail have been reported in association with

tethered cord syndrome or spina bifida occulta. We report herein on an interesting case of a bazaar faun tail naevus on a 36-year-old male.

CASE REPORT

A 36-year-old man was referred to our dermatology outpatient clinic for the treatment of a congenital focal hypertrichotic area on the lumbosacral region because it was cosmetically embarrassing. The dermatologic examination revealed a localized, 3.0×5.0 cm sized, reverse triangular shaped hair tuft on the lumbosacral region. Coarse, dark, terminal hairs were observed and there was a single skin colored protruding papule within the hairs (Fig. 1A). The lesion had been present since his birth. The past medical history was noncontributory except for psoriasis vulgaris. No motor weakness or sensory changes were observed on the neurological examination. His height was estimated to be 156 cm. There was no history of a similar lesion in the family and relatives. The complete blood cell count, erythrocyte sedimentation rate and blood chemistry were all within the normal ranges. Simple lumbosacral radiography showed no specific finding. The magnetic resonance imaging scan showed no specific finding, except for a left subarticular protrusion of L4-5 and the loss of lordosis of the lumbar spine. The skin biopsy from the hypertrichotic patch demonstrated normal epidermis and a superficial perivascular lymphocytic infiltration with mature terminal hair follicles in the dermis (Fig. 2). The other biopsy revealed a skin tag. A diagnosis of faun tail without any underlying neurologic disease was made. He was periodically treated with intense pulsed light (IPL) for hair removal and he was well satisfied with the result (Fig. 1B).

Received June 3, 2008, Accepted for publication August 5, 2008

Reprint request to: Beom Joon Kim, M.D., Department of Dermatology, Chung-Ang University Yong-San Hospital, 65-207, Hangangro 3-ga, Yongsan-gu, Seoul 140-757, Korea. Tel: 82-2-748-9898, Fax: 82-2-6359-9573, E-mail: beomjoon@unitel.co.kr

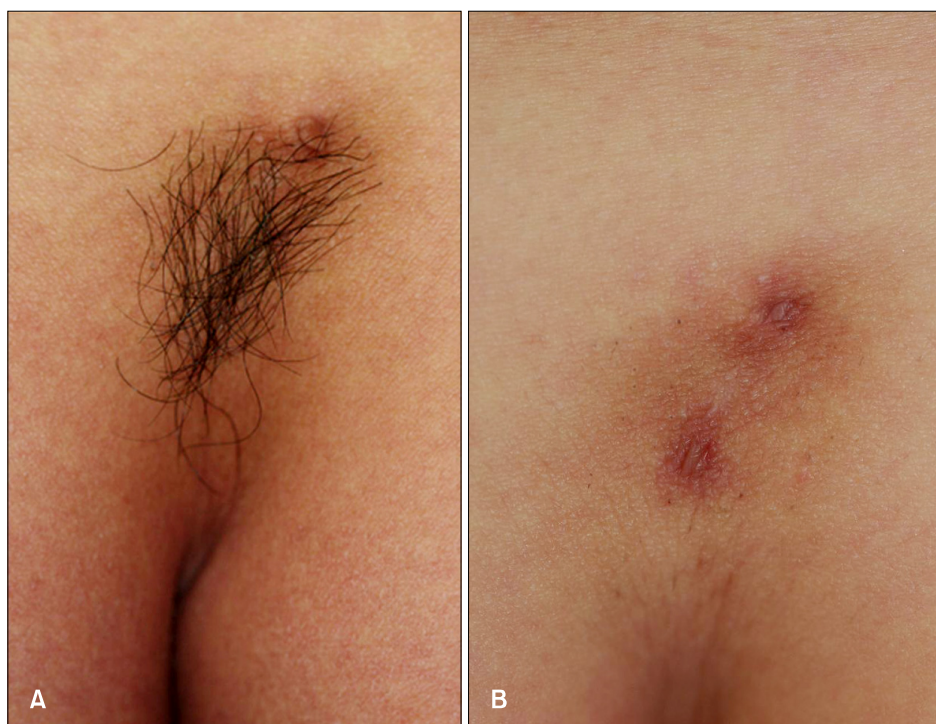

Fig. 1. (A) A localized reverse triangular shaped hair tuft with terminal hairs on the lumbosacral area. (B) The area after 3 treatment sessions with intense pulsed light (IPL) at 3 week intervals.

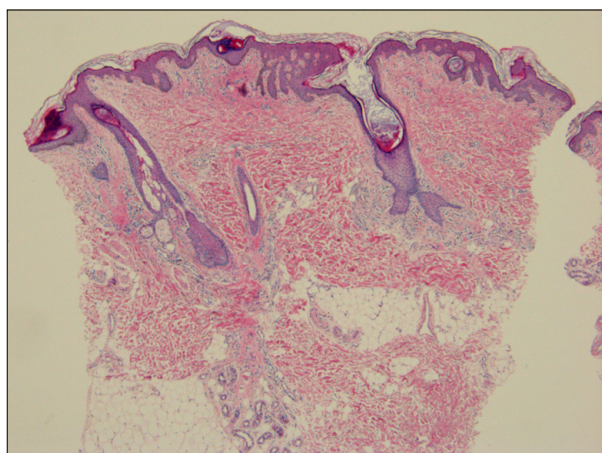


Fig. 2. The histologic findings showed a normal epidermis and a superficial perivascular lymphocytic infiltration in the terminal hair follicles in the dermis (H&E, $\times 100$).

DISCUSSION

Hypertrichosis is a condition of excessive hair growth that must be distinguished from hirsutism, which is characterized by an androgen-dependent hair pattern with an excessive body and facial terminal hair distribution in a male pattern¹. Localized hypertrichosis can be categorized into the acquired and congenital forms. Congenital localized hypertrichosis is present at birth or early in life without any inducing factors¹. Congenital localized hyper-

trichosis is most commonly located in the sacral area and this is called "faun tail".

The mechanisms for excess hair growth have not been well established. Clinical evidence exists that localized or site-specific factors may be important in determining the fate of a hair follicle. Conversion of vellus or fine caliber hairs to thicker terminal hairs occurs as a result of hormonal changes, but only at androgendependent sites such as the beard, chest, axillae and groin⁶. Congenital localized hypertrichosis in hamartomas or underlying neurologic abnormalities may represent an alternative pathway. Recent research has suggested the tremendous plasticity of the hair follicle, its mesenchyme and the surrounding connective tissue sheath, which allows for dramatic transformations of hair follicles. Localized hypertrichosis may therefore be a reflection of an abnormal signal for enlargement of the follicular papilla, a prolongation of the normal anagen hair growth cycle or both⁷.

The clinical importance of a midline cutaneous posterior anomaly is that they are frequently associated with underlying defects such as diastematomyelia, meningocele, spina bifida, kyphoscoliosis or chest deformities. As both skin and nervous tissue are of an ectodermal origin, anomalies of these tissues may occur simultaneously. When the congenital localized hypertrichosis is located away from the spine in apparently normal skin, it has been named as simple nevoid hypertrichosis, and it is usually a totally benign lesion⁸. The cutaneous lesions that should

raise a higher degree of suspicion include hypertrichosis, dimples, aplasia cutis, lipoma, hemangioma, dermoid cyst or sinus, acrochordons, true tail, pseudotail and congenital scarring^{9,10}. Thus, localized hypertrichosis may be a clue for an underlying defect, some of which are surgically correctable at an early age. Sacral hypertrichosis is also known as faun tail naevus, and this is the most common skin lesion that is evident at birth¹¹, as was seen in our patient. Hairy patches are most frequently associated with tethered cord and diastematomyelia¹². Although our case demonstrated no underlying neurologic problem associated with his localized hypertrichosis, accurate screening modalities such as MRI are necessary to detect any underlying dysraphic anomalies and to prevent the occurrence or progression of the neurologic deficit by timely intervention before neurological damage has occurred.

As for the management of hypertrichosis, long-term removal of unwanted hair is a challenge. The need for treatment depends on the degree of hypertrichosis and the psychosocial needs of the patient. The currently available treatment methods for removal of excessive hair include bleaching, trimming, waxing, physical and chemical depilatories, electrolysis, intense pulsed light therapy and laser hair removal¹³. A variety of laser devices and intense pulsed light therapy are now available. All are based on the principle of selective photothermolysis; the melanin pigment in the hair follicle provides the chromophore for selective targeting of hair follicles, while the surrounding dermis is spared. Therefore, at deeply penetrating wavelengths in the 600~1,100 nm range, melanin absorption may be used for selective photothermolysis of hair follicles¹⁴. Intense pulsed light source (590~1200 nm) therapy for hair removal seems to be more effective for darker hair¹⁵. Because our patient's lumbosacral hair was dark and thick like his axillary hair, we choose intense pulsed light therapy for hair removal. Occasionally, post-treatment erythema, edema, blisters and hyperpigmentation can occur.

The aim of this paper is to draw attention to faun tail and to emphasize the responsibility of physicians and cosmeticians to the recognize early in patients' lives lumbar paraspinal skin lesions so that appropriate early treatment can be administered for the possible underlying anomalies before the irreversible sequelae develop. Although other-

wise benign, these disorders may result in cosmetic disfigurement and psychosocial trauma for the patients. These patients should be adequately advised of the available treatment methods for both temporary and permanent hair removal.

REFERENCES

1. Vashi RA, Mancini AJ, Paller AS. Primary generalized and localized hypertrichosis in children. *Arch Dermatol* 2001; 137:877-884.
2. Choi JS, Lee WH, Lee JB. Circumscribed hypertrichosis and blue nevus with spina bifida occulta. *Korean J Dermatol* 1981;19:365-369.
3. Suhr GB, Lee JS, Lee JH, Park JK. A case of spina bifida occulta with faun-tail nevus. *Korean J Dermatol* 1988;26: 759-763.
4. Kim SW. Faun tail. *Ann Dermatol* 1993;5:47-50.
5. Bak H, Kim JY, Chung YL, Kim SC. A case of faun tail associated with tethered cord syndrome. *Korean J Dermatol* 2004;42:781-783.
6. Drolet B. Birthmarks to worry about. *Cutaneous markers of dysraphism. Dermatol Clin* 1998;16:447-453.
7. McAtee-Smith J, Hebert AA, Rapini RP, Goldberg NS. Skin lesions of the spinal axis and spinal dysraphism. Fifteen cases and a review of the literature. *Arch Pediatr Adolesc Med* 1994;148:740-748.
8. Tobin DJ, Gunin A, Magerl M, Handijski B, Paus R. Plasticity and cytokinetic dynamics of the hair follicle mesenchyme: implications for hair growth control. *J Invest Dermatol* 2003;120:895-904.
9. Bertolino AP, Freedberg IM. Hair. In: Fitzpatrick TB, Eisen AZ, Wolff K, editors. *Dermatology in general medicine*. New York: McGraw-Hill, 1987:627-666.
10. Ettl A, Marinkovic M, Koornneef L. Localized hypertrichosis associated with periorbital neurofibroma: clinical findings and differential diagnosis. *Ophthalmology* 1996;103:942-948.
11. Kumar R, Singh SN. Spinal dysraphism: trends in northern India. *Pediatr Neurosurg* 2003;38:133-145.
12. Tavafoghi V, Ghandchi A, Hambrick GW Jr, Udverhelyi GB. Cutaneous signs of spinal dysraphism. Report of a patient with a tail-like lipoma and review of 200 cases in the literature. *Arch Dermatol* 1978;114:573-577.
13. Trueb RM. Causes and management of hypertrichosis. *Am J Clin Dermatol* 2002;3:617-627.
14. Liew SH. Laser hair removal: guidelines for management. *Am J Clin Dermatol* 2002;3:107-115.
15. Olsen EA. Methods of hair removal. *J Am Acad Dermatol* 1999;40:143-155.